



Educational Case

Educational Case: Ovarian neoplasms: A series of educational cases to review malignancies of epithelial, stromal, and germ cell origin



Jordyn B. Tumas, MD^{a,*},†, Joanna Chan, MD^b

^a Mount Sinai West Hospital, New York, NY, USA

^b Thomas Jefferson University Hospital, Philadelphia, PA, USA

The following fictional case is intended as a learning tool within the Pathology Competencies for Medical Education (PCME), a set of national standards for teaching pathology. These are divided into three basic competencies: Disease Mechanisms and Processes, Organ System Pathology, and Diagnostic Medicine and Therapeutic Pathology. For additional information, and a full list of learning objectives for all three competencies, see <https://www.journals.elsevier.com/academic-pathology/news/pathology-competencies-for-medical-education-pcme>.¹

Keywords: Diagnostic studies, Differential diagnosis, Female reproductive system – ovary, Organ system pathology, Ovarian neoplasia, Pathology competencies, Special studies, Surgical pathology

Primary objective

Objective FO1.2: Causes of Ovarian Neoplasm: Describe the risk factors, genetic associations, and molecular basis, including hereditary cancer syndromes, for ovarian neoplasms, including those derived from epithelium, sex-cord stromal as well as germ cell neoplasms.

Competency 2: Organ System Pathology; Topic FO: Female Reproductive—Ovary; Learning Goal 1: Ovarian Neoplasia

Secondary objectives

Objective SP1.2: Differential Diagnosis: List the major differential diagnoses for each type of cytology or surgical pathology specimen derived from a lesion or mass and describe appropriate further studies, both special stains and immunohistochemistry.

Competency 3: Diagnostic Medicine and Therapeutic Pathology; Topic SP: Surgical Pathology; Learning Goal 1: Role in Diagnosis

Objective SP1.3: Special Studies: After looking at slides of a tissue lesion or mass, the pathologist makes a diagnosis. List options for surgical and nonsurgical treatment and describe prognostic and therapy-guiding tests that may be performed on the tissue.

Competency 3: Diagnostic Medicine and Therapeutic Pathology; Topic SP: Surgical Pathology; Learning Goal 1: Role in Diagnosis

Patient presentation #1

A 72-year-old woman presents to her gynecologist for an annual health maintenance visit. She has noticed that over the last few weeks, she has been feeling winded when walking up the stairs in her home. In addition, she has been experiencing early satiety and abdominal bloating but assumes it to be related to her eating habits. She has well-controlled diabetes and a past surgical history of a cholecystectomy. She is post-menopausal, has had no vaginal bleeding, and has no history of abnormal pap smears. Family history reveals that a cousin on her mother's side was diagnosed with breast cancer in her early 50s.

Diagnostic findings, Patient 1, Part 1

On physical examination, vital signs are within normal limits, and the patient is well-appearing. Cardiac exam is normal. There are decreased lung sounds at the bases of both lungs upon auscultation. The patient's abdomen is distended and nontender, with large bilateral masses palpated on both abdominal and bimanual pelvic exams. Speculum exam

* Corresponding author. Mount Sinai West Hospital, 410 W 53rd Street, Apt 617, New York, NY, 10019, USA.

E-mail address: jordyn.tumas@mountsinai.org (J.B. Tumas).

† Permanent address: 2 Meadows Lane Wayside NJ 07712, USA.

is unremarkable without any external lesions, bleeding, or discharge, and with a normal-appearing cervix.

Questions/discussion points, Patient 1, Part 1

Given the patient's clinical presentation, what is the differential diagnosis?

A broad differential diagnosis for a woman with abdominal/pelvic masses includes both benign and malignant processes. In this case, the temporality of these masses is uncertain, given the lack of prior imaging for comparison. Therefore, the masses could represent uterine leiomyomas (fibroids), hydro- and hematosalpinx, or benign adnexal masses (e.g., fibromas or mucinous or serous cystadenomas). In the setting of advanced age, bloating, and early satiety, the patient could have ovarian, colon, or peritoneal cancer, leiomyosarcoma, or lymphoma. For a postmenopausal woman with pelvic masses, ovarian or peritoneal cancer should be highly suspected, followed by adnexal masses such as fibromas or cystadenomas.

What initial diagnostic tests should be ordered?

Initial imaging should include a transvaginal ultrasound (TVUS). If masses are identified, a CT scan or MRI of the abdomen and pelvis will likely be recommended next to further establish the qualities of the mass and to plan for surgery, provided the patient is a good surgical candidate. Given the physical exam finding of decreased lung sounds, it would also be appropriate to include chest imaging to evaluate for pleural effusions or distal tumor involvement. Serum tumor markers such as cancer antigen 125 (CA-125) and carcinoembryonic antigen (CEA) and baseline laboratory tests (complete blood count (CBC) and basic metabolic panel (BMP)) should be ordered as well.

For this patient, a TVUS and labwork (CA-125, CEA, CBC, and BMP) are ordered.

Diagnostic findings, Patient 1, Part 2

The TVUS shows bilateral adnexal masses measuring $15 \times 12 \times 13$ cm and $9 \times 8 \times 7$ cm. Both masses have mixed solid and cystic components, thickened walls, and septations. There is ascites present. CEA level is 4.0 ng/mL (normal <2.5 ng/mL), and CA-125 is 4234 U/mL (normal <35 U/mL). Baseline CBC and BMP are normal.

Questions/discussion points, Patient 1, Part 2

How would you interpret the imaging and laboratory findings for this patient?

The ultrasound findings (the size of the masses, presence of thickened walls and septations, and presence of solid components) are all concerning for a possible malignant process. Additionally, the serum CA-125 level is greatly elevated at 4234 U/mL as >35 U/mL is considered abnormal in postmenopausal women. The patient should next undergo a CT scan of the chest, abdomen, and pelvis to better characterize the masses and to look for any other concerning signs of malignancy or metastasis.

The CT scan shows bilateral adnexal masses measuring $16.4 \times 13 \times 13.1$ cm and $9 \times 8 \times 6.5$ cm. Septations in the masses measure 4 mm. Small volume ascites is present in the abdomen, and there is mild basilar atelectasis. There are no enlarged lymph nodes or evidence of carcinomatosis or metastatic implants. The patient is counseled on the high suspicion of malignancy and is scheduled for surgery.

Diagnostic findings, Patient 1, Part 3

The patient undergoes an exploratory laparotomy via midline vertical incision. The gynecologic oncologist first obtains a sample of the ascites

for cytology. The right mass is noted to involve the ovary and fallopian tube, and so a salpingo-oophorectomy (resection of the fallopian tube and ovary, as well as the mass) is performed with the mass intact and sent to the pathology department to be processed as an intraoperative frozen specimen. The pathologist will examine the specimen grossly and then select one or several representative areas of tissue to quickly create slides for evaluation. This process provides a preliminary diagnosis to aid decision-making on the extent of surgery to be performed. While waiting for the frozen sample, the team resects the left adnexa and begins the hysterectomy and omentectomy. The pathologist calls the operating room within twenty minutes to report on the H&E-stained slides (Fig. 1).

Questions/discussion points, Patient 1, Part 3

How would you describe the histology in Fig. 1?

This image contains ovarian tissue with both solid and glandular components. The cells have different sizes and shapes (pleomorphic) and have nuclei that are enlarged and hyperchromatic (representing high mitotic activity). Some of the cells have nucleoli that are particularly stained red.

Based on the clinical picture and pathology, what is the correct diagnosis?

The patient has high grade serous epithelial ovarian carcinoma (HGSC).

How common is ovarian cancer, and what screening modalities exist?

Ovarian cancer is the second most common gynecologic cancer in developed countries, after endometrial cancer, and it is the most common cause of gynecologic cancer death. It is estimated that 1 in 78 women will be diagnosed with ovarian cancer in the United States each year. Ovarian cancer can arise from any cell type in the ovary—epithelial, sex cord-stromal, or germ cells. Epithelial ovarian cancer is the most prevalent of the subtypes although most patients present at advanced stages (Stage III or IV) with only minimal or vague symptoms such as abdominal bloating, early satiety, or weight loss.²

There are currently no effective screening tools for ovarian cancer in the general population, which also limits early diagnosis. Among women with epithelial ovarian cancer, the serum biomarker CA-125 is elevated

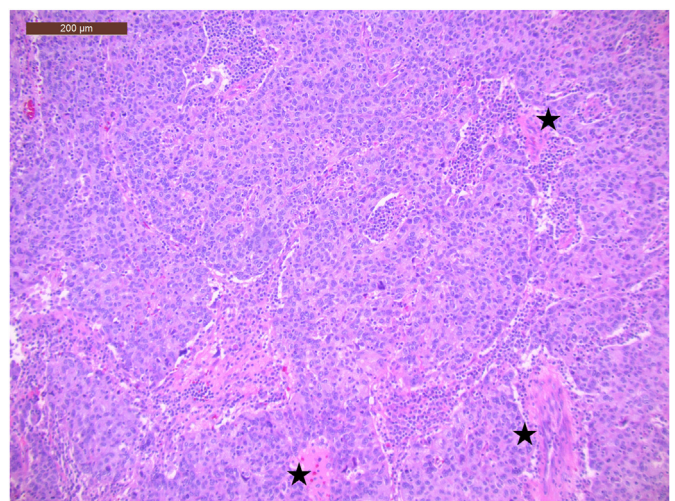


Fig. 1. Low power view of the tumor's solid and glandular architecture with atypical and pleomorphic cells as well as associated necrosis (black stars) (H&E 10 \times).

in about 50% of early stage disease and 80% of advanced stage disease. However, CA-125 is also commonly elevated in the setting of endometriosis, leiomyomas, and pelvic inflammatory disease. These noncancerous conditions are common in premenopausal women, effectively making CA-125 nonspecific in this population. Routinely obtaining a CA-125 level can lead to unnecessary imaging and workup in otherwise healthy women. Instead, CA-125 may be a more reliable tumor marker in postmenopausal women. Several studies have looked into using a combination of CA-125 and TVUS to screen for ovarian cancer, but even when combined, they are not sensitive and specific enough to reliably detect early disease. Instead of acting as a screening tool, a baseline CA-125 and TVUS can be helpful in established ovarian cancer for comparison after surgery and/or adjuvant treatment to monitor for disease progression or recurrence.²

Describe the pathological features of HGSC

These tumors are often large, up to 20 cm in diameter, and frequently have areas of hemorrhage and necrosis. They range from being smooth to having friable surface papillae, from cystic to multilocular, and can contain both soft and firm solid components. Histologic architectural patterns include complex papillary, glandular, microcystic, and solid. Psammoma bodies may be seen, but these are more common in low-grade carcinomas. The main histological features of HGSC are cellular atypia and high mitotic activity. Nuclei will be hyperchromatic and enlarged up to three times the normal size with nucleoli that are large and densely eosinophilic. “Cherry Red” nucleoli are a common and specific finding. Numerous mitotic figures are seen throughout these tumors³ (Figs. 2 and 3).

What special studies would help support the diagnosis?

Immunohistochemistry (IHC) is a technique that highlights specific proteins in tissue samples that can complement the information gained from the standard H&E stain. Performing these additional stains takes time, usually 1–2 days. IHC can be done to confirm histologic diagnosis (including identifying the primary origin of a malignancy), narrow the differential diagnosis, or estimate prognosis. For example, if the index of suspicion for HGSC is high, a P53 stain can be done to confirm the diagnosis. P53 is a tumor suppressor gene commonly implicated in different cancers, including HGSC, and encodes proteins that have a role in inhibiting cell proliferation and inciting apoptosis of genetically damaged cells. In cancers with P53 mutations, abnormal P53 proteins accumulate in cell nuclei⁴ (Fig. 4). In other cases, the suspected diagnosis

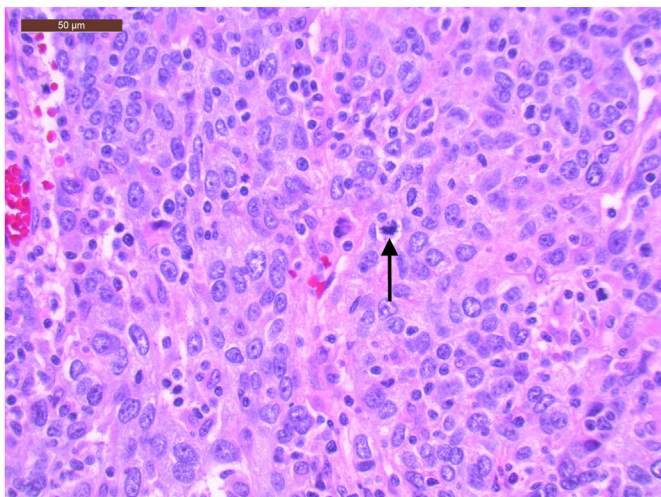


Fig. 2. High power view of atypia with large hyperchromatic nuclei and mitotic figure (black arrow) (H&E 40 \times).

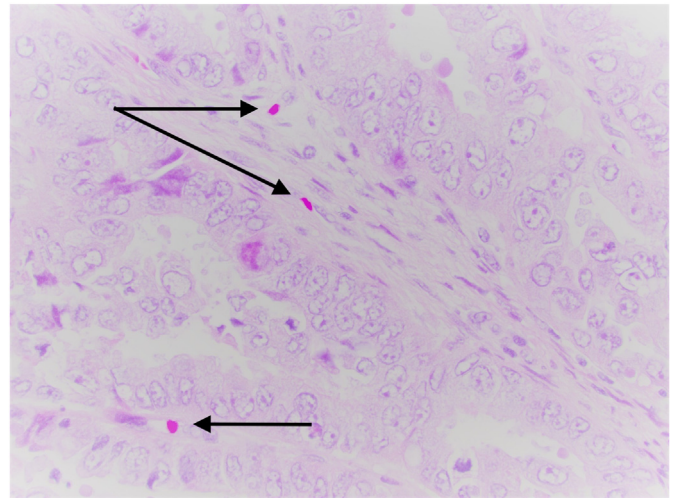


Fig. 3. Example of high power view of “cherry red” nucleoli (black arrows) (H&E 40 \times).

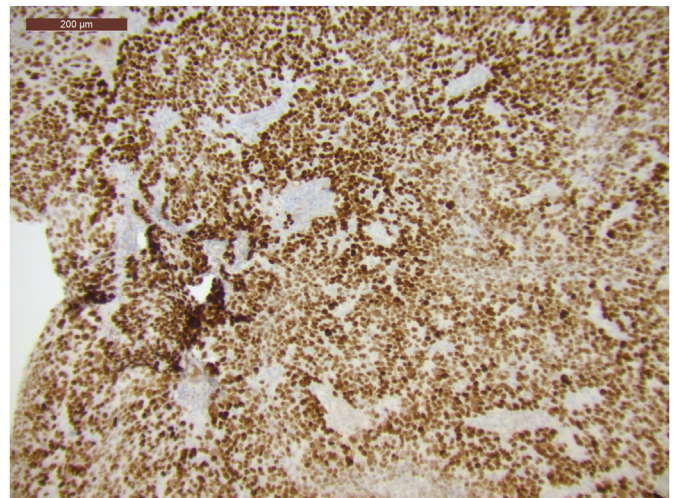


Fig. 4. Diffuse nuclear staining for p53 suggestive of a p53 mutation; greater than ninety percent nuclear staining (p53 10 \times).

may not be as clear; for example, gastrointestinal and gynecological cancers can present in a similar fashion. In these cases, IHC for cytokeratins CK7 and CK20 can be illustrative. Cytokeratins are intermediate filament proteins found in different tissues throughout the body. CK7 can be found in normal tissue of the ovary, endometrium, lung, breast, and biliary tract whereas CK20 is found in gastrointestinal epithelium, urothelium, and Merkel cells of the skin.⁵ Subsequently, IHC of gynecologic cancers are CK7 positive and CK20 negative, while gastrointestinal cancers are CK20 positive and CK7 negative.⁶

Describe the grading and staging of HGSC

Grading refers to the amount of cellular differentiation in a tissue containing cancer. The more similar to the native tissue the cancer cells appear, the more “well differentiated” they are, indicating a lower grade of disease. When cancer cells become more atypical in size, color, and shape, they are more “poorly differentiated,” which is often associated with a higher stage of disease. Staging, on the other hand, provides an assessment of disease extent based on the location of the tumor in the body. Lower stage tumors are usually confined to the original organ, whereas higher stage tumors have spread to lymph nodes and distant organs. The International Federation of Gynecology and Obstetrics

(FIGO) is the gold standard classification system for staging gynecologic cancers. For epithelial ovarian cancers, a summary of the FIGO staging is as follows: Stage I ovarian cancer is confined to adnexal structures (ovaries and fallopian tubes), Stage II includes other gynecologic structures in the pelvis, Stage III has spread to nearby lymph nodes and other peritoneal structures, and Stage IV has spread outside the abdominal cavity or to distant lymph nodes.⁷

What are the risk factors and protective factors for epithelial ovarian cancer?

Risk factors for epithelial ovarian cancer include increasing age (most common ages 55–65), history of infertility or no prior pregnancies, delayed menopause, and increased body mass index (BMI). Known protective factors include oral contraceptive use (35% risk reduction for 5–9 years of use and lasts up to 30 years after discontinuation), previous full-term pregnancy (20% risk reduction with first childbirth and 10% for each subsequent birth), history of breastfeeding, and prior tubal ligation or salpingo-oophorectomy. The roles of postmenopausal hormone therapy, early menarche, and talc exposure are still unclear in the development of epithelial ovarian cancer.⁸

Is epithelial ovarian cancer genetic?

HGSC often has an underlying P53 mutation, which is usually sporadic. However, at least 10–14% of HGSC cases can be a part of Hereditary Breast and Ovarian Syndrome and contain either somatic or germline mutations in the *BRCA1* or *BRCA2* genes. *BRCA1* and *BRCA2* are tumor suppressor genes that mainly encode homologous DNA repair mechanisms. While the lifetime risk of ovarian cancer in the general population is 1.4%, *BRCA*-heritable mutations increase the lifetime risk substantially to 25–65% for *BRCA1* mutations and 11–37% for *BRCA2* mutations. Several other genetic mutations have also been identified including *BRIP1*, *RAD51C*, *RAD51D*, and DNA mismatch repair genes *MLH1*, *MSH2*, *MSH6*, and *PMS2* (which are implicated in Lynch syndrome).^{3,4,9}

A thorough family history is important for determining genetic risk. Ovarian cancer associated with *BRCA* mutations in Hereditary Breast and Ovarian Syndrome tends to occur at earlier ages and stages than in the general population and have higher incidence in certain populations, including those of Ashkenazi Jewish heritage (in whom the risk can be as high as 1/40). There are several notable characteristics in a family history that would warrant genetic testing. Some of these include two first-degree relatives with breast cancer (one of whom diagnosed at age 50 or younger), three or more first- or second-degree relatives with breast cancer regardless of age at diagnosis, first- and second-degree relatives with both breast and ovarian cancer, or a history of breast cancer in a male relative. On the other hand, it is not recommended to routinely test for *BRCA* mutations in the general population.¹⁰ Additionally, every patient with ovarian cancer herself should undergo genetic testing. If a patient without personal history of ovarian cancer tests positive for a *BRCA1* or 2 mutation, it may be recommended to her to start combined oral contraceptives, which can reduce the risk of ovarian cancer by 50% in high-risk patients, and/or undergo risk-reducing surgery in the form of a bilateral salpingo-oophorectomy (BSO).⁴

Are there any other hereditary syndromes associated with ovarian cancer?

Lynch syndrome (formerly hereditary nonpolyposis colorectal cancer (HNPCC)) is a hereditary syndrome that confers an increased risk of several cancers including colon, endometrial, and ovarian cancers, through mutations in DNA mismatch repair genes, especially *MSH2* and *MLH1*. While colorectal and endometrial cancers are the main cancers seen with the syndrome, there is a 6–12% risk of ovarian cancer.^{11,12} Similar to *BRCA*-related cancers, patients with Lynch syndrome typically

present 10–20 years earlier than the general population and with earlier-staged disease, though this may be due to increased surveillance when physicians are alerted to their family histories. All society guidelines recommend that women with Lynch syndrome undergo a risk-reducing total hysterectomy with BSO.⁴

What is the pathogenesis of HGSC?

There are currently several theories as to the pathogenesis of HGSC, the most widely accepted being that it originates from the fallopian tubes rather than the ovary itself. Specifically, it arises from serous tubal intraepithelial carcinoma (STIC) lesions that migrate to the ovarian surface. This theory is supported by data based on women with *BRCA* mutations who underwent risk-reducing BSO surgery in whom about 5% had early cancers incidentally found in the fallopian tubes. There is ongoing research into explaining possible mechanisms of tumor spread for HGSC¹³ (Figs. 5 and 6).

What are the treatment options for high-grade serous epithelial ovarian carcinoma?

For patients with resectable disease burden, surgery is indicated and should include pelvic washings for cytologic evaluation, a total

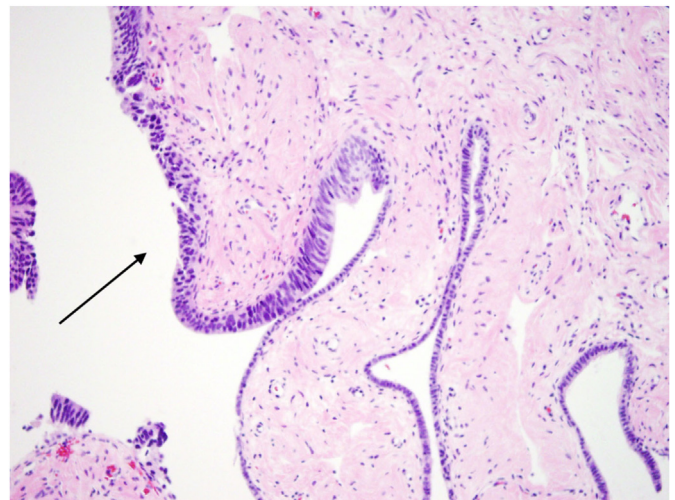


Fig. 5. Fallopian tube with a serous tubal intraepithelial carcinoma (STIC) lesion (black arrow) (H&E 20×).

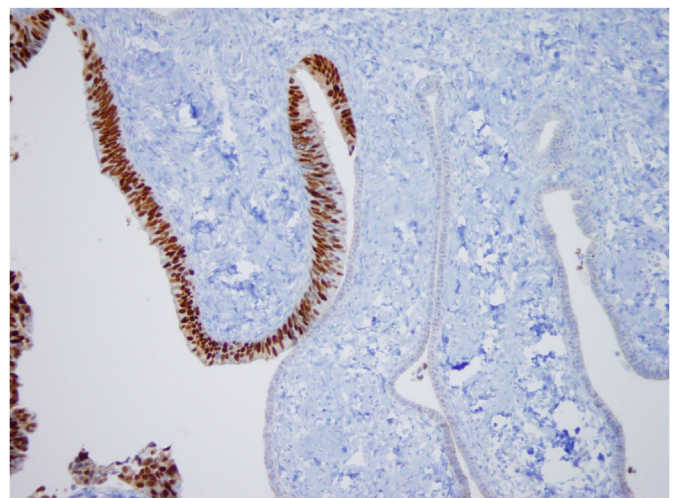


Fig. 6. Fallopian tube with a STIC lesion highlighted by p53 stain (p53 20×).

hysterectomy with BSO, and biopsies of the peritoneum, omentum, and lymph nodes. In almost all cases, adjuvant chemotherapy is also indicated. The standard choice for chemotherapy in ovarian carcinoma is platinum-based agents, such as cisplatin or carboplatin, and carboplatin.²

For patients with *BRCA* mutations, significantly improved disease-free progression rates have been seen with the addition of poly ADP-ribose polymerase (PARP) inhibitors (e.g., Olaparib), for maintenance therapy after initial chemotherapy. PARP is an enzyme normally involved in repairing single-strand DNA breaks. If unrepaired, single-strand breaks can become double-strand breaks during DNA replication. Patients with *BRCA* mutations have impaired ability to repair these double-strand DNA breaks. PARP inhibitors cleverly use the *BRCA* mutations against the cancers in which they exist; by preventing the repair of single-strand breaks, PARP inhibitors allow for double-strand DNA breaks to become more prevalent, which are then defenseless in *BRCA*-mutated cells. The ultimate result is apoptosis of cancer cells.¹⁴

What is the prognosis for patients with HGSC?

For patients with earlier stage tumors (Stage IA and IB), the 5-year survival rate is greater than 90% after surgery. Survival decreases as stage increases, reaching a 5-year survival of less than 20% for Stage IV disease. Poor prognostic factors include the increasing histologic grade, ovarian capsule rupture, adherence to adjacent structures, positive pelvic washings, and ascites.²

Patient presentation #2

A 32-year-old woman presents to the emergency department with two days of acute-onset left lower quadrant pelvic pain. She mentions that she has also noted several months of irregular and heavier periods, soaking eight pads per day for 6 days with light bleeding between periods. Otherwise, she has been in her usual state of health. She is sexually active, does not use anything for birth control. Her body mass index (BMI) is 37. Otherwise, she has no past medical or surgical history and has no family history of any malignancies.

Diagnostic findings, Patient 2, Part 1

On physical examination, the patient appears uncomfortable and has focal tenderness in the left lower quadrant of the abdomen with some fullness appreciated in the left adnexa. There is minimal blood in the vagina and no active bleeding. There is no abnormal vaginal discharge or nodularity and no vulvar lesions. The cervix appears normal, and there is no cervical motion tenderness.

Questions/discussion points, Patient 2, Part 1

Given the patient's clinical presentation, what is the differential diagnosis?

An initial differential diagnosis for this patient should include: ovarian torsion, ruptured ectopic pregnancy, ruptured tubo-ovarian abscess or ovarian cyst, and acute pelvic inflammatory disease.

What initial diagnostic tests should be ordered?

Initial testing for this patient should include a TVUS with Doppler studies, urine pregnancy test (and if positive, a quantitative beta-HCG level), CBC, and type and screen.

Diagnostic findings, Patient 2, Part 2

TVUS reveals a left adnexal mass with both cystic and solid components measuring approximately 11 cm. There is no ascites or free fluid in

the abdomen or pelvis. There is normal doppler flow noted to both ovaries. The urine pregnancy test is negative, CBC within normal limits, and her blood type is AB positive.

Given the abnormal ultrasound findings, a CT scan of the abdomen and pelvis is also performed, which shows a 12.5 cm cystic mass with irregular septations and solid components confined to the left ovary and adnexa. There are no intracystic papillary structures or calcifications seen.

Questions/discussion points, Patient 2, Part 2

How would you interpret the imaging results?

Although the TVUS shows normal doppler flow to both ovaries, the patient has a clinical picture consistent with ovarian torsion. This would require emergent surgical intervention to prevent loss of the ovary; however, the imaging findings also suggest a possible ovarian malignancy, given the large size and abnormal components of solid areas and septations. Therefore, care should be taken to conduct additional workup as the patient is being prepared for the operating room and consider involving the gynecology oncology team.

What additional laboratory tests should be drawn?

For women with solid ovarian masses, serum tumor markers can help to narrow the differential diagnosis. In the workup of ovarian neoplasms, a CA-125 will likely be ordered initially by most providers. A few other serum markers can be useful for identifying hormonally active tumors. For example, testosterone may be elevated in Leydig cell tumors, estradiol in thecomas. Inhibin A, inhibin B, and anti-müllerian hormone (AMH) are elevated in granulosa cell tumors. For these tumors, obtaining both inhibin and AMH has been shown to be more sensitive and specific than either marker on its own. Similarly to CA-125, these hormone levels can aid in diagnosis or can be used to monitor tumor response to treatment.¹⁵

Because the clinical picture is concerning for ovarian torsion, the patient is consented for an urgent diagnostic laparoscopy, possible detorsion, and removal of the adnexal mass. A gynecologist–oncologist is called for intraoperative consult given the abnormal qualities of the mass and suspicion for possible malignancy. Pelvic washings are first obtained, and then the left fallopian tube and ovary with mass are removed. Had the patient had a simple cyst instead, the gynecologic surgeon would have performed a cystectomy and kept the ovary in situ given the patient's young age. However, with concern for malignancy, the ovary and tube are both removed on the affected side. Additionally, at the end of the case, a dilation and curettage (D&C) is performed to sample the endometrial lining given the history of abnormal uterine bleeding. All specimens were sent for final pathologic evaluation. Images of the final pathology slides are shown in Figs. 7 and 8.

How would you describe the histology in Figs. 7 and 8?

These images show sheets of cells with a trabecular and solid growth pattern, with minimal surrounding normal ovarian tissue. Several cells have dark-grooved nuclei that are grouped in rosette-like clusters.

Based on the pathology results, what is the correct diagnosis?

The patient has a granulosa cell tumor, which is the most common sex cord-stromal tumor, classified as a pure sex cord tumor. Ovarian sex cord-stromal tumors are relatively rare, constituting roughly 1% of all primary ovarian cancers. Sex cord-stromal tumors include granulosa cell tumors, fibroma-thecomas, and Sertoli-Leydig cell tumors among many others, and they range from hormonally active to inactive, benign to malignant. The ovarian stroma from which these tumors arise normally supports the

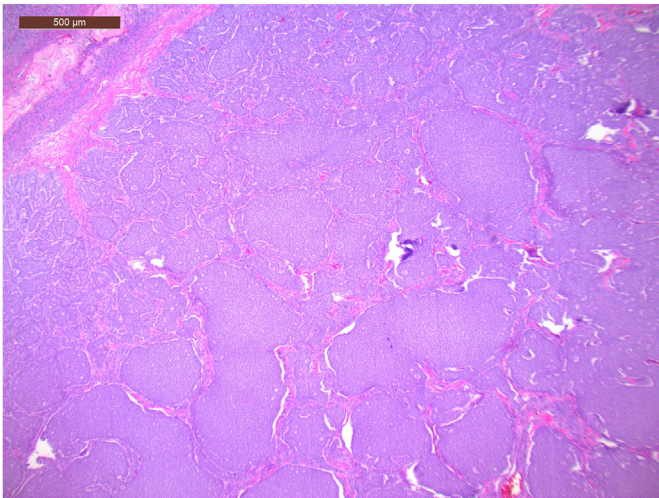


Fig. 7. Trabecular and solid growth pattern with diffuse sheets of cells and minimal normal ovarian tissue (H&E, 4×).

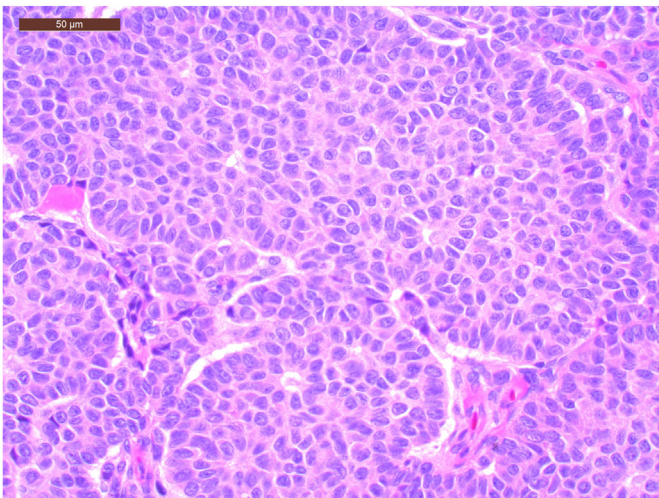


Fig. 8. Tumor cells with dark-grooved nuclei that appear to be grouped in rosette-like clusters with notable lack of cellular pleomorphism or mitoses (H&E, 40×).

ovary and provides important structure, blood supply, and hormonal environment for follicle development. Granulosa cell tumors are considered hormonally active and malignant, and they exist in two main forms: adult and juvenile. The adult subtype accounts for 95% of granulosa cell tumors, develops as a large and asymptomatic mass, and has a median age of diagnosis of 50–54 years, though can occur at any age. The juvenile subtype constitutes the other 5% and more commonly presents prior to puberty, often causing precocious puberty.³

Describe the pathology of granulosa cell tumors

On gross pathology, adult subtype granulosa cell tumors have both solid and cystic components and are on average about 10 cm in diameter. Histologic evaluation can demonstrate several patterns: diffuse pattern with sheets of cells, insular pattern with cords and trabeculae, macrofollicular pattern with large follicles, or microfollicular pattern with classic Call-Exner bodies. Call-Exner bodies are clusters or rosettes of granulosa cells, which tend to be round with scant cytoplasm and “coffee-bean” grooved nuclei. Cellular atypia or increased mitoses are not typical of granulosa cell tumors, as can be seen in other cancers.³

How does immunohistochemistry aid in diagnosis of granulosa cell tumors?

IHC studies that can confirm a granulosa cell tumor include inhibin, calretinin, and FOXL2. Most helpful is staining for inhibin, which is a peptide hormone secreted by the ovarian granulosa cells¹⁵ (Fig. 9). Reticulin is a separate, special stain that can also be useful. Reticulin is present in normal ovarian tissue and can be seen threading in between individual cells; however, in granulosa cell tumors, the reticulin characteristically surrounds groups or islands of tumor cells³ (Fig. 10).

Which patients are at higher risk for granulosa cell tumors?

Granulosa cell tumors more commonly present in women who are nonwhite, have increased BMI >30, and have a family history of ovarian or breast cancer. There is a decreased rate of disease associated with smoking, oral contraceptive pills, and history of pregnancy.¹⁶

Explain why the patient may have presented with irregular periods

Patients with granulosa cell tumors can be expected to present with signs and symptoms of hyperestrogenism, including abnormal uterine

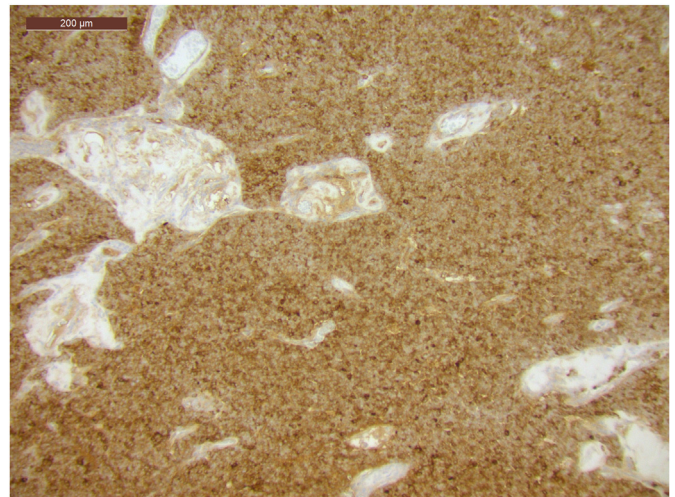


Fig. 9. Inhibin stains diffusely positive in granulosa cell tumors (Inhibin 10×).

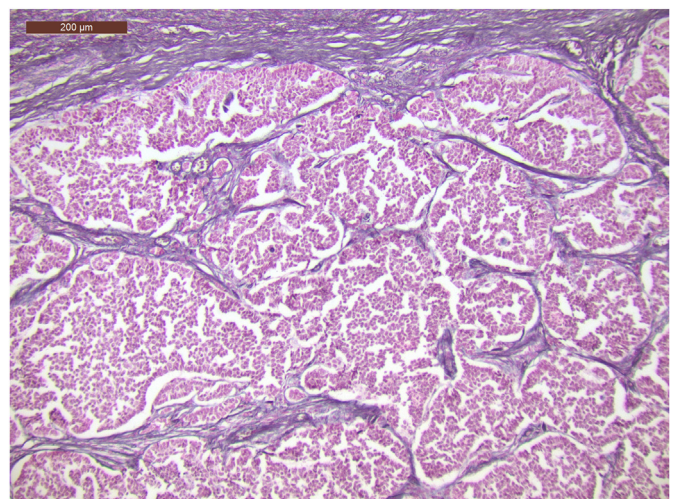


Fig. 10. Reticulin stains black and forms a characteristic pattern of banding around groups of cells in granulosa cell tumors (Reticulin 10×).

bleeding (both pre- and postmenopausal) and breast tenderness. These are the direct result of the hormonally active tumors secreting estradiol. In rare cases, granulosa cell tumors may also secrete androgens such as testosterone and cause hirsutism (e.g., male-patterned hair growth). Patients can also present with ascites, increasing abdominal girth, abdominal pain due to torsion, intraneoplasml hemorrhage, or tumor rupture and hemoperitoneum.¹⁶ Abnormal uterine bleeding in the context of an adnexal mass is important to note, as patients with granulosa cell tumors have an increased risk of developing endometrial neoplasms, that is, complex endometrial hyperplasia, which is shown to co-occur in 32–85% of patients, and endometrioid adenocarcinoma, shown to co-occur in 3–22% of patients. Sampling of the endometrium should be performed for these patients. If the patient has a workup as an outpatient, sampling could be an office endometrial biopsy. If they are taken to the operating room for an urgent surgery, a D&C can be done. Patients with granulosa cell tumors can also be at increased risk of developing infertility related to the unregulated inhibin production and breast cancer from long-term estrogen exposure and so should have appropriate counseling and mammogram surveillance.¹⁷

What role does genetic testing play in granulosa cell tumors?

Several genetic mutations have been implicated in granulosa cell tumor formation; most notably, FOXL2 mutations (seen in more than 90% of adult subtype granulosa cell tumors), which can affect both expression of transforming growth factor beta (TGF- β) and effective apoptotic signaling cascades. FOXL2 has also been shown to play a role in sex differentiation and the formation of follicles in the ovary. In fact, this gene has been linked to several different hereditary conditions of ovarian dysfunction. The benefits of testing for a FOXL2 mutation include differentiating between juvenile and adult granulosa cell tumors and confirming a diagnosis if there is suspicion of another sex cord-stromal tumor. Further, increasing research suggests that metastatic and recurrent granulosa tumors require a more specific treatment, and understanding the role of FOXL2 is essential for this.¹⁸ Juvenile subtype tumors have been associated with a few hereditary conditions as well; namely, Ollier disease and Maffucci syndrome.³

What are the treatment options for granulosa cell tumors?

The majority of patients with granulosa cell tumors are diagnosed at Stage IA, when the tumor is confined to one ovary, and surgical resection is sufficient treatment. For patients who wish to preserve fertility, conservative surgery may be performed, which would consist of a unilateral salpingo-oophorectomy and pelvic washings. For patients with higher stage or poor prognostic factors, full surgical staging is recommended with hysterectomy, bilateral salpingo-oophorectomy, intraperitoneal biopsies, pelvic washings, lymph node dissections of enlarged lymph nodes, and omentectomy. Adjuvant chemotherapy with platinum-based agents is recommended for more advanced disease (Stage IC to IV) due to the increased risk of recurrence. Radiation therapy, on the other hand, has been studied with conflicting results.^{19,20}

What is the prognosis for patients with granulosa cell tumors?

Overall, the prognosis after proper treatment of granulosa cell tumors is favorable, with a 10-year survival rate of 60–90%. However, studies show that 10–30% of patients have a recurrence, usually in the pelvis, and up to 40 years after the initial diagnosis and treatment. Recurrence of disease is an especially poor prognostic indicator, as are advanced stage, tumor size greater than 15 cm, bilaterality, and tumor rupture.^{3,18}

Patient presentation #3

An 18-year-old woman presents to the emergency department with right-sided abdominal pain. The pain started 3 weeks ago and has been

getting progressively worse and more frequent. She has had nausea, vomiting, and some vaginal bleeding. She is otherwise healthy, takes no medications, and has never had surgery. There is no history of any gynecologic or gastrointestinal cancers in her family. She is sexually active with one male partner and cannot remember the date of her last menstrual period. Physical exam findings include abdominal tenderness in the RLQ with voluntary guarding and fullness in the right adnexa on bimanual exam.

Based on the clinical picture alone, what would an initial differential diagnosis include?

An initial differential diagnosis for this patient should include intermittent ovarian torsion, acute appendicitis, ruptured ectopic pregnancy, ruptured tubo-ovarian abscess or ovarian cyst, and acute pelvic inflammatory disease.

What initial laboratory tests and imaging should be ordered?

Initial testing should include a CBC, BMP, lactate, serum quantitative beta-HCG, urinalysis and urine culture, a focused bedside abdominal ultrasound, and TVUS with Doppler studies.

Diagnostic findings, Patient 3, Part 1

CBC shows a mild leukocytosis with WBC 12, otherwise within normal limits. BMP and lactate are also within normal limits. Serum quantitative beta-HCG is 0. Urinalysis is contaminated but has no nitrites or leukocyte esterase. Urine culture is pending.

Bedside ultrasound exam shows no free fluid; the appendix is unable to be visualized. On formal TVUS, a large right-sided pelvic mass with solid and cystic components is seen. The left ovary is of normal size and architecture. There is no free fluid in the pelvis, and Doppler studies show adequate blood flow to both ovaries though with increased flow to the right side. The patient is then sent for a CT scan of the abdomen and pelvis that shows a right-sided solid-cystic mass in the ovary with intratumoral hemorrhage and marked heterogeneous enhancement. The mass measures 12.5 \times 10 \times 10.5 cm, and there are enlarged vessels inside the tumor. The left ovary appears normal and measures 3 \times 2.3 \times 4 cm. There is no ascites present, no enlarged lymph nodes, and the appendix appears normal without any surrounding inflammation or fat stranding.

Questions/discussion points, Patient 3, Part 1

How would you interpret the imaging results?

There is a large ovarian mass with abnormal characteristics seen on imaging. It is reassuring that Doppler studies show flow to both ovaries, and such a large mass makes ovarian torsion less likely, though it is ultimately a clinical diagnosis. This patient may have an intermittent ovarian torsion given the pain has been present for several weeks; however, a large mass without causing torsion can be painful as well. The concerning features of this mass include its size, intralesional vessels, and increased blood flow.

What is the differential diagnosis of the adnexal mass?

The differential diagnosis of the adnexal mass includes a dermoid cyst (mature teratoma), germ cell tumor (dysgerminoma, immature teratoma, or yolk sac tumor), borderline ovarian tumor, and stromal tumor (granulosa cell tumor or Sertoli-Leydig cell tumor).

What serum markers can aid in the diagnosis?

With high suspicion for an ovarian tumor, several serum levels should be checked in addition to the beta-HCG and CA-125 to aid in diagnosis.

While testosterone, inhibin, and AMH help identify sex cord-stromal tumors, lactate dehydrogenase (LDH), placental alkaline phosphatase (PLAP), and alpha-fetoprotein (AFP) help identify malignant germ cell tumors. Dysgerminomas, the most common malignant germ cell tumor (usually seen in children and young women, often bilateral, and with excellent overall prognosis), usually have elevated serum LDH and PLAP with a normal AFP. Beta-HCG may be elevated or normal. Yolk sac tumors have elevated AFP, normal beta-HCG, and either elevated or normal LDH. In immature teratomas, beta-HCG will be normal, and AFP may be elevated.^{4,21}

Diagnostic findings, Patient 3, Part 2

The patient is admitted overnight for pain control and continued monitoring and workup. In the morning, she is taken to the operating room for diagnostic laparoscopy, pelvic washings, and right salpingo-oophorectomy with the gynecology oncology team. The right ovary with mass and right fallopian tube are sent to the pathology department for frozen section. The specimen is evaluated in the lab. Grossly, the mass is 13 cm in diameter and soft with a firm capsule surrounding it. There are several distinct areas of hemorrhage and necrosis. Images of the frozen H&E slides of the tumor tissue are seen in Figs. 11 and 12.

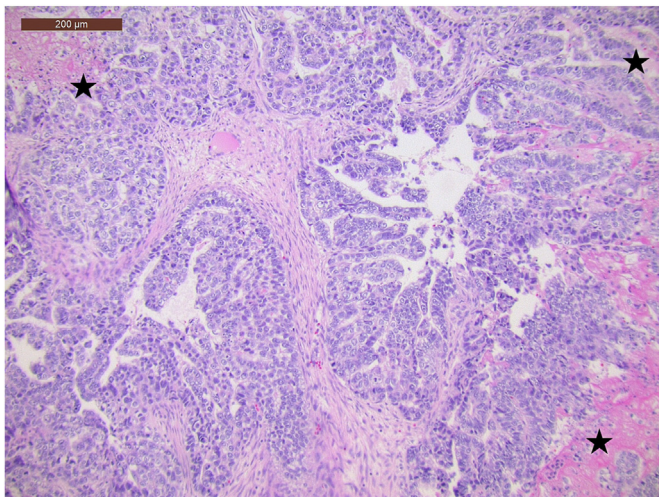


Fig. 11. Low power view of the tumor's glandular proliferation with associated necrosis (black stars) (H&E 10 \times).

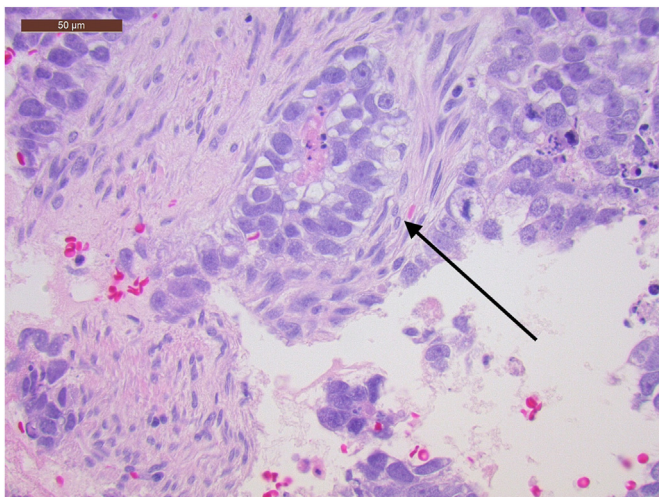


Fig. 12. High power view of tumor cells surrounding a blood vessel defined as a "Schiller-Duval Body" (black arrow) (H&E 40 \times).

How would you describe the histology in Fig. 11?

These images show groups of atypical cells forming glandular and tubular structures adjacent to areas of necrosis (indicated by stars). The figure with the arrow shows those same atypical cells surrounding a small blood vessel.

Based on the pathology results, what is the correct diagnosis?

This patient has a yolk sac tumor. Yolk sac tumors, previously called endodermal sinus tumors, are the third most common malignant ovarian germ cell tumor, after dysgerminomas and immature teratomas, respectively. In general, germ cell tumors account for 20–25% of all ovarian tumors, and about 5% are malignant. Derived from the primitive germ cells of the embryonic gonad, yolk sac tumors tend to be unilateral and occur in young women (median age of 18 years). Classically, they exhibit rapid growth, spreading quickly to intra-abdominal viscera, and produce severe, acute abdominal pain. When they occur in younger patients, they can cause precocious puberty.⁴

Describe the pathologic features of yolk sac tumors

On histology, yolk sac tumors have several architectural patterns including reticular, solid, glandular, and hepatoid. The most common is the reticular pattern, recognizable by scattered tubules lined by single layers of flattened cuboidal cells, loose reticular stroma, and abundant para-aminosalicylic (PAS)-positive globules. Schiller-Duval bodies, which are invaginated papillary structures surrounding a central blood vessel, are pathognomonic for yolk sac tumors^{3,22} (Fig. 12).

What special stains can confirm the diagnosis?

Yolk sac tumors stain positive for proteins secreted by normal yolk sac tissue, which include AFP, glypican-3, cytokeratin AE1/AE3, SALL4, and LIN28.²³ These immunohistochemical stains are helpful as they are specific to tumors that grow from the yolk sac. Of these stains, AFP is the most specific. Occasionally, other rare tumors stain for AFP, such as teratomas with hepatic or enteral tissues, ovarian hepatoid carcinoma, metastatic hepatocellular carcinoma, embryonal carcinoma, and Sertoli-Leydig cell tumors with heterologous hepatocytic differentiation. Yolk sac tumors are also generally patchily positive for P53 (wild type)^{3,24} (Figs. 13–15).

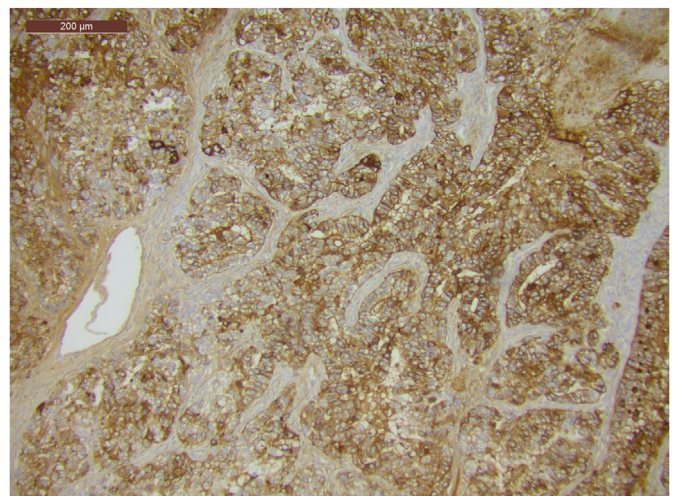


Fig. 13. Diffuse alpha fetoprotein (AFP) staining (AFP 10 \times).

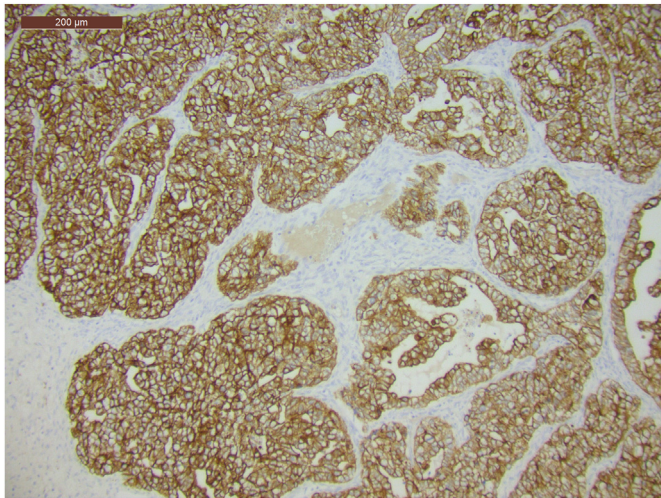


Fig. 14. Diffuse cytokeratin staining (AE1-AE3 10×).

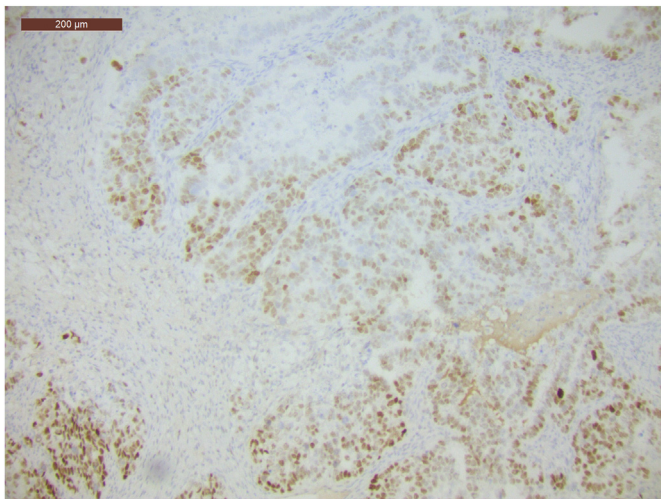


Fig. 15. Wild-type p53 staining pattern (p53 10×).

Questions/discussion points, Patient 3, Part 2

Do germ cell tumors have a genetic component?

There is no known role for genetics in the development or detection of yolk sac tumors or any germ cell tumor.³

What are the treatment options for this patient?

The gold standard of treatment for yolk sac tumors is surgery with adjuvant multi-agent chemotherapy. For surgery, a unilateral salpingo-oophorectomy supplemented by surgical staging is sufficient. Staging is especially important given the age group in which these tumors tend to occur. While these tumors show minimal to no response to radiation therapy, they respond very well to chemotherapy, especially cisplatin-based agents, unless associated with a somatic neoplasm.^{3,21}

What is the prognosis for patients with germ cell tumors and what factors are important?

Diagnosis of germ cell tumors at an earlier stage is associated with better prognosis. Factors associated with a worse prognosis include having higher volumes of ascites and more residual tumor after treatment. With the advances made in multiagent chemotherapy for germ cell tumors, overall prognosis has improved dramatically. Without treatment, these tumors historically had an abysmal 5-year survival rate; retrospective studies have shown that only 25% of patients with Stage I yolk sac tumors survived 2 years after diagnosis. Now, with the recommended treatment, the 5-year survival can be closer to 60–70%.^{4,25}

Teaching points

- Cancer can arise from any cell type in the ovary. The three main categories of primary ovarian cancer are epithelial, sex cord-stromal, and germ cell (Fig. 16).
- In the United States, ovarian cancer is the second most common gynecologic malignancy and the most common cause of gynecologic cancer death. One in 78 women in the United States will have ovarian cancer in her lifetime.
- Currently, no reliable screening tools exist for ovarian cancer, and most women will present with advanced stage disease (Stage III or IV) with no or nonspecific symptoms.

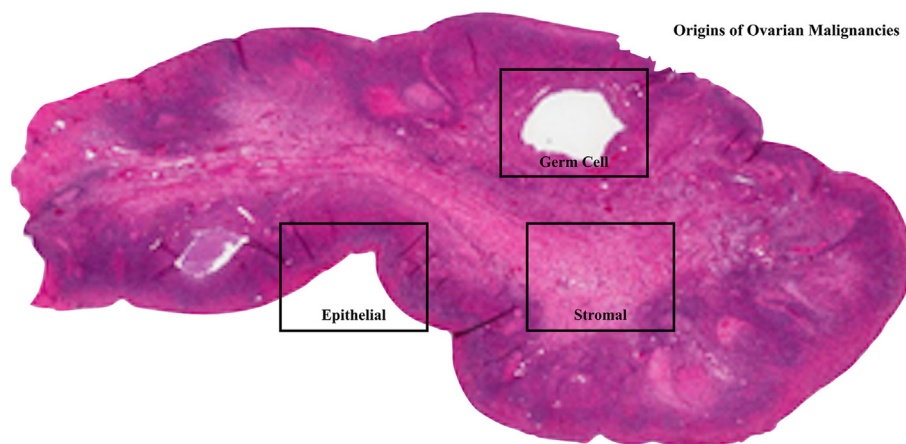


Fig. 16. Depiction of the cell origins of primary ovarian malignancies.

Table 1
Special stains and other testing for ovarian cancers.

	HGSC (epithelial)	Granulosa (stromal)	Yolk sac (germ cell)
Diagnostic IHC stains	CK7: positive CK20: negative	Inhibin or Calretinin: diffusely positive	AFP: diffusely positive Glypican-3: positive Cytokeratin AE1/AE3: diffusely positive
Additional IHC stains	P53: diffusely positive	Reticulin: surrounds islands of cells, rather than around individual cells	P53: patchy (wild type)
Serum markers	CA-125: elevated	Inhibin/AMH: elevated	AFP: elevated
Genetic/molecular testing	BRCA1/2 mutation	FOXL2 mutation	None

IHC: immunohistochemistry; HGSC: high grade serous epithelial ovarian carcinoma; CK: cytokeratin; AFP: alpha fetoprotein; AMH: anti-müllerian hormone; BRCA1/2: breast cancer gene 1 or 2.

- High-grade serous epithelial ovarian carcinoma (HGSC) is the most common epithelial ovarian carcinoma and is most often seen in women in the 4th–6th decades of life. To treat HGSC, surgery and full clinical staging at the minimum is performed, and unless extremely early stage and low-grade tumors, they will also require chemotherapy.
- Granulosa cell tumors are the most common sex cord stromal tumors, though they are still rare. They are more likely to be diagnosed in postmenopausal women who present with signs of hyperestrogenism (abnormal uterine bleeding, breast tenderness) or hyperandrogenism (abnormal hair growth, weight gain). These tumors generally have a favorable prognosis after treatment but frequently recur later in life.
- Adult subtype granulosa cell tumors are associated with FOXL2 mutations.
- Dysgerminomas are the most common malignant germ cell tumor, and mature teratomas are the most common benign germ cell tumor. They are usually diagnosed in children or young women and tend to occur as bilateral ovarian masses. They can be distinguished from other germ cell tumors by levels of serum LDH, PLAP, AFP, and beta-HCG.
- Yolk sac tumors are rare germ cell tumors that can occur in women of any age. Most commonly they present in young women with acute symptoms of abdominal or pelvic pain. They will require chemotherapy in order to have a good survival rate.
- It is important to obtain a thorough family history for every patient and consider genetic testing when appropriate.
- A strong family history of endometrial, colon, and/or ovarian cancer is suggestive of Lynch syndrome, marked by *MSH2*, *MLH1*, *PMS1*, *PMS2*, and *MSH6* mutations.
- A strong family history of breast and ovarian cancer is suggestive of hereditary breast and ovarian cancer syndrome, marked by *BRCA1/2* mutations.
- When constructing a differential diagnosis, it is important to take into account the patient's clinical presentation as well as imaging and laboratory results. One must consider the most acute pathologies, those most likely to result in patient mortality, and those most likely in general given the baseline risk in the population. With each piece of new information, the differential diagnosis should start to narrow.
- Immunohistochemical (IHC) staining can help determine the diagnosis and prognosis of various ovarian malignancies (Table 1).
- For HGSC, look for CK7 positive and CK20 negative staining or diffusely positive P53 staining.
- Granulosa cell tumors stain diffusely positive for inhibin and calretinin.
- Yolk sac tumors stain positive for AFP, Glypican-3, and Cytokeratin AE1/AE3.

Declaration of competing interest

The author(s) declared no potential conflicts of interest with respect to the research, authorship, and/or publication of this article.

Funding

The article processing fee for this article was funded by an Open Access Award given by the Society of '67, which supports the mission of the Association of Pathology Chairs to produce the next generation of outstanding investigators and educational scholars in the field of pathology. This award helps to promote the publication of high-quality original scholarship in *Academic Pathology* by authors at an early stage of academic development.

References

1. Knollmann-Ritschel BEC, Regula DP, Borowitz MJ, Conran R, Prystowsky MB. Pathology competencies for medical education and educational cases. *Acad Pathol*. 2017;4. doi:10.1177/2374289517715040
2. Bhoola S, Hoskins WJ. Diagnosis and management of epithelial ovarian cancer. *Obstet Gynecol*. 2006;107(6):1399–1407.
3. Carcangiu ML, Kurman RJ, Carcangiu ML, Herrington CS. Chapter 1: Tumours of the ovary. In: Kurman RJ, Carcangiu ML, Herrington CS, Young RH, eds. *World Health Organization Classification of Tumours of Female Reproductive Organs*. 4th ed. The International Agency for Research on Cancer; 2014:11–86.
4. Berek JS, Hacker NF. Chapter 12: Germ cell and nonepithelial ovarian cancer. In: *Berek and Hacker's Gynecologic Oncology*. 6th ed. Wolters Kluwer; 2015: 530–554.
5. Lugli A, Tzankov A, Zlobec I, Terracciano LM. Differential diagnostic and functional role of the multi-marker phenotype CDX2/CK20/CK7 in colorectal cancer stratified by mismatch repair status. *Mod Pathol*. 2008;21:1403–1412.
6. Kriplani D, Patel MM. Immunohistochemistry: a diagnostic aid in differentiating primary epithelial ovarian tumors and tumors metastatic to the ovary. *South Asian J Cancer*. 2013;2(4):254–258.
7. Forstner R, Meissnitzer M, Cunha TM. Update on imaging of ovarian cancer. *Curr Radiol Rep*. 2016;4(31).
8. Torre LA, Trabert B, DeSantis CE, et al. Ovarian cancer statistics, 2018. *CA Cancer J Clin*. 2018;68(4):284–296.
9. Moschetta M, George A, Kaye SB, Banerjee S. BRCA somatic mutations and epigenetic BRCA modifications in serous ovarian cancer. *Ann Oncol*. 2016;27(8): 1449–1455.
10. U.S. Preventive Services Task Force. Genetic risk assessment and BRCA mutation testing for breast and ovarian cancer susceptibility: recommendation statement. *Ann Intern Med*. 2005;143(5):355–361.
11. Barrow E, Robinson L, Alduajj W, et al. Cumulative lifetime incidence of extracolonic cancers in Lynch syndrome: a report of 121 families with proven mutations. *Clin Genet*. 2009;75(2):141–149.
12. Umar A, Boland CR, Terdiman JP, et al. Revised Bethesda guidelines for hereditary nonpolyposis colorectal cancer (Lynch syndrome) and microsatellite instability. *J Natl Cancer Inst*. 2004;96(4):261–268.
13. Soong TR, Howitt BE, Horowitz N, Nucci MR, Crum CP. The fallopian tube, “precursor escape” and narrowing the knowledge gap to the origins of high-grade serous carcinoma. *Gynecol Oncol*. 2019;152(2):426–433.
14. Ledermann J, Harter P, Gourley C, et al. Olaparib maintenance therapy in platinum-sensitive relapsed ovarian cancer. *N Engl J Med*. 2012;366(15): 1382–1392.
15. Geerts I, Vergote I, Neven P, Billen J. The role of inhibins B and antimüllerian hormone for diagnosis and follow-up of granulosa cell tumors. *Int J Gynecol Cancer*. 2009;19(5):847–855.
16. Boyce EA, Costaggini I, Vitonic A, et al. The epidemiology of ovarian granulosa cell tumors: a case-control study. *Gynecol Oncol*. 2009;115(2):221–225.
17. Horta M, Cunha TM. Sex cord-stromal tumors of the ovary: a comprehensive review and update for radiologists. *Diagn Interv Radiol*. 2015;21(4):277–286.
18. Rosario R, Cohen PA, Shelling AN. The role of FOXL2 in the pathogenesis of adult ovarian granulosa cell tumours. *Gynecol Oncol*. 2014;133(2):382–387.

19. Pectasides D, Pectasides E, Psyrris A. Granulosa cell tumor of the ovary. *Cancer Treat Rev*. 2008;34(1):1–12.
20. Meisel JL, Hyman DM, Jotwani A, et al. The role of systemic chemotherapy in the management of granulosa cell tumors. *Gynecol Oncol*. 2015;136(3):505–511.
21. Aggarwal P, Kehoe S. Serum tumour markers in gynaecological cancers. *Maturitas*. 2010;67(1):46–53.
22. Bidus MA, Elkas JC, Rose GS. Chapter 12: Germ cell, stromal, and other ovarian tumors. In: Di Saia PJ, Creasman WT, eds. *Clinical Gynecologic Oncology*. 8th ed. Mosby; 2012:329–340.
23. Nogales FF, Quiñonez E, López-Marín L, Dulcey I, Preda O. A diagnostic immunohistochemical panel for yolk sac (primitive endodermal) tumours based on an immunohistochemical comparison with the human yolk sac. *Histopathology*. 2014; 65(1):51–59.
24. Rabban JT, Soslow RA, Zaloudek CZ. Chapter 18: Immunohistology of the female genital tract. In: Dabbs DJ, ed. *Diagnostic Immunohistochemistry: Theranostic and Genomic Applications*. 3rd ed. Saunders; 2010:721–724.
25. Nawa A, Obata N, Kikkawa F, et al. Prognostic factors of patients with yolk sac tumors of the ovary. *Am J Obstet Gynecol*. 2001;184(6):1182–1188.