

## Male Lower Urinary Tract Symptoms

# Holmium Laser Enucleation of the Prostate With Percutaneous Nephrostomy Into the Transplanted Kidney in Patient With Severe Benign Prostatic Hyperplasia With Vesicoureteral Reflux – A Case Report



Takahiro Nohara\*, Satoko Matsuyama, Takashi Shima, Shohei Kawaguchi, Chikashi Seto

Department of Urology, Toyama Prefectural Central Hospital, 2-2-78 Nishi-nagae, Toyama, Toyama 930-8550, Japan

## ARTICLE INFO

## Article history:

Received 23 October 2015

Accepted 3 November 2015

## Keywords:

HoLEP

Renal transplantation

Nephrostomy

## ABSTRACT

A 66-year-old male, who had received renal transplantation 10 years before, was admitted to our hospital with urinary retention. The prostate volume was 169.2 ml. Furthermore, grade 5 vesicoureteral reflux (VUR) was shown in the cystography. Holmium laser enucleation of prostate (HoLEP) was performed, and percutaneous nephrostomy to the transplanted kidney was performed simultaneously to prevent from severe perioperative infection. After that, renal graft function improved and no urinary retention reoccurred, although surgical repair against VUR was necessary 10 months after HoLEP. We conclude that surgical treatment for BPH after kidney transplantation should be strongly considered with care for infections.

© 2016 The Authors. Published by Elsevier Inc. This is an open access article under the CC BY-NC-ND license (<http://creativecommons.org/licenses/by-nc-nd/4.0/>).

## Introduction

The urinary disorders such as BPH are often paid little or no attention during follow-up. There are few reports discuss BPH after kidney transplantation. We report a case of BPH with VUR in the transplanted kidney, treated with HoLEP and percutaneous nephrostomy.

## Case presentation

A 66 year-old male, who had received kidney transplantation from a deceased donor when he was 56 year old, was hospitalized at our department with urinary retention followed by pyelonephritis of the transplanted kidney. He didn't complain about urinary symptoms during follow up after transplantation. His body temperature was 38.6 °C and sCr was 1.93 mg/dl on admission. SCr decreased to 1.2 mg/dl by urethral

catheterization. Urinalysis revealed bacteriuria and pyuria. His prostate volume estimated by TRUS was as large as 169.2 ml for total and 139.5 ml for adenoma. Voiding cystourethrography showed grade 5 VUR to the transplanted kidney (Fig. 1). Thus, we diagnosed BPH with VUR. We did not expect pharmacological treatment to provide full recovery; therefore, surgical treatment was indicated.

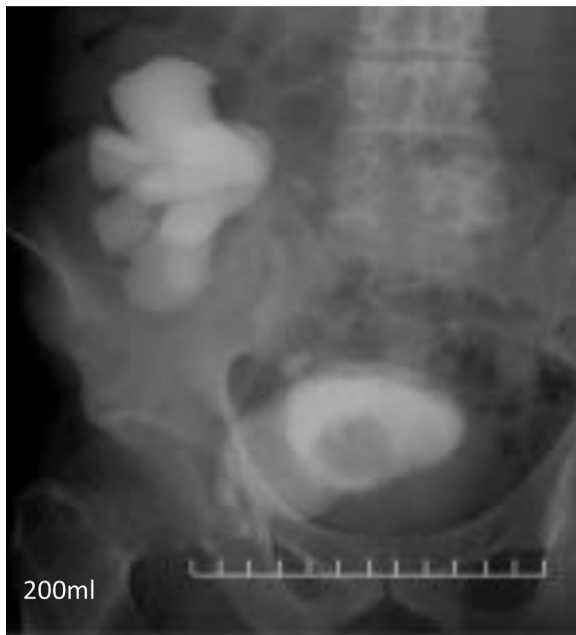After pyelonephritis was resolved, HoLEP and nephrostomy to the transplanted kidney were performed. At lithotomy position, hydronephrosis was induced by saline instillation using transurethral endoscope. Subsequently, to prevent from severe urinary tract infection such as urosepsis, 7 Fr pig-tail catheter was inserted percutaneously into the renal pelvis of the transplanted kidney. HoLEP was performed with the nephrostomy catheter opened (Fig. 2). Because irrigation solution was discharged on nephrostomy, intraoperative ultrasonography revealed no hydronephrosis. The enucleation weight was 133 g and the total operative time was 235 min.

Severe urinary tract infection did not reoccur immediately after surgery. Although the urethral catheter was removed on POD 2, intermittent catheterization was necessary for several days because of residual urine of approximately 100–200 ml. The residual urine of the patient decreased below 50 ml and he left the hospital on POD 21.

**Abbreviations:** BPH, benign prostatic hyperplasia; VUR, vesicoureteral reflux; HoLEP, Holmium laser enucleation of the prostate; sCr, serum creatinine; TRUS, transrectal ultrasonography; POD, post operation day; TURP, transurethral resection of the prostate.

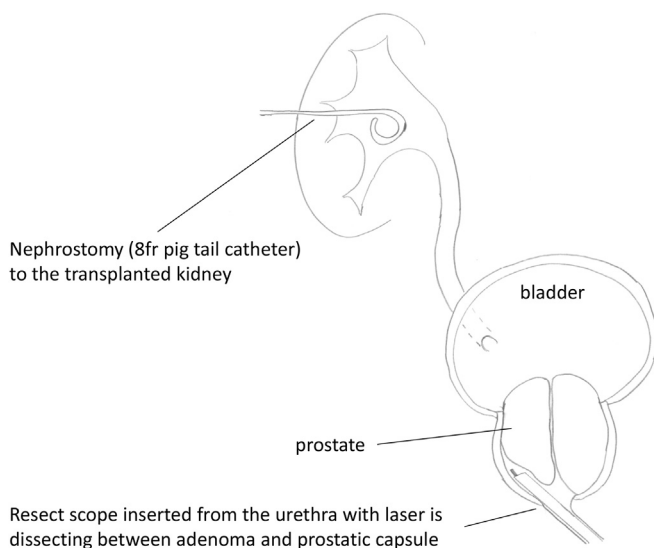
\* Corresponding author.

E-mail address: [t\\_nohara704@yahoo.co.jp](mailto:t_nohara704@yahoo.co.jp) (T. Nohara).



**Figure 1.** Voiding cystourethrography before HoLEP. Contrast medium was injected from the urethral balloon catheter inserted on admission. Grade 5 VUR was shown.

Postoperative sCr was around 1.2 mg/dl and urination was smooth. However, cystography showed grade 4 VUR to the transplanted kidney. Furthermore, hospitalization was necessary at seven and 8 month after HoLEP because of pyelonephritis with VUR. Thus, it was assumed that repair of VUR was necessary. At 10 months after HoLEP, open surgical repair of VUR was performed. A transplanted ureter was connected to the top of the bladder and there was no intramural urinary tract. The ureteral joint with the bladder was cut and re-anastomosed to the other part of the bladder wall by Lich-Gregoir technique. The operative



**Figure 2.** Schema during HoLEP.

time was 145 min, and total intraoperative bleeding was 42 ml. There were no perioperative complications, and he left the hospital on POD 8.

VUR was not recognized on cystography 2 months after the surgical repair of VUR (Fig. 3). The renal graft function has been good (sCr 1.1–1.2 mg/dl) without showing the recurrence of urinary tract infection.

## Discussion

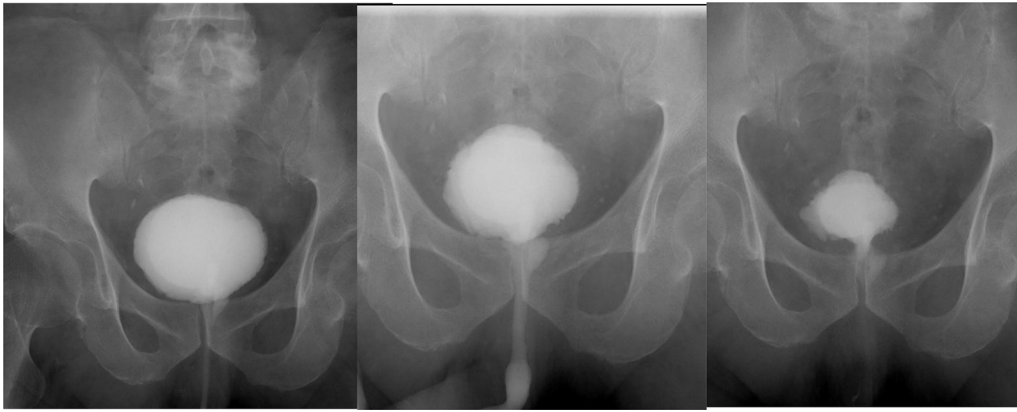
Although there are few reports that discuss prostatic hyperplasia after renal transplant, all of them strongly recommend treatment immediately after renal transplantation.<sup>1–3</sup> Volpe et al reported that 32 patients who underwent TURP with prostatic hyperplasia after transplantation improved not only dysuria but also renal function, which strongly supported surgical treatment.<sup>4</sup> In the present case, it was assumed that surgical treatment should be performed because urinary retention occurred despite the pharmacological treatment provided.

On the other hand, VUR occurs in 20%–40% of kidney transplantation cases. In addition, cases of disuse atrophic bladder due to long term dialysis have the tendency to progress to VUR.<sup>5,6</sup> Most cases of VUR do not require surgical intervention. Surgical treatment is only indicated in patients suffering from recurring urinary tract infection and deterioration of renal function due to VUR.<sup>7</sup> In the present case, we thought that surgery for BPH was only indicated and repair of VUR was not necessary. Because it appeared that VUR was secondary to bladder outlet obstruction and it was spontaneously improved after surgery for BPH.

HoLEP was the superior method because it can be safely performed without depending on the size of the prostate. Furthermore, the risk of severe perioperative infection when performing surgery for BPH under immunosuppression needs to be considered. Patients who receive immunosuppressive therapy are at risk for serious complications such as possible death by urosepsis after TURP, as reported by Reinberg.<sup>1</sup> Thus, performing nephrostomy to the transplanted kidney was superior in the present case because the patient had VUR and urinary tract infection, and high irrigation pressure was necessary during HoLEP. We assumed that pyelectasia during HoLEP was suppressed and severe infection such as sepsis was prevented by the nephrostomy. Though the surgical repair of VUR was necessary, our treatment strategy was reasonable because the operations could be performed safely and postoperative renal graft function improved.

In the present case, other strategies were considered. First, vesicoureteral reflux could be managed endoscopically with bulky agents. HoLEP and endoscopic repair of VUR, without nephrostomy, would be better treatment option. However, the orifice of the transplanted ureter opened widely and it seemed that VUR was not resolved by using bulky agents. Second, transvesical adenomec-tomy and simultaneous ureteral reimplant would be the other option. However, open adenomec-tomy often requires blood transfusion and has high rate of perioperative complication, although this strategy can avoid 2 operations and 2 anesthetics.<sup>8</sup> Furthermore, these two options might undergo simultaneous repair of VUR, which was the unnecessary procedure.

In conclusion, we experienced a case with severe BPH after kidney transplantation in which HoLEP was performed with percutaneous nephrostomy followed by surgical repair of VUR. The procedures were safely performed. We strongly recognized the



**Figure 3.** Voiding cystourethrography after surgical repair of VUR showing no VUR.

need to treat urinary dysfunction after renal transplantation. We recommend that surgical treatment for BPH after renal transplantation should be strongly considered along with careful monitoring for infections.

#### Conflict of interest

The authors declare that there is no conflict of interest regarding the publication of this paper.

#### References

1. Reinberg Y, Manivel JC, Sidi AA, Ercole CJ. Transurethral resection of prostate immediately after renal transplantation. *Urology*. 1992;39(4):319–321.
2. Tsaor I, Jones J, Melamed RJ, et al. Postoperative voiding dysfunction in older male renal transplant recipients. *Transplant Proc*. 2009;41(5):1615–1618.
3. Mokos I, Kastelan Z, Jukic NB, et al. Transurethral incision/resection of the prostate (TUIP/TURP) in operative treatment of repeated bladder outlet obstruction early after kidney transplantation. *Acta Clin Croat*. 2011;50(3):381–384.
4. Volpe A, Billia M, Quaglia M, et al. Transurethral resection of the prostate in kidney transplant recipients: urological and renal functional outcomes at long-term follow-up. *BJU Int*. 2013;112(3):386–393.
5. Inoue T, Satoh S, Saito M, et al. Correlations between pretransplant dialysis duration, bladder capacity, and prevalence of vesicoureteral reflux to the graft. *Transplantation*. 2011;92(3):311–315.
6. Margreiter M, Györi GP, Böhmig GA, et al. Value of routine voiding cystourethrography after renal transplantation. *Am J Transplant*. 2013;13:130–135.
7. Dinçkan A, Aliosmanoglu I, Kocak H, et al. Surgical correction of vesico-ureteric reflux for recurrent febrile urinary tract infections after kidney transplantation. *BJU Int*. 2013;112(4):366–371.
8. Serretta V, Morgia G, Fondacaro L, et al. Open prostatectomy for benign prostatic enlargement in southern Europe in the late 1990s: a contemporary series of 1800 interventions. *Urology*. 2002;60:623–627.