

## ORIGINAL ARTICLE

## Common bile duct dilatation after cholecystectomy: a one-year prospective study

Seon Mee Park, Woo Seok Kim<sup>1</sup>, Il-Hun Bae<sup>2</sup>, Ji Hoon Kim<sup>3</sup>, Dong Hee Ryu<sup>3</sup>, Lee-Chan Jang<sup>3</sup>, Jae-Woon Choi<sup>3</sup>

Department of Internal Medicine, Chungbuk National University College of Medicine, Medical Research Institute, Cheongju, <sup>1</sup>Department of Surgery, Soonchunhyang University Gumi Hospital, Soonchunhyang University College of Medicine, Gumi, Departments of <sup>2</sup>Radiology and <sup>3</sup>Surgery, Chungbuk National University College of Medicine, Medical Research Institute, Cheongju, Korea

**Purpose:** Bile duct dilatation after cholecystectomy continues to be a matter of controversy. We aimed determine the magnitude of common bile duct (CBD) dilatation after cholecystectomy followed up to 1 year. **Methods:** Sixty-four cases (age, 47.3 ± 11.7 years; men, 28; women, 36) enrolled in this study. They received laparoscopic cholecystectomy in Chungbuk National University Hospital for symptomatic cholelithiasis or gallbladder polyps with normal bile duct, less than 7 mm. The CBD diameter was measured by one radiologist using ultrasonography at the maximum point after full length evaluation of extrahepatic bile duct. Forty-five and thirty-one cases were followed at 6 months and 1 year, respectively. **Results:** The CBD was dilated slightly from 4.1 mm at baseline to 5.1 mm at 6 months and 6.1 mm at 12 months after cholecystectomy. The number of cases of CBD dilatation of more than 7 mm at 6 months and at 12 months after cholecystectomy were 11 (24.4%) and 9 (29.0%), respectively. Seven cases at 6 months and 5 cases at 12 months showed bile duct dilation of more than 3 mm compared to baseline. There were no cases having bile duct dilation of more than 10 mm. **Conclusion:** Postcholecystectomy dilatation of the bile duct occurred slightly in most cases. But some cases showed more than 3 mm dilatation over baseline. Asymptomatic bile duct dilatation of up to 10 mm can be considered as normal range in patients after cholecystectomy.

**Key Words:** Cholecystectomy, Common bile duct, Dilatation, Ultrasound

### INTRODUCTION

As abdominal ultrasonographic exams are frequently performed, bile duct dilatations are incidentally found in gallbladder resected patients. When bile duct dilatation is discovered in asymptomatic patients, it is often difficult to differentiate whether it is the physiological change of gallbladder resection or the early findings of bile duct lesions.

In order to differentiate the diagnosis of asymptomatic bile duct dilatation, one needs to perform magnetic resonance cholangiopancreatography or endoscopic retrograde cholangiopancreatography (ERCP), which are both expensive and/or invasive tests. Therefore, it is necessary to understand the physiological change of the bile duct after cholecystectomy to reduce unnecessary testing for the early detection of bile duct lesions.

Received April 9, 2012, Revised May 20, 2012, Accepted May 31, 2012

Correspondence to: Jae-Woon Choi

Department of Surgery, Chungbuk National University College of Medicine, 52 Naesudong-ro, Heungdeok-gu, Cheongju 361-804, Korea  
Tel: +82-43-269-6037, Fax: +82-43-266-6037, E-mail: dhryu@chungbuk.ac.kr

© Journal of the Korean Surgical Society is an Open Access Journal. All articles are distributed under the terms of the Creative Commons Attribution Non-Commercial License (<http://creativecommons.org/licenses/by-nc/3.0/>) which permits unrestricted non-commercial use, distribution, and reproduction in any medium, provided the original work is properly cited.

After a hypothesis suggested by Oddi in 1887, many studies reported that the physiological dilatation of the bile duct after cholecystectomy was due to the disappearance of the gallbladder's reservoir function. However, the frequency and degree of bile duct dilatation after gallbladder resection are reported differently. In addition, since most of the reported studies were based on the western population, it is assumed that these results may be different in the eastern population, who frequently show anomalous union of pancreaticobiliary duct (AUPBD) and a high incidence of bile duct stones. However, there have only been a few studies reported thus far.

The present study aims to determine the physiological change of the bile duct by measuring the diameter of the common bile duct (CBD) in patients who had laparoscopic cholecystectomy for gallbladder stones or gallbladder polyps.

## METHODS

### Patients

The patients who received laparoscopic cholecystectomy from one surgeon at the Chungbuk National University Hospital between January and December in 2007. Patients who previously underwent abdominal surgeries or ERCP, showed abnormal liver function tests (LFTs) or pancreatitis at the time of surgery, or showed a bile duct diameter of more than 7 mm were excluded from this study.

### Methods

The sex, age and diagnosed diseases of the patients were investigated and the CBD diameter was measured, 6 months after and 12 months after surgery. This was done by one specialist of diagnostic radiology using a single type of ultrasonography (Combison 310, KretzTechnik, Zipf, Austria). The CBD diameter was measured in 0.1 mm scale at the widest point of extrahepatic bile ducts. The changes of CBD diameter before and after surgery were measured from the same patient. The normal range of the CBD diameter was defined to be less than 6 mm; and the frequencies of being less than 5.0 mm, 5.1 to 6.9 mm, and more than 7.0 mm were measured. The change of CBD di-

ameter was expressed in percentages (%), based on the measurements before the surgery and during the follow-up periods. In particular, the clinical characteristics of patients who showed bile duct to be over 7 mm and a duct dilatation of more than 3 mm at the follow-up examinations were investigated.

### Statistical analysis

The CBD diameters that were measured at each point were expressed as mean and standard deviation, and the change was investigated by t-test. The changes of a single patient before, 6 months after, and 12 months after the surgery were analyzed using a paired t-test wherein the P-value results of less than 0.05 were interpreted as significant.

## RESULTS

### Patient characteristics

Among the 71 patients receiving cholecystectomy, 64 patients (28 males and 36 females) were included while 7 patients who showed CBD diameter of more than 7 mm were excluded. Of the 64 patients, there were 53 patients with cholelithiasis and 11 patients with gallbladder polyps with a mean age of  $47.3 \pm 11.7$  years (range, 28 to 83 years) old. The abdominal ultrasonographic follow-up exams, 6 months and 12 months after surgery, were performed in 45 patients and 31 patients, respectively.

### The change of CBD diameter (Table 1)

#### Before surgery

Before surgery, 82.8% of patients had a CBD diameter of less than 5 mm while 17.2% of patients were in the 5 to 6.9

**Table 1.** Common bile duct diameter at preoperation and at 6 months and 12 months after cholecystectomy

| Time         | No. of patients | Common bile duct diameter (%) |            |            |
|--------------|-----------------|-------------------------------|------------|------------|
|              |                 | ≤5 mm                         | 5.1-6.9 mm | ≥7.0-10 mm |
| Preoperative | 64              | 82.8                          | 17.2       | 0          |
| Post 6 mo    | 45              | 35.6                          | 40.0       | 24.4       |
| Post 12 mo   | 31              | 29.0                          | 42.0       | 29.0       |

mm range making the mean diameter  $4.1 \pm 1.1$  mm. The CBD diameter was found to increase by age. Eight patients 60 years or older had CBD diameters of  $4.5 \pm 0.8$  mm compared to 56 patients less than 60 years of age with CBD diameters of  $4.1 \pm 1.8$  mm ( $P < 0.05$ ). Other than that, there were no significant differences observed in relation to sex or gallbladder disease type.

#### *Six months after surgery*

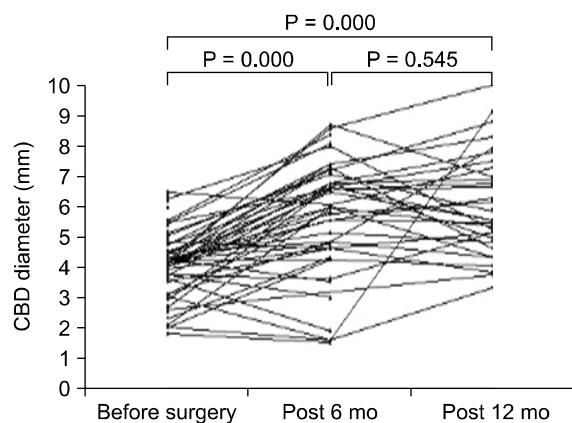
Forty-five patients had follow-up exams 6 months after surgery and out of those 35.6% had CBD diameter measurements of less than 5 mm while 40.0% measured between 5.1 to 6.9 mm with a mean diameter of  $5.7 \pm 1.8$  mm. In 11 patients (24.4%), the CBD diameter was more than 7 mm (range, 7.0 to 9.2 mm), but no patient had a measurement of more than 10 mm.

#### *Twelve months after surgery*

There were 31 patients who had follow-up exams 12 months after surgery and CBD diameter results showed that 29% had less than 5 mm and 42.0% ranged from 5.1 to 6.9 mm, with a mean diameter of  $6.1 \pm 1.7$  mm. In 9 patients (29.0%), the CBD diameter was more than 7 mm (range, 7.1 to 9.3 mm), but no patient had a measurement of more than 10 mm.

### Change of CBD diameter before and after surgery

Before surgery, the CBD diameters of 6 months and 12 months after surgery show an increase of  $45.3 \pm 41.8\%$  and  $52.7 \pm 43.4\%$ , respectively (baseline vs. post 6 months,  $P < 0.0001$ ; baseline vs. post 12 months,  $P < 0.000$ ; by paired



**Fig. 1.** Common bile duct (CBD) diameter increase 12 months after surgery.

t-test). CBD diameter increased more than 3 mm in 7 patients (20%) 6 months after surgery and in 5 patients (20%) 12 months after surgery. Among the 7 patients at 6 months after surgery, 4 patients showed a reduction in diameter at the 12-month examination, and the 3 patients that were normal at the time, showed a CBD diameter increase 12 months after surgery (Fig. 1). At the follow-up examination, any specific clinical characteristics of the patients who showed more than a 3 mm dilatation were not discovered and they remained in an asymptomatic state by showing normal LFTs.

## DISCUSSION

The hypothesis of bile duct dilatation as a physiological change that results from the resection of gallbladder was initiated in the 1880s. Suggesting that CBD dilatation was due to the loss of the storing function of the gallbladder after its resection was confirmed in an animal experiment [1]. Then, dilatation of the bile duct was proved in the case of gallbladder resection compared to normal cases of human autopsy samples [2]. Afterward, studies measuring bile duct diameter were performed using intravenous cholangiography. However, contrary to these findings, the bile duct diameter remained the same or on the contrary decreased, while the increase was observed only in limited patients [3-5]. After introducing the abdominal ultrasonography that enables the direct measurement of bile duct diameter in a normal state, the study mainly used this method. The occurrence of a physiological change of the bile duct after cholecystectomy was confirmed by a cross sectional study.

Although many cross sectional studies revealed CBD diameter increase in gallbladder resected patients compared to normal people, the magnitudes and frequencies of dilatation are different according to each study. One study reported a CBD diameter of 4.5 mm in the gallbladder resected group by showing a slight difference of 0.7 mm dilatation from the normal subjects' 3.7 mm [6]. Another study reported a dramatically increased CBD diameter of 6.2 mm in the gallbladder resected group compared to that of 2.8 mm in normal subjects [7]. In a recent

study, the gallbladder resected group revealed a bile duct dilatation of more than 6 mm, which was observed at 80% of the proximal part and 58% of the distal part of the CBD [8]. Since the cross sectional study presents the possibility that bile duct dilatation is related with bile duct diseases before surgery, there is a limitation that the dilatation was purely caused by physiologic changes from the cholecystectomy.

In prospective studies that can represent the direct change of the bile duct after gallbladder resection, the bile duct dilatation occurred in a limited number of patients, revealed by the different results of the 16-month follow-up study, 7 out of 67 patients revealed a dilatation of up to 6 to 10 mm [9], but there was also a report that showed a dilatation in only a single case out of 40 patients [10]. Similar results were reported in the more long-term observational studies. The result of a 5 year follow-up for 21 patients after surgery revealed that only 2 patients showed a common hepatic duct dilatation of about 4 mm, and 7 patients showed a slight change of CBD diameter from 4.8 to 5.9 mm [11].

In other studies investigating patients showing normal gallbladder function and a CBD diameter up to 5 years after surgery, results showed common hepatic duct dilatation of more than 6.0 mm in only a single case out of 59 patients [12]. The longest follow-up observational study, which investigated bile duct dilatation up to 12 years after the cholecystectomy, reported that patients who were 60 years of age or older revealed a significant increase from 5.0 to 6.7 mm, but there was no difference for those under 60 years old [13]. When integrating the above results, most of the patients showed a bile duct dilatation after gallbladder resection in the normal range and only a limited number of patients showed a dilatation higher than normal range.

In studies involving eastern populations, a cross sectional study investigating the CBD diameter by using abdominal ultrasonography of Korean patients revealed the CBD diameter was 8.1 mm in the gallbladder resected group, which was wider than the 4.5 mm in the normal population [14]. One prospective study performed in Hong-Kong, investigating the CBD diameter before and after cholecystectomy by ERCP, revealed that 88.6% of 35

patients showed a dilatation of about 2.0 mm, and the degree of dilatation increased proportionally to time passed for the period of 4 to 14 months [15]. However, in a Taiwanese study, 197 patients revealed a slight CBD dilatation from 5.9 to 6.1 mm, and the degree of dilatation was not related to time passage [16]. Since the above studies on eastern populations applied different imaging techniques and showed different results, bile duct change after gallbladder resection still remains in dispute.

In the present study, the CBD diameter at 6 months and at 12 months after surgery showed increases of 1.6 mm and 2.0 mm, respectively, and 20% of the patients displayed more than a 3 mm dilatation compared to that before surgery. These results showed more CBD dilatation and frequency than previous studies. Eastern populations showed that the CBD dilatation was frequently accompanied by ampullary diverticulum, biliary sludge, or AUPBD. However, the patients showing a biliary dilatation in the present study were found to be asymptomatic with normal LFTs. Precision was applied to the present study from the perspective in that the tests were performed by a single skilled diagnostic radiologist using abdominal ultrasonography. Moreover, since the present study was performed by contrasting all CBD regions and based on repeated measurement values that measured the widest CBD diameter, it can be judged to be meaningful and accurate.

Next, what clinical characteristics can be observed in the patients of bile duct dilatation after the cholecystectomy? Although the general clinical characteristics of bile duct dilatation have not been well defined, some reports showed that it is commonly observed when the initial diameter of the bile duct is smaller before surgery [17] and when the patient is older [13]. But in the present study, the patients' age, sex, diagnosis and bile duct diameter did not have effect on the bile duct dilatation after surgery.

Although there is no official guideline, a bile duct diameter of less than 6 mm is generally considered to be a normal size in adults younger than 65 years of age, and more than 7 mm is considered abnormal [18]. Bile duct size is not largely affected by sex, body weight and height of the patient, but reported to have a major correlation with age as there was an increase of 0.3 to 0.6 mm for patients of 10

years difference [19,20]. According to a study that investigated the CBD diameter of 230 healthy Koreans, results showed that they had CBD diameters of  $4.5 \pm 1.8$  mm while 95% of the investigated populations had less than 7.3 mm [14].

The present study was performed on patients with CBD diameters of less than 7 mm before surgery in order to investigate the degree of dilatation after surgery of normal people. At 6 months after surgery, a 7 to 10 mm of dilatation was observed in 30% of the total patients. And with the absence of a 10 mm dilatation in the results, it can be assumed that normal bile duct diameter after receiving the cholecystectomy be established within 10 mm.

The present study investigated the CBD diameter of patients having normal bile ducts for up to 1 year after getting a cholecystectomy. A bile duct dilatation of more than 7 mm in 30% of the patients was observed, while no patients had bile duct dilatation of more than 10 mm. All of the bile duct dilatation patients were asymptomatic while clinical characteristics that can be differentiated from the others were not observed.

In conclusion, a CBD dilatation within 10 mm in gallbladder resected patients can be regarded as normal physiological change.

## CONFLICTS OF INTEREST

No potential conflict of interest relevant to this article was reported.

## REFERENCES

- Judd ES, Mann FC. The effect of removal of the gallbladder: an experimental study. *Surg Gynecol Obstet* 1917; 24:437-42.
- Puestow CB, Morrison RB. The relationship of cholecystitis and cholecystectomy to dilatation of the choledochus. *Ann Surg* 1935;101:599-602.
- Sandweiss DJ, Fulton H. Intravenous cholangiography; results in one hundred cholecystomized patients with upper abdominal symptoms. *J Am Med Assoc* 1955;159:998-1001.
- Le Quesne LP, Whiteside CG, Hand BH. The common bile duct after cholecystectomy. *Br Med J* 1959;1:329-32.
- Longo MF, Hodgson JR, Ferris DO. Size of the common bile duct following cholecystectomy. *Ann Surg* 1967;165: 250-3.
- Bruneton JN, Roux P, Fenart D, Caramella E, Occelli JP. Ultrasound evaluation of common bile duct size in normal adult patients and following cholecystectomy: a report of 750 cases. *Eur J Radiol* 1981;1:171-2.
- Niederer C, Muller J, Sonnenberg A, Scholten T, Erckenbrecht J, Fritsch WP, et al. Extrahepatic bile ducts in healthy subjects, in patients with cholelithiasis, and in postcholecystectomy patients: a prospective ultrasonic study. *J Clin Ultrasound* 1983;11:23-7.
- Chawla S, Trick WE, Gilkey S, Attar BM. Does cholecystectomy status influence the common bile duct diameter? A matched-pair analysis. *Dig Dis Sci* 2010;55:1155-60.
- Graham MF, Cooperberg PL, Cohen MM, Burhenne HJ. The size of the normal common hepatic duct following cholecystectomy: an ultrasonographic study. *Radiology* 1980;135:137-9.
- Mueller PR, Ferrucci JT Jr, Simeone JF, Wittenberg J, vanSonnenberg E, Polansky A, et al. Postcholecystectomy bile duct dilatation: myth or reality? *AJR Am J Roentgenol* 1981;136:355-8.
- Hunt DR, Scott AJ. Changes in bile duct diameter after cholecystectomy: a 5-year prospective study. *Gastroenterology* 1989;97:1485-8.
- Majeed AW, Ross B, Johnson AG. The preoperatively normal bile duct does not dilate after cholecystectomy: results of a five year study. *Gut* 1999;45:741-3.
- Csendes GP, Csendes JA, Burgos LA, Burdiles PP. Bile duct diameter before and 12 years after cholecystectomy. *Rev Med Chil* 2007;135:735-42.
- Cho SW, Shim CS, Park NC, Lee JS. The measurement of size of extrahepatic bile ducts in normal control, patients with cholelithiasis, and postcholecystectomy patients. *Korean J Gastroenterol* 1987;19:178-82.
- Chung SC, Leung JW, Li AK. Bile duct size after cholecystectomy: an endoscopic retrograde cholangiopancreatographic study. *Br J Surg* 1990;77:534-5.
- Feng B, Song Q. Does the common bile duct dilate after cholecystectomy? Sonographic evaluation in 234 patients. *AJR Am J Roentgenol* 1995;165:859-61.
- Pilleul F. Asymptomatic or paucisymptomatic CBD dilatation on US after cholecystectomy: management. *J Radiol* 2006;87(4 Pt 2):494-9.
- Parulekar SG. Ultrasound evaluation of common bile duct size. *Radiology* 1979;133(3 Pt 1):703-7.
- Wu CC, Ho YH, Chen CY. Effect of aging on common bile duct diameter: a real-time ultrasonographic study. *J Clin Ultrasound* 1984;12:473-8.
- Bachar GN, Cohen M, Belenky A, Atar E, Gideon S. Effect of aging on the adult extrahepatic bile duct: a sonographic study. *J Ultrasound Med* 2003;22:879-82.