

This article is licensed under the Creative Commons Attribution-NonCommercial 4.0 International License (CC BY-NC) (<http://www.karger.com/Services/OpenAccessLicense>). Usage and distribution for commercial purposes requires written permission.

## Single Case

# Hemobilia Derived from Cystic Artery Pseudoaneurysm

Takayuki Tanaka Kazuki Takakura Yuki Maruyama Akihisa Hidaka  
Masanori Nakano Yuichi Torisu Masayuki Saruta

Division of Gastroenterology and Hepatology, Department of Internal Medicine, The Jikei University School of Medicine, Tokyo, Japan

## Keywords

Cystic artery pseudoaneurysm · Hemobilia · Rupture · Embolization · Cholecystitis

## Abstract

Cystic artery pseudoaneurysm (CAP) is a rare disease, with small number of previous reports related to CAP. Besides, it is frequently prone to critical condition due to arterial bleeding. Here, we presented a case of ruptured CAP with acute calculus cholecystitis and its subsequent successful management with temporary endoscopic biliary drainage for obstructive jaundice and embolization for the culprit artery without cholecystectomy. Since CAP is at high risk of bleeding, intravascular treatment, which is only one currently available therapeutic option, is urgently required in the clinical sites.

© 2019 The Author(s)  
Published by S. Karger AG, Basel

## Introduction

Cystic artery pseudoaneurysm (CAP) is a rare disease, with a small number of previous reports related to CAP. Besides, it is frequently prone to critical condition due to arterial bleeding. At this time, CAP is defined as a hematoma aggregator in perivascular connective tissue due to rupture of the vascular wall. After excluding the most common pathogenesis, cholecystectomy-related iatrogenic injury, it is likely that the erosion of inflammation to the vessel wall inside the gallbladder could occur in cases of cholecystitis and could lead to the development of CAP [1–3]. As CAP is exceedingly uncommon, there has been no established epidemiological

evidence, with only a few case reports. Therefore, analysis of the efficacy of therapeutic options to CAP, including catheterization and endoscopic or surgical procedures, has not been done yet. Here, we presented a case of ruptured CAP with acute calculus cholecystitis and the subsequent successful management.

## Case Report

A 80-year-old woman presented to the emergency department with tarry stool, abdominal pain, and vomiting. Her past medical history included type 2 diabetes mellitus on dialysis for end-stage renal disease, hypertension, gallstone, prior myocardial infarction, and postoperative gastric cancer. She was prescribed antithrombotic drug (aspirin 100 mg/day) as a prophylactic agent for the recurrence of cardiovascular event. Physical examination revealed a soft abdomen with right upper quadrant tenderness. Laboratory investigations showed increased hepato-pancreatobiliary enzymes as follows: aspartate aminotransferase 851 IU/L, alanine aminotransferase 606 IU/L, lactate dehydrogenase 609 IU/L, total bilirubin 2.0 mg/dL, direct bilirubin 1.6 mg/dL, alkaline phosphatase 1,001 IU/L,  $\gamma$ -glutamyltransferase 177 IU/L, and amylase 938 IU/L. In addition, C-reactive protein was slightly elevated (1.31 mg/dL), whereas hemoglobin (9.4 g/dL) and platelet count ( $141 \times 10^3$  cells/mL) were decreased, with a normal leukocyte count ( $7.9 \times 10^3$  cells/mL). The arterial phase of dynamic CT imaging revealed not only acute suppurative cholecystitis with thickening of the gallbladder wall and inflammation of the fat surrounding the gallbladder, but also gallstone and an area of high density within the gallbladder and common bile duct, suggesting recent intraluminal bleeding; this was diagnosed as a ruptured CAP (Fig. 1).

Based on the stable observations of the patient, emergent endoscopic biliary drainage was performed for her obstructive jaundice (Fig. 2). In the procedure, multiple blood clots were seen inside her stomach and duodenum. Besides, hemorrhage from the papilla of Vater was clearly visualized, suggesting active hemobilia (Fig. 3). For her hemostasis, embolization by using HydroCoil for the culprit cystic artery was successfully performed, resulting in the absence of aneurysm (Fig. 4). The patient had no serious posttreatment complications, with normalization of laboratory tests. Therefore, her biliary stent could be removed and she was subsequently discharged after 16 days. Fortunately the clinical course has been uneventful without cholecystectomy so far.

## Discussion

As the incidence of hemobilia is around 2–5% in upper gastrointestinal hemorrhage [4] and only 25% of cases occurred from the gallbladder [5], CAP is undoubtedly rare. After excluding the most common pathogenesis, cholecystectomy-related iatrogenic injury, it was presumed that the erosion of inflammation derived from cholecystitis to the wall of the cystic artery had damaged several layers and resulted in CAP formation in the process [1–3]. In addition, we hypothesized the involvement of underlying diseases, and antithrombotic drugs can also lead to arteriosclerotic changes and be thought of as triggers. In this case, the basal administration of aspirin might be supposed to have been involved in the rupture of the CAP. Besides, a previous study reported that the mechanical stimulation of gallstone was also a risk factor of CAP and hemobilia [2, 6, 7]. Furthermore, a clot can be the origin of biliary obstruction as an acute complications, leading to the formation of gallstone as a late complication of

hemobilia [8, 9]. Considering the risk of recurrence of biliary obstruction, continuous observation is needed after the endoscopic drainage.

The recommended managements of CAP are still controversial. A previous report showed the necessity of hemostasis by emergent surgical intervention or embolization with subsequent cholecystectomy, because the recurrence of cholecystitis or necrosis of the gallbladder can possibly be generated after the embolization [10], whereas patients treated with embolization alone having no troubles within 12 months were also reported, suggesting that the requirement of cholecystectomy cannot be applied to all CAP cases [11, 12]. In addition, a report demonstrated that embolization had a high success rate of hemostasis in 75–100% of patients with hemobilia [13]. Taken together, temporary endoscopic biliary drainage for obstructive jaundice and embolization for the culprit artery were conducted without cholecystectomy in this case.

In conclusion, a rare case of ruptured CAP successfully treated with arterial embolization and biliary drainage is reported. Since CAP is at high risk of bleeding, intravascular treatment, which is only one currently available therapeutic option, is urgently required in the clinical sites.

### Statement of Ethics

All procedures were performed in accordance with the ethical standards laid down in the 1964 Declaration of Helsinki and its later amendments. The patient provided consent for the publication of her images.

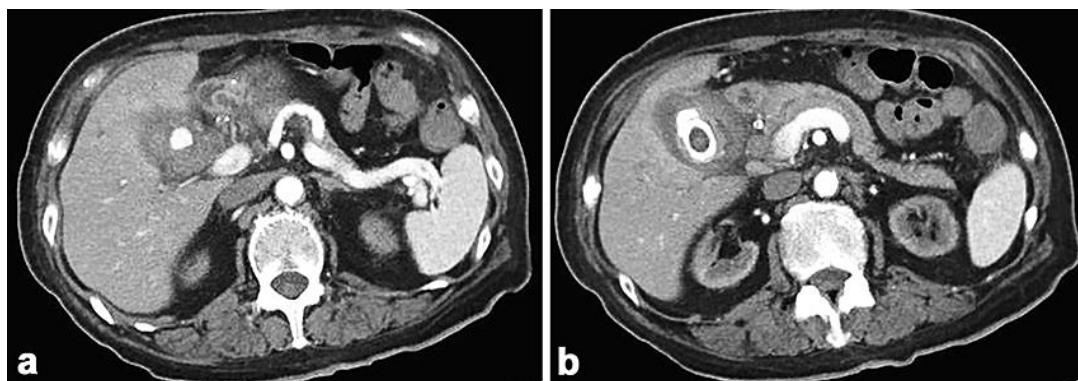
### Disclosure Statement

The authors have no conflict of interest.

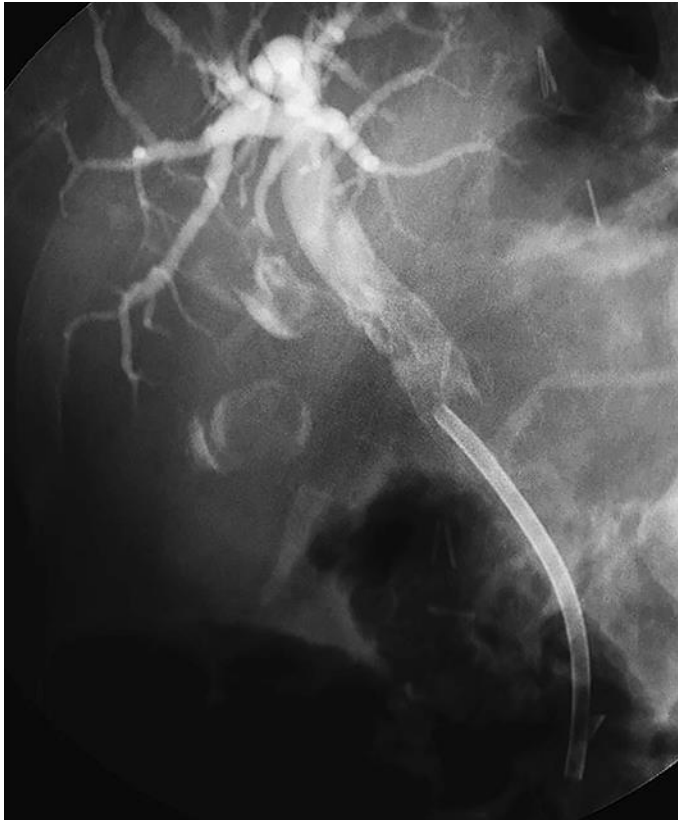### References

- 1 Nkwam N, Heppenstall K. Unruptured Pseudoaneurysm of the cystic artery associated with acute calculus cholecystitis. *J Surg Case Rep*. 2010 Apr;2010(2):4.
- 2 Akatsu T, Tanabe M, Shimizu T, Handa K, Kawachi S, Aiura K, et al. Pseudoaneurysm of the cystic artery secondary to cholecystitis as a cause of hemobilia: report of a case. *Surg Today*. 2007;37(5):412–7.
- 3 Desai AU, Saunders MP, Anderson HJ, Howlett DC. Successful transcatheter arterial embolisation of a cystic artery pseudoaneurysm secondary to calculus cholecystitis: a case report. *J Radiol Case Rep*. 2010;4(2):18–22.
- 4 Sandblom P. Hemorrhage into the biliary tract following trauma; traumatic hemobilia. *Surgery*. 1948 Sep; 24(3):571–86.
- 5 Kerr HH, Mensh M, Gould EA. Biliary tract hemorrhage; a source of massive gastro-intestinal bleeding. *Ann Surg*. 1950 May;131(5):790–800.
- 6 Glaysher MA, Cruttenden-Wood D, Szentpali K. A rare cause of upper gastrointestinal haemorrhage: ruptured cystic artery pseudoaneurysm with concurrent cholecystojejunial fistula. *Int J Surg Case Rep*. 2014;5(1):1–4.
- 7 Saluja SS, Ray S, Gulati MS, Pal S, Sahni P, Chattopadhyay TK. Acute cholecystitis with massive upper gastrointestinal bleed: a case report and review of the literature. *BMC Gastroenterol*. 2007 Mar;7(1):12.
- 8 Luzuy F, Reinberg O, Kauszlaric D, Anderegg A, Droguett M, Donati D, et al. Biliary calculi caused by hemobilia. *Surgery*. 1987 Nov;102(5):886–9.
- 9 Hiramatsu Y, Watanabe T, Shiokawa M, Kurita A, Matsuura M, Uza N, et al. Hemobilia: another complication associated with anti-thrombotic therapy. *Clin J Gastroenterol*. 2011 Feb;4(1):49–51.

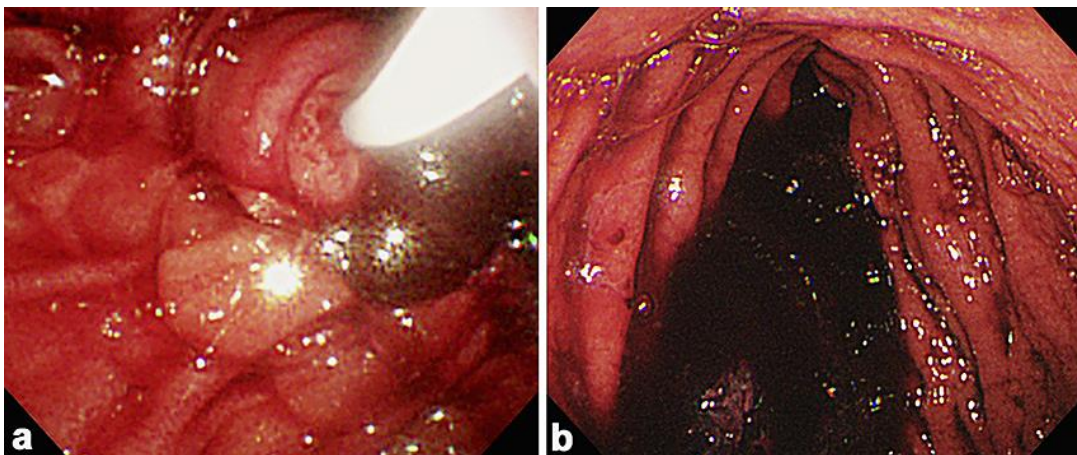
- 10 Kaida S, Arahata K, Itou A, Takarabe S, Kimura K, Kishikawa H, et al. Two cases of cystic artery pseudoaneurysm rupture due to acute cholecystitis with gallstone impaction in the neck. *Nihon Shokakibyō Gakkai Zasshi*. 2016 Sep;113(9):1572–81.
- 11 Mullen R, Suttie SA, Bhat R, Evgenikos N, Yalamarthy S, McBride KD. Microcoil embolisation of mycotic cystic artery pseudoaneurysm: a viable option in high-risk patients. *Cardiovasc Intervent Radiol*. 2009 Nov;32(6):1275–9.
- 12 Mokrane FZ, Alba CG, Lebbadi M, Mejdoubi M, Moulabbi M, Lombard F, et al. Pseudoaneurism of the cystic artery treated with hyperselective embolisation alone. *Diagn Interv Imaging*. 2013 Jun;94(6):641–3.
- 13 Green MH, Duell RM, Johnson CD, Jamieson NV. Haemobilia. *Br J Surg*. 2001 Jun;88(6):773–86.



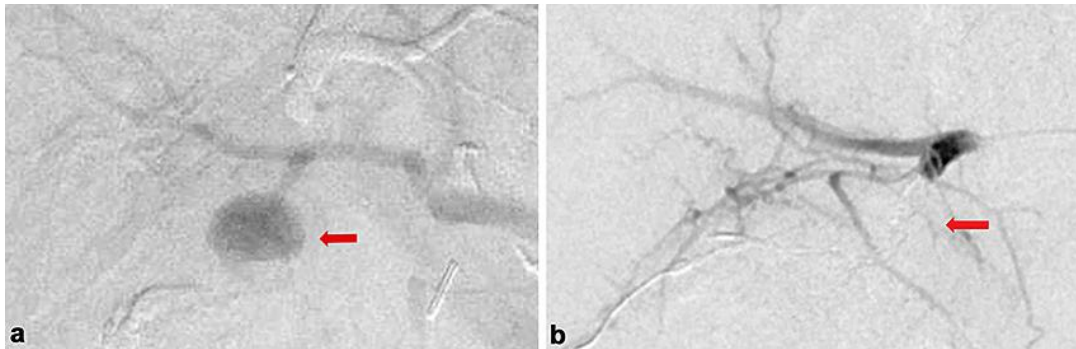
**Fig. 1.** Abdominal CT showing the cystic artery pseudoaneurysm (a) and hemobilia into the common bile duct and gallbladder stone (b).



**Fig. 2.** Endoscopic retrograde cholangiography showing dilatation of the common bile duct and a plastic stent (10 Fr, 5 cm) for drainage.



**Fig. 3. a, b** Endoscopy showing the hemorrhage from the papilla of Vater.



**Fig. 4.** Angiography showing the cystic artery pseudoaneurysm before embolization (**a**) and after embolization (disappeared) (**b**).