

School of Medicine, Experimental Medicine Building, Yunnan Garden Campus, Nanyang Technological University, 59 Nanyang Drive, 636921, Singapore; ⁴Translational and Clinical Research Institute, Newcastle University, Centre for Life, Newcastle upon Tyne, NE1 7RU, UK; and ⁵Bristol Dermatology Centre, University Hospitals Bristol NHS Foundation Trust, Bristol, UK

Correspondence: Neil Rajan.
Email: neil.rajan@newcastle.ac.uk

References

- Huriez C, Deminati M, Agache P et al. [Sclero-atrophiing and keratodermic genodermatosis of the extremities]. *Ann Dermatol Syphiligr (Paris)* 1969; **96**:135–46.
- Hamm H, Traupe H, Brocker EB et al. The scleroatrophic syndrome of Huriez: a cancer-prone genodermatosis. *Br J Dermatol* 1996; **134**:512–18.
- Lee YA, Stevens HP, Delaporte E et al. A gene for an autosomal dominant scleroatrophic syndrome predisposing to skin cancer (Huriez syndrome) maps to chromosome 4q23. *Am J Hum Genet* 2000; **66**:326–30.
- Gunther C, Lee-Kirsch MA, Eckhard J et al. SMARCAD1 haploinsufficiency underlies Huriez syndrome and associated skin cancer susceptibility. *J Invest Dermatol* 2018; **138**:1428–31.
- Marks KC, Banks WR 3rd, Cunningham D et al. Analysis of two candidate genes for Basan syndrome. *Am J Med Gen Part A* 2014; **164A**:1188–91.
- Nousbeck J, Burger B, Fuchs-Telem D et al. A mutation in a skin-specific isoform of SMARCAD1 causes autosomal-dominant dermatoglyphia. *Am J Hum Genet* 2011; **89**:302–7.
- Kavanagh GM, Jardine PE, Peachey RD et al. The scleroatrophic syndrome of Huriez. *Br J Dermatol* 1997; **137**:114–8.
- Chang X, Li D, Tian L et al. Heterozygous deletion impacting SMARCAD1 in the original kindred with absent dermatoglyphs and associated features (Baird, 1964). *J Pediatr* 2018; **194**:248–52.e2.

Funding sources: N.R. and S.M.'s research is supported by the Newcastle NIHR Biomedical Research Centre (BMRC). B.R. is a fellow of the National Research Foundation, an A*STAR Investigator and Young EMBO Investigator. This work was in part supported by a Strategic Positioning Fund on Genetic Orphan Diseases from the BMRC, A*STAR, Singapore to B.R. and B.V. C.M.H received funding support from the Nanyang Technological University Undergraduate Research Experience on Campus (URECA) Programme.

Conflicts of interest: none to declare.

Oral ivermectin for a scabies outbreak in a long-term care facility: potential value in preventing COVID-19 and associated mortality

DOI: 10.1111/bjd.19821

DEAR EDITOR, To date, the COVID-19 pandemic has affected over 85 million persons worldwide, with 14% of cases severe and 5% critical, and a general population case-fatality rate of 1%. Age is the main risk factor for severe disease and death,¹ making residents of long-term care facilities (LTCFs)

particularly vulnerable.² Therapeutic agents for COVID-19 remain sparse, but ivermectin, an antiparasitic, has shown anti-SARS-CoV-2 activity *in vitro*.³ Moxidectin, another macrocyclic lactone, with a longer plasma half-life, could also be considered.⁴

On 6 March 2020, a 66-year-old woman (Resident 1) with numerous comorbidities, from LTCF-A (Seine-et-Marne county, in suburban Paris, France) was referred to our dermatology department with profuse scabies. She was treated in our randomized controlled trial (NCT02841215) with ivermectin 400 or 200 µg kg⁻¹ (exact dose double-blinded) on days 0, 7 and 14. LTCF-A identified three more residents with scabies, residing on different floors, and declared an outbreak. They were treated accordingly, and all remaining LTCF-A residents and staff (n = 117) were also treated simultaneously with ivermectin (200 µg kg⁻¹, days 0–7, starting 10 March 2020) (Figure 1).

All confirmed or suspected cases of COVID-19 among LTCF-A's residents and staff from 5 March to 15 May 2020 were identified. LTCF-A residents' demographics (age and sex) and COVID-19 clinical outcomes (recovery, hospitalization or death) were recorded. During the same period (5 April to 1 May 2020; no prior data available), all confirmed COVID-19 cases and deaths in all other LTCFs in Seine-et-Marne were systematically declared in the French national online database (<https://signalement.social-sante.gouv.fr>) and all data were gathered by the Agence Régionale de Santé-Ile-de-France (<https://www.iledefrance.ars.sante.fr>).

We selected all county-wide LTCFs comparable with LTCF-A in terms of fees and size (50–90 residents). All remaining LTCFs provided aggregated demographic data (age and sex). Each retained LTCF – except LTCF-A – was considered a cluster. R software (v6.1.2; R Foundation, Vienna, Austria) was used to estimate COVID-19 infection and mortality rates, and their distributions. In parallel, an *in vitro* virological study measured the anti-SARS-CoV-2 activity of ivermectin and moxidectin on VeroE6-monkey kidney cells at increasing concentrations (range 0.05–10 µmol L⁻¹) by RNA quantification and immunofluorescence (with cell viability controlled at each step). We also performed a time-of-drug-addition assay.

Between 5 March and 15 May 2020, 69 LTCF-A residents (median age 90 years, interquartile range 84–94; 78% female) and 52 staff members received ivermectin (Figure 1). Eleven persons presented confirmed or suspected COVID-19 (1.4% declared in the ARS online database), with the first symptoms noticed on 11 March 2020 (Resident 1 on 19 March 2020). One resident (Resident 1) had a SARS-CoV-2-positive reverse-transcriptase polymerase chain reaction. No hospitalizations and no deaths were noted. Forty-five 'matched' county-wide LTCFs were included as a reference sample (out of 177), housing 3062 residents (median age 86 years, interquartile range 87–89; 77.3% female). Among them, a mean of 22.6% (95% confidence interval 16.3–28.9) acquired declared COVID-19, with a lethality of 4.9% (95% confidence interval 3.2–6.5).

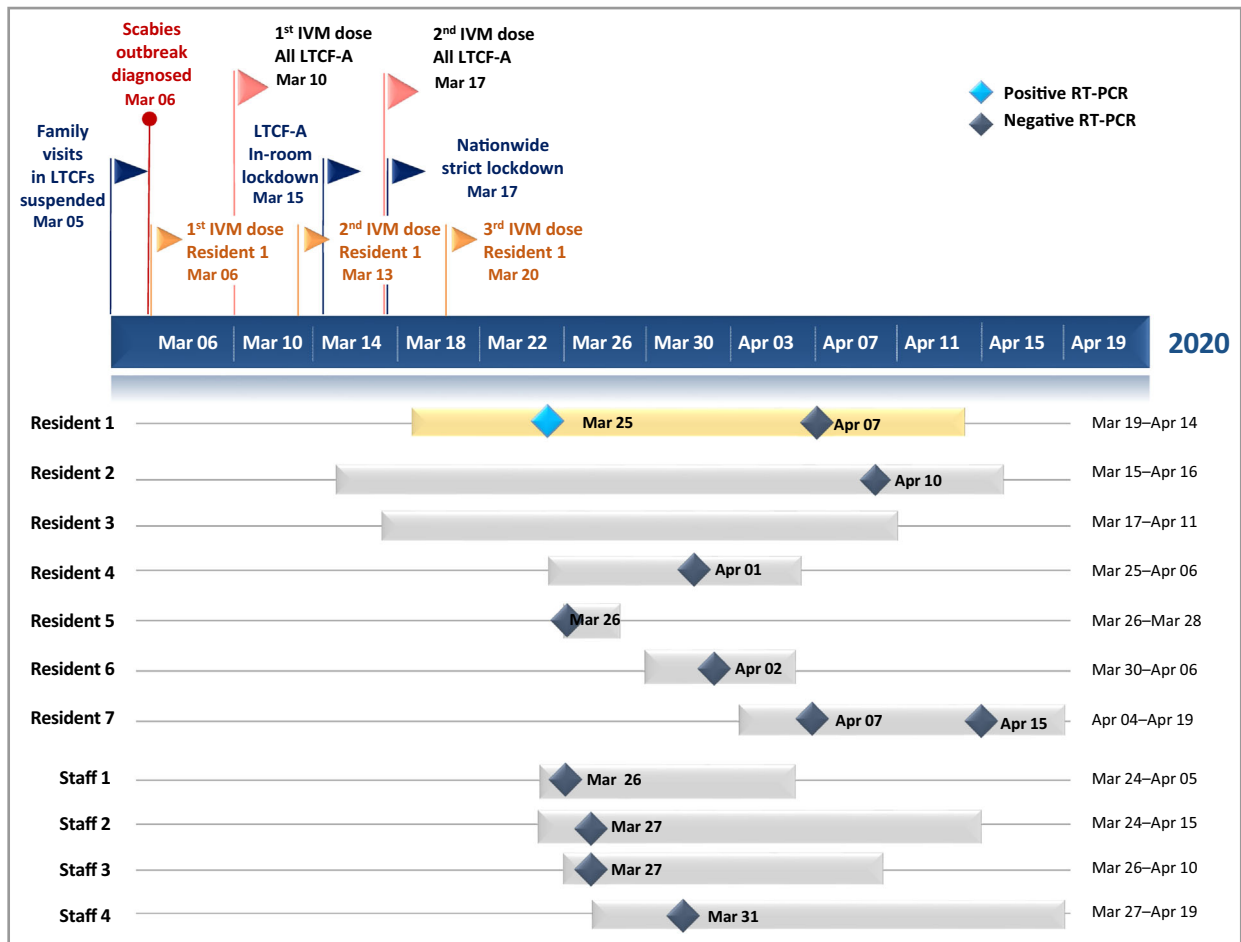




Figure 1 Concomitant COVID-19 and ivermectin-treated scabies outbreak in a long-term care facility. The navy blue timeline represents COVID-19-dictated closure coinciding with onset of a scabies outbreak in long-term care facility A (LTCF-A), and the oral ivermectin (IVM) treatments for the scabies-infested patients ($n = 4$) and their contacts ($n = 117$), for a total of 121 IVM-treated individuals, according to NCT02841215 and current therapeutic recommendations on scabies. The bars below the timeline represent the different individuals with confirmed or suspected COVID-19 (LTCF-A residents and staff). Real-time reverse-transcriptase polymerase chain reaction (RT-PCR) (RdRp gene, CT 36 and N gene, CT 34) detected Resident 1's COVID-19 (yellow bar).

The virological study confirmed important *in vitro* antiviral activity, with EC_{50} values of $0.14 \pm 0.02 \mu\text{mol L}^{-1}$ and $0.48 \pm 0.08 \mu\text{mol L}^{-1}$ for ivermectin and moxidectin, respectively. The maximum inhibitions at $5 \mu\text{mol L}^{-1}$ were 55 000 and 19 000-fold, respectively, without affecting cell viability. The study also showed dose-dependently limited numbers of SARS-CoV-2-infected cells, and complete inhibition of SARS-CoV-2 infection at $2.5 \mu\text{mol L}^{-1}$. When ivermectin and moxidectin were added 3 h after infection (i.e. early during SARS-CoV-2 infection), no antiviral effect was seen (data not shown).

To control scabies, the entire LTCF-A population was given ivermectin, while at the same time a COVID-19 outbreak was declared. No ivermectin-exposed LTCF-A resident developed severe COVID-19 or died, while residents from control LTCFs showed higher COVID-19 rates. Usually, once COVID-19 enters an LTCF – in any healthcare system – its rapid dissemination⁵ is associated with a high risk of death. Ivermectin is

an antiparasitic drug that is used to treat neglected tropical diseases such as onchocerciasis, helminthiases and scabies, and is evaluated at high doses for malaria control. It could have a protective role in COVID-19 within a therapeutic margin,⁶ as supported by our optimized virological study. Other populations might have already benefited from ivermectin, as its use was associated with lower in-hospital mortality in a multihospital retrospective cohort study of 280 North American patients [ivermectin, $n = 173$ (15%) vs. no ivermectin, $n = 107$ (25.2%), odds ratio 0.52, 95% confidence interval 0.29–0.96; $P = 0.03$].⁷ There are both epidemiological (i.e. the ecological nature of the data with probability of unmeasured confounding) and virological limitations of the available data, and difficulties in extrapolating *in vitro* antiviral effects against different coronaviruses to clinical efficacy. However, the plausibility is sufficient to carry out further studies to elucidate whether ivermectin (and moxidectin) is or is not an appropriate candidate for the prevention of COVID-19.

Acknowledgments: We would like to gratefully acknowledge all of the residents, healthcare workers and administrative staff of LTCF-A and their directors for agreeing to participate in this report, and providing their technical support. We acknowledge Margaut Petignier, ARS Ile-de-France, for assistance in generating COVID-19 and mortality rate data in Seine-et-Marne county, and all of the certified nurse assistants and administrative staff of the 45 LRCFs that agreed to share their demographic information. We thank Saskia Ingen-Housz-Oro, Françoise Foulet, Audrey Colin and the nursing staff of the Dermatology Department, Henri-Mondor Hospital, Créteil, for their devoted patient care; Hayat Medjenah, Elie Guichard, Laetitia Grégoire, the AGEPS pharmacists and the administrative staff of the Unité de Recherche Clinique, Henri-Mondor Hospital, Créteil, for NCT02841215 RCT support; Françoise Botterel and Jacques Guillot for their assistance supervising preliminary laboratory work; Selim Aractingi, Jean-Philippe Derenne, Anaïs Farcet, Bruno Housset, Pascal del Giudice, Fatimata Ly and Solène Makdessi for discussions and thoughtful advice; Anne-Claude Crémieux for the specific COVID-19 literature weekly review of APHP hospitals; and Janet Jacobson for editorial assistance.

C. Bernigaud ^{1,2} D. Guillemot,^{3,4,5} A. Ahmed-Belkacem,⁶ L. Grimaldi-Bensouda,^{3,4} A. Lespine,⁷ F. Berry,⁶ L. Softic,⁶ C. Chenost,⁸ G. Do-Pham,⁹ B. Giraudeau,¹⁰ S. Fourati^{1,6} and O. Chosidow ^{1,2}

¹APHP, Hôpital Henri-Mondor, Université Paris-Est, Créteil, France; ²Research Group Dynamic, Université Paris-Est Créteil, Créteil, France; ³Université Paris-Saclay, Montigny-Le-Bretonneux, France; ⁴APHP, Paris-Saclay, Le Kremlin-Bicêtre, France; ⁵Institut Pasteur, Epidemiology and Modelling of Antibiotic Evasion, Paris, France; ⁶Inserm U955, Université de Santé, Paris-Est, Créteil, France; ⁷INTHERES, Université de Toulouse, Toulouse, France; ⁸Long-Term Care Facility Chief Medical Officer, Seine-et-Marne, France; ⁹Service de Médecine Interne, Centre Intercommunal de Créteil, Créteil, France; and ¹⁰UMR SPHERE Inserm U1246, Université de Tours, Tours, France
Email: charlotte.bernigaud@aphp.fr

D.G. and A.A.-B. contributed equally. L.G.-B. and A.L. contributed equally. B.G. and S.F. contributed equally.

References

- Williamson E, Walker AJ, Bhaskaran KJ et al. Factors associated with COVID-19-related death using OpenSAFELY. *Nature* 2020; **584**:430–6.
- McMichael TM, Currie DW, Clark S et al. Epidemiology of COVID-19 in a long-term care facility in King County, Washington. *N Engl J Med* 2020; **382**:2005–11.
- Caly L, Druce JD, Catton MG et al. The FDA-approved drug ivermectin inhibits the replication of SARS-CoV-2 in vitro. *Antiviral Res* 2020; **178**:104787.
- Guzzo CA, Furtek CI, Porras AG et al. Safety, tolerability, and pharmacokinetics of escalating high doses of ivermectin in healthy adult subjects. *J Clin Pharmacol* 2002; **42**:1122–33.
- Arons MM, Hatfield KM, Reddy SC et al. Presymptomatic SARS-CoV-2 infections and transmission in a skilled nursing facility. *N Engl J Med* 2020; **382**:2081–90.
- Bray M, Rayner C, Noël F et al. Ivermectin and COVID-19: a report in *Antiviral Research*, widespread interest, an FDA warning, two letters to the editor and the authors' responses. *Antiviral Res* 2020; **178**:104805.
- Cepelowicz Rajter J, Sherman M, Fatteh N et al. Use of ivermectin is associated with lower mortality in hospitalized patients with COVID-19 (ICON study). *Chest* 2021; **159**:85–92.

Funding sources: The double-blind randomized controlled trial GALECRUSTED (NCT02841215) is funded by the French Ministry of Health (Programme Hospitalier de Recherche Clinique, 2014 AOM14612) and supported by a grant from the French Society of Dermatology (March 2019).

Conflicts of interest: C.B. and O.C. act as unpaid scientific advisors for Medicines Development for Global Health. O.C. is the principal investigator of the RCT 'Dose-finding Study of Moxidectin for Treatment of Scabies' (NCT03905265). G.D.-P. is the principal investigator, B.G. is the main statistician and O.C. is the scientific head of the RCT 'Efficacy Study Between Two Different Dosages of an Antiparasitic in Patients With Crusted Scabies 'GALECRUSTED' (NCT02841215).

Linear and disseminated porokeratosis in one family showing identical and independent second hits in MVD among skin lesions, respectively: a proof-of-concept study

DOI: 10.1111/bjd.19824

DEAR EDITOR, Porokeratosis is an autosomal dominant skin disorder characterized by annular or circular skin lesions surrounded by a hyperkeratotic rim called 'cornoid lamella'.¹ Clinical subtypes of porokeratosis have been classified mostly based on age at onset, and the distribution and size of skin lesions.¹ It has been demonstrated that most patients with porokeratosis have a heterozygous germline mutation in genes that encode enzymes of the mevalonate pathway (MVK, MVD, PMVK or FDPS) in both familial and sporadic cases.^{2,3} Recent reports have claimed that second-hit genetic changes that render the monoallelic mutation biallelic initiate the formation of skin lesions in linear porokeratosis (LP)^{4,5} and disseminated superficial actinic porokeratosis (DSAP).⁵ Here, we present a familial case of porokeratosis with DSAP in a father and LP in his daughter. Biopsy of multiple skin lesions revealed independent second hits in DSAP, and an identical hit in LP, as previously observed in sporadic cases,⁵ which validates the concept of the porokeratosis pathogenesis.

Patient 1 was an 83-year-old Japanese man with type 2 diabetes mellitus who presented to our hospital with annular skin lesions distributed throughout the entire body (Figure 1a). These lesions were itchy and had been present for approximately 50 years, over which time they increased in number.