

MINI-FOCUS ISSUE: IMAGING

INTERMEDIATE

IMAGING VIGNETTE: CLINICAL VIGNETTE

3-Dimensional Speckle-Tracking Echocardiography-Derived Interventricular Activation Imaging in a Patient With Repaired Tetralogy of Fallot



Tomoko Ishizu, MD, PHD,^a Yoshihiro Seo, MD, PHD,^b Yuki Komatsu, MD, PHD,^a Nobuyuki Ohte, MD, PHD,^b Masaki Ieda, MD, PHD^a

ABSTRACT

Using 3-dimensional speckle-tracking echocardiography-derived activation imaging system, we visualized interventricular dyssynchrony in a repaired tetralogy of Fallot case with pacing-induced left ventricular dysfunction. The activation imaging system visualized interventricular dyssynchrony and resynchronization after cardiac resynchronization therapy and may be useful to assess electromechanical disturbance in complicated congenital heart diseases. **(Level of Difficulty: Intermediate.)** (J Am Coll Cardiol Case Rep 2020;2:1575–7) © 2020 The Authors. Published by Elsevier on behalf of the American College of Cardiology Foundation. This is an open access article under the CC BY-NC-ND license (<http://creativecommons.org/licenses/by-nc-nd/4.0/>).

Cardiac resynchronization therapy (CRT) has been performed in adult congenital heart diseases (ACHD) with electrophysiological disturbances. However, the evaluations of mechanical dyssynchrony are often challenging because of complicated anatomical and electrophysiological matters. Three-dimensional speckle-tracking echocardiography (3D-STE) is available as the activation imaging, which can image the propagation of regional myocardial contraction in both ventricles (1,2). Recently, the authors developed an activation imaging system that can visualize images integrating both ventricular contractions. Then, they used the modality in assessing the effect of CRT in a patient with ACHD.

A 24-year-old man with tetralogy of Fallot had a history of intracardiac repair that was performed when he was 3 years of age and elimination of remaining right ventricular (RV) outflow obstruction that was performed when he was 8 years of age. During the second operation with a monocusp transannular patch, the complete atrioventricular block was caused, and epicardial DDD pacemaker implantation was performed, and the RV lead was located at RV outflow (Supplemental Figure 1). When he was 21 years old, he presented with left ventricular (LV) systolic dysfunction with 28% LV ejection fraction (EF) and was treated with enalapril and carvedilol, which could not improve LV systolic function. Also, severe pulmonary regurgitation PR was concomitant. Because magnetic resonance imaging was not available due to the magnetic resonance imaging nonconditional pacemaker, 3D-STE was used in assessing both ventricular functions and revealed that LVEF was 30% and RVEF was 42%. Besides, the activation imaging system allowed us to visualize the

From the ^aDepartment of Cardiology, Faculty of Medicine, University of Tsukuba, Tsukuba, Japan; and the ^bDepartment of Cardiology, Nagoya City University Graduate School of Medical Sciences, Nagoya City, Japan. The authors have reported that they have no relationships relevant to the contents of this paper to disclose. The authors attest they are in compliance with human studies committees and animal welfare regulations of the authors' institutions and Food and Drug Administration guidelines, including patient consent where appropriate. For more information, visit the *JACC: Case Reports* [author instructions page](#).

Manuscript received May 18, 2020; accepted June 9, 2020.

ABBREVIATIONS AND ACRONYMS

ACHD = adult congenital heart diseases

CRT = cardiac resynchronization therapy

EF = ejection fraction

LV = left ventricular

RV = right ventricular

2D = 2-dimensional

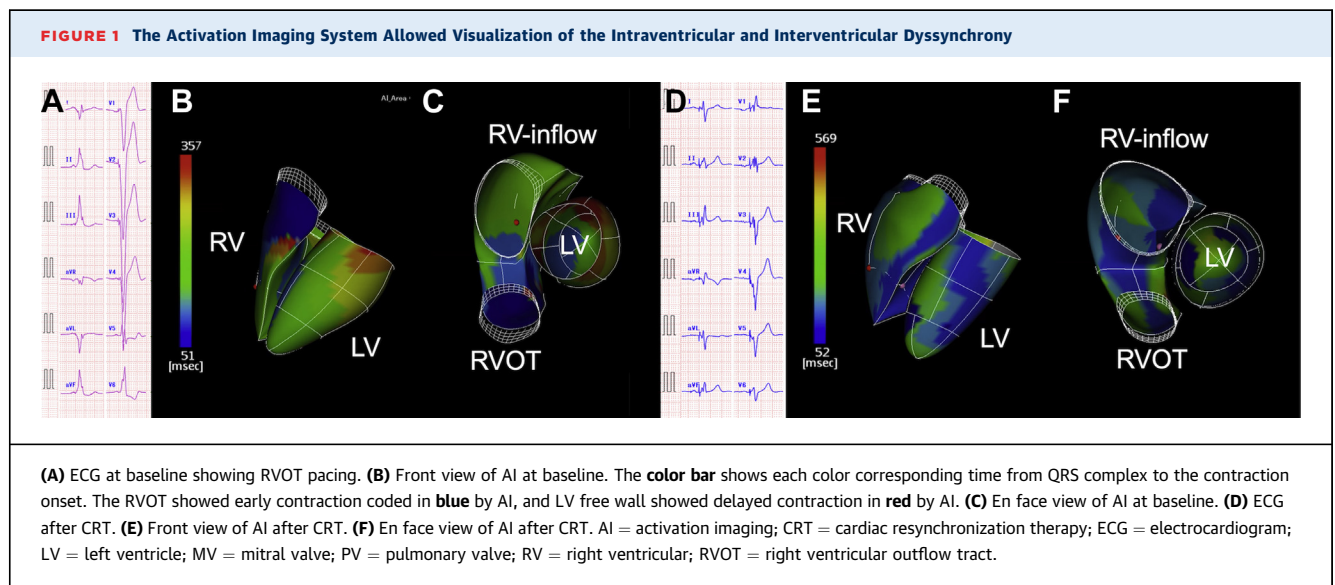
3D-STE = 3-dimensional speckle-tracking echocardiography

intraventricular and interventricular dyssynchrony (Figure 1, Videos 1, 2, 3, and 4). Despite the presence of severe pulmonary regurgitation, it was apparent that his critical issue was LV dysfunction caused by pacemaker-induced LV dyssynchrony. Then, CRT was performed when he was 22 years old, and intraventricular and interventricular dyssynchrony was dramatically resynchronized (Figure 1). At 1 year after CRT, LV reverse remodeling was obtained (LV end-systolic volume, 113 to 90 ml, 20% reduction, LVEF 30% to 42%). In contrast, despite RV resynchronization, RVEF was reduced from 42% to 38%. The residual significant pulmonary insufficiency may be related to the nonresponded RV function after CRT.

DISCUSSION

Because of the large variability of electromechanical sequences with very different structures, patients with ACHD require tailor-made therapy for each case. The integrated activation imaging of both ventricles may be helpful in assessing the pathophysiology and be a guide for a strategy using cardiac implantable electronic devices in patients with ACHD. In the present case, we used the 3D-STE, which is derived from the cubic pattern-matching technology using the cube-shaped template in a 3D echocardiography volume dataset (3). 3D-STE is better than 2-dimensional (2D)-STE in the following points. First, 3D-STE is not affected by the 3D movement of the heart. In the setting of 2D echocardiography, the heart moves through the 2D plane of interest, and, in fact, different myocardium appear in the 2D image frame by frame (4). This is called “through plane or out of the plane phenomenon.” Second, for RV, 2D assessment has drawbacks related to the intrinsic complexity in its anatomy and deformation pattern. As a result, this may cause no negligible effects on the accuracy of tissue tracking in 2D images. In contrast, 3D full-volume LV and RV data overcome the limitation of the plane-dependency of the 2D image (5).

We presented this case with the development of pacemaker-induced dyssynchrony in congenital heart disease, which is a critical sequela in ACHD care with the previous implantation of a pacemaker at childhood. The initial pacemaker ventricular lead was on the RV outflow region, which is an uncommon site for epicardial pacing. According to the multicenter study by Janoušek et al. (6), epicardial pacing lead site is rarely at RV outflow tract (n = 8 of 178; 5%), and they concluded that the pacing from the RV outflow tract/lateral RV was related to significantly decreased LV function.




ADDRESS FOR CORRESPONDENCE: Dr. Yoshihiro Seo, Department of Cardiology, Nagoya City University Graduate School of Medical Sciences, 1 Kawasumi, Mizuho-Cho, Mizuho-Ku, Nagoya 467-8601, Japan. E-mail: yo-seo@med.nagoya-cu.ac.jp.

REFERENCES

1. Seo Y, Ishizu T, Kawamura R, et al. Three-dimensional propagation imaging of left ventricular activation by speckle-tracking echocardiography to predict responses to cardiac resynchronization therapy. *J Am Soc Echocardiogr* 2015;28:606-14.
2. Ishizu T, Seo Y, Atsumi A, et al. Global and regional right ventricular function assessed by novel three-dimensional speckle-tracking echocardiography. *J Am Soc Echocardiogr* 2017;30:1203-13.
3. Takeguchi T, Nishiura M, Abe Y, Ohuchi H, Kawagishi T. Practical considerations for a method of rapid cardiac function analysis based on three-dimensional speckle tracking in a three-dimensional diagnostic ultrasound system. *J Med Ultrason* 2010;37:41-9.
4. Mann DL, Gillam LD, Weyman AE. Cross-sectional echocardiographic assessment of regional left ventricular performance and myocardial perfusion. *Prog Cardiovasc Dis* 1986;29:1-52.
5. Seo Y, Ishizu T, Atsumi A, Kawamura R, Aonuma K. Three-dimensional speckle tracking echocardiography. *Circ J* 2014;78:1290-301.
6. Janoušek J, van Geldorp IE, Krupičková S, et al. Permanent cardiac pacing in children: choosing the optimal pacing site: a multicenter study. *Circulation* 2013;127:613-23.

KEY WORDS activation imaging system, tetralogy of Fallot, 3-dimensional speckle-tracking echocardiography

 **APPENDIX** For a supplemental figure and videos, please see the online version of this paper.