

Postoperative posterior capsular striae and the posterior capsular opacification in patients implanted with two types of intraocular lens material

Rajesh Subhash Joshi

Aim: To evaluate the incidence of postoperative posterior capsular striae (PCS) and its influence on posterior capsular opacification (PCO) in patients implanted with two types of lens material. **Setting:** Tertiary eye care center in central rural India. **Study Design:** A prospective, observational, nonrandomized study. **Materials and Methods:** The study included 1247 patients having age-related cataract scheduled for removal by phacoemulsification technique and implantation of hydrophilic or hydrophobic intraocular lens (IOL). Demographic profile, nuclear grading, axial length, and IOL power were noted. Details of PCS were noted on the 1st postoperative day in patients with clear cornea. Postoperative follow-up was ensured to study the status of PCS and development of PCO. **Results:** The overall incidence of PCS was 19.8% (247 out of 1247 eyes). Out of 1247 patients, 641 patients (51.4%) had hydrophilic IOL implantation and 201 eyes had PCS (31.4%) and 606 patients (48.6%) had hydrophobic IOL implantation and 46 eyes had PCS (7.6%), $P = 0.04$. Three and more striae were seen in 119 eyes (119/641, 18.6%) in hydrophilic group and 4 eyes (4/606, 0.66%) in hydrophobic group. Sixty-two eyes (62/201, 30.9%) in hydrophilic group with multiple PCS were reported with persistent striae after 6 months of surgery. Two eyes in hydrophobic group had persistent striae even after 3 years of follow-up. Evaluation of PCO score of the hydrophilic group was 0.6 whereas of the hydrophobic group was 0.1 ($P = 0.04$). Ten patients of the hydrophilic group only required neodymium-doped yttrium aluminum garnet (ND: YAG) laser capsulotomy. **Conclusion:** The incidence of PCS was higher in hydrophilic than hydrophobic IOLs. Multiple PCS persisting in patients beyond 6 months after operation should be followed up for early development of PCO, particularly in patients implanted with hydrophilic IOL.

Key words: Hydrophilic intraocular lens, hydrophobic intraocular lens, posterior capsular opacification, posterior capsular striae

Intraoperative posterior capsular striae (PCS) are characteristically seen after the implantation of intraocular lens (IOL) into the capsular bag. Striae appear to arise in the axis joining the apices of the haptics because of a size disparity between the IOL and the capsular bag.^[1] Previous studies showed that the development of intraoperative PCS has been associated with older age, greater lens thickness, and shorter axial length.^[2] They have not been reported with the placement of IOL over the capsular bag, suggesting that disparity between the size of the IOL and bag leads to the formation of striae. It has been shown that the presence of two or more striae suggests greater disparity between bag and the IOL.^[3,4]

Vasavada and Trivedi had studied on the disappearance of striae and its long-term effect on vision.^[2] Nonetheless, Wolken and Oetting had analyzed the formation of linear posterior capsular opacification (PCO) along persistent striae.^[1] The presence of such linear striae with PCO in the visual axis may cause visual problems necessitating neodymium-doped yttrium aluminum garnet (ND: YAG) laser capsulotomy. Shah *et al.* have shown no effect of PCS on the development of PCO over the follow-up period of 3 years.^[5]

Department of Ophthalmology, Shri Vasantarao Government Medical College, Yavatmal, Maharashtra, India

Correspondence to: Dr. Rajesh Subhash Joshi, 77, Panchatara Housing Society, Manish Nagar, Somalwada, Nagpur - 440 015, Maharashtra, India. E-mail: jrjesh5@rediffmail.com

Manuscript received: 28.04.16; **Revision accepted:** 17.05.17

Video Available on:
www.ijo.in

Access this article online

Website:
www.ijo.in

DOI:
10.4103/ijo.IJO_344_16

Quick Response Code:



IOL materials are segregated into hydrophobic and hydrophilic. Hydrophilic IOLs are widely used as it can be implanted in patients through sub-2-mm incision due to its property of compressibility.^[6,7] Literature confirms that incidence rate of PCO in patients implanted with hydrophilic lenses is higher than that in hydrophobic group.^[8-11] However, some studies also contradict that PCO incidence in hydrophilic is less than that in hydrophobic lenses.^[12,13]

In the previous studies of clinical practice, there has been no comparison of development of PCS between two commonly used IOL materials and the influence of the increased number of striae on the development of PCO. Therefore, the aim of the present study is to compare the influence of PCS incidences in patients implanted with two different types of lens material.

Materials and Methods

The Ethical Committee of the hospital approved the study. Written informed consent was also obtained from each patient.

This is an open access article distributed under the terms of the Creative Commons Attribution-NonCommercial-ShareAlike 3.0 License, which allows others to remix, tweak, and build upon the work non-commercially, as long as the author is credited and the new creations are licensed under the identical terms.

For reprints contact: reprints@medknow.com

Cite this article as: Joshi RS. Postoperative posterior capsular striae and the posterior capsular opacification in patients implanted with two types of intraocular lens material. *Indian J Ophthalmol* 2017;65:466-71.

Patients with uncomplicated age-related cataract having phacoemulsification during the study period, i.e., January 2011–December 2012, were evaluated in a prospective observational manner. Patients were allocated to one of the groups depending on the preference for the implantation of IOL.

Exclusion criteria were corneal degeneration, dystrophies and scarring, glaucoma, uveitis, previous intraocular surgeries, subluxated cataracts, poor pupillary dilation, and intraoperative complications such as posterior capsular tear.

Surgical technique

Preoperative dilatation of the pupil was achieved using a combined solution of 0.8% tropicamide and 5% phenylephrine. Patients were operated under 0.5% topical proparacaine hydrochloride drops instilled twice in every 10 min before the surgical procedure, which was supplemented by 0.5 ml subconjunctival injection of 2% lignocaine hydrochloride at the beginning of the surgery. A side port incision was created on the appropriate side. Viscoelastic (2% hydroxypropyl methylcellulose, Appavisc, Appasamy Ocular Devices, Puducherry, India) was injected through the side port with 23-gauge blunt tip cannula. A 2.8-mm clear corneal temporal incision was performed. Continuous curvilinear capsulorhexis of approximate size of 5–5.5 mm was completed using the capsulorhexis forceps under the viscoelastic material. Hydrodissection was accomplished with balanced salt solution.

The settings used for nucleus chop were 90% (linear) power, 350 mmHg vacuum, and aspiration flow rate of 34 cm³/min. Phacoemulsification was performed in the capsular bag by implementing the quick-chop technique.^[14] A thorough cortical cleanup was accomplished by irrigation-aspiration probe. A single-piece hydrophilic (12.50 mm length, 6 mm optic diameter, Ultima Natural, Biovision limited, Wayside, Tring road, Wellhead, Dunstable, Beds, UK) or hydrophobic (Acrysof Natural, single-piece, 13 mm length, 6 mm optic size, planar haptics, Acrysof IQ SN60WF, Alcon Laboratories, Inc.) lens was implanted in the capsular bag.

Postoperative assessment

On the 1st postoperative day, patients were examined under slit lamp for PCS incidence along with their number and location. Follow-up visits were scheduled for patients with striae incidences after 2 days, 7 days, 1 month, 3 months, 6 months, and 3 years, postoperatively. Individual retro-illumination slit lamp images (Imaging system-990 5X Elite, CSO, Italy) were obtained at each visit. The morphology of PCSs observed was categorized as:

1. Single stria with single-fold covering the entire optic area on the posterior capsule [Fig. 1]
2. Two folds covering the entire optic area [Fig. 2]
3. Three or more striae confining to the optic area [Fig. 3].

Patients with persistent PCS after 6 months of surgery were evaluated for PCO by using Evaluation of PCO Software (EPCO).^[15] Kai Mehlretter and Klaus Sauer, Mannheim, Germany, developed the Software EPCO2000. It was first released in 1997. However, new updated version was released in September 2000.

The density of the opacification in the area behind the IOL optic (5.0–6.0 mm) was graded from 0 to 4 (i.e., 0 = none, 1 = minimal, 2 = mild, 3 = moderate, and 4 = severe). The

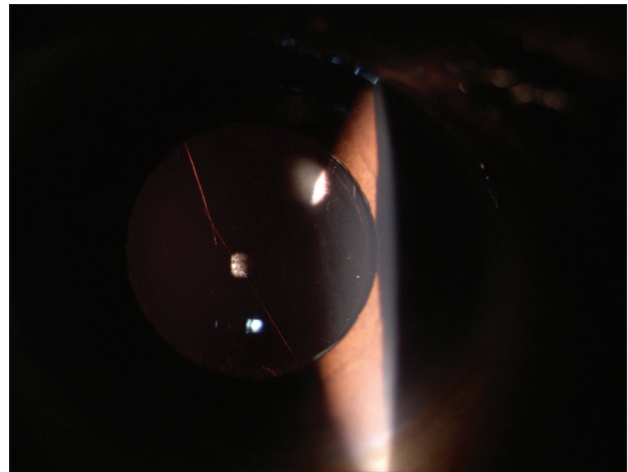


Figure 1: Single stria covering the entire optic area on the posterior capsule




Figure 2: Two folds covering the entire optic area




Figure 3: Three or more striae confining to the optic area

individual PCO scores were calculated by multiplying the density of the opacification by the fraction of the capsule area involved behind the optic. The result was inferred in terms of EPCO score.

Statistical analysis was performed using the Chi-square test for independence and the Student's *t*-test.

Results

A total of 1247 patients were operated during the study period, of which 247 patients (19.8%) had postoperative PCS incidences. Out of 1247 patients, 641 patients (51.4%) had hydrophilic IOL implantation and 201 eyes had PCS (31.4%) and 606 patients (48.6%) had hydrophobic IOL implantation and 46 eyes had PCS (7.6%), $P = 0.04$.

The mean patient's age was 69.59 ± 11.74 (standard deviation) in Group 1 and 69.91 ± 11.54 in Group 2, with no significant difference ($P = 0.63$). There were 660 (52.93%) males and 587 (47.07%) females ($P = 0.62$) in total, of which 122 male (49.39%) and 125 female (50.61%) patients developed striae ($P = 0.53$). Demographic characteristics of two groups are depicted in Table 1.

Average axial length in Group 1 was 22.63 ± 1.52 mm and in Group 2 was 21.09 ± 2.06 mm ($P = 0.89$). In Group 1, 12 out of

17 eyes (70.59%) having axial length < 22 mm and 10 out of 20 eyes (50%) having 26 mm or more axial length developed striae. In Group 2, two out of 15 eyes (13.3%) with 22 mm or less axial length and three out of 14 eyes (21.4%) with 26 mm or more axial length developed striae. The mean capsulorhexis size in both the groups was 5.5 ± 0.32 mm. In Group 1, 90% patients had a central capsulorhexis, while in Group 2, the rate was 92% ($P = 0.07$). The IOL was well centered in both the groups. The grade of cataract was considered to be hard in 15 eyes (2.34%) of Group 1 and 5 eyes (0.83%) of Group 2 ($P = 0.65$). Five of 15 eyes in hydrophilic group ($P = 0.67$) and two of five eyes ($P = 0.68$) in hydrophobic group developed PCS.

The distribution of PCS is depicted in Table 2. Single stria was seen in 37 eyes (37/641, 5.77%) in hydrophilic group and 33 eyes (33/606, 5.45%) in hydrophobic group. Three and more striae were seen in 119 eyes (119/641, 18.6%) in hydrophilic and 4 eyes (4/606, 0.66%) in hydrophobic group. Disappearance of striae in the hydrophilic group is shown in Table 3. Maximum number of single stria (15 eyes, 15/201, 7.5%) disappeared by the 2nd postoperative day. Remaining 2-fold striae (22 eyes) disappeared by 3 months of postoperative period. In patients with multiple striae, 62 (62/201, 30.9%) eyes had persistent striae even after 6 months postoperatively.

In the hydrophobic group, single stria disappeared by the 2nd postoperative day in 23 eyes (23/46, 50%). However, the striae persisted in two eyes (2/46, 4.4%) even after 3 years of follow-up [Fig. 4] without any PCO occurrences. Out of four eyes with multiple striae, two eyes were observed with striae disappearance by the day 2 of the surgery and rest two had persistent striae even after 6 months. The course of PCS of this group of patients is illustrated in Table 4. None of the patients reported any visual symptoms of striae incidences.

The mean baseline distance visual acuity in the hydrophilic group after 6 months of follow-up was 0.09 logMAR (± 0.1) and 3 years of follow-up was 0.3 logMAR (± 0.2) ($P = 0.86$), whereas in hydrophobic group, it was 0.08 logMAR (± 0.1) after 6 months and 0.2 logMAR (± 0.2) after 3 years ($P = 0.83$).

The number of striae and PCO observed in both the IOL groups are represented in Table 5. Twenty-one patients in the hydrophilic and two patients in the hydrophobic group detected with three or more striae had PCO (0.02). Under the category of multiple striae, PCO occurred in the hydrophilic group within 12–18 months [Fig. 5a and b], whereas it

Table 1: Demographic characteristics of two groups

Characteristics	Hydrophilic group	Hydrophobic group	<i>P</i>
Age (years), mean \pm SD	69.59 \pm 11.74	69.91 \pm 11.54	0.63
Range	49–80	50–80	
Sex (female/male)	300/341	287/319	0.57
Eye (right/left)	419/222	328/278	0.47
Grade of cataract (NO 2/NO 3/NO 4)	200/300/141	180/200/226	
Axial length (mm)	22.63 \pm 1.52	21.09 \pm 2.06	0.89

NO: Nuclear opalescence, SD: Standard deviation

Table 2: Distribution of posterior capsular striae in two groups

Number of striae	Hydrophilic group (n=641)	Hydrophobic group (n=606)
Single (%)	37 (5.77)	33 (5.45)
Two (%)	45 (7.02)	9 (1.49)
Three and more (%)	119 (18.6)	4 (0.66)
Total eyes	201	46

Table 3: Course of posterior capsular striae in hydrophilic group (distribution out of 201 eyes)

Number of striae	Day 2	7 days	30 days	90 days	180 days	Persisted after 180 days	Total eyes (%)
Single stria (%)	15 (7.5)	7 (3.5)	10 (5)	5 (2.5)	-	-	37 (18.4)
Two striae (%)	18 (9)	8 (4)	3 (1.5)	2 (1)	4 (2)	10 (5)	45 (22.4)
Three and more striae (%)	18 (9)	15 (7.5)	8 (4)	10 (5)	6 (3)	62 (30.9)	119 (59.2)

Table 4: Course of posterior capsular striae in hydrophobic group (distribution out of 46 eyes)

Number of striae	Day 2	7 days	30 days	90 days	180 days	Persisted after 180 days	Total eyes (%)
Single stria (%)	23 (50)	5 (10.9)	1 (2.2)	1 (2.2)	1 (2.2)	2 (4.4)	33 (71.7)
Two striae (%)	7 (15.2)	1 (2.2)	1 (2.2)	-	-	-	9 (19.6)
Three and more striae (%)	2 (4.4)	-	-	-	-	2 (4.4)	4 (8.8)

was 3 years in the hydrophobic group [Fig. 6]. EPCO score was 0.6 and 0.1 in hydrophilic and hydrophobic groups, respectively ($P = 0.04$) [Table 6]. Ten patients in hydrophilic group required ND: YAG laser capsulotomy, while none of the patients in a hydrophobic group required capsulotomy.

Discussion

Intraoperative or postoperative posterior capsule striae are commonly seen after implantation of posterior chamber IOL in the capsular bag.^[1,2] They appear after the removal of the viscoelastic material from the bag. The striae tend to disappear with the remodeling of capsule-haptic interface.

Striae have been shown to disappear by the 5th month of postsurgery phase.^[2] Wolken and Oetting have shown persistent striae leading to PCO after the implantation of multi-piece hydrophobic IOL.^[1]

In the present study, the overall incidence of postoperative PCS was 19.8%. The incidence rate in hydrophobic group was 7.6%, while it was 31.4% in hydrophilic group. A study by Vasavada and Trivedi showed 56% incidence of intraoperative striae in multi-piece^[2] and 13.6% in single-piece hydrophobic IOL.^[5] The lower incidence of striae in hydrophobic group in

our study could be due to the consideration of postoperative period for the examination of striae, i.e., by which time IOL gets remodeled in the capsular bag and disappears with the deepening of the anterior chamber of the striae. We could not compare incidence of striae in the hydrophilic group as there has been no study in the literature on this IOL material, to the best of our knowledge. However, our results recorded more striae incidences in hydrophilic group as compared to the hydrophobic group. This could be due to the difference in the configuration of the haptics in two groups and the overall size of the lenses. The size of the implanted hydrophilic lens was 12.5 mm against the 13 mm size of hydrophobic lens. A small-sized IOL shows unstable fixation due to the insufficient arc of contact between haptics and capsular bag,^[16] while large-sized IOL causes stretching of the capsular bag leading to the formation of striae.^[17] On comparing the haptics, hydrophilic IOL is bulkier and broader than the hydrophobic ones stretching the capsular bag along with the axis of the haptics. The striae were seen on the axis joining the highest point of the haptics. Hydrophilic IOLs are present with closed-end loupe and cervixes in the haptics. We could not draw conclusion whether the presence of these cervixes contributed to the higher incidence of striae in this group or

Table 5: Number of striae and posterior capsular opacification in two groups

Number of striae	PCO in hydrophilic group	PCO in hydrophobic group	P
Single	0	0	-
Two	2	0	0.63
Three and more	21	2	0.02

PCO: Posterior capsular opacification

Table 6: Evaluation of posterior capsular opacification score in two groups

Parameter	Hydrophilic group	Hydrophobic group	P
EPCO score	0.6	0.1	0.04

EPCO: Evaluation of posterior capsular opacification




Figure 4: Persistent striae in hydrophobic intraocular lens 3-years of follow-up

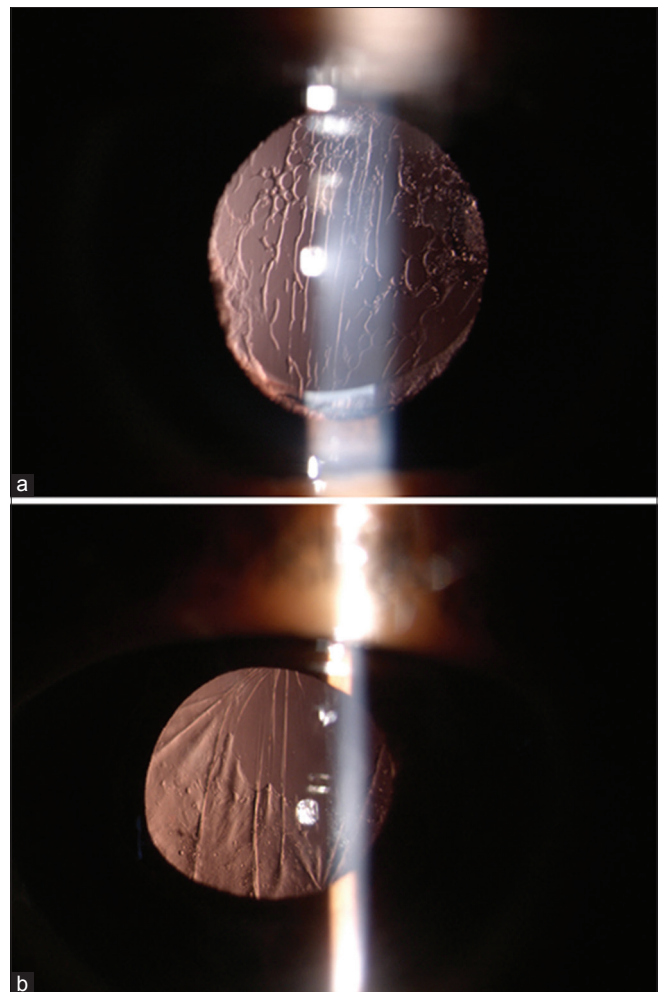


Figure 5: (a) Multiple striae with posterior capsular opacification in hydrophilic intraocular lens. (b) Multiple striae with posterior capsular opacification in hydrophilic intraocular lens

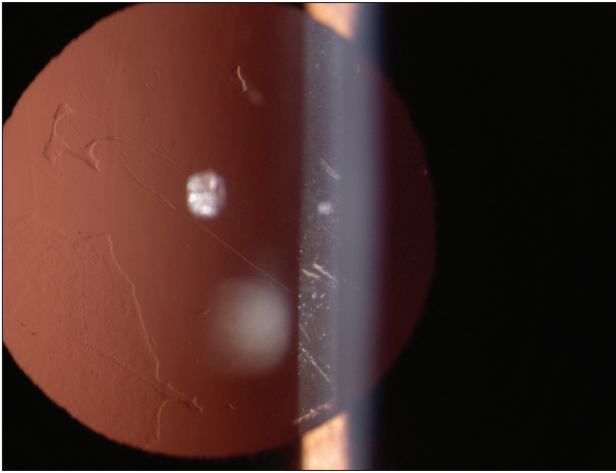


Figure 6: Multiple striae with posterior capsular opacification in hydrophobic intraocular lens

not due to the unavailability of posterior video-photographic technique in our setup. Hydrophobic IOL haptics are C-loupe malleable and configured to the size of the bag, which causes less distortion of the bag. This also could be the reason for development of number of striae in the hydrophilic group, which were more than that in the hydrophobic group. Of all, 119 eyes (18.6%) in the hydrophilic group developed three and more striae as compared to the hydrophobic group with only four eyes (0.66%) developing multiple striae. Shah *et al.* had reported about 36.7% incidence rate of multiple striae after the implantation of single-piece IOL.^[5] IOL material does play an important role in the development of PCS. Hydrophilic acrylic material causes distortion of capsular bag more than the hydrophobic acrylic biomaterial, thus increasing the number of striae formation in a hydrophilic group.^[7] Bio-adhesive (tackiness) nature of hydrophobic lens should also be considered in the development of PCS. Studies have shown that due to tackiness of acrylate material to posterior capsule the incidence of PCO is less.^[18,19]

This could be another reason for the less PCS in hydrophobic material than the hydrophilic lenses.

Striae have a variable course of disappearance. To our experience, we have noted the disappearance of the intraoperative striae after the formation of the anterior chamber and its reappearance with the shallow anterior chamber [Video 1]. Single stria in a hydrophilic group disappeared within 90 days, while two eyes in the hydrophobic group recorded persistent stria even after 3 years of follow-up. Shah *et al.* showed persistent striae in patients implanted with hydrophobic IOL within the follow-up period of 3 years.^[5] The persistence of striae after such a long period could be due to the failure of haptics to configure the shape of the capsular bag and fix the haptics with the contraction of capsular bag. However, no PCO was noted in the eyes. Some authors showed development of linear PCO in patients having persistent striae after the implantation of hydrophobic IOL.^[1] Persistent capsule striae create a gap between the lens edge and the capsule interface providing a channel for epithelial cell migration, which allows the cells to migrate centrally beyond the block of the square optic edge by forming linear PCO.^[1]

There was no significant difference in the visual acuity at the baseline or within the 3 years of postoperative phase between the two groups. This correlates with the study by Shah *et al.* on the development of PCO in hydrophobic with persistent striae with follow-up of 3 years.^[5,7]

EPCO score in hydrophilic group was 0.6 as against the hydrophobic group, which was with 0.1 score in our study. None of the patients with single stria in both the groups and two striae in hydrophobic group had PCO. However, significant number of eyes having three or more striae in hydrophilic group and only two eyes in the hydrophobic group having multiple striae had PCO ($P = 0.02$). Early development of PCO (12–18 months) in the hydrophilic group could be due to the creation of channel by striae for equatorial epithelial cell migration to the central optical zone. Ten eyes in the hydrophilic group, and none from hydrophobic group, required ND: YAG laser capsulotomy. Hydrophobic lens material has lower PCO and ND: YAG laser treatment rate than the hydrophilic lens.^[20-23] Hydrophilic lens used in this study had 360° square edge, which has been reported to prevent PCO.^[13] The only remaining factor of this study is the incidence of multiple striae, leading to the PCO development. However, lens material was a confounding factor in the study. Occurrence of multiple striae could be one of the factors for the early development of PCO. We could not compare the PCO rate in the hydrophilic group due to the multiple striae incidence as there were no peer-reviewed studies available in the literature.

The present study was carried out in a rural setup. Cost factor was a limiting factor to have an equal number of patients in two groups. 641 (51.4%) patients had hydrophilic IOL implantation as against 606 (48.6%) who had hydrophobic IOL. Though number of eyes developing striae in hydrophilic group ($n = 201$) was more than hydrophobic group ($n = 46$), the difference between two groups was 35 eyes only.

The importance of studying PCS in hydrophilic IOL lies in the fact that nowadays multifocal and toric lenses are available on the hydrophilic platform. As our study was limited to the monofocal implantation, it is difficult to comment on whether the appearance of multiple striae in the central visual axis in patients implanted with multifocal or toric lenses causes blurring of vision or not. However, occurrence of early PCO in the toric lens patients should be kept in mind.

Conclusion

The incidence of posterior capsule striae was higher in hydrophilic than hydrophobic IOL. Intraoperative deepening of anterior chamber causes disappearance, and the shallowing of the chamber results in reappearance of striae. This could be a good indication of proper wound closure. Eyes with persistent multiple striae even after 6 months should be followed up closely for the detection of PCO development, particularly with hydrophilic IOL.

Financial support and sponsorship

Nil.

Conflicts of interest

There are no conflicts of interest.

References

1. Wolken MA, Oetting TA. Linear posterior capsule opacification with the AcrySof intraocular lens. *J Cataract Refract Surg* 2001;27:1889-91.
2. Vasavada AR, Trivedi RH. Posterior capsule striae. *J Cataract Refract Surg* 1999;25:1527-31.
3. Pandey SK, Werner L, Wilson ME Jr., Izak AM, Apple DJ. Capsulorhexis ovaling and capsular bag stretch after rigid and foldable intraocular lens implantation: Experimental study in pediatric human eyes. *J Cataract Refract Surg* 2004;30:2183-91.
4. Izak AM, Werner L, Pandey SK, Apple DJ. Pathological evaluation of postmortem human eyes implanted with a new single-piece hydrophobic acrylic lens. *J Cataract Refract Surg* 2004;30:1537-44.
5. Shah GD, Vasavada AR, Praveen MR, Shah AR, Trivedi RH. Incidence and influence of posterior capsular striae on the development of posterior capsule opacification after 1-piece hydrophobic acrylic intraocular lens implantation. *J Cataract Refract Surg* 2012;38:202-7.
6. Kugelberg M, Wejde G, Jayaram H, Zetterström C. Two-year follow-up of posterior capsule opacification after implantation of a hydrophilic or hydrophobic acrylic intraocular lens. *Acta Ophthalmol* 2008;86:533-6.
7. Vasavada AR, Raj SM, Shah A, Shah G, Vasavada V, Vasavada V. Comparison of posterior capsule opacification with hydrophobic acrylic and hydrophilic acrylic intraocular lenses. *J Cataract Refract Surg* 2011;37:1050-9.
8. Iwase T, Nishi Y, Oveson BC, Jo YJ. Hydrophobic versus double-square-edged hydrophilic foldable acrylic intraocular lens: Effect on posterior capsule opacification. *Semin Ophthalmol* 2012;27:15-8.
9. Saeed MU, Jafree AJ, Saeed MS, Zia R, Sheikh IM, Heravi M. Intraocular lens and capsule opacification with hydrophilic and hydrophobic acrylic materials. *Acta Ophthalmol* 2014;92:179-83.
10. Cullin F, Busch T, Lundström M. Economic considerations related to choice of intraocular lens (IOL) and posterior capsule opacification frequency – A comparison of three different IOLs. *Int J Ophthalmol* 2015;8:118-21.
11. Duman R, Karel F, Özyol P, Ateş C. Effect of four different intraocular lenses on posterior capsule opacification. *J Cataract Refract Surg* 2011;37:1060-8.
12. Schriefel SM, Menapace R, Stifter E, Zaruba D, Leydolt C. Posterior capsule opacification and neodymium: YAG laser capsulotomy rates with 2 microincision intraocular lenses: Four-year results. *J Cataract Refract Surg* 2015;41:956-63.
13. Bai L, Zhang J, Chen L, Ma T, Liang HC. Comparison of posterior capsule opacification at 360-degree square edge hydrophilic and sharp edge hydrophobic acrylic intraocular lens in diabetic patients. *Int J Ophthalmol* 2015;8:725-9.
14. Joshi RS. A single drop of 0.5% proparacaine hydrochloride for uncomplicated clear corneal phacoemulsification. *Middle East Afr J Ophthalmol* 2013;20:221-4.
15. Tetz MR, Auffarth GU, Sperker M, Blum M, Völcker HE. Photographic image analysis system of posterior capsule opacification. *J Cataract Refract Surg* 1997;23:1515-20.
16. Lim SJ, Kang SJ, Kim HB, Apple DJ. Ideal size of an intraocular lens for capsular bag fixation. *J Cataract Refract Surg* 1998;24:397-402.
17. Assia EI, Apple DJ. Side-view analysis of the lens. II. Positioning of intraocular lenses. *Arch Ophthalmol* 1992;110:94-7.
18. Linnola RJ, Werner L, Pandey SK, Escobar-Gomez M, Znoiko SL, Apple DJ. Adhesion of fibronectin, vitronectin, laminin, and collagen type IV to intraocular lens materials in pseudophakic human autopsy eyes. Part 1: Histological sections. *J Cataract Refract Surg* 2000;26:1792-806.
19. Linnola RJ, Werner L, Pandey SK, Escobar-Gomez M, Znoiko SL, Apple DJ. Adhesion of fibronectin, vitronectin, laminin, and collagen type IV to intraocular lens materials in pseudophakic human autopsy eyes. Part 2: Explanted intraocular lenses. *J Cataract Refract Surg* 2000;26:1807-18.
20. Elgohary MA, Hollick EJ, Bender LE, Heatley CJ, Wren SM, Boyce J, *et al.* Hydrophobic acrylic and plate-haptic silicone intraocular lens implantation in diabetic patients: Pilot randomized clinical trial. *J Cataract Refract Surg* 2006;32:1188-95.
21. Nejima R, Miyai T, Kataoka Y, Miyata K, Honbou M, Tokunaga T, *et al.* Prospective inpatient comparison of 6.0-millimeter optic single-piece and 3-piece hydrophobic acrylic foldable intraocular lenses. *Ophthalmology* 2006;113:585-90.
22. Stein JD. Serious adverse events after cataract surgery. *Curr Opin Ophthalmol* 2012;23:219-25.
23. Fong CS, Mitchell P, Rohtchina E, Cugati S, Hong T, Wang JJ. Three-year incidence and factors associated with posterior capsule opacification after cataract surgery: The Australian Prospective Cataract Surgery and Age-related Macular Degeneration Study. *Am J Ophthalmol* 2014;157:171-9.e1.