

Idiopathic spontaneous rupture of the urinary bladder (SRUB). A case report and review of literature

Zubair Al-Qassim, Aza Mohammed, Roland England, Zeb Khan

Urology Unit, Kettering General Hospital, Northamptonshire, United Kingdom

KEY WORDS

idiopathic ▶ spontaneous ▶ rupture ▶ perforation
▶ bladder

ABSTRACT

Spontaneous rupture of the urinary bladder (SRUB) is a rare urological emergency. It is usually secondary to an underlying pathology. An idiopathic entity has not been reported in the literature.

We report a case of idiopathic SRUB in a young female presented with abdominal pain and acute renal injury in the absence of prior trauma. We have conducted a literature review to identify commonly reported etiologies. SRUB is usually secondary to an underlying pathology, but in extremely rare cases it can be idiopathic.

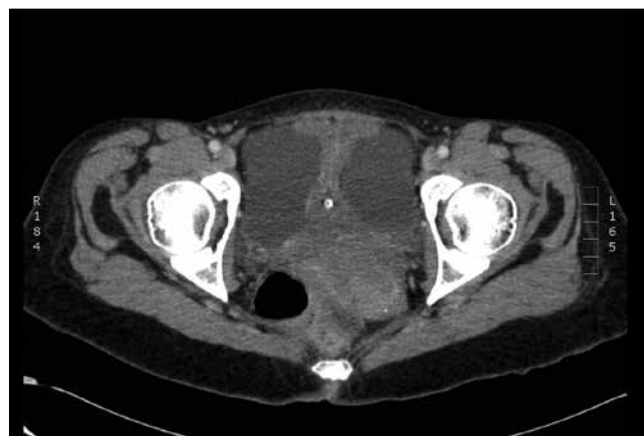

Fig. 1. CT scan of the pelvis showing free fluid around a collapsed empty bladder with the catheter tip within.

INTRODUCTION

Spontaneous rupture of the urinary bladder (SRUB) is a rare occurrence and is often the result of an underlying pathology [1]. It was not until 1929 that Sisk and Wear first coined the term SRUB. They defined the condition as: "If the bladder ruptures without external stimulation, it is spontaneous and deserves to be reported as such" [2]. The diagnosis of SRUB is a challenging endeavor. Schein et al. assert that SRUB is normally an unrecognized diagnosis and is usually discovered during laparotomy [3].

CASE REPORT

A 33-year old Caucasian female presented to the accident and emergency unit at our institute with a five-day history of anuria accompanied by abdominal pain and distention. Her past medical history was unremarkable with no particular urinary symptoms. She is a heavy smoker and drinks alcohol only in moderation. She had two uneventful Cesarean sections 12 years prior to this presentation. On examination, her abdomen was symmetrically distended with a tender suprapubic region. Her blood tests revealed a serum creatinine of 593 nmol/L, urea: 26.3 mmol/L, and eGFR of 7.5 mL/min/1.73m². Her arterial blood gas analysis revealed compensated metabolic acidosis.

The patient was catheterized with a 14F silicon catheter, which immediately drained 250 mL of bloodstained urine. A diuretic phase eventually resulted in normalization of her renal function. She had a CT scan that confirmed the presence of somewhat large amounts of free fluid in the peritoneum (Fig. 1), as well as normal kidneys and an empty bladder. The patient underwent an urgent diagnostic laparoscopy that revealed a flaccid empty bladder with a small perforation on the dome of the bladder (Figs. 2 and 3) with no other intra-abdominal pathologies. Biopsies were taken from the cut edge of the bladder and it was repaired using delayed

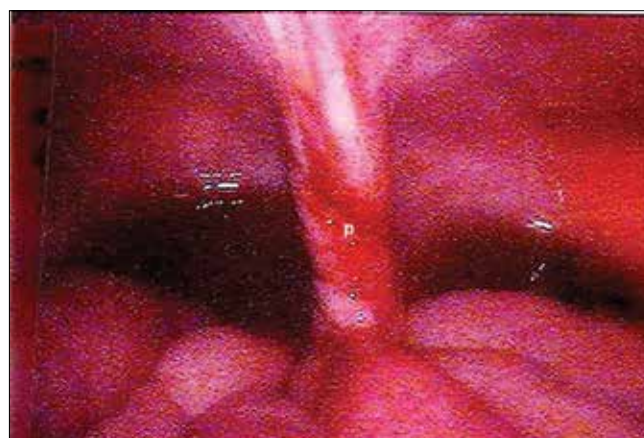

Fig. 2. Laparoscopic picture of the pelvis with free fluid behind and a small perforation (P) at the dome of the bladder.

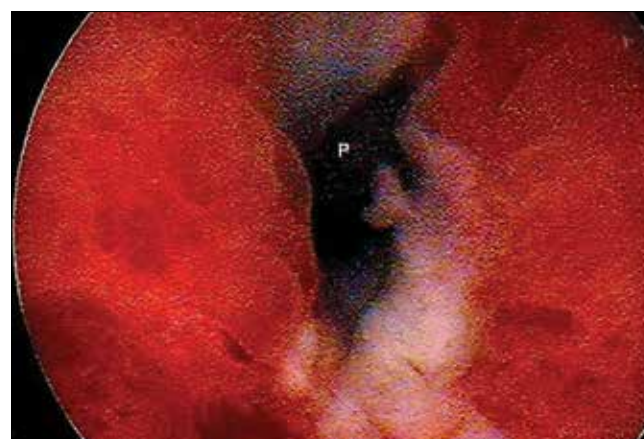

Fig. 3. Close view of the perforation (P).

absorbable Polydioxanon 2/0 suture material in two layers. A silicon urethral catheter was used for bladder drainage while the retro-pubic space was drained with a Penrose tube drain. The histology report confirmed a nonspecifically inflamed bladder wall with no evidence of malignancy.

The patient passed a trial without a catheter after a normal cystogram (Fig. 4). A subsequent MRI of the pelvis and spine ruled out pelvic or spinal cord pathology (Fig. 5). A urodynamic study was performed three months after showing an entirely stable bladder during the filling phase, and she voided to completion with a normal flow rate. A follow up cystoscopy was performed afterwards and was again normal. She remains asymptomatic.

We could not identify any clear cause of SRUB in our patient. In the absence of prior urinary symptoms and no abnormal findings upon histology, urodynamics, or imaging (including MRI), we deemed this case idiopathic SRUB.

DISCUSSION

A few commonly reported conditions associated with SRUB were found in the literature (Tab. 1). Falk and Whitman reported three cases in 1939 due to inflammatory etiology, most of which were of gonorrhoeal origin [4].

Retention of urine alone rarely predisposes the patient to SRUB, although it has been reported to happen in both sexes with different backgrounds. SRUB due to obstructed labor is a reported cause in females and could be immediate or delayed according to Torpin, who reviewed the published cases during pregnancy and labor in 1940. Eight of the reviewed cases were associated with retroverted gravid uterus at the end of the first trimester. Two other cases were immediate SRUB during labor and four others were delayed between the fourth to the tenth day postpartum [5]. McAlester reported two cases of SRUB in 1955. The first was a 51-year-old physically fit man with acute retention after hernia repair. The bladder wall was normal and there were no clear signs of bladder outflow obstruction. The second was a 66 year old male who died secondary to missed SRUB and post mortal study showed linear rupture of a thin diverticulum secondary to bladder outflow obstruction [6].

Table 1. Common reported causes of SRUB

Inflammation or infection	Gonococcal, tuberculous, schistosomias, tubo-ovarian abscess
Neurogenic bladder	Stroke, tabes dorsalis, etc.
Retention of urine	Female: retroverted uterus, obstructed labor; Male: outflow obstruction, diverticulum.
Pelvic irradiation	Previous radiotherapy of prostate or cervical cancer
Invasive tumor	Transitional or squamous cell carcinoma
Idiopathic	No clear underlying pathology

History of radiotherapy has been blamed for SRUB. Until 1986, the only case of SRUB with a background of pelvic irradiation in the English-language literature was reported by Airman and Horsburgh in 1966 [7]. In 1986, Schein et al reported a case of SRUB in a 68 year old woman who had adjuvant radiotherapy following hysterectomy for cervical cancer 24 years before presentation [3].

Another factor predisposing to SRUB is a neurogenic bladder. Wilson reported a case of SRUB due to neurogenic bladder in a patient with *Tabes Dorsalis* in 1940 [8].

Indeed invasive tumor may be seen as an underlying factor behind bladder wall weakness and eventually SRUB. However Stone (1931) and Bastable et al. (1959) in two separate reviews of over 100 cases of SRUB, concluded that perforation through a bladder tumor is rarely spontaneous [9, 10].

CONCLUSION

Although relatively rare, SRUB has been occasionally reported since the early 1900's. In the majority of cases, underlying bladder pathology has been identified, although idiopathic SRUB may occur. The diagnosis requires a high index of suspicion and must be on the differential diagnosis list when there is a similar clinical picture. Appropriate measures should be taken, including initial ultrasonography to help exclude urinary tract obstruction and

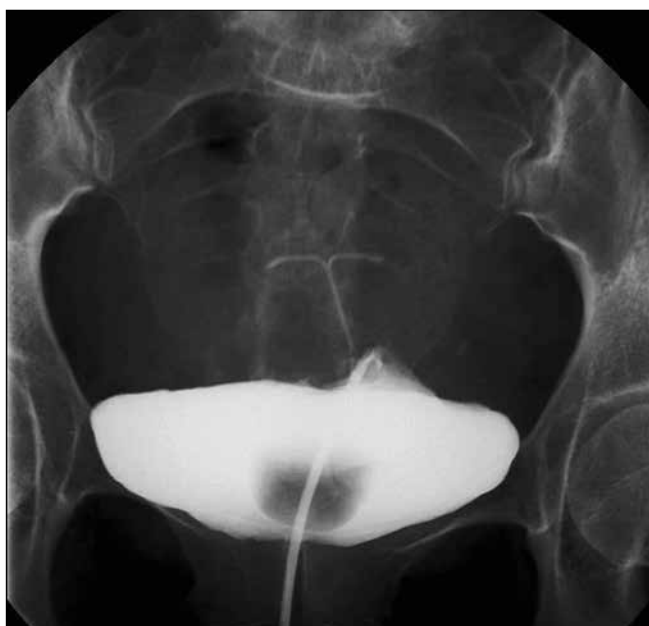

Fig. 4. Cystogram image four weeks post operation showing complete healing and no leak.

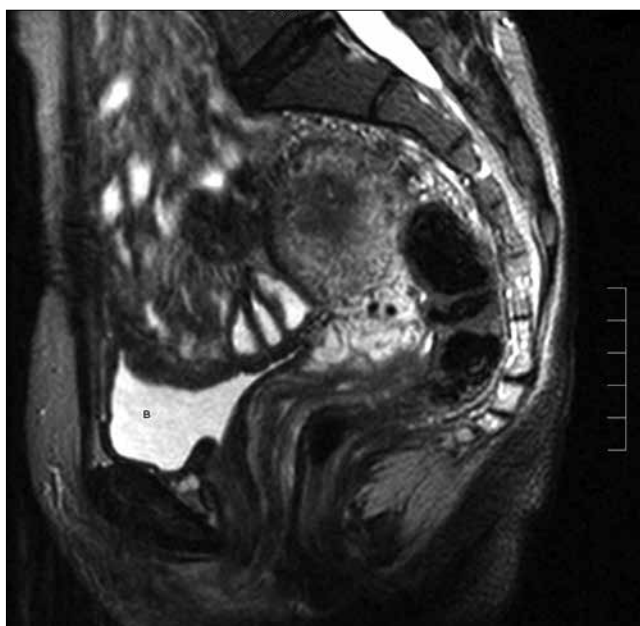


Fig. 5. MR pelvis showing normal bladder (B) and no pelvic abnormality.

identify free peritoneal fluid. A CT scan may help in the exclusion of bowel perforation or mass, but it should not delay an immediate laparoscopy/laparotomy to confirm diagnosis and begin procedures for repair in order to prevent future sequel.

REFERENCES

1. Schraur WH, Huffman J, Bagfley DH: *Acute abdominal pain caused by spontaneous perforation of the urinary bladder*. Surg Gyneco Obstet 1983; 156: 589-592.
2. Sisk IR, Wear JB: *Spontaneous rupture of the urinary bladder*. J Urol 1929; 21: 517-521.
3. Schein M, Weinstein S, Rosen A, Decker GAG: *Spontaneous rupture of the urinary bladder delayed sequel of pelvic irradiation a case report*. S Afr Med J 1986; 70: 841-842.
4. Falk HC, Hochman S: *Rupture of pelvic inflammatory masses into the urinary bladder*. Am J Obst Gynec 1939; 38: 654.
5. Torpin R: *Spontaneous rupture of the urinary bladder in labor case report literature and new Classification*. Urol Cutaneous Rev 1940; 44: 553-557.
6. Macalister CL: *Spontaneous Rupture of the Urinary Bladder*. Proc R Soc Med 1955; 48 (9): 693-697.
7. Airman B, Horsburgh AG: *Spontaneous rupture of the bladder*. Br J Urol 1966; 38: 85-88.
8. Wilson L: *Spontaneous rupture of the urinary bladder in a tabetic patient*. Med Bull Vet Admin 1940; 17: 93-95.
9. Stone E: *Spontaneous bladder rupture*. Arch Surg 1931; 23: 129.
10. Bastable JRG, De Jode LR, Warren RP: *Spontaneous rupture of the bladder*. Br J Urol 1959; 31: 78-86.

Correspondence

Zubair Al-Qassim
 Urology Offices, Warren Hill house
 Kettering General Hospital NHS
 Rothwell Road, Kettering NN16 8UZ
 Northamptonshire, United Kingdom
 phone: +44 153 649 37 86
 zubair.al-qassim@kgh.nhs.uk