

## Digital single-operator cholangioscopy with EHL as salvage therapy of an internalized and stone-impacted biliary stent 13 years after implantation

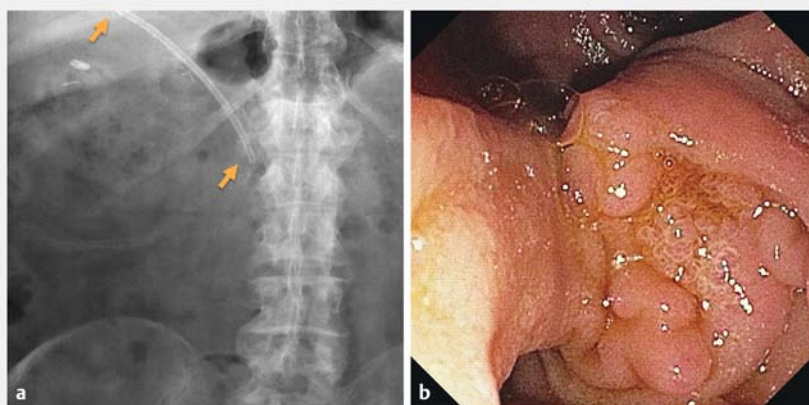


We report the case of a 72-year-old patient who presented with an inadvertently remaining CBD stent that was completely internalized and heavily impacted by biliary concretions over its entire length 13 years after implantation. Following an unsuccessful conservative

ERC salvage attempt, digital single-operator cholangioscopy (dSOC) in combination with electrohydraulic lithotripsy (EHL) was used to fragment the biliary concretions. Finally, after endoscopic papillary balloon dilatation up to 12 mm and removal of the fragmented concre-

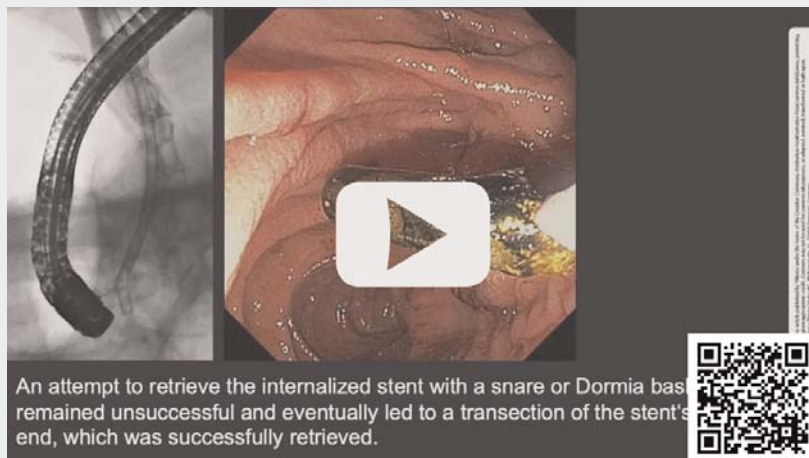
tions, the stent was successfully retrieved into the duodenum.

The development of technically advanced tools such as dSOC and dedicated instruments, including the SpyGlass Retrieval Snare and Retrieval Basket, have enabled removal of inadvertently proximally dislocated CBD stents. Our case shows that dSOC in combination with its instruments, such as EHL, is an effective and safe therapeutic option, even in special and rare cases such as this one, in which a stent was dislocated proximally and had become completely impacted by stones after 13 years.

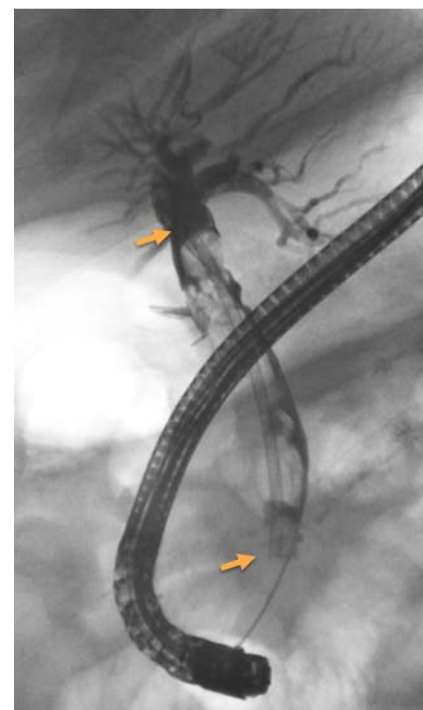


► **Fig. 1** **a** Abdominal radiography confirms the presence of a remaining CBD stent. **b** Duodenoscopy reveals a distended papilla with a complete internalization of the CBD stent.

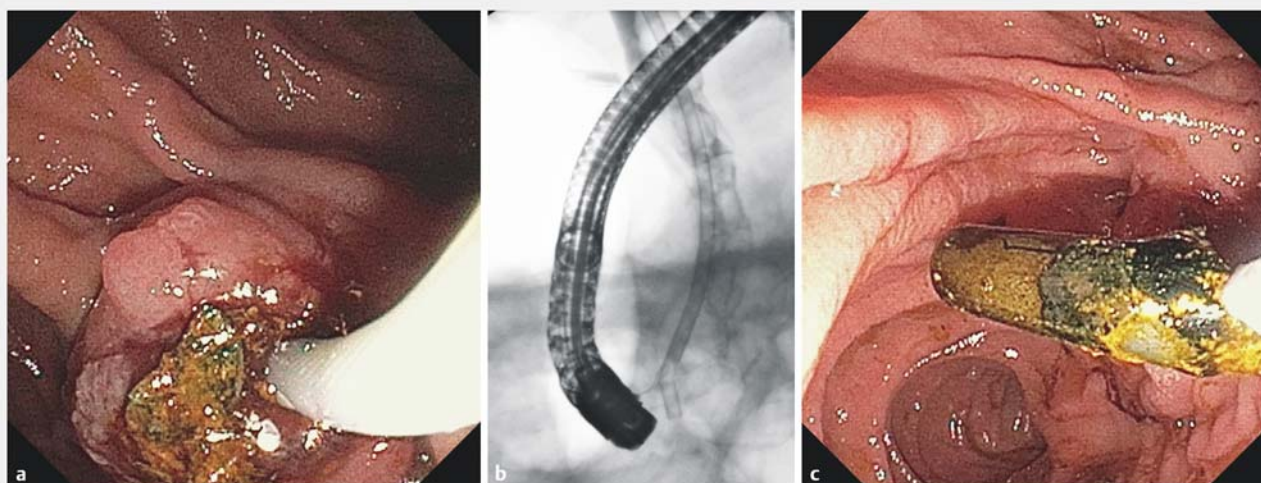
### VIDEO



► **Video 1** Digital single-operator cholangioscopy with electrohydraulic lithotripsy as salvage therapy of an internalized and stone-impacted biliary stent 13 years after implantation.



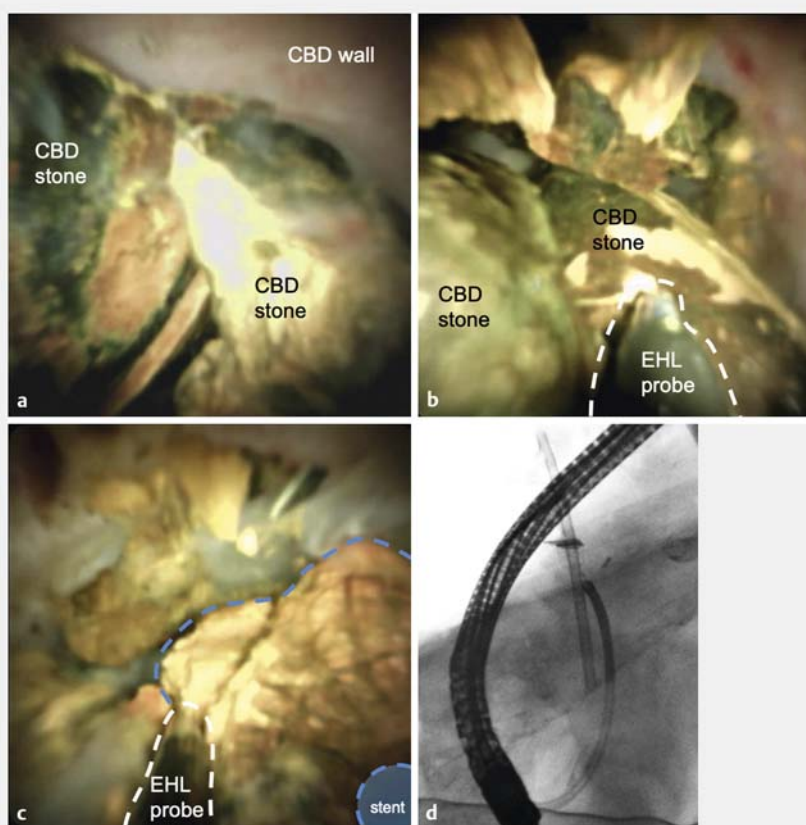
► **Fig. 2** Conventional ERC shows that the biliary stent is heavily impacted in the dilated CBD by biliary concretions over its entire length.



► **Fig. 3** **a, b** An attempt to retrieve the internalized stent with a snare or dormia basket (A and is unsuccessful and eventually leads to a transection of the stent's distal end, **c** which is successfully retrieved.

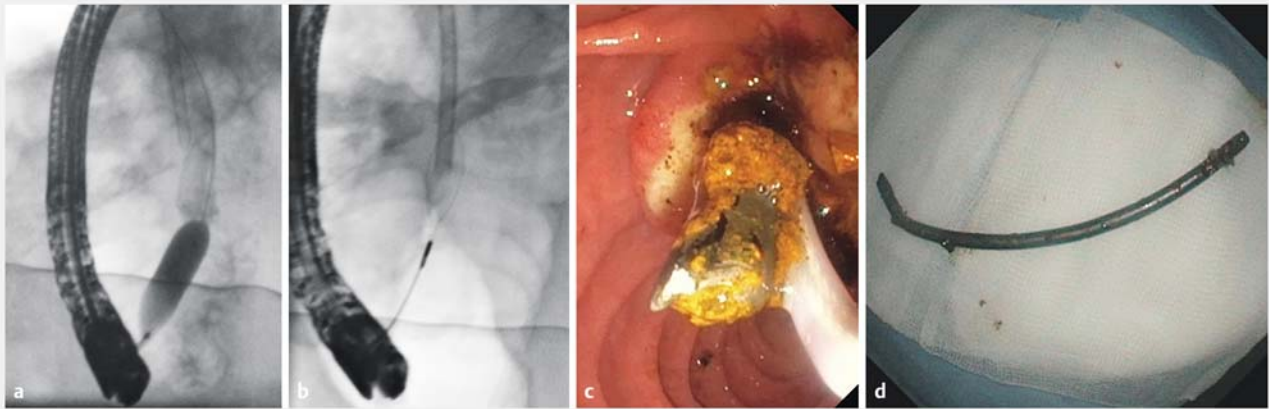
## Case presentation

A 72-year-old male patient who presented with fever and unknown focus of infection was diagnosed with a completely internalized biliary stent in the common bile duct (CBD) that was implanted for 13 years (► **Fig. 1a**, ► **Fig. 1b**, ► **Video 1**). The stent was heavily impacted by biliary concretions over its entire length (► **Fig. 2**). Smaller bile duct stones were retrieved from the distal CBD (► **Fig. 3a**). Attempts to retrieve the stent with a grasping forceps, snare, and dormia basket were unsuccessful and ended with transection of the stent at its distal end, which was successfully retrieved (► **Fig. 3b**, ► **Fig. 3c**). Digital single-operator cholangioscopy (dSOC) confirmed the impacted biliary stent (► **Fig. 4a**). The concretions were fragmented with electrohydraulic lithotripsy (EHL, ► **Fig. 4b**). In the middle segment of the CBD, the stent was completely encircled and fixated by a large concretion most likely being responsible for the unsuccessful salvage attempt in conventional ERC (► **Fig. 4c**, ► **Fig. 4d**). Following fragmentation of all larger CBD concretions and endoscopic papillary balloon dilatation to 12 mm (► **Fig. 5a**), the fragmented concretions were removed from the CBD. Finally, the stent's distal end was grasped with a snare and the stent was successfully retrieved into the duodenum (► **Fig. 5b**, ► **Fig. 5c**). To ensure bile

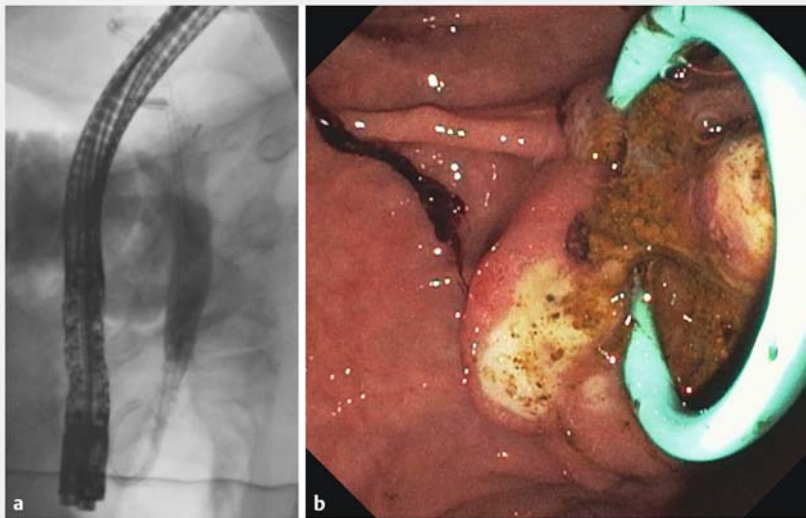


► **Fig. 4** **a** Cholangioscopy of the stent's distal end illustrates that the stent is impacted by several larger CBD stones. **b** The electrohydraulic lithotripsy (EHL) probe is applied and the biliary stones are consecutively fragmented. **c, d** In the middle segment of the CBD, a concretion that completely encircled the stent in a circular fashion is successfully fragmented.





► **Fig. 5** **a** The papilla is dilated up to 12 mm and the fragmented concretions are removed using a dormia basket. **b** The detached stent is successfully grasped with a snare and **c** retrieved into the duodenum. **d** The stent is successfully retrieved with the duodenoscope.



► **Fig. 6 a, b** A 10F/10-cm double pigtail stent is placed in the CBD to ensure bile drainage after the extended mechanical manipulation and to avoid repeated dislocation.

drainage after mechanical manipulation, a 10F/10-cm double pigtail stent was placed in the CBD (► **Fig. 6a**, ► **Fig. 6b**). Removal of proximally migrated biliary stents using cholangioscopy has been successfully performed in the past [1,2], including in complex anatomical situations such as liver transplantation [3]. The development of technically advanced tools such as dSOC and dedicated instruments including the SpyGlass Retrieval Snare and Retrieval Basket [4, 5], have enabled removal of inadvertently proximally dislocated CBD stents. Our case shows that dSOC in combination

with its instruments, such as EHL, is an effective and safe therapeutic option, even in special and rare cases, such one in which a stent was dislocated proximally and had become completely impacted by stones after 13 years. Thus, dSOC is increasingly evolving as a therapeutic salvage procedure for difficult situations in which conventional ERC would otherwise fail.

### Competing interests

The authors declare that they have no conflict of interest.

### Funding

H2020 European Research Council 771083  
Deutsche Forschungsgemeinschaft CA  
830/3-1, CRC1380/A01, LU 1360/3-1

### The authors

**Sven H. Loosen, Anselm Kunstein, Stephan vom Dahl, Johannes G. Bode, Tom Luedde, Jennis Kandler**

Clinic for Gastroenterology, Hepatology and Infectious Diseases, University Hospital Düsseldorf, Medical Faculty of Heinrich Heine University Düsseldorf, Düsseldorf, Germany

### Corresponding author

**Sven H. Loosen**

Clinic for Gastroenterology, Hepatology and Infectious Diseases, University Hospital Düsseldorf, Medical Faculty of Heinrich Heine University Düsseldorf, Moorenstraße 5, 40225 Düsseldorf, Germany  
Fax: +49 211 81 04489  
sven.loosen@med.uni-duesseldorf.de

### References

- [1] Sejpal VD, Vamadevan AS, Trindade AJ. Removal of an embedded, migrated plastic

- biliary stent with the use of cholangioscopy. *Gastrointest Endosc* 2015; 81: 1482–1483
- [2] Maselli R, Troncone E, Fugazza A et al. Endoscopic retrieval of a proximally migrated biliary plastic stent using direct per-oral cholangioscopy. *J Gastrointest Liver Dis* 2019; 28: 8
- [3] Banerjee D, Perisetti A, Raghavapuram S et al. Successful removal of proximally migrated biliary stent in a liver transplant patient by single-operator digital cholangioscopy. *ACG Case Rep J* 2018; 5: e50
- [4] Bas-Cutrina F, Garcia-Sumalla A, Velasquez J et al. Removal of a migrated biliary stent using new digital cholangioscopy retrieval devices in a transplant patient. *Endoscopy* 2019; 51: E323–E324
- [5] Fejleh MP, Thaker AM, Kim S et al. Cholangioscopy-guided retrieval basket and snare for the removal of biliary stones and retained prostheses. *VideoGIE* 2019; 4: 232–234

### Bibliography

*Endosc Int Open* 2022; 10: E269–E272

DOI 10.1055/a-1728-9526

ISSN 2364-3722

© 2022. The Author(s).

This is an open access article published by Thieme under the terms of the Creative Commons Attribution-NonDerivative-NonCommercial License, permitting copying and reproduction so long as the original work is given appropriate credit. Contents may not be used for commercial purposes, or adapted, remixed, transformed or built upon. (<https://creativecommons.org/licenses/by-nc-nd/4.0/>)

Georg Thieme Verlag KG, Rüdigerstraße 14,  
70469 Stuttgart, Germany

