

# Complete anterior–posterior minimally invasive thoracoscopic robotic-assisted and posterior tubular approach for resection of thoracic dumbbell tumor

## ABSTRACT

Thoracic dumbbell tumors are relatively uncommon neoplasms that arise from the neurogenic elements. Surgical resection can be challenging as the tumor involves both the spinal canal and thoracic cavity. Historically, thoracotomy and laminectomy were utilized for the resection of these tumors. Although single-stage removal of such tumors has been described recently, there is no prior description of a total minimally invasive single-stage resection of a thoracic dumbbell ganglioneuroma. The current report describes a completely minimally invasive surgical resection for such a tumor performed using the posterior minimally invasive tubular approach to resect the intraspinal component with ligation of the T2 nerve root in conjunction with robotic-assisted thoracoscopic resection of the extraforaminal, intrathoracic component of the tumor. This report illustrates the safety and utility of a completely minimally invasive endoscopic resection of a thoracic dumbbell tumor that can potentially obviate the morbidity associated with open surgical resections for such tumors.

**Keywords:** Dumbbell tumor, minimally invasive, robot assisted, thoracic spine

## INTRODUCTION

Thoracic dumbbell tumors are a relatively rare pathology. The differential diagnosis for such tumors includes schwannoma, neurofibroma, nerve sheath tumors, and ganglioneuroma, with schwannomas accounting for nearly 90% of all cases.<sup>[1]</sup> Ganglioneuromas in this location are generally uncommon and are considered benign tumors of neural crest origin, arising either through differentiation from neuroblastoma or as a primary entity.<sup>[2-5]</sup> These tumors are typically slow growing and present secondary to compression of nearby structures with histological characteristics of mature or immature ganglion cells, neurites, Schwann cells, and fibrous tissues.<sup>[2]</sup> Uptake of metaiodobenzylguanidine, which is seen in neuroblastomas, is lost as maturation progresses to ganglioneuromas.<sup>[2]</sup> Historically, thoracic dumbbell tumors have been categorized according to Eden's classification<sup>[6]</sup> [Table 1].

Accessibility and adequate exposure for these tumors can be challenging using standard approaches. A variety of combined

approaches have been documented to resect these tumors and often consist of thoracotomy, thoracotomy plus open posterior approach, video-assisted thoracoscopic surgery (VATS) plus open posterior approach, and open posterior approach only.<sup>[1,7,8-19]</sup> Recent technological advancements in minimally invasive and endoscopic approaches have allowed surgeons to treat complex pathologies with minimal approach-related morbidity and mortality. To date, this is the first description of a completely

**JOSHUA T WEWEL<sup>1</sup>, MANISH K KASLIWAL<sup>1,3</sup>, GARY W CHMIELEWSKI<sup>2</sup>, JOHN E O'TOOLE<sup>1</sup>**

Departments of <sup>1</sup>Neurosurgery and <sup>2</sup>Thoracic and Cardiac Surgery, Rush University Medical Center, Chicago, IL,

<sup>3</sup>Department of Neurological Surgery, University Hospitals Cleveland Medical Center, Case Western Reserve University School of Medicine, Cleveland, OH, USA

**Address for correspondence:** Dr. Manish K Kasliwal, University Hospitals Cleveland Medical Center, 11100 Euclid Avenue, Cleveland 44106, OH, USA.  
E-mail: manish.kasliwal@uhhospitals.org


**Submitted:** 15-Apr-20 **Accepted:** 02-May-20

**Published:** 05-Jun-20

This is an open access journal, and articles are distributed under the terms of the Creative Commons Attribution-NonCommercial-ShareAlike 4.0 License, which allows others to remix, tweak, and build upon the work non-commercially, as long as appropriate credit is given and the new creations are licensed under the identical terms.

**For reprints contact:** WKHLRPMedknow\_reprints@wolterskluwer.com

**How to cite this article:** Wewel JT, Kasliwal MK, Chmielewski GW, O'Toole JE. Complete anterior–posterior minimally invasive thoracoscopic robotic-assisted and posterior tubular approach for resection of thoracic dumbbell tumor. *J Craniovert Jun Spine* 2020;11:148-51.

Access this article online	
<b>Website:</b> www.jcvjs.com	<b>Quick Response Code</b> 
<b>DOI:</b> 10.4103/jcvjs.JCVJS_52_20	

minimally invasive approach for the resection of a thoracic dumbbell tumor, utilizing robotic assistance thoracoscopically with a posterior minimally invasive spinal (MIS) tubular approach.

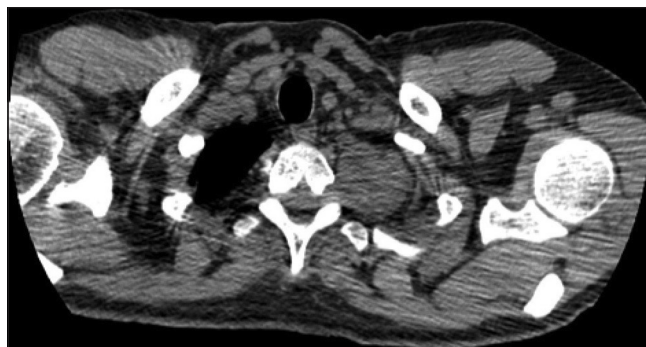
## CASE REPORT

A 58-year-old male was referred for a 1-month history of respiratory discomfort with neck discomfort, and left proximal arm and axillary anesthesia. There was no pertinent past medical history. The patient's general, pulmonary, and neurological examination was unremarkable except for the presence of mild anesthesia along the proximal left upper extremity and left axilla in the T2 dermatome. Computed tomography scan of the chest without contrast revealed a solid, soft-tissue mass along the left lung apex with bony remodeling of the T2–T3 foramen [Figure 1]. Magnetic resonance imaging (MRI) of the thoracic spine with and without gadolinium revealed a 4.9 cm × 4.2 cm avidly enhancing, dumbbell-shaped, soft-tissue mass within the left T2–T3 foramen, extending into the apex of the left hemithorax [Figure 2a and b]. Under general anesthesia, the patient was placed in the prone position. Through a paramedian incision, a 22 mm tubular retractor was docked at the left T2–T3 level. Using a microscope, a hemilaminectomy and partial facetectomy was performed. The T2 nerve root was displaced caudally and directly entered the tumor mass lateral to the spinal canal and foramen. The T2 nerve root was ligated, and the proximal portion of the tumor was resected and freed from the surrounding structures. The patient was subsequently repositioned in a right lateral decubitus position. The Da Vinci Robotic Surgical Platform (Intuitive Surgical, Sunnyvale, CA, USA) was utilized for the intrathoracic portion of the procedure. The robotic camera was introduced through an incision at the T6 intercostal space along the mid-thoracic line. Robotic port sites were placed on either side of the main port (9 cm apart) [Figure 3]. The da Vinci Si robotic platform was docked and resection was initiated. A large feeding vessel from the superior intercostal artery was ligated. The mass was resected *en bloc* using sharp and blunt dissection and monopolar cautery. A thoracostomy tube was inserted at the end of the procedure. Histopathological examination confirmed the diagnosis of a ganglioneuroma. Postoperative neurological examination was baseline with full strength and the aforementioned preoperative sensory deficits. The chest tube was removed postoperative day 1, and the patient was discharged home that day with a resumption of all regular preoperative activities by 6 weeks. A routine MRI of the thoracic spine at 6 weeks after surgery revealed no residual tumor [Figure 4].

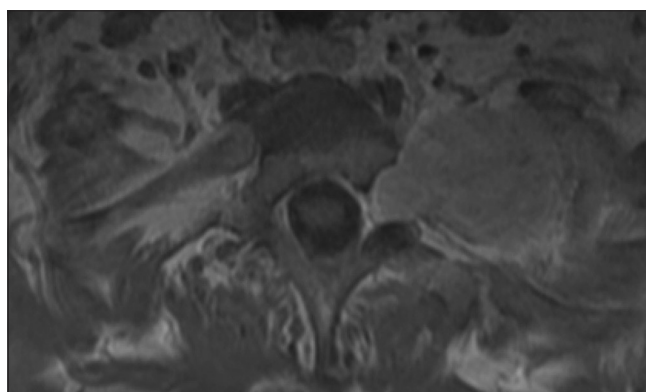
## DISCUSSION

Tumors of the posterior mediastinum are most commonly benign neurogenic tumors, with only 10% having dumbbell

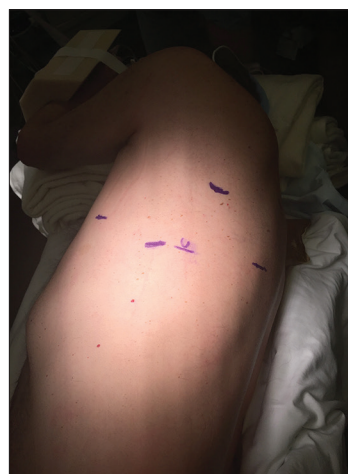morphology.<sup>[20]</sup> Dumbbell tumors are a relatively rare entity and can pose a surgical dilemma, especially when occurring in the upper thoracic spine (T1–T3). Singular approaches (posterior only, transthoracic only) often limit



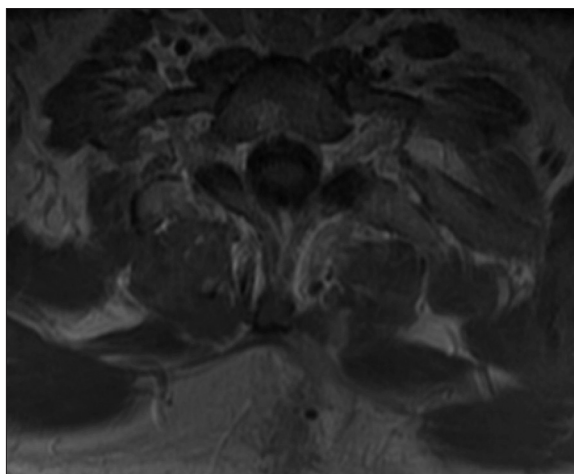
**Figure 1:** Preoperative noncontrast axial computed tomography of the chest illustrating a homogenous, soft-tissue mass along the left lung apex, abutting the spinal column with bony remodeling of the left T2–T3 foramen



**Figure 2:** Preoperative postgadolinium axial magnetic resonance imaging of the thoracic spine illustrating an avidly enhancing mass occupying the left T2–T3 foramen and extending into the perivertebral and apical thoracic spaces



**Figure 3:** Perioperative photograph is taken before the robot-assisted portion of the case. The patient is in the right side lateral decubitus position. The sixth rib is marked at the mid-axillary line. Two additional port sites are marked to the left and right. The superior marking represents the tip of the scapula



**Figure 4:** Postoperative postgadolinium axial magnetic resonance imaging showing complete tumor excision with no obvious residual tumor

#### Table 1: Eden's classification

Type I: Intra- and extradural type
Type II: Intra- and extradural and paravertebral type
Type III: Extradural and paravertebral type
Type IV: Foraminal and paravertebral type

exposure secondary to surrounding structures such as ribs, the thoracic cage, mediastinum, and vasculature. Increased morbidity may also be introduced with extended exposures that require rib separation, diaphragm takedown, and/or mobilization of the mediastinum.

Posterior alone approaches to dumbbell tumors often demand facetectomies and/or costotransversectomies with subsequent instrumented fusions and associated morbidity. In 1983, Shadmehr *et al.* were the first to describe the combined approach consisting of a posterolateral thoracotomy and concomitant laminectomy for single-stage resection of a thoracic dumbbell tumor.<sup>[18]</sup> While allowing a single-stage surgery, all posterior approaches entail a significant soft-tissue dissection and can be associated with significant pain, morbidity, and prolonged hospital stay as reported in the case series by Ando *et al.*, in which two patients sustained pleural injury and one patient suffered excessive bleeding during surgery.<sup>[7]</sup> Combined single-stage surgery has become popular recently in the removal of such tumors and can be performed either posterior spinal, followed by VATS or vice versa depending on surgeons' preference.<sup>[16]</sup>

Advances in minimally invasive surgical techniques now can be applied in the treatment of complex spinal pathologies, which were once amenable only to open surgical resection that is typically associated with significant perioperative morbidity and complications. There is no prior report of a complete anterior–posterior minimally invasive/endoscopic

resection of a thoracic dumbbell tumor. The present case demonstrates the successful use of MIS and thoracoscopic procedures to allow resection of a thoracic dumbbell ganglioneuroma with an excellent clinical outcome and minimal hospital stay. This robotic-assisted thoracoscopic surgery along with minimally invasive tubular posterior spinal approach represents a novel surgical strategy. The posterior approach was performed first to resect the tumor from within the neural foramen to prevent avulsion injury to the nerve root during the subsequent transthoracic portion. Partial resection, ligation of the T2 nerve root, and freeing of the tumor are allowed for an uneventful transthoracic resection. In addition, the hemilaminectomy and partial facetectomy did not render the spine unstable; therefore, no instrumentation of fusion of the spine was considered necessary.

As technology has improved, less invasive treatment options have become increasingly accessible for patients with complex pathology. VATS with or without posterior spinal approaches have been well documented since its advent in the early 1990s. VATS offers a less invasive means for resection than open thoracotomy and when combined with posterior approaches, favorable outcomes have been achieved.<sup>[9,13-16,18,19]</sup> The drawback to VATS is that the angle of the selected instrument is limited by the port at the level of the chest wall. With the use of a robot, the orientation of the instruments can be controlled at the distal end of the robotic arm, allowing for a dramatically increased range of motion and accessibility.

#### CONCLUSION

Thoracic dumbbell tumors are unique in that they commonly demand dual approaches for safe and successful resection. This is the first report describing an anterior–posterior completely minimally invasive robot-assisted thoracoscopic combined with a tubular posterior approach for resection of a thoracic dumbbell tumor. Careful application of minimally invasive applications can allow resection of tumors which were once considered the domain of open surgery as demonstrated in the present case.

#### Disclosure

Dr. O'Toole is a consultant for Globus Medical and receives royalties from Globus Medical and RTI Surgical and has stock ownership in Theracell. The other authors have no disclosures.

#### Declaration of patient consent

The authors certify that they have obtained all appropriate patient consent forms. In the form the patient(s) has/have

given his/her/their consent for his/her/their images and other clinical information to be reported in the journal. The patients understand that their names and initials will not be published and due efforts will be made to conceal their identity, but anonymity cannot be guaranteed.

#### Financial support and sponsorship

Nil.

#### Conflicts of interest

There are no conflicts of interest.

#### REFERENCES

- Ando K, Imagama S, Wakao N, Hirano K, Tauchi R, Muramoto A, *et al.* Single-stage removal of thoracic dumbbell tumors from a posterior approach only with costotransversectomy. *Yonsei Med J* 53:611–617, 2012
- Geoerger B, Hero B, Harms D, Grebe J, Scheidhauer K, Berthold F. Metabolic activity and clinical features of primary ganglioneuromas. *Cancer* 2001;91:1905-13.
- Mordant P, Le Pimpec-Barthes F, Riquet M. Neurogenic tumors of the mediastinum in adults. *Rev Pneumol Clin* 2010;66:81-94.
- Rha SE, Byun JY, Jung SE, Chun HJ, Lee HG, Lee JM. Neurogenic tumors in the abdomen: Tumor types and imaging characteristics. *Radiogr Rev Publ Radiol Soc N Am Inc* 2003;23:29-43.
- Skovronsky DM, Oberholtzer JC. Pathologic classification of peripheral nerve tumors. *Neurosurg Clin N Am* 2004;15:157-66.
- Eden K. The dumb-bell tumours of the spine. *Br J Surg* 1941;28:549-70.
- Ando K, Imagama S, Ito Z, Tauchi R, Muramoto A, Matsui H, *et al.* Removal of thoracic dumbbell tumors through a single-stage posterior approach: Its usefulness and limitations. *J Orthop Sci Off J Jpn Orthop Assoc* 2013;18:380-7.
- Barrenechea IJ, Fukumoto R, Lesser JB, Ewing DR, Connery CP, Perin NI, *et al.* Endoscopic resection of thoracic paravertebral and dumbbell tumors. *Neurosurgery* 2006;59:1195-201; discussion 1201-2.
- Citow JS, Macdonald RL, Ferguson MK. Combined laminectomy and thoracoscopic resection of a dumbbell neurofibroma: Technical case report. *Neurosurgery* 1999;45:1263-5; discussion 1265-6.
- DeCou JM, Schlatter MG, Mitchell DS, Abrams RS. Primary thoracoscopic gross total resection of neuroblastoma. *J Laparoendosc Adv Surg Tech A* 15:470-473, 2005
- Han PP, Dickman CA. Thoracoscopic resection of thoracic neurogenic tumors. *J Neurosurg* 2002;96:304-8.
- Kan P, Schmidt MH. Minimally invasive thoracoscopic resection of paraspinal neurogenic tumors: Technical case report. *Neurosurgery* 2008;63:ONSE54.
- Konno S, Yabuki S, Kinoshita T, Kikuchi S. Combined laminectomy and thoracoscopic resection of dumbbell-type thoracic cord tumor. *Spine* 2001;26:E130-4.
- McCormick PC: Surgical management of dumbbell and paraspinal tumors of the thoracic and lumbar spine. *Neurosurgery* 1996;38:67-74; discussion 74–5.
- Ng CS, Yim AP. Technical advances in mediastinal surgery: Videothoracoscopic approach to posterior mediastinal tumors. *Thorac Surg Clin* 2010;20:297-309.
- Ohya J, Miyoshi K, Kitagawa T, Sato Y, Maehara T, Mikami Y. Combined video-assisted thoracic surgery and posterior spinal surgery for the treatment of dumbbell tumor of the first thoracic nerve root. *Asian Spine J* 2015;9:595–9.
- Ponce FA, Killory BD, Wait SD, Theodore N, Dickman CA. Endoscopic resection of intrathoracic tumors: Experience with and long-term results for 26 patients. *J Neurosurg Spine* 2011;14:377-81.
- Shadmehr MB, Gaissert HA, Wain JC, Moncure AC, Grillo HC, Borges LF, *et al.* The surgical approach to “dumbbell tumors” of the mediastinum. *Ann Thorac Surg* 2003;76:1650-4.
- Shiraishi T, Hida S, Isayama T, Yoneda S, Kawahara K, Shirakusa T. A combined thoracoscopic and posterior-spinal approach for “dumbbell” neurofibroma minimizes the anatomical destruction of the vertebrae: Report of a case. *Surg Today* 2002;32:155-8.
- Akwari OE, Payne WS, Onofrio BM, Dines DE, Muhm JR. Dumbbell neurogenic tumors of the mediastinum. Diagnosis and management. *Mayo Clin Proc* 1978;53:353-8