

## Case report

# Clinical appearance and pathological findings of conjunctival myxoma: Case report and literature review

Kuo-Hsuan Hung<sup>a,b,c</sup>, Lung-Kun Yeh<sup>a,b,\*</sup><sup>a</sup> Department of Ophthalmology, Chang Gung Memorial Hospital, Taiwan<sup>b</sup> Chang Gung University, College of Medicine, Taiwan<sup>c</sup> Institute of Clinical Medicine, National Yang-Ming University, Taipei, Taiwan

## ARTICLE INFO

## Keywords:

Conjunctival myxoma  
Ocular neoplasia  
Conjunctival benign tumor  
Spindle and stellate-shaped cells

## ABSTRACT

**Purpose:** To describe a case with a growing erythematous conjunctival mass in the left eye, diagnosed as conjunctival myxoma.

**Observations:** A 31-year-old lady had corrected visual acuity of 6/7.5 and normal intraocular pressure in both eyes. Congested left bulbar conjunctiva with one slightly elevated nodule at nasal area was noted for one year. Excisional biopsy was performed after failed treatment with topical eye drops. Pathology showed conjunctival myxoma with spindle- and stellate-shaped cells, which was a rare ocular surface neoplasia. There was no combined systemic disease found.

**Conclusions and importance:** We described the clinical and pathological features of conjunctival myxoma. Systemic evaluation should be considered before and after surgical excision.

## 1. Introduction

Myxoma is a rare benign tumor without metastatic potential, discovered in sinuses, pharynx, heart, breast, intestines, genitourinary tract, skin, muscles, and bones. With incidence rate from less than 0.001% to 0.1%, conjunctival myxoma is an extremely rare ocular neoplasia of primitive mesenchymal origin, according to large reviews of thousand conjunctival lesions.<sup>1-3</sup> Conjunctival myxoma, usually present in older people, was first described in 1913 by Magalif, followed by limited number of case reports. Other than conjunctiva, ocular myxoma could occur in the optic nerve, orbit, eyelid, and the cornea,<sup>4-7</sup> or develop with systemic diseases such as Zollinger-Ellison syndrome and Carney complex. In literature review, patient with Zollinger-Ellison syndrome could present with pancreatic gastrinoma, inter-atrial septal thickening, and conjunctival myxoma at the same time.<sup>8</sup> Carney complex is comprised of cutaneous or cardiac myxomas with pigmented skin or ocular lesion, endocrine overactivity.<sup>4</sup>

Clinically, conjunctival myxoma is a benign ocular tumor, presenting as a slowly growing, painless, gelatinous mass.<sup>9</sup> Its appearance could be pink, white, or fleshy in colour, and cyst-like, semi-encapsulated in shape. Accordingly, conjunctival cyst is the commonest initial impression. In histology, stroma of the tumor is mainly composed of spindle-

and stellate-shaped cells, with scarce lymphocytes, macrophages, and mast cells.<sup>9</sup> Extracellular matrix of myxoma could consist of collagen, chondroitin sulfate, and hyaluronic acid.<sup>10-12</sup> Excision of tumor mass for pathological analysis is the main strategy to manage conjunctival myxoma. In this article, we are going to present clinical case of a young lady with a painless, bulbar conjunctival mass for one-year period. The final diagnosis is conjunctival myxoma without systemic involvement. Literatures of conjunctival myxoma are also reviewed in this article.

## 2. Case report

A 31-year-old lady presented at our clinic with congested left eye and concerned about a tiny nodule on the ocular surface over one year (Fig. 1). There was no remarkable personal systemic disease. Ophthalmic examination showed that the best corrected visual acuity was 6/7.5, and intraocular pressure was 13 mmHg in both eyes. Under slit-lamp examination, a 5 mm × 6.5 mm, slightly elevated, freely mobile cystic lesion was noted at nasal bulbar conjunctiva in the left eye, surrounded by engorged conjunctival vessels and subconjunctival hemorrhage. No combined systemic finding was noted during examination. Topical eye drops, including 0.025% ketotifen twice a day and 0.1% fluorometholone three times a day, were administered first to treat

\* Corresponding author. Department of Ophthalmology, Chang-Gung Memorial Hospital, Linkou, No.5, Fu-Hsing St., Kuei Shan Hsiang, Tao Yuan Hsien, Taiwan.  
E-mail address: [yehlungkun@gmail.com](mailto:yehlungkun@gmail.com) (L.-K. Yeh).

the lesion, but no improvement was observed. Because of cosmetic reason and irritation, excision of the conjunctival mass was performed three weeks later.

Before operation, well-defined elevated gelatinous lesion with congestion and subconjunctival hemorrhage was noted at nasal bulbar conjunctiva in the left eye. Conjunctival cyst was impressed first. After meticulous excisional biopsy through conjunctival incision, the specimen of conjunctival tumor was sent for pathological analysis. Gross inspection revealed two fleshy pieces of tissue, 2 × 2x1 mm and 6 × 5x1 mm in size, respectively. Under microscopic examination, well-defined nodule with spindle- and stellate-shaped cells within stroma, scarce scattered delicate vascular tissues, and surrounding mast cells were found in hematoxylin and eosin (H&E) stain (Fig. 2). Accordingly, conjunctival myxoma was diagnosed. There was no focal recurrence during short-term follow-up.

### 3. Discussion

In literature review, conjunctival myxoma generally affects older patients with mean presenting age of 47.6 years (median age of 49 years, ranging from 11 to 80 years),<sup>1,2,9</sup> which is relatively older than that in our case. However, ocular myxoma could also be presented in even younger patients in literature.<sup>13,14</sup> Although there is no gender predilection found in the results of two large case series of ocular myxoma,<sup>1,2</sup> slight female predominance with female-to-male ratio around 4 to 3 had been reported.<sup>3</sup> Since clinical presentation of conjunctival myxoma is similar to a painless, mobile, cystic lesion below conjunctiva, the commonest impression is conjunctival cyst, which would be overlooked until pathologically proved. Other than conjunctival cyst, ocular surface tumors from benign to malignant origin, such as amelanotic nevus, lymphangioma, myxoid neurofibroma, myxoid liposarcoma, and amelanotic melanoma, should be considered.<sup>3</sup>

Conjunctival myxoma tends to develop at bulbar conjunctiva, followed by limbal, fornix, and palpebral area. It is often observed at temporal rather than nasal area,<sup>13</sup> which is opposite to the presentation in our patient. Long-lasting lesion with subconjunctival hemorrhage, engorged vessels, and ocular history of refractory topical treatment or failed aspiration may suggest further intervention. Imaging studies of orbital myxoma have shown a homogeneously isodense mass on computed tomography (CT), a hypointense and bright lesion on T1- and T2-weighted MRI without contrast enhancement, respectively.<sup>14</sup> These further imaging studies are helpful for evaluation of larger and deeper periorbital lesions of unknown origin. At presentation, there was no systemic comorbidity in our patient; however, some conjunctival myxoma patients will develop systemic diseases before or during their follow-up.<sup>4,8</sup> Cardiac sonography, survey of endocrine overactivity, inspection of any skin or ocular pigmentation, and evaluation of patients' relatives would not be overemphasized. Whether conjunctival myxoma will induce later systemic involvement or it is just one sequelae of these syndromes remains to be elucidated; therefore, long-term

follow-up with systemic evaluation is required.

Different from clinical characteristics of pterygium, conjunctival myxoma tends to occur at temporal region of globe than other area,<sup>12,15</sup> implying its different manifestation. Additionally, pathological findings of conjunctival myxoma show primitive mesenchymal origin with immersed spindle- or stellate-shaped cells in the stroma, different from solar elastosis in pterygium, loss of epithelial polarity in ocular surface squamous neoplasia (OSSN), or lymphoid follicle in lymphoma. In sum, ocular surface tumor such as reactive lymphoid hyperplasia, lymphangioma, lymphoma, and lipoma should be put into differential diagnosis. With myxoid entity, myxochondroma, myxolipoma, and myxoid neurofibroma should also be considered.<sup>16</sup> However, characteristics of scarce vessel channels in conjunctival myxoma show less possibility of solid tumor of ocular surface.

According to histopathological findings in cardiac myxoma, hypersecretion of myxoid stromal contents such as hyaluronic acid by fibroblasts and myofibroblasts has ever been considered as a theory of myxoma formation.<sup>17</sup> Histological stain with alcian blue, colloidal iron, and hyaluronidase treatment for dissolving mucopolysaccharides are useful tests to confirm this property.<sup>10,11</sup> Based on cellular morphology in H&E stain, conjunctival myxoma could be identified from other tumors with melanocytes or lymphocytes. Furthermore, immunohistochemical(IHC) stain for vimentin and  $\alpha$ -smooth muscle actin ( $\alpha$ -SMA) could also be used to identify mesenchymal origin and myofibroblasts entity in conjunctival myxoma.<sup>11</sup> Stain positive for vimentin, acceptably positive for S-100 according to whether tissues from neural crest origin, negative for  $\alpha$ -SMA, SOX10 and GLUT1 are shown in conjunctival myxoma.<sup>3</sup> In our case, conjunctival myxoma could be diagnosed by its typical histological presentation with sparse cellular and vascular components in myxoid stroma.

Since conjunctival myxoma is a rare ocular surface neoplasia, pathogenesis of this tumour is not well established due to limited sample. However, mutation of *PRKARIA* gene with abnormal subsequent cAMP-dependant protein kinase A (PKA) had ever been proposed being associated with more aggressive and systemic myxoma lesion.<sup>18</sup> With immunohistochemical stain, absence of *PRKARIA* protein has strong association with cardiac myxoma or Carney complex, providing an advanced screening tool for suspected systemically involved patients.

### 4. Conclusions

We presented a young lady diagnosed as conjunctival myxoma at nasal bulbar conjunctiva, which is a rare and benign conjunctival tumor. Although excision is the main strategy to deal with conjunctival myxoma, thorough systemic evaluation for complex disease and evaluation of patient's relatives are easily overlooked and should be taken into consideration.

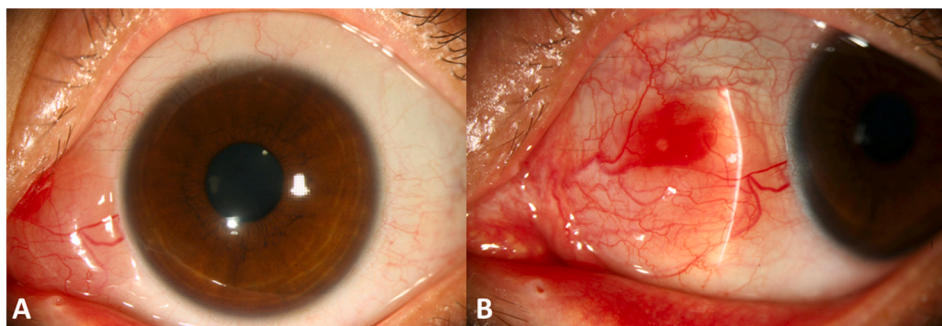
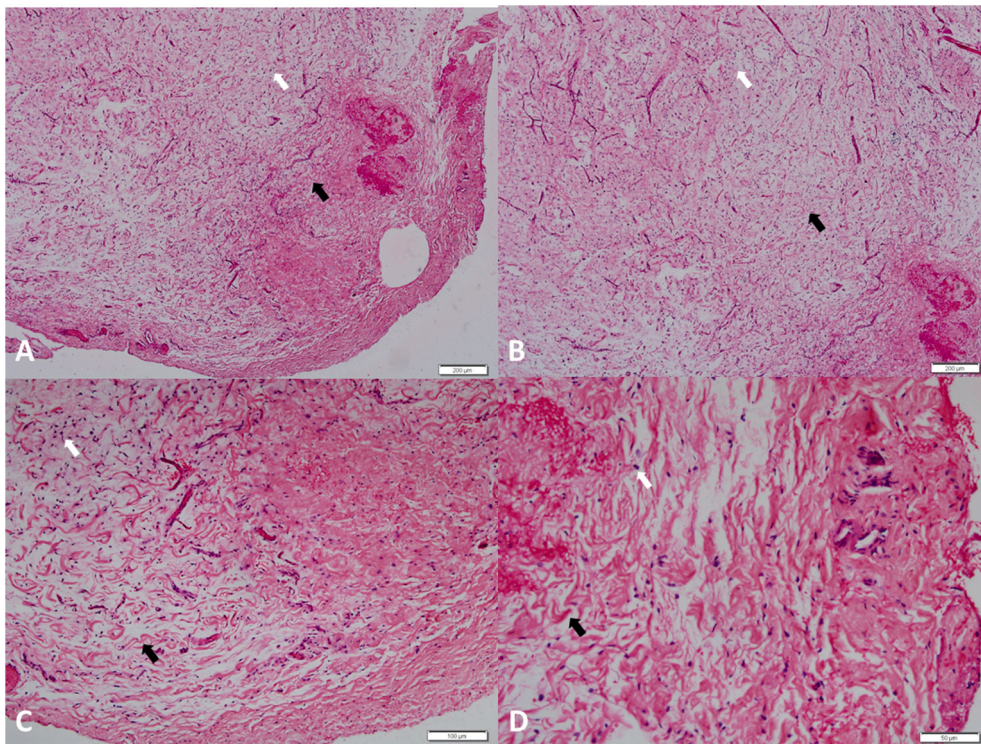


Fig. 1. Clinical picture of conjunctival myxoma over nasal conjunctiva of a 31-year-old lady. External eye photos, showing well-demarcated, fleshy, gelatinous, elevated lesion over left nasal bulbar conjunctiva (A). Congested conjunctiva with mild subconjunctival hemorrhage and engorged vessels around the lesion (B).



**Fig. 2.** Histology of conjunctival myxoma. Microscopic examination of conjunctival myxoma. Sparse spindle- and stellate-shaped cells were found in myxoid stroma. Less vascular structure was noted in the specimen (A & B; 40X, scale: 200  $\mu\text{m}$ ). Wave- or Swirl-like spindle cells mixed with stellate, round cells in acidic stroma of myxoma (C: 100X, scale: 100 $\mu\text{m}$ ; D: 200X, scale: 50 $\mu\text{m}$ ). Spindle and stellate cells were marked with black and white arrow, respectively.

#### Patient consent

Consent to publish the case report was not obtained. This report does not contain any personal information that could lead to the identification of the patient. The report was approved by The Ethics Institutional Review Board of Chang Gung Memorial Hospital (No. 201801321B0).

#### Funding

No funding or grant support

#### Authorship

All authors attest that they meet the current ICMJE criteria for Authorship.

#### Declaration of competing interest

The following authors have no financial disclosure: KHH, LKY.

#### Acknowledgements

None.

#### References

- Grossniklaus HE, Green WR, Luckenbach M, Chan CC. Conjunctival lesions in adults. A clinical and histopathologic review. *Cornea*. 1987;6(2):78–116.
- Shields CL, Demirci H, Karatza EC, Shields JA. Clinical survey of 1643 melanocytic and nonmelanocytic conjunctival tumors. *Ophthalmology*. 2004;111(9):1747–1754.
- Rios Y Valles-Valles D, Hernandez-Ayuso I, Rodriguez-Martinez HA, Medina-Cruz A, Salcedo-Casillas G, Rodriguez-Reyes AA. Primary conjunctival myxoma: case series and review of the literature. *Histopathology*. 2017;71(4):635–640.
- Kennedy RH, Flanagan JC, Eagle Jr RC, Carney JA. The Carney complex with ocular signs suggestive of cardiac myxoma. *Am J Ophthalmol*. 1991;111(6):699–702.
- Soong T, Soong V, Salvi SM, et al. Primary corneal myxoma. *Cornea*. 2008;27(10):1186–1188.
- Manjandavida FP, Chahar S, Dave B. Isolated intraosseous extra-gnathic orbital myxoma: a clinicopathologic case report. *Orbit*. 2019;38(5):401–406.
- Rodriguez-Una I, Troyano-Rivas JA, Gonzalez-Garcia C, et al. Orbital nerve sheath myxoma with extraocular muscle involvement: a rare case. *Semin Ophthalmol*. 2015;30(4):316–320.
- Ramaesh K, Wharton SB, Dhillon B. Conjunctival myxoma, Zollinger-Ellison syndrome and abnormal thickening of the inter-atrial septum: a case report and review of the literature. *Eye(Lond)*. 2001;15(Pt3):309–312.
- Xiong MJ, Dim DC. Conjunctival myxoma: a synopsis of a rare ocular tumor. *Arch Pathol Lab Med*. 2015;139(5):693–697.
- Demirci H, Shields CL, Eagle RC Jr, Shields JA. Report of a conjunctival myxoma case and review of the literature. *Arch Ophthalmol*. 2006;124(5):735–738.
- Horie Y, Ikawa S, Okamoto I, Nagata M, Tamai A. Myxoma of the conjunctiva: a case report and a review of the literature. *Jpn J Ophthalmol*. 1995;39(1):77–82.
- Patrinely JR, Green WR. Conjunctival myxoma: a clinicopathologic study of four cases and a review of the literature. *Arch Ophthalmol*. 1983;101(9):1416–1420.
- Chen CL, Tai MC, Chen JT, et al. A rare case of conjunctival myxoma and a review of the literature. *Ophthalmologica*. 2008;222(2):136–139.
- Mani NB, Shankar S, Singh P, et al. MRI findings of retrobulbar myxoma – a case report. *Clin Imaging*. 2000;24:81–83.
- Pe'er J, Hidayat AA. Myxomas of the conjunctiva. *Am J Ophthalmol*. 1986;102:80–86.
- Mackenzie DH. The myxoid tumors of somatic soft tissue. *Am J Surg Pathol*. 1981;5:443–458.
- Weiss SW, Goldblum JR. Benign soft tissue tumours and pseudotumours of uncertain type. In: *Enzinger and Weiss's Soft Tissue Tumors*. fifth ed. Philadelphia, PA: Mosby Elsevier; 2008:p1066–p1075.
- Maleszewski JJ, Larsen BT, Kip NS, et al. PRKAR1A in the development of cardiac myxoma: a study of 110 cases including isolated and syndromic tumors. *Am J Surg Pathol*. 2014;38(8):1079–1087.