

Bruise Location in Supracondylar Humerus Fractures Predicts Specific Neurovascular Injuries

Jacob D. Schultz, MD,* Andrew B. Rees, MD,* Lucas C. Wollenman, MD,*
Nathaniel Lempert, MD,†‡ Stephanie N. Moore-Lotridge, PhD,†‡§
and Jonathan G. Schoenecker, MD, PhD†‡§¶¶#**

Purpose: The presence of soft tissue injury in pediatric supracondylar humerus fractures (SCHFs) has been shown to be an independent predictor of any neurovascular injury. Potentially expanding this concept, the specific neurovascular structure injured around the elbow is thought to be dependent upon the direction and magnitude of fracture displacement and subsequent soft tissue injury. Therefore, it was hypothesized that the bruise location following SCHF is indicative of the anatomic location of maximal soft tissue injury and therefore is a specific prognosticator of which neurovascular structure may be injured. **Methods:** Retrospective chart review of all SCHFs treated at a tertiary pediatric hospital from 2007 to 2017 collected information on bruise location, neurovascular injury patterns, and outcomes. Bruise location was classified as anterior, anterolateral, anteromedial, or posterior. Injury radiographs were reviewed by a

blinded pediatric orthopaedic surgeon to neurovascular structure injured.

Results: Of 2845 SCHFs identified, 267 (9.4%) had concomitant neurovascular injury—of which 128 (47.9%) met inclusion criteria. Among the vascular injuries, all bruising was anteromedial (28/45, 62.2%, $P < 0.05$) or anterior (17/45, 37.8%, $P > 0.05$). Fractures with anteromedial bruising correlated with median nerve injury (24/27, 88.9%, $P < 0.05$), whereas fractures with anterolateral bruising correlated with radial nerve injuries (24/25, 96.0%, $P < 0.05$). Bruising or radiographic evaluation correctly identified 60.2% and 64.1% of neurovascular injuries, respectively, whereas the combination identified 82.0% of neurovascular injuries correctly. Bruise location identified 23 neurovascular injuries not predicted by radiographic evaluation alone.

Conclusion: Bruise location is an important physical examination finding that can be used as an adjunct to improve the diagnostic accuracy of neurovascular injury in SCHFs in conjunction with neurovascular physical examination and radiographic evaluation. SCHFs with anterior or anteromedial bruising should raise concern for vascular injury. In addition, anteromedial bruising is predictive of a median nerve injury and anterolateral bruising is predictive of radial nerve injury. This adjunct diagnostic is particularly helpful in a noncooperative child or if performed by a clinician with limited experience in diagnosing neurovascular injuries or interpreting pediatric elbow radiographs.

Level of Evidence: Level IV, case series.

Key Words: pediatric elbow, bruising, supracondylar humerus fractures, neurovascular injury, nerve injury, radiographic evaluation, vascular injury

(*J Pediatr Orthop* 2022;42:e250–e256)

From the *School of Medicine; ¶Department of Pharmacology, Vanderbilt University; †Division of Pediatric Orthopaedics, Monroe Carell Jr. Children's Hospital at Vanderbilt, Nashville, TN; Departments of ‡Orthopaedics; ¶Pediatrics; #Pathology, Microbiology, and Immunology; **Medicine; and §Center for Bone Biology, Vanderbilt University Medical Center, Nashville, TN.

This study was supported by the Caitlin Lovejoy Fund, the Vanderbilt University Medical Center Department of Orthopaedics, and the Vanderbilt School of Medicine Research Immersion program. Creation of the retrospective database utilized in this study was supported by CTSA award No. UL1 TR002243 from the National Center for Advancing Translational Sciences. Its contents are solely the responsibility of the authors and do not necessarily represent official views of the National Center for Advancing Translational Sciences or the National Institutes of Health.

J.G.S. receives research funding from OrthoPediatrics, served as a board member of Pediatric Society of North America (POSNA) and research support from IONIS Pharmaceuticals. The remaining authors declare no conflicts of interest.

Reprints: Jonathan G. Schoenecker, MD, PhD, Department of Pediatric Orthopaedics, Monroe Carell Jr. Children's Hospital at Vanderbilt, 2200 Children's Way, Nashville, TN 37232. E-mail: jon.schoenecker@vumc.org.

Supplemental Digital Content is available for this article. Direct URL citations appear in the printed text and are provided in the HTML and PDF versions of this article on the journal's website, www.pedorthopaedics.com.

Copyright © 2021 The Author(s). Published by Wolters Kluwer Health, Inc. This is an open access article distributed under the terms of the Creative Commons Attribution-Non Commercial-No Derivatives License 4.0 (CCBY-NC-ND), where it is permissible to download and share the work provided it is properly cited. The work cannot be changed in any way or used commercially without permission from the journal.

DOI: 10.1097/BPO.0000000000002027

unattainable.¹⁷ Additionally, radiographs are limited in their ability to predict neurovascular injury as the distal fracture fragment often settles in a position that does not indicate the maximum magnitude or direction of displacement at the instant of injury. Thus, adjunct physical examination findings that require minimal provider experience or patient cooperation are required to triage SCHFs regarding neurovascular injury.

Damage to soft tissues including neurovascular structures occurs via disruption of the protective layer of periosteum caused by displacement of the distal fracture fragment.^{6,18,19} As such, soft tissue injury, such as bruising, often occurs in an anatomic location opposite the direction of distal fragment displacement. Previous work has determined that the presence (vs. absence) of soft tissue injury in SCHFs predicts any neurovascular injury.²⁰ Expanding on this concept and finding, it is hypothesized that the anatomic location of bruising indicates the anatomic location of the maximal soft tissue injury and therefore prognosticates which neurovascular structure may be injured. While this concept has been suggested,⁶ no study exists to date that correlates the bruise location with a specific nerve or vascular injury.

In the initial test of this hypothesis, we set out to determine if the bruise location associated with a specific nerve or vascular injury in a retrospective cohort of SCHFs with either nerve or vascular injury in which the anatomic location of the bruising was recorded. In addition, we assessed the utility of bruise location in conjunction with radiographic evaluation to predict the presence of specific nerve or vascular injuries preoperatively.

METHODS

Using an institutional Research Derivative database with Institutional Review Board approval (IRB #171899), patients aged 0 to 16 treated for SCHF at a tertiary children’s hospital between November/2007 and October/2017 were identified via CPT codes and retrospectively reviewed. Data regarding injury patterns (based on classification²¹ in operative reports or nonoperative diagnosis by the senior-most treating orthopedist), radiographs, evaluation, management, and long-term outcomes were collected from the electronic medical record (EMR). All data were deidentified and managed using REDCap data collection tools.^{22,23}

Bruising patterns were recorded as described by orthopaedic house-staff or surgeon documentation. The location of the bruise was categorized as anterior, anterolateral, anteromedial, or posterior. Fractures without bruising present or bruising location documented were excluded.

Patients with preoperative neurovascular injuries documented were identified via physician diagnosis and documented physical examination. Neuropraxias were categorized as ulnar, radial, or median nerve injuries. These were verified at presentation and each subsequent follow-up appointment for validity. Sensory-only nerve injuries were excluded as they were transient and typically nonspecific to a nerve distribution. Patients with floating elbow type fractures were excluded due to the possible

confounding of neurovascular injury caused by a distal fracture. Vascular injuries were included if there was documentation of either non-palpable pulses or decreased doppler signal on vascular examination preoperatively.

Radiographs from the time of injury were collected and blinded for review by a pediatric orthopaedic surgeon (N.L.). The reviewer was asked to predict the neurovascular structure injured using imaging alone, from the following options: median nerve/vascular injury, radial nerve injury, ulnar nerve injury, and indeterminate. Results were used to determine the capacity of radiographic evaluation to predict specific neurovascular injury in an idealized population of known neurovascular injuries. For this radiographic review, median nerve and vascular injury were pooled as they are found in similar anatomic locations. Fractures without standard anteroposterior and lateral injury radiographs were excluded.

To evaluate correlations between bruise location and neurovascular injuries, a series of contingency tables were constructed with a single neurovascular injury and bruising pattern versus all others (ie, anteromedial bruising vs. all other bruising patterns by median nerve injury vs. all other neurovascular injuries). Pearson χ^2 tests were used to calculate a χ^2 value for each contingency table, which were then used to calculate the ϕ coefficient for categorical correlation. ϕ coefficients were interpreted according to Akoglu.²⁴ Specificity calculations were also performed. All statistical calculations and figures were generated with GraphPad Prism version 8.0.0 (<http://www.graphpad.com>).

RESULTS

In total, 2845 SCHFs were identified. Of these, 267 (9.4%) patients had a concomitant neurovascular injury (Fig. 1), including 140 patients (4.9%) with nerve injuries, 48 (1.7%) with combined nerve and vascular injuries, and 38 (1.3%) with isolated vascular injuries (Fig. 2). A total of 39 patients were excluded from subsequent analysis for

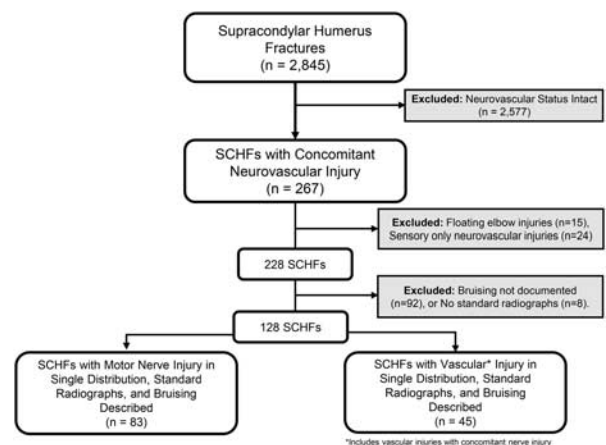


FIGURE 1. Inclusion criteria. All supracondylar humerus fractures during the study period were identified. Fractures were excluded as depicted. Fractures with concomitant nerve and vascular injury (N = 28) were included in the vascular injury cohort. SCHF indicates supracondylar humerus fractures.

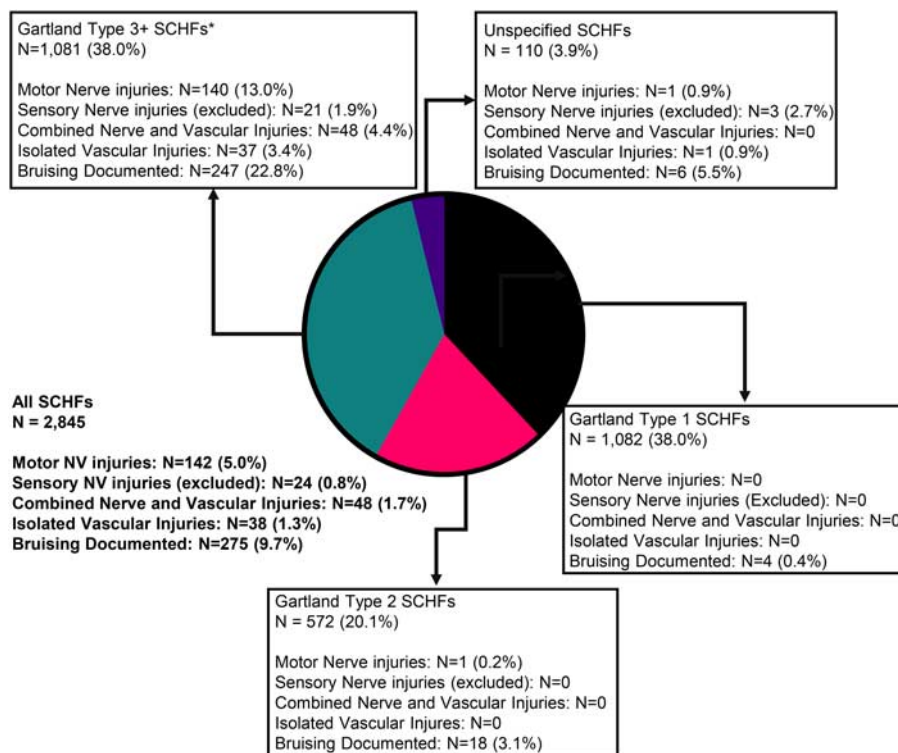


FIGURE 2. Neurovascular injury and bruising by fracture type: fractures were sorted into categories by fracture type including Gartland type 1, Gartland type 2, Gartland type 3+ (*included all Gartland type 3 fractures including Wilkins modification of the Gartland Classification type 3a posteromedial and 3b posterolateral, flexion type, Gartland type 4, T-type supracondylar, and metadiaphyseal junction supracondylar fractures) and unspecified supracondylar humerus fractures (SCHFs) based on either the operative report (for operative fractures) or diagnosis by the senior-most pediatric orthopaedist who treated the fracture (non-operative). The percentage of each category that had concurrent neurovascular injury and bruising documented are displayed. There was a large increase in the proportion of fractures with both concurrent neurovascular injury and documented bruising as severity of the fracture increased. Data reflects cohort after exclusion of floating elbow fractures (N = 15).

experiencing sensory-only neurovascular injuries (N = 24) or floating elbow injuries (N = 15), resulting in a cohort of 228 patients (Fig. 1).

To determine the utility of bruise location and radiographic evaluation to predict the presence of specific nerve or vascular injuries pre-operatively, all patients necessitated both standard radiographs and bruising documentation at admission. Across all SCHFs (N = 2845), bruising was documented in only 9.7% of cases. However, when considering fracture severity, the incidence of bruising documentation was markedly greater (22.8%) in patients with Gartland type 3+ SCHFs, mirroring the increased incidence of neurovascular injuries (Fig. 2, Supplemental Table 1, Supplemental Digital Content 1, <http://links.lww.com/BPO/A443>). Of the 228 patients with concomitant neurovascular injury, 128 (56.1%) had radiographic images *and* bruising location documented. This final study cohort included 83 (64.8%) isolated nerve injuries and 45 (35.2%) vascular injuries with (N = 28) or without (N = 17) concurrent nerve injuries (Fig. 3).

Among the vascular injuries, 17 (37.8%) had anterior bruising and 28 (62.2%) had anteromedial bruising. No patients with vascular injury had documented anterolateral or posterior bruising. Thus, in fractures with known

neurovascular injury, anteromedial bruising had a very strong positive association with vascular injury ($\phi > 0.25$, Fig. 3) and anterolateral bruising had a very strong negative association with vascular injury ($\phi > 0.25$, Fig. 3). The specificities for anterior and anteromedial bruising for vascular injury among all supracondylar fractures with neurovascular injury were 0.663 and 0.675, respectively. All 28 fractures with combined nerve and vascular injuries involved median nerve injury.

Of the 83 patients with isolated nerve injuries, 27 (32.5%) had anteromedial bruising, 28 (33.7%) had anterior bruising, 25 (30.1%) had anterolateral bruising, and 3 (3.6%) had posterior bruising. Of patients with anteromedial bruising, 88.9% (24/27) had median nerve injury, 0.0% had radial nerve injury, and 11.1% (3/27) had ulnar nerve injury. Thus, in fractures with known nerve injury, anteromedial bruising had a very strong positive association with median nerve injury and a very strong negative association with radial nerve injury ($\phi > 0.25$, Fig. 4). The specificity of anteromedial bruising for median nerve injury among all SCHFs with nerve injuries was 0.939.

Of the fractures with nerve injury and anterior bruising, 32.1% (9/28) of patients had median nerve injury, 64.3% (18/28) had radial nerve injury, and 3.6% (1/28) had ulnar

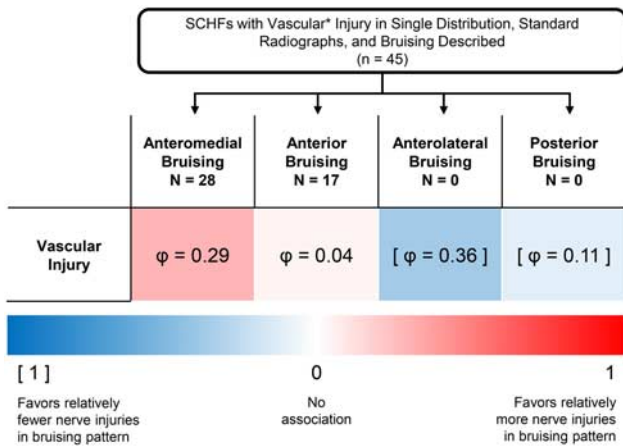


FIGURE 3. Vascular injury by bruising pattern. Each bruising pattern was tested for correlation with vascular injury (vs. any other nerve injury without vascular injury) and arranged in a contingency table. For each bruising location, a chi-square value was calculated. Using the χ^2 value, a ϕ value of categorical correlation was calculated. These were displayed based on whether they predicted a positive (red) or negative (blue) correlation. ϕ values were interpreted according to Akoglu ($\phi > 0.25$, very strong association; $0.15 < \phi < 0.25$, strong association; $0.1 < \phi < 0.15$, moderate association; $0.05 < \phi < 0.1$, weak association; and $\phi < 0.05$, no or very weak association).²⁴ *Vascular injuries with concomitant nerve injury.

nerve injury. Thus, in fractures with known nerve injury, anterior bruising had a moderate to strong association with all patterns of nerve injury (Fig. 4).

Of the fractures with nerve injury and anterolateral bruising, 4.0% (1/25) had median nerve injury, 96.0% (24/25) had radial nerve injury, and 0.0% had ulnar nerve injury. Thus, in fractures with known nerve injury, anterolateral bruising had a very strong positive association with radial nerve injury and a very strong negative association with median nerve injuries ($\phi > 0.25$, Fig. 4). The specificity of anterolateral bruising for radial nerve injury among all SCHFs with nerve injury was 0.974.

Finally, of the fractures with posterior bruising, 66.7% (2/3) had radial nerve injury and 33.3% (1/3) had ulnar nerve injury. Given the small sample size, interpreting ϕ values or specificity is difficult; however, posterior bruising did show a strong association with ulnar nerve injury (Fig. 4).

Bruising and Radiographic Diagnosis

Examining injury radiographs from the same patient cohort, a blinded reviewer was able to correctly predict which neurovascular structure was injured in 64.1% (82/128) of fractures. Comparatively, bruising location alone correctly predicted the neurovascular injury in 60.2% (77/128) of fractures (Table 1). In patients where bruising did not predict the neurovascular structure injured, radiographs correctly identified an additional 11 vascular injuries, 5 median nerve injuries, and 12 radial nerve injuries. Likewise, in patients where radiographs did not predict the neurovascular structure injured, bruising correctly identified an additional 6 vascular injuries, 8 median nerve injuries, and 9 radial nerve injuries. Thus, when

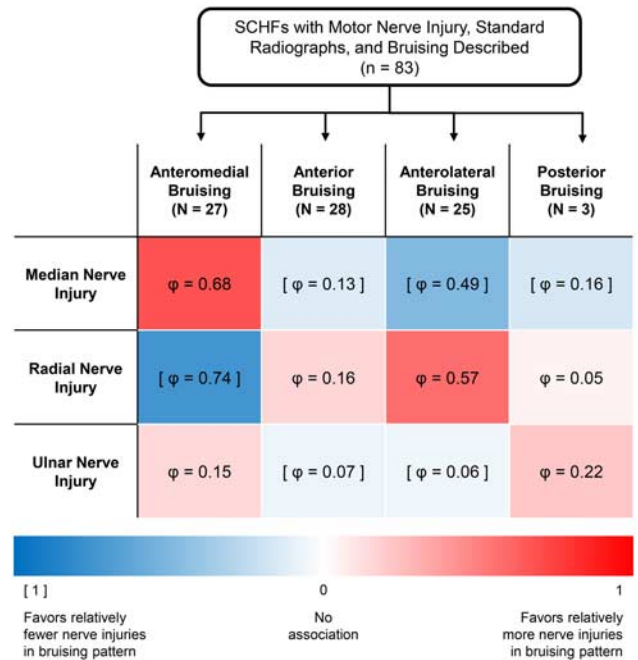


FIGURE 4. Nerve injury by bruising pattern. Each bruising pattern was paired with each category of neurological injury and arranged in a contingency table with all other bruising patterns and all other neurological injuries (ie, anterior bruising vs. all other bruising patterns and median nerve injury vs. all other neurological injuries). For each possible contingency table, a χ^2 value was calculated. Using the χ^2 value, a phi value of categorical correlation was calculated. These were displayed based on whether they predicted a positive (red) or negative (blue) correlation. ϕ values were interpreted according to Akoglu ($\phi > 0.25$, very strong association; $0.15 < \phi < 0.25$, strong association; $0.1 < \phi < 0.15$, moderate association; $0.05 < \phi < 0.1$, weak association; and $\phi < 0.05$, no or very weak association).²⁴ SCHF indicates supracondylar humerus fractures.

considering bruising or radiographs in tandem, this increased the percentage of correctly predicted neurovascular injuries to 82.0% (105/128) of fractures (Table 1).

DISCUSSION

Although SCHFs are common, they occur on a spectrum of severity with many possible sequelae, including concomitant neurovascular injury. Here, we report a 9.4% rate of neurovascular injury in all SCHFs, which is consistent with prior studies.⁷⁻⁹ In addition, 20.6% of Gartland type 3 or more severe SCHFs had concomitant neurovascular injury. Ho et al²⁰ reported that the binary presence (or absence) of soft tissue injury “is strongly associated with neurovascular compromise” and “plays a critical role in assessing the severity” of SCHFs. This study expands on these findings and illustrates the clinical utility of a simple physical examination finding, specific bruise location, in predicting which neurovascular structure may be damaged. While the findings within this

TABLE 1. Rate of Identification of Neurovascular Injury by Radiographic Evaluation, Bruise Location, and the Combination of Both

	n /N (%)				Total
	Vascular Injuries	Median Nerve Injuries	Radial Nerve Injuries	Ulnar Nerve Injuries	
Radiographic imaging alone	33/45 (73.3)	21/34 (61.8)	27/44 (61.4)	1/5 (20.0)	82/128 (64.1)
Bruising documentation alone	28/45 (62.2)	24/34 (70.6)	24/44 (54.5)	1/5 (20.0)	77/128 (60.2)
Radiographic imaging + bruising documentation	39/45 (86.7)	29/34 (85.3)	36/44 (81.8)	1/5 (20.0)	105/128 (82.0)

study may not be surprising, as many providers discuss bruise location when predicting neurovascular injury in clinical practice, currently there are no definitive studies which corroborate this clinical intuition. Thus, this study serves as both an important educational reminder and an objective measure of the utility of bruise location to predict neurovascular injuries in SCHFs. In addition, this simple adjunct diagnostic may prove clinically valuable for the less experienced clinician considering if a patient should be emergently transferred for a displaced SCHF.

Perhaps the most catastrophic complication of SCHFs is vascular injury, which can pose an increased risk of emergent complications and necessitate additional operative interventions.^{10–12} Vascular injuries are typically diagnosed via pulse or doppler examination.²⁵ However, pulse examination may be difficult to obtain in a non-cooperative child and doppler sonography may not always

be immediately available. This study provides data regarding the strong association between certain bruise locations and vascular injuries. Specifically, all patients with a vascular injury and documented bruising had anterior (17/45) or anteromedial bruising (28/45). Furthermore, associated median nerve injury (28/45, 62.2%) and posterolateral displacement of the distal fracture fragment (33/45, 73.3%) also correlated with vascular injury. Of the 17 fractures with anterior bruising and vascular injuries, 11 had posterolateral displacement and an additional 4 experienced median nerve injury, aligning with the anatomy of the pediatric elbow (Fig. 5B). In sum, using this constellation of findings, 95.6% (43/45) of SCHFs with vascular injury were retrospectively identified. Thus, if present individually or in combination, these findings should increase suspicion for an associated vascular injury when evaluating SCHFs.

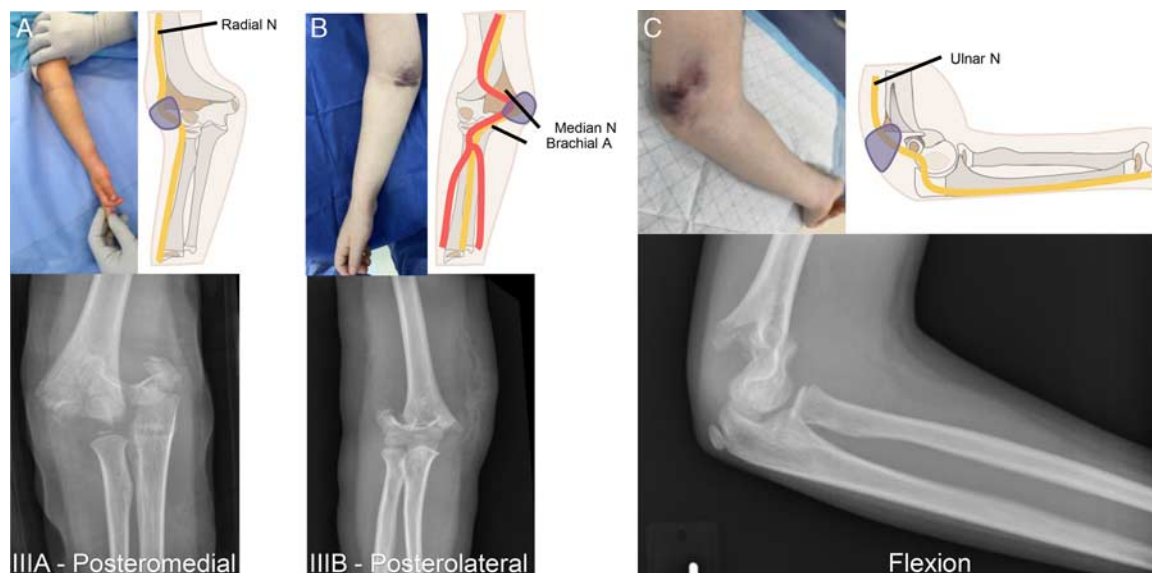

FIGURE 5. Bruising, radiographs, and neurovascular injury of SCHFs. A, A Wilkins modification of the Gartland classification type IIIA—posteromedial displacement fracture is shown on x-ray with lateral-sided bruising. An illustration showing this displacement is provided with the course of the radial nerve and bruise location (purple shadowing) provided to show proximity to the proximal humeral fracture fragment. In this study, strong association between radial nerve injury and lateral-sided bruise location was observed (N = 25). B, A Wilkins modification of the Gartland classification type IIIB—posterolateral displacement fracture is shown on x-ray with medial-sided bruising. An illustration showing this displacement is provided with the course of the median nerve, brachial artery, and bruise location (purple shadowing) provided to show proximity to the proximal humeral fracture fragment. In this study, strong association between median nerve injury and medial-sided bruise location was observed (N = 55). C, A flexion type fracture is shown on x-ray with posterior bruising. An illustration showing this displacement is provided with the course of the ulnar nerve and bruise location (purple shadowing) provided to show proximity to the proximal humeral fracture fragment. In this study, weak association between ulnar nerve injury and posterior bruise location was observed as a result of low incidence (N = 3).

In addition to vascular injuries, SCHFs with concomitant nerve injuries pose another diagnostic challenge. While full recovery is expected in most patients with primarily neurologic injury, it remains critical to correctly diagnose and follow these patients until recovery.^{13–16} Currently, a combination of directed physical examination and radiographic evaluation is used to diagnose neurapraxias in children with SCHFs. However, neurological examinations can be difficult to perform due to patient age, pain, or anxiety.^{6,17} Therefore, an easily discernible physical examination finding requiring minimal patient participation or manipulation, such as bruise location, could improve diagnostic accuracy. Although not a sensitive examination finding, this study demonstrated the utility of bruise location as a specific indicator of which neurological structure might be injured. Specifically, this retrospective study demonstrated that medialization or lateralization of bruising was indicative of the rotational displacement in posterolateral (Wilkins modification of the Gartland classification type IIIB) or posteromedial (Wilkins modification of the Gartland classification type IIIA) SCHFs, respectively (Figs. 5A, B), with strong correlations to which nerves were injured. Unfortunately, low incidence (N=3) limited the interpretation of the association between ulnar nerve injury and posterior bruising (Fig. 5C). This study provides a strong foundation for assessing the utility of bruise location as an additional indicator of specific neurological injury, but future multicenter prospective studies with standardized recording of bruising patterns are needed to further validate these results.

Finally, this study examined the use of bruising and radiographs in conjunction to evaluate nerve injury. This is particularly valuable when patients are transferred from providers unaccustomed to evaluating SCHFs. Radiographic evaluation consists of an AP and lateral image, but these static, postinjury radiographs can be unreliable in their ability to predict a nerve injury. Additional confounding factors in the radiographic examination include difficulty in positioning children with fractures due to pain²⁶ and the potential for displaced fracture fragments to return to a less displaced resting position due to periosteal and soft tissue tension.²⁷ This study highlighted the difficulty of predicting motor nerve injury via radiographic evaluation alone, with an overall correct identification rate of 59.0% (49/83). However, when radiographs were used in tandem with documented bruise location, the nerve injury was correctly identified in 79.5% (66/83) of fractures. Although never a replacement for radiographs and neurovascular examination, bruise location can be a helpful adjunct to assist clinicians in appropriately treating SCHFs.

Study Limitations

Due to the study's retrospective design, there are notable limitations. Most importantly, all data for this study was gathered from the EMR without a standardized template for the variables of interest. Therefore, we anticipate that many cases of bruising, particularly in more severe fracture types, were not documented. While across the entire database of 2845 SCHFs there were patients where bruising was documented without location, within the cohort of patients

that experience neurovascular injury, there were no patients that had binary documentation (yes/no) without a location denoted. However, many documented bruises may not be precisely documented by laterality (ie, no designation of anteromedial or anterolateral); thereby potentially reducing the true capacity for which bruise location can assist clinicians in predicting the presence of specific nerve or vascular injuries preoperatively.

In addition, this study did not evaluate all patients with SCHFs, but rather a specific subpopulation of patients with confirmed neurovascular injuries. Therefore, the ability to extrapolate these findings to any SCHF with a bruise is limited as some fractures will not have bruising, and not every bruise indicates a neurovascular injury. However, despite these limitations, bruise location in SCHFs still provided valuable data in predicting which neurovascular structure was injured in a cohort of SCHFs with neurovascular injury.

CONCLUSION

Diagnosis of neurovascular injury is vital in the management of SCHFs. This study demonstrated that the presence of anterolateral bruising, median nerve injury, or posterolateral displacement on radiographs are all associated with vascular injury, and fractures with any of these features cannot be ignored. In addition, specific anatomic location of bruising in posterolaterally or posteromedially displaced SCHFs can be a reliable indicator of median or radial nerve injury, respectively, and should be included as a valuable adjunct to radiographic evaluation and physical exam. These findings provide objective data to support the clinical intuition that the bruise *location* predicts specific neurovascular injuries in SCHFs. Future prospective studies are required to determine the specificity and sensitivity of this finding.

ACKNOWLEDGMENTS

The authors would like to thank members of the Division of Pediatric Orthopaedics for their care of patients at our institution; this work would not have been possible without their dedication. The authors would also like to thank their family and friends for their continual support and understanding.

REFERENCES

1. Cheng JCY, Ng BKW, Ying SY, et al. A 10-year study of the changes in the pattern and treatment of 6,493 fractures. *J Pediatr Orthop.* 1999;19:344–350.
2. Lyons RA, Delahunty AM, Kraus D, et al. Children's fractures: a population based study. *Inj Prev.* 1999;5:129–132.
3. Naranje SM, Erali RA, Warner WCJ, et al. Epidemiology of pediatric fractures presenting to emergency departments in the United States. *J Pediatr Orthop.* 2016;36:e45.
4. Hosseinzadeh P, DeVries CA, Nielsen E, et al. Changes in the practice of pediatric orthopaedic surgeons over the past decade: analysis of the Database of the American Board of Orthopaedic Surgery. *J Pediatr Orthop.* 2018;38:e486. doi: 10.1097/BPO.0000000000001214.
5. Tuason D, Hohl JB, Levicoff E, et al. Urban pediatric orthopaedic surgical practice audit: implications for the future of this subspecialty. *J Bone Joint Surg Am.* 2009;91:2992–2998.
6. Kasser J, Beaty J. *Supracondylar fractures of the distal humerus. Rockwood and Wilkins' Fractures in Children*, 8th ed. Lippincott Williams & Wilkins; 2015:577.

7. Babal JC, Mehlman CT, Klein G. Nerve injuries associated with pediatric supracondylar humeral fractures: a meta-analysis. *J Pediatr Orthop*. 2010;30:253–263.
8. Holt JB, Glass NA, Shah AS. Understanding the epidemiology of pediatric supracondylar humeral fractures in the United States: identifying opportunities for intervention. *J Pediatr Orthop*. 2018;38:e245–e251.
9. Omid R, Choi PD, Skaggs DL. Supracondylar humeral fractures in children. *J Bone Joint Surg Am*. 2008;90:1121–1132.
10. Choi PD, Melikian R, Skaggs DL. Risk factors for vascular repair and compartment syndrome in the pulseless supracondylar humerus fracture in children. *J Pediatr Orthop*. 2010;30:50–56.
11. Shaw BA, Kasser JR, Emans JB, et al. Management of vascular injuries in displaced supracondylar humerus fractures without arteriography. *J Orthop Trauma*. 1990;4:25–29.
12. Battaglia TC, Armstrong DG, Schwend RM. Factors affecting forearm compartment pressures in children with supracondylar fractures of the humerus. *J Pediatr Orthop*. 2002;22:431–439.
13. Gosens T, Bongers KJ. Neurovascular complications and functional outcome in displaced supracondylar fractures of the humerus in children. *Injury*. 2003;34:267–273.
14. Valencia M, Moraleda L, Diez-Sebastián J. Long-term functional results of neurological complications of pediatric humeral supracondylar fractures. *J Pediatr Orthop*. 2015;35:606–610.
15. Culp RW, Osterman AL, Davidson RS, et al. Neural injuries associated with supracondylar fractures of the humerus in children. *J Bone Joint Surg Am*. 1990;72:1211–1215.
16. Harris LR, Arkader A, Broom A, et al. Pulseless supracondylar humerus fracture with anterior interosseous nerve or median nerve injury—an absolute indication for open reduction? *J Pediatr Orthop*. 2019;39:e1.
17. Jan MMS. Neurological examination of difficult and poorly cooperative children. *J Child Neurol*. 2007;22:1209–1213.
18. Wilkins K. Fractures and dislocations of the elbow region. In: Wilkins KE, King RE, eds. *Fractures in Children*. Philadelphia, PA: Lippincott; 1984:363–575.
19. Gartland JJ. Management of supracondylar fractures of the humerus in children. *Surg Gynecol Obstet*. 1959;109:145–154.
20. Ho CA, Podeszwa DA, Riccio AI, et al. Soft tissue injury severity is associated with neurovascular injury in pediatric supracondylar humerus fractures. *J Pediatr Orthop*. 2018;38:443–449.
21. Wang SI, Kwon TY, Hwang HP, et al. Functional outcomes of Gartland III supracondylar humerus fractures with early neurovascular complications in children. *Medicine (Baltimore)*. 2017;96:25.
22. Harris PA, Taylor R, Thielke R, et al. Research electronic data capture (REDCap)—a metadata-driven methodology and workflow process for providing translational research informatics support. *J Biomed Inform*. 2009;42:377–381.
23. Harris PA, Taylor R, Minor BL, et al. The REDCap consortium: building an international community of software platform partners. *J Biomed Inform*. 2019;95:103208.
24. Akoglu H. User's guide to correlation coefficients. *Turk J Emerg Med*. 2018;18:91–93.
25. Usman R, Jamil M, Hashmi JS. Management of arterial injury in children with supracondylar fracture of the humerus and a pulseless hand. *Ann Vasc Dis*. 2017;10:402–406.
26. Zorrilla S de Neira J, Prada-Cañizares A, Marti-Ciruelos R, et al. Supracondylar humeral fractures in children: current concepts for management and prognosis. *Int Orthop*. 2015;39:2287–2296.
27. Prakash L, Jain A, Shah R, et al. Supracondylar fractures: a new classification and philosophy of management. The Gravity method. In: Prakash L, Jain AD, Shah RK, eds. *Biological Methods of Fracture Management*. Chennai, India: Indian Academy of Orthopaedic Surgeons; 2019:264–293.