



Accuracy of periocular lesion assessment using telemedicine

Swan Kang ¹, Mohammad Dehabadi,¹ Dawn A Sim,² Peter B M Thomas ², Doris Appiah Ewusi,¹ Daniel Ezra¹

To cite: Kang S, Dehabadi M, Sim DA, *et al.* Accuracy of periocular lesion assessment using telemedicine.

BMJ Health Care Inform 2021;**28**:e100287. doi:10.1136/bmjhci-2020-100287

► Additional material is published online only. To view please visit the journal online (<http://dx.doi.org/10.1136/bmjhci-2020-100287>).

Received 19 November 2020

Revised 15 December 2020

Accepted 24 December 2020

ABSTRACT

Objectives To assess the agreement in diagnosis and management plans reached between clinicians reviewing eyelid lesions remotely and in face-to-face clinics.

Methods In this single-centre observational case series, data were prospectively collected on 50 consecutive adults referred with eyelid lesions suitable to be seen by a nurse. A proforma was completed to gather salient information.

A nurse specialist saw patients in face-to-face clinics and collected information using the proforma, devising a diagnosis and management plan. Photographs of the eyelid lesions were taken by a medical photographer. A subsequent remote review was completed by an oculoplastic consultant using the proforma information and photographs in the absence of the patient. The diagnosis and management plan constructed by the nurse specialist were compared with those reached by the consultant.

Results Complete data were available for 44 consecutive cases. There was an overall 91% agreement (40 cases out of 44) between the diagnoses reached by the nurse specialist, and the remote reviewer; kappa coefficient 0.88 (95% CI 0.76 to 0.99). There was an overall 82% agreement (36 out of 44 cases) in the management plans devised by the nurse-led clinic and remote reviewer; kappa coefficient 0.74 (95% CI 0.58 to 0.90). The average time taken for a remote reviewer to reach a diagnosis and management plan was 1 min and 20 s.

Conclusions This study evaluated the feasibility of assessing eyelid lesions using asynchronous telemedicine. There was overall a high rate of concordance in the diagnosis reached, and management devised between the clinic and remote review.

INTRODUCTION

Telemedicine is the use of electronic information and communication technologies to deliver healthcare services at a distance¹ and is well established in ophthalmology, particularly in the subspecialty areas of medical retina and glaucoma.^{2–5} Prior to the COVID-19 pandemic, the reported applications of telemedicine in oculoplastics were largely limited to settings where the access to healthcare remains a challenge^{6–9} and only few studies evaluated the utility of synchronous telemedicine in assessment of oculoplastic conditions.^{10–12} Since the emergence of COVID-19, the use of telemedicine, particularly video consultations, has increased exponentially.

Summary

What is already known?

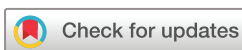- The evidence base for the use of telemedicine in oculoplastics is limited.
- Telemedicine provides benefits such as improved outcomes, efficiency and access to healthcare.

What does this paper add?

- Eyelid lesion assessment using store-and-forward telemedicine is comparable to face-to-face evaluation.
- Remote eyelid lesion assessment can be used to optimise patient care pathways.

The literature reports varying degree of effectiveness of video consultations in assessment of eyelid lesions.^{13 14} While the evidence base for the use of video consultations in oculoplastics is growing following the COVID-19 outbreak, the literature on the application of asynchronous or store-and-forward telemedicine in the assessment of eyelid lesions remains scarce.^{15 16} This contrasts significantly with the successful implementation and scaling of a closely related specialty—teledermatology, which has matured over two decades and is now a widely accepted form of service delivery.¹⁷

The hospital eye service is experiencing a severe shortage of resources to safely cope with demand and it is predicted that the demand will increase by 30%–40% over the next 20 years.¹⁸ In our oculoplastic service patients with eyelid lesions make up more than 50% of new referrals. Optimising pathways for these patients is vital to provide an efficient service and to reduce waiting times particularly when identification of malignant lesions is time sensitive. Multiple initiatives have been implemented to offer prompt diagnosis and treatment of eyelid lesions. A nurse-led eyelid lesions service has been shown to provide comparable diagnostic accuracy compared with a doctor-led service.¹⁹ One-stop minor surgery lists have been set up in order to provide patients with same



© Author(s) (or their employer(s)) 2021. Re-use permitted under CC BY-NC. No commercial re-use. See rights and permissions. Published by BMJ.

¹Adnexal Department, Moorfields Eye Hospital NHS Foundation Trust, London, UK
²NIHR Biomedical Research Centre for Ophthalmology, Moorfields Eye Hospital NHS Foundation Trust and UCL Institute of Ophthalmology, London, UK

Correspondence to

Dr Swan Kang;
swan.kang1@nhs.net

day surgery to expedite the delivery of their treatment and to reduce the need for multiple hospital visits. The National Health Service (NHS) long-term plan and NHS England service transformation plans for ophthalmology suggest remote care as a means to cope with a surge in patient demand.^{20 21} The recent pandemic along with the increasing access and use of the internet and digital technology as well as growing acceptance of remote care among clinicians and patients have accelerated the move towards telemedicine.

We investigated the use of asynchronous telemedicine to remotely diagnose and formulate management plans for eyelid lesions. To enhance the diagnostic accuracy of such an approach, templates for structured and pertinent data collection including patient history, along with photographs of eyelid lesions were designed and used. The data and photographs were reviewed by a clinician in the absence of the patient. The agreement between the diagnosis and management plan reached by clinician reviewing the data remotely with those devised by clinician reviewing patients in face-to-face clinics was assessed.

METHODS

This was a single-centre prospective observational case series conducted in a tertiary ophthalmic specialist hospital. Verbal consent was obtained from study participants.

Fifty consecutive adult patients, who were referred with benign eyelid lesions based on the information provided by the referrer, were included in the study. We excluded suspected skin cancer referrals. Data were prospectively collected on patients seen between November 2019 to January 2020 in nurse-led clinics as benign eyelid lesion cases are seen in nurse-led clinics at our institution. A bespoke structured proforma was designed to characterise the eyelid lesions and gather relevant information including history of skin lesions, ophthalmic, medical and drug history (online supplemental material). A nurse specialist saw patients in face-to-face clinics and collected information using the proforma and devised a diagnosis and management plan. Photographs of the eyelid lesions were taken at the end of the clinic appointment by a qualified medical photographer using a Canon EOS 7D camera with 5184×3456 pixels resolution. A subsequent remote review of collected data and photographs was completed by an oculoplastic consultant in the absence of the patient. All cases were assessed by the same nurse specialist and the same consultant remote reviewer. Data, including patient demographics, number of days patients waited between the date of referral and the review, time taken for the consultant to review the cases remotely and referral sources as well as histopathological diagnoses where available, were collected. The diagnosis and management plan constructed by the nurse specialist in the face-to-face clinic and those reached by the consultant via remote review were compared by an independent assessor (oculoplastic fellow).

Table 1 Diagnoses and management plans of the excluded cases

Excluded cases	Face-to-face diagnosis	Face-to-face management plan
A	Chalazion	Incision and curettage
B	Chalazion	Incision and curettage
C	Chalazion	Discharge
D	Epidermoid cyst	Follow-up
E	Epidermoid cyst	Discharge
F	Epidermoid cyst	Excision biopsy

Kappa coefficient and 95% CIs were used to evaluate the agreement between the face-to-face clinic and remote review. Pearson's χ^2 test was used compare the distribution of outcomes. Tests with p values less than 0.05 were considered statistically significant. Data analysis was performed using R software (R Core Team, 2017).

RESULTS

Complete data were available for 44 consecutive cases. Six cases were excluded from the study as these patients did not wait to have their photographs taken after the face-to-face consultations, thus not allowing remote review to take place. The details of the excluded cases are listed in [table 1](#). No case was excluded due to the insufficient photograph quality.

The mean age of patients reviewed was 47.3 years (range:18 to 72 years). Twenty-seven (61.4%) patients were female, and 17 (38.6%) patients were male. Patients waited an average of 49 days (range: 18–97) from the date of referral to be seen in the face-to-face clinic. Twenty-eight (64%) patients were referred by general practitioners while 12 (27%) were by ophthalmologists who do not specialise in oculoplastics, and 4 (9%) by optometrists. An average time taken to review a case remotely by means of assessing the collected data and photographs was measured to be 1 min 20 s (range: 20–120 s). The baseline characteristics and key metrics are summarised in [table 2](#).

Table 2 Baseline characteristics of the study participants and key metrics

Characteristics	Total no, n=44
Age—mean (SD) in years	47.3 (14.5)
Sex—female n(%)	27 (61.4)
No of days patients waited between the date of referral and the review—mean (SD) in days	49 (18.0)
Referral source n(%)	
General practitioners	28 (64)
Non-oculoplastic ophthalmologists	12 (27)
Optometrists	4 (9)

Table 3 Outcomes of face-to-face clinic and remote review

	Face-to-face outcome n (%)	Remote review outcome n (%)
Discharge	19 (43.2)	17 (38.6)
Incision and curettage	13 (29.5)	14 (31.8)
Excision biopsy	7 (15.9)	11 (25)
Follow-up	5 (11.4)	2 (4.5)

The primary diagnoses were (as per the standard outpatient care, face-to-face clinic): chalazion n=19 (43.2%), epidermoid cyst n=9 (20.5%), papilloma n=9 (20.5%), hidrocystoma n=2 (4.5%), naevus n=2 (4.5%), xanthelasma n=1 (2.3%), conjunctival granuloma n=1 (2.3%) and lipoma n=1 (2.3%). The outcomes of face-to-face clinic were discharge n=19 (43.2%), incision and curettage n=13 (29.5%), excision biopsy n=7 (15.9%) and follow-up n=5 (11.4%). The outcomes of remote review were discharge n=17 (38.6%), incision and curettage n=14 (31.8%), excision biopsy n=11 (25%) and follow-up n=2 (4.5%) (table 3). There was no statistically significant difference between the distribution of outcomes between face-to-face and remote review (p=0.21).

The full list of cases where there were disagreements of diagnosis and/or management plan between those reached by the face-to-face clinician and the remote reviewer is outlined in table 4.

There was an overall 91% agreement (40 cases out of 44) between the diagnoses made by the nurse specialist, and the remote reviewer. Kappa coefficient for diagnostic agreement between face-to-face and remote review was 0.88 (95% CI 0.76 to 0.99). Three out of the four cases with disagreements in diagnosis resulted in different management plans. In one case (case 5 of table 4; hereinafter all numerical case numbers refer to those listed in table 4), the nurse specialist diagnosed the lesion as a benign cyst and discharged the patient whereas the remote reviewer suspected a basal cell carcinoma due to the presence of central ulceration and listed for a biopsy. The lesion subsequently spontaneously resolved without

intervention indicating that the lesion was of benign origin. In two cases, the lesions (a chalazion and a lipoma, cases 3 and 9, respectively) were not demonstrated well on photographs as these were subcutaneous, the undulation caused by the lesions was subtle, and there were no overlying skin changes. The lesions in question were not the focal point in the photographs probably due to the photographer being uncertain of the location of the lesions of concern. In case 3, the remote reviewer diagnosed an enlarged caruncle, where the patient was referred with a small chalazion in the lower lid near the punctum which did not display well in the photographs. The remote reviewer listed the patient for a biopsy of the caruncle whereas the nurse booked the patient for an incision and curettage of the chalazion. In case 9, the remote reviewer noted and diagnosed a papilloma which was adjacent to the lipoma and listed for a biopsy whereas the nurse practitioner brought the patient back for a review of the suspected lipoma. In case 4, a diagnosis of an epidermoid cyst was made by the nurse specialist whereas the remote reviewer diagnosed it as a chalazion and despite the discrepancy in the diagnosis, both the nurse practitioner and the remote reviewer discharged the patient.

There was an overall 82% agreement (36 out of 44 cases) in the management plans devised by the nurse-led clinic and remote reviewer. Kappa coefficient for management agreement between face-to-face and remote review was 0.74 (95% CI 0.58 to 0.90). In two cases of chalazia (cases 1 and 2), the remote reviewer chose to list for an incision and curettage whereas the nurse specialist discharged the patients. In two cases of papilloma (cases 5 and 6), the remote reviewer either discharged the patient or listed for excision biopsy, however, the nurse specialist booked follow-up appointments in 3 months. In the case of a naevus (case 8), the remote reviewer opted for a biopsy whereas the nurse specialist arranged a follow-up appointment in a clinic.

Seven patients were listed for excision biopsy by the face-to-face clinician and histopathological diagnoses were available for six as one patient did not contact the

Table 4 List of cases where there were disagreements of diagnosis and management plan between those reached by the face-to-face clinician and the remote reviewer

Case no	Face-to-face diagnosis	Face-to-face management plan	Remote diagnosis	Remote management plan
1	Chalazion	Discharge*	Chalazion	Incision and curettage*
2	Chalazion	Discharge*	Chalazion	Incision and curettage*
3	Chalazion*	Incision and curettage*	Enlarged caruncle*	Follow-up*
4	Epidermoid cyst*	Discharge	Chalazion*	Discharge
5	Epidermoid cyst*	Discharge*	Basal cell carcinoma*	Excision biopsy*
6	Papilloma	Follow-up*	Papilloma	Excision biopsy*
7	Papilloma	Follow-up*	Papilloma	Discharge*
8	Naevus	Follow-up*	Naevus	Excision biopsy*
9	Lipoma*	Follow-up*	Papilloma*	Excision biopsy*

*Indicates disagreements between face-to-face and remote reviewer.

Table 5 Clinical diagnoses reached by face-to-face clinician and remote reviewer where histopathological diagnoses were available

Case no	Face-to-face diagnosis	Remote diagnosis	Histopathological diagnosis
a	Epidermoid cyst	Epidermoid cyst	Epidermoid cyst
b	Epidermoid cyst	Epidermoid cyst	Epidermoid cyst
c	Benign intradermal naevus	Benign intradermal naevus	Benign intradermal naevus
d	Papilloma	Papilloma	Benign intradermal naevus
e	Papilloma	Papilloma	Papilloma
f	Granuloma	Granuloma	Granuloma

hospital to arrange a date for surgery. In five cases, clinical diagnose reached by both face-to-face and remote reviewers were in agreement and were confirmed by histopathological diagnoses. In one case, both face-to-face and remote reviewers diagnosed the lesion as a papilloma and the histological diagnosis demonstrated a benign intradermal naevus (table 5).

DISCUSSION

The benefits of telemedicine including improved outcomes, cost and time-efficiency, and increasing access to healthcare are well documented in ophthalmology.^{22–24} Telemedicine played a vital role in allowing continued provision of patient care while mitigating the risk of viral transmission during the recent COVID-19 pandemic and it has accelerated rapid integration of remote care into routine clinical practice. Oculoplastics is particularly well suited to telemedicine due to the highly visual nature of clinical assessment which can be evaluated without the need of a specialist equipment, however, the evidence base to support wider application of telemedicine is limited.¹³

Our study assessed the ability to establish accurate diagnoses and management plans of eyelid lesions remotely using a data collection proforma and photographs. Diagnostic and management plan agreements were good between face-to-face consultations and remote review at 91% and 82%, respectively. Histopathological diagnoses, where available, were compared with clinical impressions made by face-to-face assessor and remote reviewer. Both face-to-face assessor and remote reviewer correctly diagnosed eyelid lesions in five out of six cases (83.3%) with both clinicians diagnosing the same lesion as a papilloma where the histopathology demonstrated a benign intradermal naevus. It is possible that the diagnostic discrepancy demonstrated in our study is not indicative of the disagreements between different modes of review but rather represents the diagnostic inaccuracies that would be observed in face-to-face clinic settings. Previous studies reported the diagnostic accuracy of 70%–96%.^{25–28} It has therefore been recommended that all excised eyelid tissues should be sent for histopathological analysis as clinical assessment alone will not warrant accurate diagnosis and malignant eyelid lesions may masquerade

as clinically benign conditions. It is not uncommon to observe a diversity of clinical opinion among oculoplastic clinicians on the optimal management options for individual patients. In our study, although not statistically significant, the remote reviewer had a lower threshold to opt for excision biopsy whereas the face-to-face clinician was more likely to adopt a ‘wait and see’ approach. In one case, the remote reviewer suspected a basal cell carcinoma and chose to list the patient for a biopsy taking a more cautious approach.

Although the evaluation of eyelid lesions is akin to that of skin lesions, the inherent two-dimensional character of photographic evaluation poses particular challenges for eyelid lesions. The multilamellar anatomical construction of the eyelids means that the lesions can originate from or extend to deeper anatomical structures such as the tarsus or conjunctiva and may not be demonstrated well on photographs. Furthermore, eyelid lesions are likely to be smaller than those found on other parts of the body and may require more specialised lenses for adequate image resolution. A dynamic examination of eyelid lesions provides additional information as it is possible to ascertain, for example, if the lesion is tethered to the underlying structure, which is likely to narrow down the differential diagnoses.

Our study is one of the few that examined the utility of asynchronous telemedicine in oculoplastics. The proforma used in this study has been specifically designed to collect pertinent information to risk stratify the eyelid lesions by incorporating non-genetic risk factors such as age, history of previous skin malignancies and drug history.^{29–33}

Our study has several limitations. A small number of patients at a single centre with a limited range of diagnoses was enrolled and suspected malignant cases were excluded, thus limiting generalisability of the study. Six cases were excluded as clinical photographs were not captured. The face-to-face evaluation was performed by a nurse while the remote review was conducted by a doctor. The discrepancy between face-to-face consultations and remote review could be attributed to the inherent difference in training received. Having more than one face-to-face and remote reviewers and assessing intraobserver and interobserver agreement would have allowed more

in-depth exploration and reduce bias. In some cases, the lesion in question was not the focal point of some clinical photographs and this made it difficult for the remote assessor to evaluate the case.

The use of telemedicine in eyelid lesion assessment has a potential to reduce outpatient appointment and surgery waiting times, permit more accurate triaging of eyelid lesion cases, obviate the need for face-to-face appointments, and allow enhanced monitoring of eyelid lesions. This approach can be adopted for (1) referral refinement which has been shown to successfully reduce unnecessary or inappropriate referrals thus reducing waiting times; (2) image-based triage to risk stratify patients to allow more accurate assessment of the clinical urgency; (3) electronic consultation where the remote assessment can obviate the need for face-to-face appointments and (4) remote monitoring of eyelid lesions where photograph-based measurement has been shown to be more accurate than traditional face-to-face clinical evaluation.^{34–37}

A multicentre study including more subjects with a wider range of pathologies and histopathological diagnoses needs to be performed to further assess the accuracy of the use of asynchronous eyelid lesion assessment and to evaluate generalisability of the results. Involving more than one face-to-face and remote reviewers is important to minimise bias. Further research into patients' and clinicians' views on the use of telemedicine in oculoplastics should be carried out in order to design a service that addresses their needs and concerns.

Twitter Dawn A Sim @dawnasim and Peter B M Thomas @pbrmthomas

Contributors Initials of the authors involved in each of the following step of writing this paper are listed below. Planning: SK, MD, DAS, PBMT, DAE; conducting: SK, MD, DAE, DE; reporting: SK, MD, PBMT, DAS, DE; guarantor: SK.

Funding The publication costs of this article has been enabled by a grant from Moorfields Eye Charity (GR001325).

Competing interests None declared.

Patient consent for publication Not required.

Ethics approval The study was performed in full compliance with the Declaration of Helsinki. Permission to perform this study was granted by Moorfields Eye Hospital NHS Foundation Trust (reference number: CA/AD/675).

Provenance and peer review Not commissioned; externally peer reviewed.

Data availability statement Data are available on reasonable request.

Supplemental material This content has been supplied by the author(s). It has not been vetted by BMJ Publishing Group Limited (BMJ) and may not have been peer-reviewed. Any opinions or recommendations discussed are solely those of the author(s) and are not endorsed by BMJ. BMJ disclaims all liability and responsibility arising from any reliance placed on the content. Where the content includes any translated material, BMJ does not warrant the accuracy and reliability of the translations (including but not limited to local regulations, clinical guidelines, terminology, drug names and drug dosages), and is not responsible for any error and/or omissions arising from translation and adaptation or otherwise.

Open access This is an open access article distributed in accordance with the Creative Commons Attribution Non Commercial (CC BY-NC 4.0) license, which permits others to distribute, remix, adapt, build upon this work non-commercially, and license their derivative works on different terms, provided the original work is properly cited, appropriate credit is given, any changes made indicated, and the use is non-commercial. See: <http://creativecommons.org/licenses/by-nc/4.0/>.

ORCID iDs

Swan Kang <http://orcid.org/0000-0002-1303-9188>

Peter B M Thomas <http://orcid.org/0000-0003-1681-7659>

REFERENCES

- Ryu S. Telemedicine: opportunities and developments in member states: report on the second global survey on eHealth 2009 (global Observatory for eHealth series, volume 2). *Health Inform Res* 2012;18:153–5.
- Scanlon PH. The English national screening programme for diabetic retinopathy 2003–2016. *Acta Diabetol* 2017;54:515–25.
- Wei JC, Valentino DJ, Bell DS, *et al*. A web-based telemedicine system for diabetic retinopathy screening using digital fundus photography. *Telemed J E Health* 2006;12:50–7.
- Taylor CR, Merin LM, Salunga AM, *et al*. Improving diabetic retinopathy screening ratios using telemedicine-based digital retinal imaging technology: the Vine Hill study. *Diabetes Care* 2007;30:574–8.
- Boucher MC. Organisation of seamless teleophthalmology reliable management of diabetic retinopathy screening through. *Can J Diabetes* 2009;33:284.
- Misra N, Khanna RC, Mettla AL, *et al*. Role of teleophthalmology to manage anterior segment conditions in vision centres of South India: EyeSmart study-I. *Indian J Ophthalmol* 2020;68:362–7.
- BenZion I, Helveston EM. Use of telemedicine to assist ophthalmologists in developing countries for the diagnosis and management of four categories of ophthalmic pathology. *Clin Ophthalmol* 2007;1:489–95.
- Mines MJ, Bower KS, Lappan CM, *et al*. The United States Army Ocular Teleconsultation program 2004 through 2009. *Am J Ophthalmol* 2011;152:126–32.
- Verma M, Raman R, Mohan RE. Application of tele-ophthalmology in remote diagnosis and management of adnexal and orbital diseases. *Indian J Ophthalmol* 2009;57:381–4.
- Rayner S, Beaconsfield M, Kennedy C, *et al*. Subspecialty adnexal Ophthalmological examination using telemedicine. *J Telemed Telecare* 2001;7 Suppl 1:29–31.
- Hwang CJ, Eftekhari K, Schwarcz RM, *et al*. The aesthetic Oculoplastic surgery video Teleconference consult. *Aesthet Surg J* 2019;39:714–8. 21.
- Threlkeld AB, Fahd T, Camp M, *et al*. Telemedical evaluation of ocular adnexa and anterior segment. *Am J Ophthalmol* 1999;127:464–6.
- Kang S, Thomas PBM, Sim DA, *et al*. Oculoplastic video-based telemedicine consultations: Covid-19 and beyond. *Eye* 2020;34:1193–5.
- Jamison A, Diaper C, Drummond S, *et al*. Telemedicine in Oculoplastics: the real-life application of video consultation clinics. *Ophthalmic Plast Reconstr Surg* 2020. doi:10.1097/IOP.0000000000001852. [Epub ahead of print: 04 Nov 2020].
- Aoki L, Pereira IC, Matayoshi S. Comparative study between conventional camera images and smartphone images for eyelid tumor telediagnosis. *Rev Col Bras Cir* 2019;46:e2083.
- Rossato LA, Carneiro RC, Miyazaki A. *Accuracy of clinical examination in the diagnosis of eyelid lesions*. 73, 2014.
- Mehrtens SH, Shall L, Halpern SM. A 14-year review of a UK teledermatology service: experience of over 40 000 teleconsultations. *Clin Exp Dermatol* 2019;44:874–81.
- NHS Digital. Hospital Outpatient Activity 2018–19 [Internet]. Available: <https://digital.nhs.uk/data-and-information/publications/statistical/hospital-outpatient-activity/2018-19> [Accessed 12 Jul 2020].
- Mohite AA, Johnson A, Rathore DS, *et al*. Accuracy of clinical diagnosis of benign eyelid lesions: is a dedicated nurse-led service safe and effective? *Orbit* 2016;35:193–8.
- Plan NLT. NHS Long Term Plan [Internet]. NHS Long Term Plan. Available: <https://www.longtermplan.nhs.uk> [Accessed 02 Dec 2020].
- NHS England ». Transforming elective care services ophthalmology [Internet]. Available: <https://www.england.nhs.uk/publication/transforming-elective-care-services-ophthalmology/> [Accessed 02 Dec 2020].
- Jani PD, Forbes L, Choudhury A, *et al*. Evaluation of diabetic retinal screening and factors for ophthalmology referral in a telemedicine network. *JAMA Ophthalmol* 2017;135:706–14.
- Avidor D, Loewenstein A, Waisbourd M, *et al*. Cost-Effectiveness of diabetic retinopathy screening programs using telemedicine: a systematic review. *Cost Eff Resour Alloc* 2020;18:16.
- Ting DSW, Tan GSW. Telemedicine for diabetic retinopathy screening. *JAMA Ophthalmol* 2017;135:722–3.
- Kersten RC, Ewing-Chow D, Kulwin DR, *et al*. Accuracy of clinical diagnosis of cutaneous eyelid lesions. *Ophthalmology* 1997;104:479–84.

- 26 Deokule S, Child V, Tarin S, *et al.* Diagnostic accuracy of benign eyelid skin lesions in the minor operation theatre. *Orbit* 2003;22:235–8.
- 27 Margo CE. Eyelid tumors: accuracy of clinical diagnosis. *Am J Ophthalmol* 1999;128:635–6.
- 28 Hillson TR, Harvey JT, Hurwitz JJ, *et al.* Sensitivity and specificity of the diagnosis of periocular lesions by oculoplastic surgeons. *Can J Ophthalmol* 1998;33:377–83.
- 29 Clouser MC, Harris RB, Roe DJ, *et al.* Risk group, skin lesion history, and sun sensitivity reliability in squamous cell skin cancer progression. *Cancer Epidemiol Biomarkers Prev* 2006;15:2292–7.
- 30 Belbasis L, Stefanaki I, Stratigos AJ, *et al.* Non-genetic risk factors for cutaneous melanoma and keratinocyte skin cancers: an umbrella review of meta-analyses. *J Dermatol Sci* 2016;84:330–9.
- 31 Etkorn JR, Parikh RP, Marzban SS, *et al.* Identifying risk factors using a skin cancer screening program. *Cancer Control* 2013;20:248–54.
- 32 Drugge ED, Okundaye OI, Sarac RM, *et al.* Melanoma screening using patient self-assessed risk and total body photography. *Dermatol Online J* 2019;25:13030.
- 33 Fisher NM, Schaffer JV, Berwick M, *et al.* Breslow depth of cutaneous melanoma: impact of factors related to surveillance of the skin, including prior skin biopsies and family history of melanoma. *J Am Acad Dermatol* 2005;53:393–406.
- 34 Borooah S, Grant B, Blaikie A, *et al.* Using electronic referral with digital imaging between primary and secondary ophthalmic services: a long term prospective analysis of regional service redesign. *Eye* 2013;27:392–7.
- 35 Hanson C, Tennant MTS, Rudnisky CJ. Optometric referrals to retina specialists: evaluation and triage via teleophthalmology. *Telemed J E Health* 2008;14:441–5.
- 36 Kelly SP, Wallwork I, Haider D, *et al.* Teleophthalmology with optical coherence tomography imaging in community optometry. Evaluation of a quality improvement for macular patients. *Clin Ophthalmol* 2011;5:1673–8.
- 37 Soto JL, Vrcek I, Ozgur O, *et al.* Evaluating the growth of eyelid lesions: comparison of clinical evaluation and a software-based model. *Int Ophthalmol* 2017;37:1257–61.