

Evaluation of Reparative Dentine Bridge Formation after Direct Pulp Capping with Biodentine

Anh Huynh Bui, Khoa Van Pham

Department of Operative Dentistry and Endodontics, Faculty of Odonto-Stomatology, University of Medicine and Pharmacy at Ho Chi Minh City, Vietnam

Received : 10-10-20
Revised : 20-11-20
Accepted : 28-12-20
Published : 30-01-21

ABSTRACT **Aim:** To evaluate the capability of Biodentine for direct pulp capping in permanent teeth. **Materials and Methods:** The pulp of 11 human intact premolars were mechanically exposed in standard cavity dimensions and then capped with Biodentine for direct pulp capping. After 9–12 weeks, all teeth were extracted. All teeth were scanned using intraoral radiograph or cone-beam computed tomography (CBCT) scan before, right after pulp capping therapy, and after 9–12 weeks on both patient real and extracted teeth for evaluation of reparative dentin bridge formation. All clinical symptoms and signs were also recorded. Data were collected and analyzed using the MedCal statistical software at the significance of 0.05. **Results:** There was reparative dentin bridge formation in all experimental teeth, on both patient real and extracted teeth. **Conclusions:** The Biodentine could induce the formation of reparative dentin in direct pulp capping. The CBCT scan was the reliable modality for evaluation of dentin bridge formation.

KEYWORDS: Biodentine, dentin bridge formation, direct pulp capping, reparative dentin, vital pulp therapy

INTRODUCTION

Direct pulp capping is a minimally invasive dental pulp therapy which aims at preserving tooth vitality by facilitating pulp tissue repair and inducing mineralized tissue formation.^[1] It is based on the concept that the dental pulp has a natural potential for tissue repair, which leads to the formation of reparative dentin.^[1] Direct pulp capping is indicated to avoid or postpone root canal treatment, especially with immature teeth.^[2,3]

Calcium silicate-based cements have been developed about 20 years ago with the most well-known mineral trioxide aggregate (MTA) formulation which was considered as the gold standard for direct pulp capping procedures,^[1,4] and beside that, other prospective material also is introduced for vital pulp therapy beside the MTA.^[5] However, MTA has some disadvantages such as extensive setting time, difficult manipulation, and weak sealing ability. Recently, a newly developed

calcium-silicate-based cement, Biodentine (Septodont, St. Maur-des-Fossés, France), is claimed that it overcomes some limitations of the MTA.^[3]

Biodentine is a calcium silicate cement that was introduced as a “dentine replacement” material, comparable to MTA in terms of biocompatibility and induction of a calcific barrier.^[6,7] It has been shown to possess additional improvement in several other properties such as mixing, handling, shorter initial setting time, and less coronal discoloration.^[6,7] Biodentine showed better mechanical properties, excellent biocompatibility, and bioactive behavior to be used in direct pulp capping.^[6-8]

Address for correspondence: Dr. Khoa Van Pham, Department of Operative Dentistry and Endodontics, Faculty of Odonto-Stomatology, University of Medicine and Pharmacy at Ho Chi Minh City, 652 Nguyen Trai Street, Ward 11, District 5, 700000, Ho Chi Minh City, Vietnam. E-mail: khoapv@ump.edu.vn

This is an open access journal, and articles are distributed under the terms of the Creative Commons Attribution-NonCommercial-ShareAlike 4.0 License, which allows others to remix, tweak, and build upon the work non-commercially, as long as appropriate credit is given and the new creations are licensed under the identical terms.

For reprints contact: reprints@medknow.com

How to cite this article: Bui AH, Pham KV. Evaluation of reparative dentine bridge formation after direct pulp capping with biodentine. J Int Soc Prevent Communit Dent 2021;11:77-82.

Access this article online	
Quick Response Code: 	Website: www.jispcd.org
	DOI: 10.4103/jispcd.JISPCD_390_20

One of the most important signs proving for the successful of the direct pulp capping is the opaque bridge on the radiograph.^[3] Although the periapical radiography or parallel long cone radiographic technique are common in the daily practice and non-invasive methods for evaluation of the mineralized reparative dentin, these techniques cannot detect the earliest sign of the formation and make the comparison among studies impossible.^[8] With the cone beam computed tomography (CBCT), the assessment of hard tissue in a three-dimensional way becomes practical and accurate.^[9] The CBCT scan facilitates the position of the reparative dentin, the measurement of the target object in both qualitative and quantitative manner.^[10]

Although there are certain disadvantages,^[9] CBCT imager offers a creative and non-invasive method for investigation of the hard tissue with no destruction of dental tissue, on both *in vitro* experiment^[11] and clinical situation.^[10,12-14]

The aim of the present study was to evaluate the capability of the Biodentine (Septodont) for direct pulp capping in permanent teeth using the CBCT. The hypothesis is the CBCT cannot detect the formation of the dentin bridge or the Biodentine cannot induce the detectable formation of reparative dentin using CBCT.

MATERIALS AND METHODS

Setting and design

The present study was reviewed and approved by the Research Ethics Committee of the University of Medicine and Pharmacy at Ho Chi Minh City (approval number 305/ĐHYD-HĐĐĐ). Signed informed consent was obtained from all participants following thorough explanation of the research rationale, clinical procedures, and complications of the treatment.

The sample size of 11 was calculated using the G*Power 3.1.9.7 (Germany) with the power of 0.8, effect size of 0.85, and the two-side alpha level of 0.1 under the *t*-test family and signed rank-sum test (one sample case).

This prospective study was set up with the sample comprising 11 caries-free, intact, maxillary (4) and mandibular (7) permanent premolars, collected from 18- to 25-year-old humans and scheduled for extraction for orthodontic or surgical reasons.

Patient recruitment

All patients visiting the dental clinic of the Faculty of Odonto-Stomatology, University of Medicine and Pharmacy at Ho Chi Minh City, Vietnam were submitted to dental examination with the range of age from 18 to 25 years. Inclusion criteria were mature first

or second, upper or lower premolars without caries for tiny caries in enamel, with positive response to cold or electrical pulp test, without periapical change on periapical radiograph, no periodontal pocket depth over 4 mm, no former history of chronic medical illness or serious health problems that could affect the outcome of the dental procedure, no medication, no antibiotics in the last month, absence of signs or symptoms more severe than reversible pulpitis, written informed consent forms were signed relevant to the willingness to take part to the project. Exclusion criteria were bleeding following pulp exposure cannot be controlled within 10 min, nonvital teeth, open apex, pulp inflammation, pulp necrosis, periapical lesions, or root resorption on periapical radiograph.

Clinical examination

Pre-operative clinical examinations include a visual inspection of the extent of caries, gingival health, and status of adjacent soft tissue. Endodontic diagnostic tests were used to assess pulp sensitivity and vitality with percussion test and electrical test (Digitest II Pulp Vitality Tester, Parkell, USA). Electrical pulp tester's probe was used to apply an electrical impulse to the crown of the tooth (at the middle third of the buccal surface). Tooth with a response level lower than 70 is consider a vital status.

Paraclinical evaluation, through periapical radiograph and CBCT, was used to assess the extent and location of caries, restorations, pulp, and periapical status. Periapical and panoramic radiographs were obtained for each experimental tooth to assess the extent and location of caries, proximity of caries to the pulp, restorability of each tooth, periapical status, and presence of intra-radicular pathology.

Clinical protocol

Local anesthesia was achieved by standard periapical infiltration injection with lidocaine and epinephrine (1:100,000) (Lignospan Standard, Septodont, France). Then, the isolation was set up with a sterilized rubber dam soaked in 2% chlorhexidine (Cerkamed, Stalowa Wola, Polska). The tooth crown was mechanically cleaned with brush and disinfected with chlorhexidine (CHX) 2%. The occlusal class I cavity was prepared using a new sterilized round high-speed diamond bur (Dentsply Sirona, Ballaigues, Switzerland) with the diameter of 1 mm under water spray. The dimensions of the cavity were 2.0 ± 0.5 mm for occlusal depth, 2.0 ± 0.5 mm for mesiodistal width, and 2.0 ± 0.2 mm for buccolingual [Figure 1]. The pulpal wall of the cavity was placed at the depth of 0.5 mm into dentine layer. The prepared cavity was sterilized by using a cotton pellet moistened with 2% CHX.

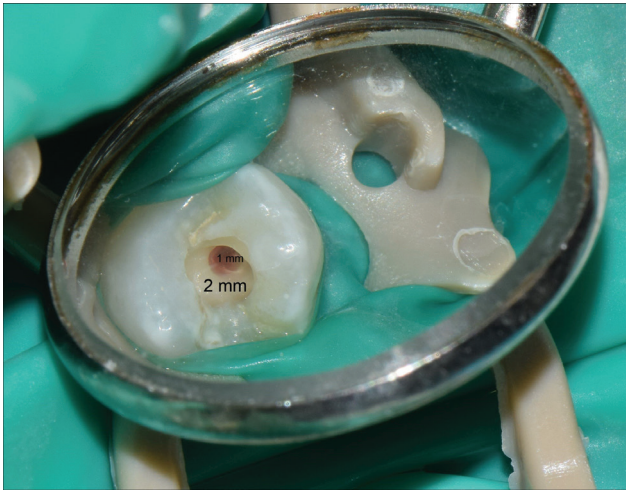

Figure 1: Dimensions of the prepared cavity

The pulp was exposed about 1 mm in diameter and directly capped with Biodentine. For achieving hemostasis, the cotton pellet moistened with sterilized saline was applied onto the exposed pulp for 1–9 min. Once bleeding stopped, the capping material was placed over the exposed pulp.

Biodentine was prepared according to the manufacturer's instructions and used to fill half the cavity with a thickness of 1.5 to 2 mm onto exposed pulp tissue and adjacent dentine. The temporary restorations were performed using glass ionomer cement (GC Gold Label 9-High Strength Posterior Restorative, GC Dental, Japan) and the final composite resin (Z250, 3M, ESPE, USA) was replaced after 1 week.

The digital radiographs were taken at baseline, right after pulp capping and after 9 weeks (before and after extraction). Digital intraoral radiographs were captured using the Sopix2, Size 1 (Sopro, La Ciotat, France), and dental X-ray machine (Satelec, Acteon Group, France) set at 70 kVp, 8 mA, and 0.08–0.04 s. The intraoral radiographs were captured with the parallel long cone technique using a 16-inch position device.

Digital CBCT scans were captured using the ProMax® 3DX-ray units (Planmeca, Helsinki, Finland). CBCT exposures were made using the parameters of 90 kVp, 14 mA, and 0.1 mm³ voxel size. The field of view was 5 cm in diameter and 5 cm in height. Slice dimensions were 1024 × 1024 pixels.

Recall protocol

Clinical assessment was performed at 1, 4, 8, and 12 weeks after direct pulp procedure and until before extraction. In periodical appointments, patient's perception on postoperative sensitivity, mastication discomfort, and sensations of pain during the experienced period were recorded. Patients could contact the operator whenever they felt any

uncomfortable pain. Tooth vitality was reassessed by electrical pulp test and percussion test. Clinical and radiographic examinations were performed to detect soft tissue swelling, coronal restoration's integrity, crown discoloration, periapical status, dentin bridge formation, and pulpal calcification.

Following the orthodontic treatment plan, the extraction of teeth was scheduled after 9–12 weeks under local anesthesia. Digital scans of extracted teeth were captured and then measured for the data collection.

Clinical evaluation

Patients provided information on postoperative sensitivity or pain throughout the experienced period on the questionnaire, according to the numerical pain scale and the Wong-Baker face pain scale ranging from 0 = no pain to 10 = worst pain.

The presence of tenderness to percussion was also recorded. The electrical sensitivity test was performed to assess pulp vital. The success of treatment in continuous controls was based on the following features, such as lack of mild/severe pain and tenderness to percussion; normal pulp viability; absence of signs and symptoms of pulp pathology; no swelling, fistula, abnormal mobility; absence of periapical pathology, internal or external resorption on radiographic images.

The failure or unresponsiveness to treatment was considered when the experimental tooth presents abnormal susceptibility to percussion and electric testing when compared with control tooth and abnormal sign of an apical lesion on radiographic images. To determine the success and failure of the treatment, clinical examinations were conducted at each appointment by one examiner who was blinded to the capping materials applied for each group.

Radiographic evaluation

Radiographs were captured before and after pulp capping and extraction. Intraoral digital radiograph was observed to evaluate the presence and the continuity of the dentin bridge using the Sopro Imaging software with the codes ranged from 1 to 4, in that code 1 was complete dentin bridge formation, code 2 was partial/incomplete dentin bridge formation extending to over one-half of the exposure site but not completely closing the exposure site, code 3 was initial dentin bridge formation extending to not over one-half of the exposure site, and code 4 was no dentin bridge formation [Figure 2].

CBCT scan was analyzed to identify reparative dentin bridges on multi-planar reconstruction images, using axial and horizontal slices. A serial profile of the dentin bridge was reconstructed from the coronal (the first virtual slice) to the cervical sections (the last virtual

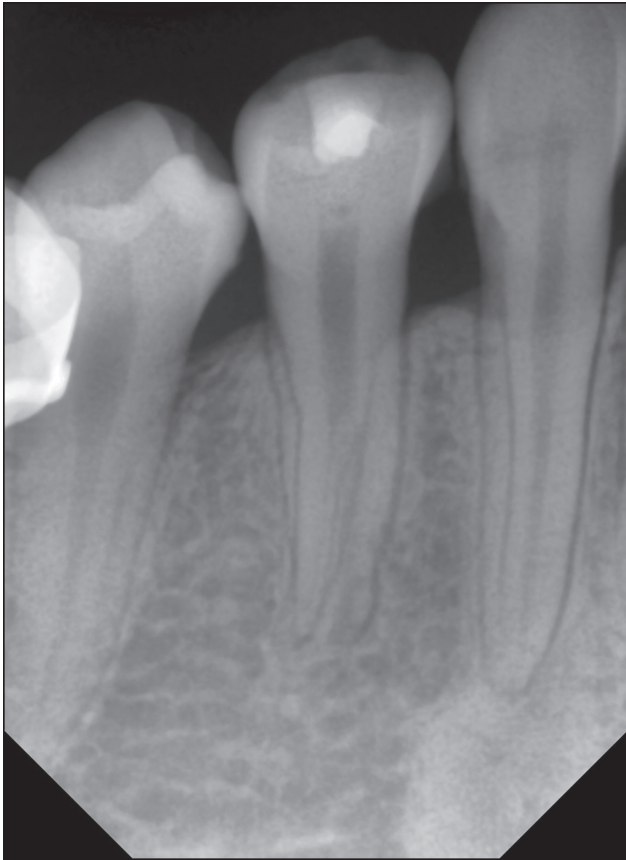

Figure 2: Formation dentin bridge on the periapical radiograph

slice) to allow calculation of the estimated volume of the reparative dentin bridge. The reparative dentin volume ranged from code 1 of high volume ($\geq 1 \text{ mm}^3$), code 2 of moderate volume ($0.5\text{--}0.99 \text{ mm}^3$), code 3 of low volume ($0.1\text{--}0.49 \text{ mm}^3$), and code 4 of no dentin or immeasurable volume of dentin [Figure 3]. Intraoral digital and CBCT scan was captured on both patient and extracted teeth.

Statistical analysis

Data were collected and analyzed using the MedCal Statistical Software version 19 (Ostend, Belgium). The Wilcoxon signed test was used to test the statistical difference between the dentin bridge volume of the teeth treated by Biodentine and the value of 0 at the significance of 0.05. The Fisher exact test was used to detect the statistical difference between the present study and the previous study^[11] on the presence or absence of the reparative dentin bridge at the significance of 0.05.

RESULTS

All patients experienced no pain or mild pain in the first few days. After these days, there was no pain for patients at any levels or any time.

Because the data were not normal distribution, the one-sample signed rank sum test was applied to detect the statistical difference between the two times, one right after the Biodentine was inserted and one after 9–12

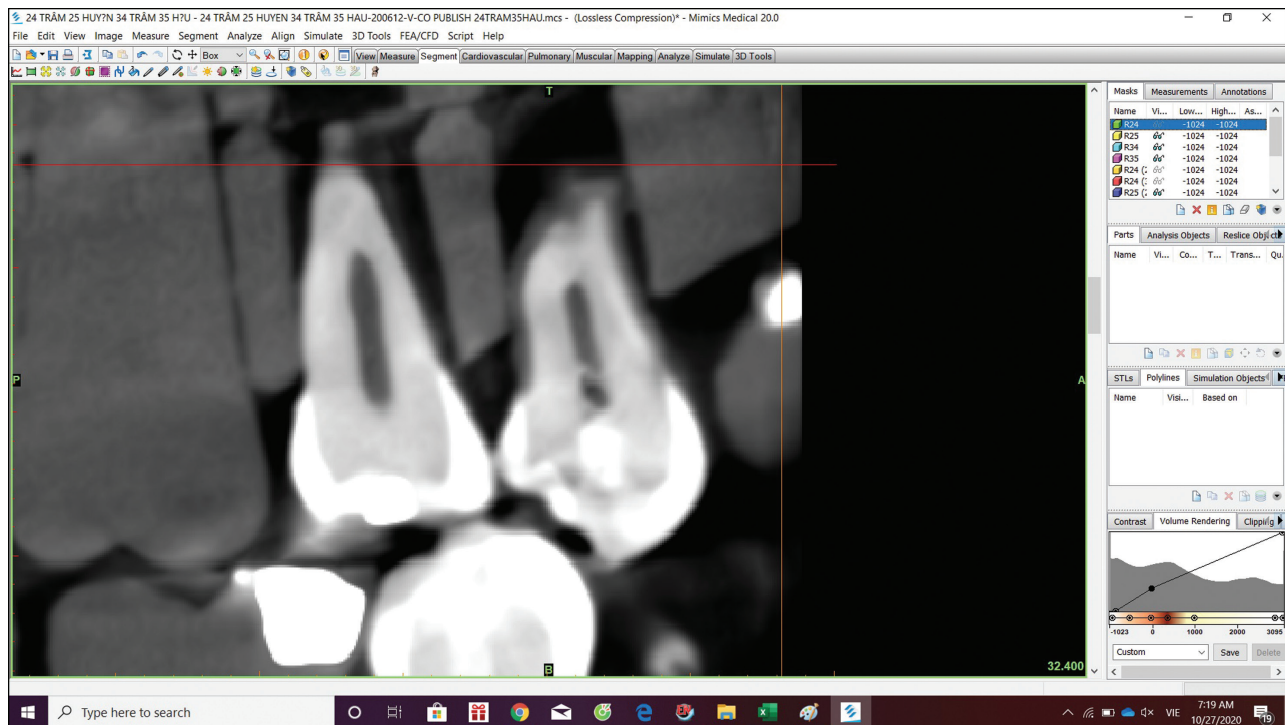


Figure 3: Formation dentin bridge on the CBCT image

weeks from the first intervention on the reparative dentin bridge volumes. The logarithmic transformation was applied to normalize the data for further comparative statistical analysis. The reparative dentin bridge volumes on patient and extracted teeth are displayed in Table 1. There were statistically significant differences between the two evaluated times on dentin bridge formation volumes for both the extracted teeth and the patient real teeth ($P < 0.05$). There was no significant difference between two measurements on extracted teeth or patient real teeth for the reparative dentin bridge volumes.

DISCUSSION

The results of the present study revealed that there were dentin bridge formations in all investigated teeth using Biodentine for direct pulp capping. The present study used CBCT scans, PA radiographs for evaluation of the dentin bridges of the teeth on patients or after extractions. Almost dentin bridge volumes were moderate to large, except for the three samples. The time for dentin bridge formation lasted from 9 to 12 weeks, after the first direct pulp capping. All patients experienced the mild pain or without pain symptom in the postoperative periodic examinations. The clinical symptoms were similar to that of the previous studies.^[6-8,12,15]

The continuity of the dentin bridge was an absence in one extracted lower first premolar of a girl at 9 weeks on the periapical digital radiograph. However, on the CBCT scan, the dentin bridge of this premolar was measured at 0.12mm^3 , the lowest value in the range of data of the results. Although there was a high correlation between the two radiographical modalities, the periapical digital X-ray showed the low sensitivity when compared with the CBCT radiograph for investigation of the dentin bridge formation after direct pulp capping. The routine intra-oral periapical digital image was popularly used for common tasks in the operative dentistry with low radiation when compared with the CBCT image. The confirmation of dentin bridge formation was usually conducted using the periapical radiograph on the asymptomatic patients after direct pulp procedure. The result of the present study revealed that the periapical digital radiograph, with the limitation of the clinical

buccolingual direction and two-dimension, could not detect the earliest dentin bridge trace on even extracted tooth, as in this circumstance.

With no artifact, the extracted tooth scanned using the CBCT device showed the high qualitative and quantitative data for evaluation of the dentin bridge formation after direct pulp capping using the Biodentine in the present study. There were differences between the results of the present study with the previous study^[11] on the proportion of dentin bridge formation and the levels of reparative dentin volume; however, these differences were not statistically significant. These differences might come from the age range of the patients and the time in the previous study.^[11] The age for the present study was in the range of 18–25 years, meanwhile the age for the previous study was in the range of 19–32 years and the time for the formation of the dentin bridge for the present study was from 9 to 12 weeks, meanwhile that of the previous study was only 6 weeks.^[11] The age range of the subjects was younger, and the investigated time were longer than those of the previous study that might induce bigger volume of the reparative dentin in the present study when compared with that of the previous study.^[11] These factors could be used for an explanation of the difference of the number of teeth without dentin bridge formation of the two studies. Three teeth had no signs of reparative dentin in the previous study when compared with there was no tooth without dentin bridge in the present study.^[11]

The CBCT image showed the major advantages in evaluation of the early marks of dentin bridge formation on both the extracted tooth and the teeth on the actual patient under the circumstances of the present study. Although the ICC index of the two measurements on extracted or real teeth was moderate correlation, the CBCT scan with the voxel size of 0.1mm^3 was prospective modality for investigation of the pulp alteration on the real clinical patient. For our knowledge, this is the first study on the reparative dentin using CBCT in both extracted tooth and real tooth. Inherent drawback of CBCT scan was the artifact which interfered the actual outcome on the clinical situation, especially with heavy metal restoration. The background

Table 1: Reparative dentin bridge formation for the patient real or extracted teeth after direct pulp capping with Biodentine from 9 to 12 weeks

Group	Volume		Log(volume)		P
	Mean	Standard deviation	Mean	Variance of logs	
Extracted teeth	1.1009	1.0145	0.7709	0.1673	0.001*
Patient real teeth	0.6186	0.5577	0.3731	0.2429	0.001*
		ICC index = 0.7082			P = 0.1184**

ICC for the raw data of volume, * $P < 0.05$, one-sample signed rank sum test with test value of 0 (for the same row), ** $P > 0.05$, independent *t*-test for the two groups [for the log(volume) data]

noise and lower contrast of the CBCT image made the interpretation of the delicate trace as early reparative dentin bridge becomes impossible. With the modern equipment and the tiny voxel size at low radiation, the result of the present study showed that the detection of the first dentin repair mark could be completely performed, even on the actual patient in the real clinical situation. There was not a significant difference between extracted and actual clinical tooth on the reparative dentin volume, and there was a moderate correlation between these two data. This result revealed that the CBCT image could be used for the evaluation of the early reparative dentin sign on the clinical circumstance.

The disadvantage of the present study was the small sample size, and the investigation was performed on the limit age range of the patient. The different voxel sizes were not conducted for the extracted tooth for the evaluation of the capability of the CBCT device was also a limitation of the present study. Further investigation of the reparative dentin bridge formation should be performed on the patient in a wider range of age, with a larger sample size, and at other voxel sizes of the CBCT scans. The randomized clinical trials should be conducted to compare the effectiveness of the Biodentine and other materials such as MTA or other calcium-sulfate materials. This kind of study should also be carried on the carious tooth without pulp inflammation to further confirm the characteristics of the Biodentine.

CONCLUSIONS

Biodentine could induce the formation of reparative dentin in direct pulp capping. The CBCT scan was the reliable modality for evaluation of dentin bridge formation.

Financial support and sponsorship

Nil.

Conflicts of interest

There are no conflicts of interest.

Ethical policy and institutional review board statement

Not applicable.

Patient declaration of consent

The authors certify that they have obtained all appropriate patient consent forms. In the form the patient(s) has/have given his/her/their consent for his/her/their images and other clinical information to be reported in the journal. The patients understand that their names and initials will not be published and due efforts will be made to conceal their identity, but anonymity cannot be guaranteed.

Data availability statement

Not applicable.

REFERENCES

1. Kunert M, Lukomska-Szymanska M. Bio-inductive materials in direct and indirect pulp capping—a review article. *Materials* 2020;13:1204.
2. Mahmoud S, El-Negoly S, Zaen El-Din A, El-Zekrid M, Grawish L, Grawish H, *et al.* Biodentine versus mineral trioxide aggregate as a direct pulp capping material for human mature permanent teeth: A systematic review. *J Conserv Dent* 2018;21:466-73.
3. Careddu R, Duncan HF. How does the pulpal response to Biodentine and ProRoot mineral trioxide aggregate compare in the laboratory and clinic? *Br Dent J* 2018;225:743-9.
4. Okiji T, Yoshida K. Reparative dentinogenesis induced by mineral trioxide aggregate: A review from the biological and physicochemical points of view. *Int J Dent* 2009;2009:464280.
5. Vu TT, Nguyen MT, Sangvanich P, Nguyen QN, Thunyakitpisal P. Acemannan used as an implantable biomaterial for vital pulp therapy of immature permanent teeth induced continued root formation. *Pharmaceutics* 2020;12:644.
6. Brizuela C, Ormeño A, Cabrera C, Cabezas R, Silva CI, Ramírez V, *et al.* Direct pulp capping with calcium hydroxide, mineral trioxide aggregate, and biodentine in permanent young teeth with caries: A randomized clinical trial. *J Endod* 2017;43:1776-80.
7. Bakhtiar H, Nekoofar MH, Aminishakib P, Abedi F, Naghi Moosavi F, Esnaashari E, *et al.* Human pulp responses to partial pulpotomy treatment with theracal as compared with biodentine and proroot MTA: A clinical trial. *J Endod* 2017;43:1786-91.
8. Paula A, Carrilho E, Laranjo M, Abrantes AM, Casalta-Lopes J, Botelho MF, *et al.* Direct pulp capping: Which is the most effective biomaterial? A retrospective clinical study. *Materials* 2019;12:3382.
9. Weber MT, Stratz N, Fleiner J, Schulze D, Hannig C. Possibilities and limits of imaging endodontic structures with CBCT. *Swiss Dent J* 2015;125:293-311.
10. Arafa A, Kenawi L, Issa N. Assessment of reparative hard tissue formation after direct pulp capping with Biodentine versus mineral trioxide aggregate. *Endodontic Practice Today* 2019;13:9.
11. Nowicka A, Wilk G, Lipski M, Kolečki J, Buczkowska-Radlińska J. Tomographic evaluation of reparative dentin formation after direct pulp capping with Ca(OH)₂, MTA, Biodentine, and Dentin bonding system in human teeth. *J Endod* 2015;41:1234-40.
12. Nowicka A, Lipski M, Parafiniuk M, Sporniak-Tutak K, Lichota D, Kosierkiewicz A, *et al.* Response of human dental pulp capped with biodentine and mineral trioxide aggregate. *J Endod* 2013;39:743-7.
13. Mathur VP, Dhillon JK, Logani A, Kalra G. Evaluation of indirect pulp capping using three different materials: A randomized control trial using cone-beam computed tomography. *Indian J Dent Res* 2016;27:623-9.
14. Hegde S, Sowmya B, Mathew S, Bhandi SH, Nagaraja S, Dinesh K. Clinical evaluation of mineral trioxide aggregate and biodentine as direct pulp capping agents in carious teeth. *J Conserv Dent* 2017;20:91-5.
15. Parinyaprom N, Nirunsittirat A, Chuveera P, Na Lampang S, Srisuwan T, Sastraruji T, *et al.* Outcomes of direct pulp capping by using either proroot mineral trioxide aggregate or biodentine in permanent teeth with carious pulp exposure in 6- to 18-year-old patients: A randomized controlled trial. *J Endod* 2018;44:341-8.