

Lens Extraction for Management of Coexisting Cataract and Post-filtering Surgery Ocular Hypotony

Ghasem Fakhraie, MD; Zahra Mohajernezhad-Fard, MD; Sasan Moghimi, MD; Zakieh Vahedian, MD
Yadollah Eslami, MD; Reza Zarei, MD

Department of Ophthalmology, Glaucoma Service, Farabi Eye Hospital, Tehran University of Medical Sciences, Tehran, Iran

Abstract

Purpose: To evaluate the safety and efficacy of phacoemulsification for management of post-filtering ocular hypotony.

Methods: This prospective interventional case series study recruited 21 consecutive patients with an established diagnosis of ocular hypotony with or without maculopathy. Clear corneal incision phacoemulsification was done for all patients. Nineteen cases that completed a follow-up of at least 6 months were considered for final analysis.

Results: Mean baseline intraocular pressure (IOP) was 2.95 ± 1.43 mm Hg, which increased to 8.84 ± 4.67 mm Hg at 6 months ($P < 0.001$). Hypotony was resolved in 13 cases (68%) at 6 months while 6 cases (32%) showed persistent hypotony at this time point. Postoperative IOP change at all follow-up time points was not correlated with patient age, time interval between filtering surgery and phacoemulsification, baseline IOP, baseline anterior chamber depth and IOP on the first postoperative day. Three cases (16%) showed filtering bleb failure with dramatic IOP rise around the first postoperative month and required glaucoma medication for IOP control. No significant intra- or postoperative complications were noted.

Conclusion: Cataract surgery alone seems promising in resolving hypotony in patients with post-filtering ocular hypotony, and can be considered as an effective treatment modality before proceeding to more complicated procedures.

Keywords: Ocular Hypotony; Phacoemulsification; Trabeculectomy

J Ophthalmic Vis Res 2015; 10 (4): 385-390.

INTRODUCTION

Ocular hypotony the incidence of which has increased following the advent of anti-metabolites,^[1-3] is a potentially devastating complication of filtering surgery

in glaucoma patients. If left untreated, associated complications of hypotony including maculopathy and corneal decompensation may become vision threatening. Other complications consist of progressive cataract, inflammation, ciliochoroidal effusion or hemorrhage, extensive retinal detachment, optic nerve edema, and even phthisis with significant visual loss.^[4]

Current surgical interventions for management of post-filtering hypotony mostly aim to reduce filtration from the bleb site. Resuturing of the scleral flap is advised at the early stages of ocular hypotony,^[5] while more

Correspondence to:

Zakieh Vahedian, MD. Glaucoma Service, Farabi Eye Hospital, Qazvin Square, South Kargar Avenue, Tehran 13366-16351, Iran.
E-mail: vahedian.z@gmail.com

Received: 15-08-2014

Accepted: 25-10-2014

Access this article online

Quick Response Code:



Website:
www.jovr.org

DOI:
10.4103/2008-322X.176908

This is an open access article distributed under the terms of the Creative Commons Attribution-NonCommercial-ShareAlike 3.0 License, which allows others to remix, tweak, and build upon the work non-commercially, as long as the author is credited and the new creations are licensed under the identical terms.

For reprints contact: reprints@medknow.com

How to cite this article: Fakhraie G, Mohajernezhad-Fard Z, Moghimi S, Vahedian Z, Eslami Y, Zarei R. Lens extraction for management of coexisting cataract and post-filtering surgery ocular hypotony. *J Ophthalmic Vis Res* 2015;10:385-90.

aggressive treatments might be considered necessary when the risk of hypotony maculopathy is judged to be high. A myriad of different interventions have been suggested by different authors;^[6-29] most of them seem to induce inflammation at the surgical site and bleb.

Among the current theories, the role of induced inflammation at the trabeculectomy site seems to be more intriguing, which is believed to decrease aqueous leak by scar formation at the trabeculectomy site.^[30-33] Theoretically, any kind of intraocular surgery might induce intraocular inflammation and our previous observations after phacoemulsification in previously filtered eyes showed intraocular pressure (IOP) rise in some patients. Based on this assumption and due to the relatively high rate of development or progression of cataracts in patients undergoing filtering surgery, we decided to perform a preliminary longitudinal study on the efficacy and safety of cataract extraction as the initial intervention for management of patients with post-filtering surgery ocular hypotony.

METHODS

In this prospective interventional case series, we recruited 21 consecutive eyes of 21 patients with an established diagnosis of post-filtering surgery ocular hypotony with or without maculopathy over a 1-year period at Farabi Eye Hospital, a University-based tertiary care center. The study was approved by the Ethics Committee of Tehran University of Medical Sciences and adhered to the tenets of the Declaration of Helsinki. Written informed consent was taken from all patients.

All patients had previously undergone a fornix-based trabeculectomy with intraoperative application of mitomycin C for the management of glaucoma and were diagnosed with persistent ocular hypotony (IOP < 6 mmHg) for more than 4 months. All patients also had visually significant cataracts.

Exclusion criteria were history of eye surgery other than filtering surgery, bleb leak, visually insignificant cataracts and reluctance for phacoemulsification as a potential treatment modality to treat ocular hypotony.

Baseline characteristics and demographic data including age, gender, time interval between filtering surgery and phacoemulsification, and type of glaucoma were recorded. Patients then received a comprehensive ophthalmologic examination including measurement of best-corrected visual acuity (BCVA) in LogMAR units, slit lamp examination, applanation tonometry (Goldmann applanation tonometer), keratometry and fundus examination.

Hypotony maculopathy was defined as a decrease of at least two lines in BCVA from baseline, retinal striae, and macular edema in the setting of low IOP. Filtering blebs were categorized as diffuse and low lying with normal conjunctival vasculature (Type I), and as localized and

avascular or ischemic (Type II). Pre-and postoperative anterior chamber depth (ACD) was measured using an optical coherence biometer (IOLMaster v. 3, Zeiss Meditec, CA, USA).

All procedures were performed by a single experienced glaucoma surgeon (GF) using the same surgical technique (temporal clear corneal incision phacoemulsification with in-the-bag implantation of a foldable intraocular lens) in all cases. Postoperatively, patients received topical steroid and antibiotic eye drops; the antibiotic drop was prescribed for 1-week, the steroid drop was used every 2 h for the 1st week and then every 4, 6, 8, and 12 h during the 2nd to 5th weeks after surgery. Follow-up sessions were scheduled on the 1st day, 1st week, and 1st, 3rd and 6th months postoperatively. The results of the 6th month and last session follow-up were noted and considered for final analysis.

Success at 6 months and last visit was defined as complete if IOP was 6 to 21 mmHg without any glaucoma medication and qualified if IOP was within the same range with the use of glaucoma medications. The outcome was categorized as a failure in case of persistent hypotony or IOP > 21 mmHg despite maximum tolerated medical therapy.

Statistical analysis was performed using SPSS for windows version 17 (SPSS Inc., Chicago, IL, USA). All data were represented as mean \pm standard deviation. Due to the relatively small sample size (and also skewed distribution of pre- and postsurgical IOP), we used Wilcoxon one-sample nonparametric test for evaluation of continuous variables. Spearman's correlation coefficient was used to evaluate the correlation between continuous variables. The contingency coefficient was used to evaluate the correlation between the two categorical variables. For all measurements, a two-tailed test was used, and $P < 0.05$ was considered significant.

RESULTS

A total of 21 eyes of 21 patients with cataract and post-filtering ocular hypotony were enrolled in the study. All procedures were performed without significant intraoperative complications, and the postoperative course was uneventful in all cases. Two cases were excluded from the study due to incomplete follow-up; the 19 cases that completed at least 6 months' follow-up were considered for final analysis.

Demographics and baseline characteristics of the patients are provided in Table 1. Mean age was 61.7 ± 10.3 (range, 48–85) years and 12 patients (63%) were male. The mean time interval time between filtering surgery and phacoemulsification was 7.1 ± 2.2 (range, 4–12) months and mean follow-up following cataract surgery was 10.6 ± 3.6 (range, 6–18) months. None of the patients were on glaucoma medication. Filtering

Table 1. Patient's demographics and characteristics (n=19)

Variable	Description (%)
Age (years)	
Mean±SD	61.68±10.30
Range	48-85
Gender n (%)	
Male	12 (63)
Female	7 (37)
Type of glaucoma n (%)	
POAG	7 (37)
PEXG	10 (53)
PG	2 (10)
Baseline IOP (mmHg)	
Mean±SD	2.95±1.43
Range	0-5
Baseline logMAR BCVA	
Mean±SD	0.95±0.2
Range	0.7-1.3
Baseline cylindrical refractive error (diopter)	
Mean±SD	2.73±0.97
Range	1-4.75
Baseline AC depth (mm)	
Mean±SD	2.48±0.59
Range	1.2-3.3
Presence of choroidal effusion n (%)	
Yes	7 (37)
No	12 (63)
Presence of hypotony maculopathy	
Yes n (%)	7 (37)
No n (%)	7 (37)
Undetectable	5 (26)

POAG, primary open-angle glaucoma; PEXG, pseudoexfoliative glaucoma; PG, pigmentary glaucoma; IOP, intraocular pressure; BCVA, best-corrected visual acuity; AC, anterior chamber; SD, standard deviation

blebs were categorized as Type I in 13 cases (68%) and as Type II in 6 cases (32%).

Mean baseline IOP was 2.9 ± 1.4 (range: 0–5) mmHg which was increased to 8.8 ± 4.7 (range: 4–20, $n = 19$) mmHg and to 10.4 ± 4.8 (range: 4–19, $n = 15$) mmHg at 6 months ($P < 0.001$) and at last visit ($P = 0.001$), respectively. The trend of IOP changes following surgery is shown in Figure 1. Mean IOP change was $+7.7 \pm 8.8$ (range: 0 to + 30, $n = 19$) mmHg, $+5.9 \pm 5.3$ (range: -1 to + 19, $n = 19$) mmHg and $+7.3 \pm 5.8$ (range: -1 to + 18, $n = 15$) mmHg at postoperative 1 and 6 months, and at last visit, respectively. There was a significant correlation between postoperative IOP rise and the presence of Type I filtering blebs ($r = 0.735$, $P < 0.001$).

Postoperative IOP change at all follow-up time points was not correlated with patient age, time interval between filtering surgery and phacoemulsification, baseline IOP, baseline ACD and IOP on postoperative

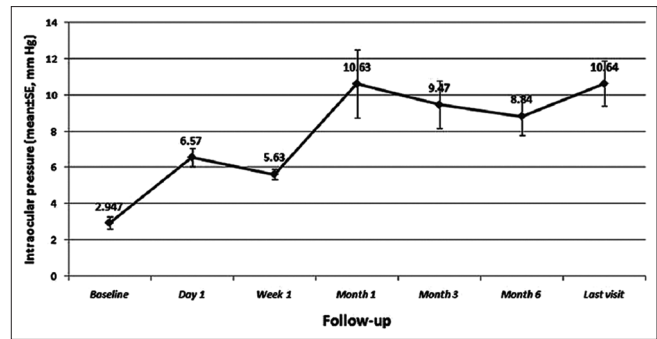


Figure 1. Intraocular pressure trend during the follow-up period (SE, standard error).

day 1. After 6 months, hypotony was resolved in 13 cases (68%), while 6 cases (32%) showed persistent hypotony. Three cases (16%) showed filtering bleb failure with dramatic IOP rise, all around the first postoperative month, and needed two glaucoma medications for IOP control. None of these eyes required additional glaucoma surgery. Clinical features of these three cases are given in Table 2. Success at 6 months ($n = 19$) was complete in 10 cases (52%) qualified in 3 cases (16%) while 6 cases (31%) were categorized as failures. Corresponding figures at last visit ($n = 15$) were 8 (53%), 3 (20%) and 4 (27%) cases, respectively.

At baseline, choroidal effusion was present in 7 cases (37%) which resolved in all but one case (5%) by 6 months. ACD increased from 2.48 ± 0.59 (range: 1.2–3.3) mm at baseline to 3.43 ± 0.36 (range: 2.3–3.8) mm at 6 months ($P < 0.001$). Retinal folds characteristic of hypotony maculopathy could be detected in 7 cases (37%) at baseline. Due to hazy media, it was not possible to perform an exact fundus examination in another 5 patients (26%). At postoperative month six, 4 cases (21%) showed persistent hypotony maculopathy.

Mean LogMAR BCVA improved from 0.95 ± 0.2 (range, 0.7–1.3) at baseline to 0.5 ± 0.16 (range: 0.2–0.8) at 6 months ($P < 0.001$). Mean cylindrical refractive error changed from 2.73 ± 0.97 (range: 1–4.75) diopters at baseline to 1.17 ± 0.44 (range: 0.5–2.25) diopters at 6 months ($P < 0.001$).

DISCUSSION

The results of our study indicate that cataract surgery can induce IOP rise in patients with post-filtering surgery hypotony and cataracts. Excluding 3 cases that demonstrated bleb failure, we achieved a 52% complete success rate at last visit to treat ocular hypotony by performing phacoemulsification; however, including these 3 cases we were able to treat hypotony in 68% of our patients by performing phacoemulsification alone. Furthermore, after 6 months, choroidal effusion and hypotony maculopathy were resolved in 95% and 79% of cases, respectively.

Table 2. Characteristics of three patients who ended up with bleb failure

Variable	Case		
	1	2	3
Age (years)	57	61	50
Gender	Male	Female	Male
Type of glaucoma	PEXG	PEXG	POAG
Bleb type	Diffuse	Diffuse	Diffuse
Surgery interval (months)	5	4	7
Baseline IOP (mmHg)	2	1	3
First month postoperative IOP (mmHg)	25	31	28
Last visit IOP (mmHg)	18	19	13
Last visit number of antiglaucoma medications	2	2	2
Follow-up (months)	15	12	15

IOP, intraocular pressure; PEXG, pseudoexfoliative glaucoma; POAG, primary open angle glaucoma

Controversy still exists on the possible effect of cataract extraction on IOP in patients with a history of trabeculectomy. There are numerous controversial studies in the literature discussing either the effect of surgical method (phacoemulsification vs. extracapsular cataract extraction [ECCE]) or the timing of surgery, i.e., simultaneous phacoemulsification-trabeculectomy or phacoemulsification at a given time interval from trabeculectomy.^[30,32,34-44]

Earlier studies on intracapsular cataract surgery or ECCE believed that these procedures may increase IOP in patients with functioning filtering blebs.^[32,37,39,42] After the introduction of phacoemulsification, Caprioli et al^[45] showed that although it may cause a transient elevation in IOP in previously trabeculectomized eyes, no significant difference in IOP control occurs after 1-year. Casson et al^[36] also performed phacoemulsification with an interval of at least 3 months from trabeculectomy in glaucoma patients and found no statistical difference between pre-and postoperative IOP taken 2 years after the surgery. Some other studies have also confirmed the findings by Caprioli et al and Casson et al.^[37,43,46] On the other hand, other studies have reported that when phacoemulsification is performed at a time interval from trabeculectomy, a statistically significant rise in IOP should be expected in glaucoma patients.^[38,39,42,44,47-49] Furthermore, certain factors such as the time interval between trabeculectomy and cataract surgery^[38,41] and IOP level before cataract surgery^[40,44,49] seem to affect the degree of IOP rise after cataract surgery in trabeculectomized eyes.

Also of interest are the controversial ideas on comparing the effect of surgical method (phacoemulsification or ECCE) on mean IOP of post-filtering surgery eyes.^[36,37,39,42,47] Halikiopoulos et al believe that both techniques increase IOP in the long-term to the same

extent;^[47] while Casson et al have claimed that ECCE, but not phacoemulsification, causes IOP rise in previously filtered eyes.^[36] Some other studies have found that both methods increase IOP in trabeculectomized eyes; however, phacoemulsification had less effect on postoperative IOP control than did ECCE.^[37,39,42]

The results of the present study support studies that showed IOP rise following phacoemulsification in post-filtering patients. We observed that following phacoemulsification at least 4 months after trabeculectomy, mean IOP increased by about 5.89 mm Hg after 6 months ($P < 0.0001$). This effect was also seen to be persistent at last follow-up in all cases. It was also observed in our case series that, after 6 months of follow-up, ocular hypotony was completely resolved in 13 patients (68%), while 6 patients (32%) still presented with ocular hypotony, among which 4 patients showed persistent hypotony maculopathy.

The main mechanism explaining increased IOP after cataract surgery in post-filtering ocular hypotony might be surgically induced inflammatory reaction along with scar tissue formation leading to decreased filtration of aqueous through the filtering bleb.^[30-33] Considering the total success rate of 68% in our study, it sounds that the induced inflammation is an unpredictable phenomenon which cannot delimit bleb function in all patients. Furthermore, due to the short-term follow-up of our study, we cannot make a comment on the long lasting effect of the inflammatory reaction on overfiltration.

In one study evaluating ultrasound biomicroscopic features of blebs before and after phacoemulsification,^[49] the route under the scleral flap became narrower and intrableb reflectivity increased after cataract surgery, these alterations were not statistically significant though. Therefore, it can be inferred that the principal location of inflammation and scar formation after cataract surgery are conjunctival-scleral and/or at the scleral flap interface.

Bleb failure occurred in 16% of our patients after cataract extraction, all in cases with diffuse and low-lying filtering blebs [Table 2]. Diffuse blebs have normal vasculature as compared to localized cystic ones, and it can be assumed that they may also have a more normal cell population as well. Therefore, it would not be surprising that these cells are capable of promoting inflammation and scar formation after an insult (such as phacoemulsification) in contrast to thin cystic blebs which may have a smaller number of pro-inflammatory cells. This theory may be evaluated in future studies by measuring the concentration of cytokines and cell populations.

Mean BCVA improved dramatically after 6 months in our patients which could not be exclusively attributed to the cataract extraction; it seems that this improvement occurred in part due to correction of hypotony

maculopathy and reduction in cylindrical refractive error in our patients.

Although we cannot compare our results with previous studies examining different strategies to treat ocular hypotony, in the current study phacoemulsification cataract surgery was able to increase mean IOP by 5.9 mmHg after 6 months and by 7.4 mmHg IOP at final follow-up. The 68% success rate for treating ocular hypotony in the current study is higher than that of currently suggested treatment modalities.^[6-29,50] This study has some limitations such as relatively small sample size, absence of a control group, relatively short-term follow-up, and lack of supporting pathobiological evidence.

In summary, cataract surgery seems to be a promising strategy for management of post-filtering surgery ocular hypotony. Although the preliminary results of the current study have been intriguing, the future direction should be toward designing multicenter controlled trials with higher sample sizes and long-term follow-up to confirm the reliability, safety and efficacy of this intervention.

Financial Support and Sponsorship

A grant from Tehran University of Medical Sciences.

Conflicts of Interest

There are no conflicts of interest.

REFERENCES

- Membrey WL, Poinosawmy DP, Bunce C, Hitchings RA. Glaucoma surgery with or without adjunctive antiproliferatives in normal tension glaucoma: 1 intraocular pressure control and complications. *Br J Ophthalmol* 2000;84:586-590.
- Haynes WL, Alward WL. Control of intraocular pressure after trabeculectomy. *Surv Ophthalmol* 1999;43:345-355.
- Bindlish R, Condon GP, Schlosser JD, D'Antonio J, Lauer KB, Lehrer R. Efficacy and safety of mitomycin-C in primary trabeculectomy: Five-year follow-up. *Ophthalmology* 2002;109:1336-1341.
- Leen MM, Mills RP. Prevention and management of hypotony after glaucoma surgery. *Int Ophthalmol Clin* 1999;39:87-101.
- Suñer JJ, Greenfield DS, Miller MP, Nicoleta MT, Palmberg PF. Hypotony maculopathy after filtering surgery with mitomycin C. Incidence and treatment. *Ophthalmology* 1997;104:207-214.
- Zacharia PT, Deppermann SR, Schuman JS. Ocular hypotony after trabeculectomy with mitomycin C. *Am J Ophthalmol* 1993;116:314-326.
- Schwartz GF, Robin AL, Wilson RP, Suan EP, Pheasant TR, Prenskey JG. Resuturing the scleral flap leads to resolution of hypotony maculopathy. *J Glaucoma* 1996;5:246-251.
- Sugar HS. Treatment of hypotony following filtering surgery for glaucoma. *Am J Ophthalmol* 1971;71:1023-1033.
- Budenz DL, Chen PP, Weaver YK. Conjunctival advancement for late-onset filtering bleb leaks: Indications and outcomes. *Arch Ophthalmol* 1999;117:1014-1019.
- Friedman SM, Mahootchi A. The use of intravitreal gas for the treatment of ocular hypotony after glaucoma filtration surgery. *Ophthalmic Surg Lasers Imaging* 2006;37:234-235.
- Shirato S, Maruyama K, Haneda M. Resuturing the scleral flap through conjunctiva for treatment of excess filtration. *Am J Ophthalmol* 2004;137:173-174.
- Van de Geijn EJ, Lemij HG, de Vries J, de Waard PW. Surgical revision of filtration blebs: A follow-up study. *J Glaucoma* 2002;11:300-305.
- Okada K, Tsukamoto H, Masumoto M, Jian K, Okada M, Mochizuki H, et al. Autologous blood injection for marked overfiltration early after trabeculectomy with mitomycin C. *Acta Ophthalmol Scand* 2001;79:305-308.
- Akova YA, Dursun D, Aydin P, Akbatur H, Duman S. Management of hypotony maculopathy and a large filtering bleb after trabeculectomy with mitomycin C: Success with argon laser therapy. *Ophthalmic Surg Lasers* 2000;31:491-494.
- Beigi B, O'Keefe M, Algawi K, Acheson R, Burke J. Sulphur hexafluoride in the treatment of flat anterior chamber following trabeculectomy. *Eye (Lond)* 1997;11(Pt 5):672-676.
- Nuyts RM, Greve EL, Geijssen HC, Langerhorst CT. Treatment of hypotonous maculopathy after trabeculectomy with mitomycin C. *Am J Ophthalmol* 1994;118:322-331.
- Yannuzzi LA, Theodore FH. Cryotherapy of post-cataract blebs. *Am J Ophthalmol* 1973;76:217-222.
- Cleasby GW, Fung WE, Webster RG Jr. Cryosurgical closure of filtering blebs. *Arch Ophthalmol* 1972;87:319-323.
- Lynch MG, Roesch M, Brown RH. Remodeling filtering blebs with the neodymium: YAG laser. *Ophthalmology* 1996;103:1700-1705.
- Bettin P, Carassa RG, Fiori M, Brancato R. Treatment of hyperfiltering blebs with Nd: YAG laser-induced subconjunctival bleeding. *J Glaucoma* 1999;8:380-383.
- Gehring JR, Ciccarelli EC. Trichloroacetic acid treatment of filtering blebs following cataract extraction. *Am J Ophthalmol* 1972;74:622-624.
- Leen MM, Moster MR, Katz LJ, Terebuh AK, Schmidt CM, Spaeth GL. Management of overfiltering and leaking blebs with autologous blood injection. *Arch Ophthalmol* 1995;113:1050-1055.
- McCoy RC, Burney EN. Treatment of bleb hypotony after phacoemulsification with autologous blood. *Ophthalmic Surg Lasers* 1998;29:849-851.
- Blok MD, Kok JH, van Mil C, Greve EL, Kijlstra A. Use of the megasoft bandage lens for treatment of complications after trabeculectomy. *Am J Ophthalmol* 1990;110:264-268.
- Haynes WL, Alward WL. Combination of autologous blood injection and bleb compression sutures to treat hypotony maculopathy. *J Glaucoma* 1999;8:384-387.
- Morgan JE, Diamond JP, Cook SD. Remodelling the filtration bleb. *Br J Ophthalmol* 2002;86:872-875.
- Myers JS, Yang CB, Herndon LW, Allingham RR, Shields MB. Excisional bleb revision to correct overfiltration or leakage. *J Glaucoma* 2000;9:169-173.
- Tannenbaum DP, Hoffman D, Greaney MJ, Caprioli J. Outcomes of bleb excision and conjunctival advancement for leaking or hypotonous eyes after glaucoma filtering surgery. *Br J Ophthalmol* 2004;88:99-103.
- Buxton JN, Lavery KT, Liebmann JM, Buxton DF, Ritch R. Reconstruction of filtering blebs with free conjunctival autografts. *Ophthalmology* 1994;101:635-639.
- Oyakawa RT, Maumenee AE. Clear-cornea cataract extraction in eyes with functioning filtering blebs. *Am J Ophthalmol* 1982;93:294-298.
- Shields MB. Combined cataract extraction and glaucoma surgery. *Ophthalmology* 1982;89:231-237.
- Dickens MA, Cashwell LF. Long-term effect of cataract extraction on the function of an established filtering bleb. *Ophthalmic Surg Lasers* 1996;27:9-14.
- Sibayan SA, Igarashi S, Kasahara N, Montenegro MH,

- Simmons RJ, Simmons RB, et al. Cataract extraction as a means of treating postfiltration hypotony maculopathy. *Ophthalmic Surg Lasers* 1997;28:241-243.
34. Drolsum L, Haaskjold E. Extracapsular cataract extraction in eyes previously operated for glaucoma. *Acta Ophthalmol (Copenh)* 1994;72:273-278.
 35. Yamagami S, Araie M, Mori M, Mishima K. Posterior chamber intraocular lens implantation in filtered or nonfiltered glaucoma eyes. *Jpn J Ophthalmol* 1994;38:71-79.
 36. Casson RJ, Riddell CE, Rahman R, Byles D, Salmon JF. Long-term effect of cataract surgery on intraocular pressure after trabeculectomy: Extracapsular extraction versus phacoemulsification. *J Cataract Refract Surg* 2002;28:2159-2164.
 37. Manoj B, Chako D, Khan MY. Effect of extracapsular cataract extraction and phacoemulsification performed after trabeculectomy on intraocular pressure. *J Cataract Refract Surg* 2000;26:75-78.
 38. Husain R, Liang S, Foster PJ, Gazzard G, Bunce C, Chew PT, et al. Cataract surgery after trabeculectomy: The effect on trabeculectomy function. *Arch Ophthalmol* 2012;130:165-170.
 39. Chiselita D, Antohi I, Medvichi R, Danielescu C, Marcu C, Trifina A, et al. The influence of cataract surgery on the efficacy of trabeculectomy in patients with open-angle glaucoma. *Oftalmologia* 2004;48:71-80.
 40. Mietz H, Andresen A, Welsandt G, Krieglstein GK. Effect of cataract surgery on intraocular pressure in eyes with previous trabeculectomy. *Graefes Arch Clin Exp Ophthalmol* 2001;239:763-769.
 41. Muñoz-Negrete FJ, Rebolleda G, García Llanes G, Reche Sainz JA. Intraocular pressure evolution after phacoemulsification in eyes with filtering blebs. *Arch Soc Esp Ophthalmol* 2000;75:757-764.
 42. Seah SK, Jap A, Prata JA Jr., Baerveldt G, Lee PP, Heuer DK, et al. Cataract surgery after trabeculectomy. *Ophthalmic Surg Lasers* 1996;27:587-594.
 43. Aziz S, Spiers N, Jay J. Effect of phacoemulsification on intraocular pressure control in primary open angle glaucoma previously treated by trabeculectomy: A casecontrol study. *Open J Ophthalmol* 2012;2:1420.
 44. Rebolleda G, Muñoz-Negrete FJ. Phacoemulsification in eyes with functioning filtering blebs: A prospective study. *Ophthalmology* 2002;109:2248-2255.
 45. Caprioli J, Park HJ, Kwon YH, Weitzman M. Temporal corneal phacoemulsification in filtered glaucoma patients. *Trans Am Ophthalmol Soc* 1997;95:153-167.
 46. Park HJ, Kwon YH, Weitzman M, Caprioli J. Temporal corneal phacoemulsification in patients with filtered glaucoma. *Arch Ophthalmol* 1997;115:1375-1380.
 47. Halikiopoulos D, Moster MR, Azuara-Blanco A, Wilson RP, Schmidt CM, Spaeth GL, et al. The outcome of the functioning filter after subsequent cataract extraction. *Ophthalmic Surg Lasers* 2001;32:108-117.
 48. Chen PP, Weaver YK, Budenz DL, Feuer WJ, Parrish RK 2nd. Trabeculectomy function after cataract extraction. *Ophthalmology* 1998;105:1928-1935.
 49. Wang X, Zhang H, Li S, Wang N. The effects of phacoemulsification on intraocular pressure and ultrasound biomicroscopic image of filtering bleb in eyes with cataract and functioning filtering blebs. *Eye (Lond)* 2009;23:112-116.
 50. Fink AJ, Boys-Smith JW, Brear R. Management of large filtering blebs with the argon laser. *Am J Ophthalmol* 1986;101:695-699.