



## Original Research

# The Effect of Lumbar Spinal Surgery History on Intradiscal O<sub>2</sub>-O<sub>3</sub> Treatment Results in Patients with Lumbar Disk Herniation

Mustafa Kılıç,<sup>1</sup> Tülay Erçalık<sup>2</sup>

<sup>1</sup>Department of Neurosurgery, Sisli Hamidiye Etfal Training and Research Hospital, Istanbul, Turkey

<sup>2</sup>Department of Physical Medicine and Rehabilitation, Sisli Hamidiye Etfal Training and Research Hospital, Istanbul, Turkey

### Abstract

**Objectives:** The aim of the present study was to investigate the effect of previous spinal surgery on intradiscal ozone-oxygen (O<sub>2</sub>-O<sub>3</sub>) treatment in low back pain associated with lumbar disc herniation (LDH).

**Methods:** Patients who underwent intradiscal O<sub>2</sub>-O<sub>3</sub> therapy for LDH-induced low back pain were screened retrospectively from hospital records. To ensure homogenization of participants, patients who had received O<sub>2</sub>-O<sub>3</sub> therapy to L4-L5 and L5-S1 intervertebral discs, those with pre-injection and post-injection month 1 data, and those who completed the first year of treatment were included in the study. Patients who completed the first year of treatment but with missing data were contacted and followed up by phone. Patients who underwent surgery at the same level as the injection level were classified as Group 1 (n=30), and those without surgery were classified as Group 2 (n=43). Pain and disability were measured by Visual Analog Scale (VAS) and Oswestry Disability Index (ODI), respectively.

**Results:** There was no statistically significant difference between the pre-injection VAS and ODI scores of the groups (p=0.719 and p=0.108). Group 1 had significantly higher VAS and ODI scores on month 1 and year 1 than Group 2, and statistically significant decreases were seen in VAS and ODI scores in both groups at follow-up (p<0.001 for all). There was no statistically significant difference between month 1 and year 1 VAS evaluations of the groups with respect to ≥50% improvement in pain reduction (p=0.213 and p=0.347).

**Conclusion:** In the present study, the effect of the history of spinal surgery on intradiscal O<sub>2</sub>-O<sub>3</sub> treatment results was investigated. Intradiscal injection was found to be effective for both groups, but more successful results were obtained in patients without surgical history.

**Keywords:** Intradiscal ozone treatment; low back pain; percutaneous discolysis.

Please cite this article as "Kılıç M, Erçalık T. The Effect of Lumbar Spinal Surgery History on Intradiscal O<sub>2</sub>-O<sub>3</sub> Treatment Results in Patients with Lumbar Disk Herniation. Med Bull Sisli Etfal Hosp 2019;53(2):148–153".

Low back pain is the sixth most common disease contributing to the global burden of disease according to the 2010 Global Burden of Disease Study. However, it is the most important cause of global disability according to the number of years lived with disability.<sup>[1]</sup> According to a review published in 2012, the prevalence of lifelong low back pain is 38.9%.<sup>[2]</sup> Lifetime prevalence of lumbosacral

radiculopathy is 3%–5%.<sup>[3]</sup> Although the majority of patients recover without treatment or with conservative treatment, 37%–54% of the patients may still feel pain after 1 year.<sup>[4]</sup>

One of the common causes of low back pain is lumbar disk hernia due to degenerative disk disease (lumbar disk herniation (LDH)). Minimally invasive methods can be

**Address for correspondence:** Mustafa Kılıç, MD. Sisli Hamidiye Etfal Eğitim ve Araştırma Hastanesi, Beyin Cerrahisi Bölümü, İstanbul, Turkey

**Phone:** +90 532 625 63 22 **E-mail:** kilicnrs@gmail.com

**Submitted Date:** May 30, 2018 **Accepted Date:** June 11, 2018 **Available Online Date:** July 08, 2019

©Copyright 2019 by The Medical Bulletin of Sisli Etfal Hospital - Available online at [www.sislietfaltip.org](http://www.sislietfaltip.org)

**OPEN ACCESS** This is an open access article under the CC BY-NC license (<http://creativecommons.org/licenses/by-nc/4.0/>).



used to prevent or delay open surgery in patients who do not respond to standard conservative treatments in LDH-induced low back pain. Intradiscal ozone therapy, which is one of these methods, was started to be used in the 1990s, and it has been increasingly adopted due to its clinical efficacy, low side effect rates, and low cost.<sup>[5]</sup>

Ozone is normally a strong oxidizing gas found in the atmosphere. Many studies have shown its safety when used in appropriate doses.<sup>[6]</sup> The main effect of the ozone gas that has anti-inflammatory, analgesic, and antiseptic properties in intradiscal application is to reduce water retention by breaking the glycosaminoglycan chains in the nucleus pulposus and to decrease the volume of hernia by discal dehydration.<sup>[6]</sup> Thus, it is possible to reduce the pressure effect and to relieve the symptoms. Another mechanism of action is the reduction of inflammation around the nerve root due to its anti-inflammatory properties.

Intradiscal ozone administration is safely performed in nontoxic doses (1–40 mg/ml) in the form of ozone–oxygen ( $O_2-O_3$ ) mixture. The application is performed with the guidance of computed tomography or fluoroscopy, and its combined use with periganglionic steroid and local anesthetic injections is recommended by many authors.<sup>[6]</sup> A limited number of studies are cited in the literature about the patient group who responds better to the application of intradiscal ozone therapy,

In this retrospective study, data of 73 patients who underwent intradiscal ozone due to LDH-induced radicular lumbar pain were reviewed retrospectively to evaluate the clinical efficacy of patients who had or had not undergone spinal surgery.

## Methods

Data of patients who had been treated with intradiscal  $O_2-O_3$  between June 2017 and April 2017 were screened from hospital records and patient files to achieve patient homogenization.

Patients who completed 1 year of treatment and whose data regarding before and 1 month after the application of ozone therapy directed to the L4–L5 and L5–S1 intraspinal disks were completely available were included in the study to achieve patient homogenization. Patients with missing hospital records who had completed their year 1 of treatment were called by phone for control. Patients whose level of previous surgical treatment was the same as the level of injection were classified as Group 1, and the surgery-naïve patients were classified as Group 2. Patients who had undergone surgery at a different level from the injection site were excluded from the study.

## Patient selection Criteria for Intradiscal Ozone Administration

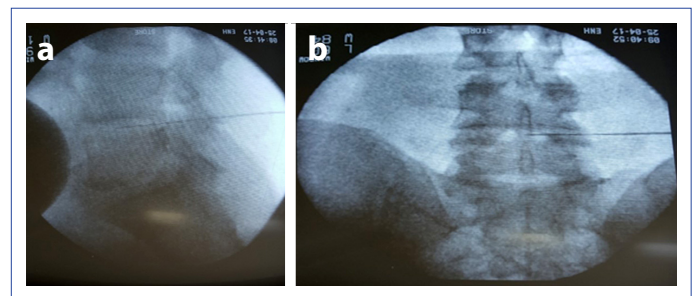
1. Lack of any response to previous conservative treatment modalities and persistence of radicular pain for at least 3 months.
2. Detection of clinical degenerative discopathy according to anamnesis, clinical examination, and lumbar magnetic resonance imaging (MRI) findings.
3. Presence of discopathy at the level of protrusion as detected using MRI.
4. Visual Analog Scale (VAS) pain score >4.

## Exclusion Criteria

Pregnant patients, patients with glucose-6-phosphate dehydrogenase deficiency, bleeding diathesis, systemic infection, motor deficits, and MRI findings, such as calcified disc, bulging, extrusion, and sequestration, were excluded from the study. All patients were informed about the injection, its benefits, and the complications before the procedure.

## Procedure

The procedures were performed under sterile conditions in the operating room, and the patient was monitored to follow-up the vital signs. Images were obtained using PHILIPS brand BV Pulsera/ref. 718095 model fluoroscopy device. The patient was placed in the prone position, and the lumbar lordosis was flattened by placing a pillow under the abdomen. The application site was cleansed according to the asepsis antisepsis guidelines. After the level of fluoroscopic intervention was determined, a 22 (20 gage for obese patients) gage 20 cm-long spinal needle was inserted through a posterolateral approach from a point 10 cm lateral to the midline at a 30°–45° angle into the affected disk. As an ozone generator, the Turkozone-Blueozon brand was used. A mixture of 10 ml  $O_2-O_3$  containing 40 mg/ml  $O_3$  was injected intradiscally. In addition, 1 cc methylprednisolone plus 1 cc 0.05% bupivacaine mixture was injected into the foraminal area (Fig. 1). All applications were performed by an experienced neurosurgeon. After the procedure, the patients were discharged with a prescription of 3 days of rest and antibiotherapy.



**Figure 1.** Lateral (a) and anteroposterior (b) fluoroscopic images of the Chiba needle.

### Evaluation Parameters

Demographic data of the patients and pain and disability scores obtained before and at 1 month controls after injection were screened from hospital records. Pain was measured using VAS, and disability was measured using Oswestry Disability Index (ODI). The first year controls were performed using the same scales.

### Statistical Analysis

Data were analyzed using SPSS 15.0 for Windows program (SPSS Inc., Chicago, IL, USA) for statistical analysis. Descriptive statistics were expressed as number and percentage for categorical variables and as mean, standard deviation, minimum, maximum, and median for numerical variables. As the numerical variables did not meet the normal distribution condition, the independent two group comparisons were made using the Mann–Whitney U test. The rates in the independent groups were compared by the chi-square test. The dependent group comparisons were analyzed by the Friedman test as the differences between the numerical variables did not meet the normal distribution condition. Subgroup analysis was performed by the Wilcoxon test. A p value <0.05 was accepted as statistically significant.

### Results

Between June 2016 and April 2017, 119 patients without missing data who received ozone therapy directed to L4–L5 or L5–S1 intradiscal space were enrolled into the study. Of the 119 patients, 15 had a history of lumbar surgery applied at various levels, and the remaining 104 were searched by phone. It was revealed that 17 patients had been treated with spinal surgery or other interventional methods (e.g., epidural steroid injection and intradiscal application) after the application of ozone therapy (Fig. 2).

One-year data of 14 patients out of the remaining 87 cases were not available. Thirty out of 73 patients whose month 1 and year 1 data were available and who had a history of surgery at the same level were classified as Group 1, whereas 43 patients with no history of surgery were classified as Group 2 (Fig. 3).

The mean age and number of female patients in Group 1 were significantly higher than those in Group 2 ( $p < 0.001$  and  $p = 0.037$ ). There was no statistically significant intergroup difference as for the level of ozone application ( $p = 0.983$ ). The painful period of Group 2 was significantly longer than that of Group 1 ( $p = 0.043$ ) (Table 1).

There was no statistically significant difference between the groups with respect to mean VAS and ODI scores ( $p = 0.719$  and  $p = 0.108$ ). The mean VAS and ODI scores of

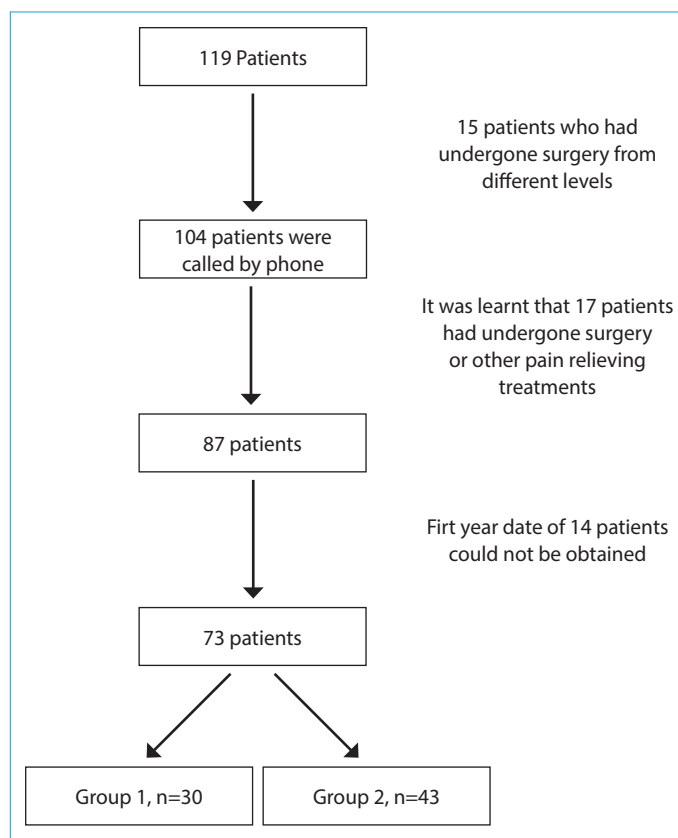


Figure 2. Study diagram.

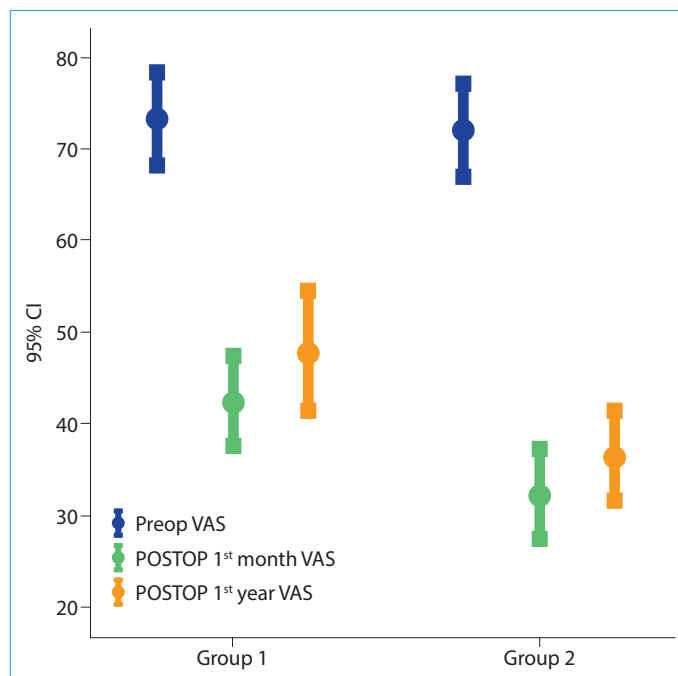


Figure 3. Changes in VAS scores.

Group 1 after injection were significantly higher than those of Group 2 ( $p = 0.024$ ,  $p = 0.014$ ,  $p = 0.003$ , and  $p = 0.009$ ). In both groups, intragroup changes occurring during the fol-

**Table 1.** Descriptive characteristics of the patients

	Group 1	Group 2	
Age, mean±SD (min–max) (year)	50.7±12.5 (27-78)	40.8±5.2 (30-54)	<0.001
Gender, n (%)			
Male	10 (33.3)	25 (58.1)	0.037
Female	20 (66.7)	18 (41.9)	
Spinal level, n (%)			
L4-5	21 (70.0)	30 (69.8)	0.983
L5-S1	9 (30.0)	13 (30.2)	
Painful period, mean±SD (min–max)	6.0±3.3 (3-18)	8.3±5.2 (3-24)	0.043
Postoperative period, mean±SD (min–max) (months)	31.4±27.9 (5-112)		

SD: Standard Deviation.

low-up period were significant ( $p < 0.001$  for all) (Fig. 1). The difference in all changes was statistically significant (VAS scores: Group 2: 1<sup>st</sup> and 1<sup>st</sup> year  $p = 0.004$  and ODI scores: Group 1: 1<sup>st</sup> and 1<sup>st</sup> year  $p = 0.003$  for all other comparisons,  $p < 0.001$ ) (Table 2).

There was no statistically significant difference as for  $\geq 50\%$  decreases in the month 1 and year 1 pain (VAS) scores of the groups when compared with pre-injection values ( $p = 0.213$  and  $p = 0.347$  and  $p = 0.213$  and  $p = 0.347$ ) (Table 3).

## Discussion

Minimally invasive percutaneous decompression techniques in the treatment of LDH-induced pain require short-term hospitalization, and they are increasingly preferred as they reduce the risk of postoperative scar formation, which is the most common cause of recurrence of pain after major surgery. Intradiscal  $O_2-O_3$  treatment, which is one of the percutaneous chemical decompression techniques, is being applied with high success rates.

**Table 2.** VAS and ODI scores of the groups

	Group 1			Group 2			p
	Mean±SD	Min–max	Median	Mean±SD	Min–max	Median	
VAS							
Preop	73.3±14.0	50-100	75	72.1±15.0	50-100	70	0.719
Postop 1 month	42.3±15.5	10-70	40	32.3±15.9	0-60	40	0.024
Postop 1 year	48.0±17.9	10-80	50	36.3±15.4	0-60	40	0.014
p		<0.001			<0.001		
Oswestry							
Preop	64.0±15.4	40-90	70	57.9±16.6	20-90	60	0.108
Postop 1 month	40.3±18.1	10-80	40	28.1±12.2	0-50	30	0.003
Postop 1 year	43.3±18.3	10-80	40	32.3±12.5	0-60	30	0.009

ODI: Oswestry Disability Index; SD: Standard Deviation; VAS: Visual Analog Scale.

**Table 3.** Percentages of patients whose VAS scores decreased  $\geq 50\%$ 

	Group 1		Group 2		p
	n	%	n	%	
VAS 1 month change					
<50%	17	56.7	18	41.9	0.213
$\geq 50\%$	13	43.3	25	58.1	
VAS 1 year change					
<50%	18	60.0	21	48.8	0.347
$\geq 50\%$	12	40.0	22	51.2	

VAS: Visual Analog Scale.

It is a less invasive procedure with good antiseptic properties and very low risk of infection but without any risk of allergic anaphylaxis. In this retrospective study, patients with intradiscal O<sub>2</sub>-O<sub>3</sub> treatment were evaluated, and the effect of previous surgery on the results was investigated. Although our findings suggest that intradiscal O<sub>2</sub>-O<sub>3</sub> treatment is effective in both groups, the results were better in patients who had not undergone surgery.

The mechanism of radicular pain related to LDH is known to have an impact under both mechanical and biochemical factors.<sup>[4]</sup> The efficacy of intradiscal ozone administration in LDH-induced low back pain is thought to be achieved both by reducing mechanical compression and by acting on biochemical cycles. These factors include interruption of the inflammatory prostaglandin cascade with ozone, prevention of tissue hypoxia by increased O<sub>2</sub> concentration, repair of damaged disc by activation of fibroblastic cells, and most importantly, reduction of disc volume by preventing water retention and decrease in mechanical pressure.<sup>[6]</sup>

There are many studies reporting successful results in the short- and long-term with intradiscal ozone application in the literature.<sup>[7-10]</sup> The success rates in the studies vary between 65% and 85%.<sup>[8, 11, 12]</sup> This range of difference is mainly due to different study designs, such as patient groups, application techniques, outcome measures used, and statistical differences. In studies evaluating efficacy, some data can be obtained that may guide the patient selection for intradiscal ozone therapy, but studies have failed to determine the ideal patient group for this treatment.

In a retrospective review by Oder et al.<sup>[13]</sup> on 621 patients, the relationship between MRI findings and many features, such as presence of degenerative alterations, previous surgery, age, sex, and success rates, was examined, and they reported better results in patients aged <50 years and inadequate response in patients who had undergone surgery. We have not encountered another study in the literature that evaluated the effect of previous spinal surgery on the O<sub>2</sub>-O<sub>3</sub> treatment. In spite of the fact that many factors have been analyzed, spinal surgery has not been elaborated in detail. We included only patients who had previously undergone surgery and received injections at L4-L5 and L5-S1 levels and attempted to establish a homogeneous group.

We found that VAS rates were lower after intradiscal ozone administration in patients who had not undergone spinal surgery in accordance with the current literature. There was a significant reduction in pain in both groups, but the difference in the number of patients whose pain was reduced ≥50% was not significantly different. Considering that the mean age in the group who had undergone surgery was

relatively higher, a more degenerate and painful disc may be detected in patients with a history of surgery. Therefore, it may be foreseeable that these patients may provide lower benefit from this procedure. Although our findings have demonstrated that previous surgery had an effect on the results of the intradiscal O<sub>2</sub>-O<sub>3</sub> therapy, we have observed that these patients had entertained a very satisfactory pain relief. Therefore, this procedure was also effective in these patients.

In the literature, the size of the herniated disc material was evaluated as another factor that might have an impact on the results. In a previous study, the effect of disc morphology on success was investigated,<sup>[14]</sup> and the best results were obtained in bulging disks compared with extruded or protruded disks. We could not make this distinction because we only included patients with protruded disks in our study. This factor is an important condition to be investigated in future studies because this distinction has not been made in many studies that evaluated the effectiveness of ozone therapy.<sup>[7, 10-15]</sup>

The overall rate of procedural complication of ozone administration is 0.1%.<sup>[5]</sup> Two meta-analyses have identified the safety and effectiveness of this therapy.<sup>[4, 5]</sup> Complications related to the applications in lumbar discopathies have been reported as case reports.<sup>[16-19]</sup> Owing to the antiseptic property of the ozone gas itself, infection is quite rare, but probably due to the inadequate attention to asepsis and antisepsis as iatrogenic complications, a case of spondylodiscitis and another case of fetal septicemia have been reported in the literature.<sup>[20, 21]</sup> In our study, no major complications were observed. Our investigation has some limitations. The most important limitations are smaller number of patients with complete data and relatively shorter follow-up period because of the retrospective design of the study.

To our knowledge, this is the first study that evaluated the effectiveness of patients who have undergone spinal surgery in comparison with the control group; this is the strength of our study.

## Conclusion

When conservative treatment is insufficient in the treatment of lumbar pain due to lumbar degenerative discopathy, percutaneous techniques should be attempted before surgery. Intradiscal O<sub>2</sub>-O<sub>3</sub> treatment is one of these techniques, which is being used with increasing success. There are limited data in the literature on which patients will have better outcomes. The impact of spinal surgery on the results was investigated in the present study.

Although the results of patients who had not undergone

surgery were better, quite successful results have been also achieved in patients who had undergone spinal surgery. Further prospective controlled long-term follow-up studies addressing other factors that may guide patient selection are needed.

#### Disclosures

**Ethics Committee Approval:** The study was approved by the Local Ethics Committee.

**Peer-review:** Externally peer-reviewed.

**Conflict of Interest:** None declared.

**Authorship Contributions:** Concept – T.E.; Design – T.E.; Supervision – M.K.; Materials – M.K.; Data collection &/or processing – M.K.; Analysis and/or interpretation – T.E.; Literature search – M.K.; Writing – M.K.; Critical review – T.E.

#### References

- Buchbinder R, Blyth FM, March LM, Brooks P, Woolf AD, Hoy DG. Placing the global burden of low back pain in context. *Best Pract Res Clin Rheumatol* 2013;27:575–89.
- Hoy D, Bain C, Williams G, March L, Brooks P, Blyth F, et al. A systematic review of the global prevalence of low back pain. *Arthritis Rheum* 2012;64:2028–37.
- Tarulli AW, Raynor EM. Lumbosacral radiculopathy. *Neurol Clin* 2007;25:387–405.
- Magalhaes FN, Dotta L, Sasse A, Teixeira MJ, Fonoff ET. Ozone therapy as a treatment for low back pain secondary to herniated disc: a systematic review and meta-analysis of randomized controlled trials. *Pain Physician* 2012;15:E115–29.
- Steppan J, Meaders T, Muto M, Murphy KJ. A metaanalysis of the effectiveness and safety of ozone treatments for herniated lumbar discs. *J Vasc Interv Radiol* 2010;21:534–48.
- Giurazza F, Guarnieri G, Murphy KJ, Muto M. Intradiscal O2O3: Rationale, Injection Technique, Short- and Long-term Outcomes for the Treatment of Low Back Pain Due to Disc Herniation. *Can Assoc Radiol J* 2017;68:171–7.
- Murphy K, Elias G, Steppan J, Boxley C, Balagurunathan K, Victor X, et al. Percutaneous Treatment of Herniated Lumbar Discs with Ozone: Investigation of the Mechanisms of Action. *J Vasc Interv Radiol* 2016;27:1242–50.
- Muto M, Ambrosiano G, Guarnieri G, Capobianco E, Piccolo G, Annunziata G, et al. Low back pain and sciatica: treatment with intradiscal-intraforaminal O(2)-O (3) injection. Our experience. *Radiol Med* 2008;113:695–706.
- Gallucci M, Limbucci N, Zugaro L, Barile A, Stavroulis E, Ricci A, et al. Sciatica: treatment with intradiscal and intraforaminal injections of steroid and oxygen-ozone versus steroid only. *Radiology* 2007;242:907–13.
- Buric J, Rigobello L, Hooper D. Five and ten year follow-up on intradiscal ozone injection for disc herniation. *Int J Spine Surg* 2014;8.
- Zhang Y, Ma Y, Jiang J, Ding T, Wang J. Treatment of the lumbar disc herniation with intradiscal and intraforaminal injection of oxygen-ozone. *J Back Musculoskelet Rehabil* 2013;26:317–22.
- Muto M, Andreula C, Leonardi M. Treatment of herniated lumbar disc by intradiscal and intraforaminal oxygen-ozone (O2-O3) injection. *J Neuroradiol* 2004;31:183–9.
- Paoloni M, Di Sante L, Cacchio A, Apuzzo D, Marotta S, Razzano M, et al. Intramuscular oxygen-ozone therapy in the treatment of acute back pain with lumbar disc herniation: a multicenter, randomized, double-blind, clinical trial of active and simulated lumbar paravertebral injection. *Spine (Phila Pa 1976)* 2009;34:1337–44.
- Oder B, Loewe M, Reisegger M, Lang W, Ilias W, Thurnher SA. CT-guided ozone/steroid therapy for the treatment of degenerative spinal disease-effect of age, gender, disc pathology and multi-segmental changes. *Neuroradiology* 2008;50:777–85.
- Ozcan S, Muz A, Yildiz Altun A, Onal SA. Intradiscal ozone therapy for lumbar disc herniation. *Cell Mol Biol (Noisy-le-grand)* 2018;64:52–5.
- Lo Giudice G, Valdi F, Gismondi M, Prosdocimo G, de Belvis V. Acute bilateral vitreo-retinal hemorrhages following oxygen-ozone therapy for lumbar disk herniation. *Am J Ophthalmol* 2004;138:175–7.
- Devetag Chalaupka F, Caneve G, Mauri M, Zaiotti G. Thunderclap headache caused by minimally invasive medical procedures: description of 2 cases. *Headache* 2007;47:293–5.
- Ginanneschi F, Cervelli C, Milani P, Rossi A. Ventral and dorsal root injury after oxygen-ozone therapy for lumbar disk herniation. *Surg Neurol* 2006;66:619–20.
- Corea F, Amici S, Murgia N, Tambasco N. A case of vertebrasilar stroke during oxygen-ozone therapy. *J Stroke Cerebrovasc Dis* 2004;13:259–61.
- Vanni D, Galzio R, Kazakova A, Pantalone A, Sparvieri A, Salini V, et al. Intraforaminal ozone therapy and particular side effects: preliminary results and early warning. *Acta Neurochir (Wien)* 2016;158:991–3.
- Gazzeri R, Galarza M, Neroni M, Esposito S, Alfieri A. Fulminating septicemia secondary to oxygen-ozone therapy for lumbar disc herniation: case report. *Spine (Phila Pa 1976)* 2007;32:E121–3.