

# ROLE OF MARROW-DERIVED MONOCYTES AND MESANGIAL CELLS IN REMOVAL OF IMMUNE COMPLEXES FROM RENAL GLOMERULI\*

BY GARY E. STRIKER, MART MANNIK, AND MILLIE Y. TUNG

*From the Departments of Pathology and Medicine, University of Washington, Seattle, Washington 98195*

Intravenously administered antigen-antibody complexes or protein aggregates localize in the glomerular mesangium. The mechanism of removal of these deposited substances has been difficult to study. Based on observations that particulates such as ferritin (1) and silver-protein aggregates (2) were found within lysosomes, mesangial cells were concluded to be phagocytic and therefore to participate in the clearing of immune complexes and aggregated IgG from the mesangium. In studies with injection of preformed immune complexes, some of the complexes deposited in glomeruli appeared to be taken up by monocytes rather than mesangial cells (3, 4). Resolution of this issue is clouded by the fact that differentiation between resident and infiltrating cells on purely morphologic grounds is not possible for the majority of cells in the mesangium. The observation that peripheral monocytes are capable of division in local sites of inflammation (5, 6) suggests that studies utilizing labeled bone marrow cells or cross-transplantation of kidneys shortly after pulse labeling may be difficult to interpret.

For these reasons, we chose to study the Chediak-Higashi (CH)<sup>1</sup> mouse; and thereby take advantage of their characteristic giant lysosomes as a marker which is visible by both light and electron microscopy.

In this study we found that CH mice cleared immune complexes normally and their mesangial cells did not contain large lysosomes in the resting state. By examining glomeruli in marrow cross-transplanted CH and C57BL/6J mice we found that after induction of glomerulonephritis with preformed immune complex administration, many of the cells in the glomeruli were marrow derived. The same marrow derived cells contained morphologically defined immune complexes, whereas resident mesangial cells did not. We therefore conclude that mesangial cells do not make a significant contribution to the phagocytic removal of immune complexes from the mesangial matrix.

## Materials and Methods

*Marrow Transplantation.* Normal C57BL/6J and the syngeneic CH (beige C57BL/6(bg/bg)) mice were obtained from the breeding colony maintained at the University of Washington by Doctors N. Wolf and E. Chi. 2-mo-old female and male mice were used for marrow transplantation or administration of immune complexes.

\* Supported by Research grants HL 03175 from the National Heart and Lung Institute and AM 11476 from the National Institute of Arthritis, Metabolism, and Digestive Diseases and the Henderson Fund.

<sup>1</sup> Abbreviation used in this paper: CH, Chediak-Higashi.

Mice to be transplanted were given 700 rads of total body irradiation over a 10-min period, and within 2 h  $6 \times 10^6$  nucleated bone marrow cells were given intravenously. The marrow cells were aspirated from donor femurs. C57BL/6J mice received marrow from CH mice and CH mice received marrow from C57BL/6J mice.

All animals received 5 mg streptomycin subcutaneously for 10 days after transplantation. Graft survival was established by finding of adequate neutrophils on serial peripheral blood smears. The presence of neutrophils with giant lysosomes confirmed the engraftment of CH marrow in C57BL/6J mice. The marrow-transplanted mice were used in further experiments 14–21 days after transplantation.

*Preparation and Studies with Immune Complexes.* Rabbit antibodies to human serum albumin were isolated with affinity chromatography, trace-labeled with  $^{125}\text{I}$ , and rendered monomeric as previously described (7). Portions of antibodies were reduced with 0.1 M 2-mercaptoethanol and alkylated with 0.11 M iodoacetamide (8). Monomers of human serum albumin were obtained by gel filtration (9). The point of equivalence was determined for each antibody preparation by quantitative precipitin curves, immune complexes were prepared at fivefold antigen excess, and the preparations were centrifuged at 1,000 *g* for 20 min before injections.

Each mouse was injected with 0.5 ml vol of immune complexes, containing 5.0 mg of antibodies. Serial 10- $\mu\text{l}$  samples of blood were obtained from the retro-orbital venous plexus, the radioactivity was determined and analyzed as previously described (9) to construct blood disappearance curves of the injected immune complexes.

*Immunofluorescence and Electron Microscopic Studies on Kidneys.* The kidneys were removed from anesthetized mice after exsanguination. The tissues were processed and examined by transmission electron microscopy and immunofluorescence microscopy as previously described (4). Fluorescein-conjugated goat antibodies specific for rabbit IgG were employed to detect the presence of rabbit IgG in immune complex deposits in glomeruli. The intensity of immunofluorescent staining in glomeruli was graded from 0 to 4+. A minimum of six glomeruli were examined by electron microscopy from each specimen. Kidney specimens, 24 and 96 h after injection of immune complexes, were chosen for detailed observations to allow mesangial localization of immune complexes and progression of cellular changes as previously described (4). Kidneys from two mice were examined from each experimental group at both time intervals by electron microscopy and immunofluorescence microscopy.

## Results

*Disappearance Kinetics of Soluble Immune Complexes in CH Mice and Cross-Transplanted Mice.* Since the CH mice are known to have decreased intracellular bacterial killing and decreased uptake and degradation of soluble foreign proteins (10, 11), disappearance of preformed immune complexes from the circulation was examined, using intact or reduced and alkylated antibodies. Groups of four CH mice were injected with preformed immune complexes, containing 5.0 mg of intact antibodies or 5.0 mg reduced and alkylated antibodies. The disappearance curves of blood radioactivity were not significantly different from the disappearance curves in normal C57BL/6J mice (9), indicating that with the large, saturating dose of immune complexes no abnormalities existed in the CH mice for hepatic uptake of immune complexes.

Similar experiments were carried out with the irradiated, marrow-transplanted mice. Seven C57BL/6J mice with CH marrow received immune complexes containing 5.0 mg of intact antibodies. Two mice were sacrificed at 24 h for microscopic studies, and five mice were followed to 96 h. No significant difference was observed in the disappearance of blood radioactivity between these transplanted mice and a control group of four C57BL/6J mice (Fig. 1). Four comparable transplanted mice received immune complexes containing 5.0 mg of reduced and alkylated antibodies. Two mice were sacrificed at 24 h for microscopic studies, two mice were followed to 96 h. The disappearance of blood radioactivity did not significantly differ in this group from a

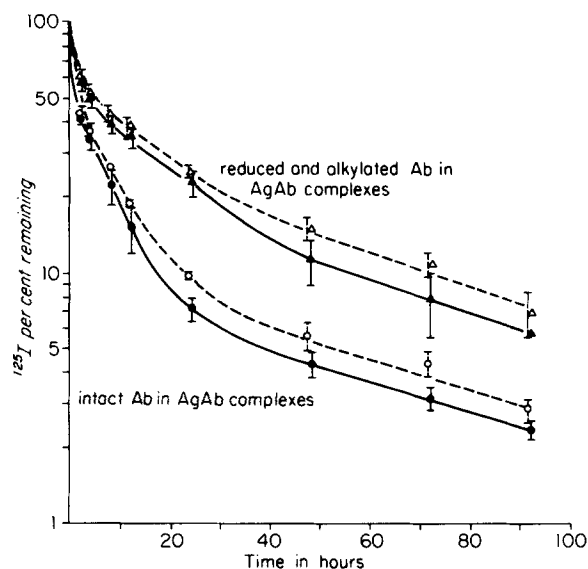


FIG. 1. Disappearance curves of immune complexes in C57BL/6J mice with CH marrow and in normal C57BL/6J mice. Immune complexes were prepared with radioiodinated intact antibodies or with radioiodinated reduced and alkylated antibodies. The  $\pm 1$  SD range is indicated for each bleeding, the results for transplanted mice are given in solid lines and for control mice in dashed lines. No significant differences were observed between the experimental and control mice.

group of four normal C57BL/6J mice given the same preparation of immune complexes (Fig. 1). The  $\pm 1$  SD range was higher in the experimental group because only two mice were followed to 96 h.

Seven CH mice with C57BL/6J marrow received immune complexes containing 5.0 mg intact antibodies; two of these mice were sacrificed at 24 h for microscopic studies and two mice were followed to 96 h. This group of mice had lost weight and were obviously sick since irradiation and transplantation. During the 1st h the rapid decrease of radioactivity from the blood was significantly slower ( $P < 0.005$ ) than in normal mice given the same preparation of immune complexes. During the later bleedings, however, the disappearance of blood radioactivity was not significantly different from normal mice. Four comparable transplanted mice received immune complexes containing 5.0 mg of reduced and alkylated antibodies, two mice were sacrificed at 24 h for microscopic studies, and two were followed to 96 h. The disappearance of blood radioactivity did not significantly differ from a group of four normal mice given the same preparation of immune complexes.

**Immunofluorescence Microscopy.** In irradiated, marrow-transplanted mice of both experimental groups, the kidneys were examined by immunofluorescence microscopy at 24 and 96 h, using a fluoresceinated goat antiserum specific for rabbit IgG, to evaluate the extent and persistence of deposition of immune complexes. As previously reported (4) in normal C57BL/6J mice, the deposition of immune complexes prepared with intact antibodies increased through 12 h and declined already by 24 h, leaving only a trace or 1+ deposits by 96 h. In contrast, after the injection of immune complexes with reduced and alkylated antibodies, the glomerular deposits were more intense and persisted through 96 h. The data on marrow-transplanted mice are

TABLE I  
*Intensity\* of Glomerular Deposits of Rabbit IgG in Marrow-Transplanted Mice after Administration of Immune Complexes*

Mice	Administered immune complexes‡	Glomerular deposition of rabbit IgG	
		24 h	96 h
C57BL/6J with CH marrow	AgAb	1-2+§	1-2+
	AgAb(RA)	4+	3-4+
CH with C57BL/6J marrow	AgAb	2+	1-2+
	AgAb(RA)	4+§	3-4+
C57BL/6J mice	AgAb	1-2+	tr-1+
	AgAb(RA)	4+	2-4+

\* The intensity of fluorescence was graded from negative to 4+. Two mice were examined in each experimental group at both time intervals.

‡ AgAb designates immune complexes prepared with intact antibodies and AgAb(RA) designates immune complexes prepared with reduced and alkylated antibodies.

§ Illustrated in Fig. 2.

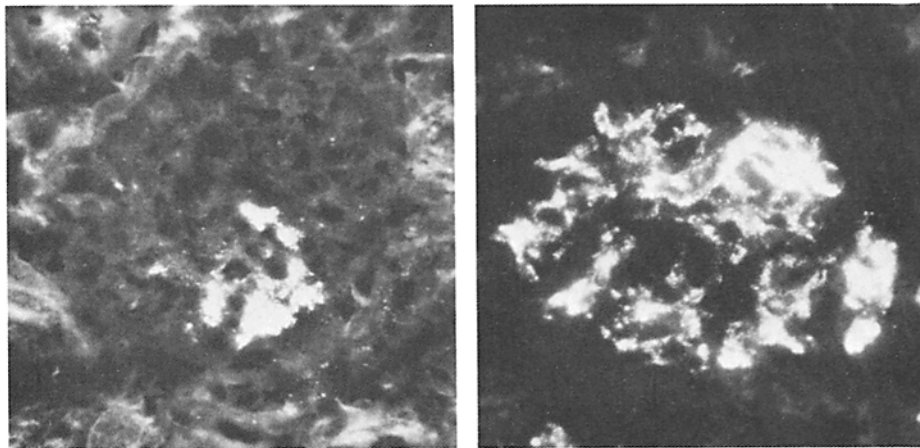


FIG. 2. Glomerular deposition of rabbit IgG in administered immune complexes by immunofluorescence microscopy. On the left 2+ glomerular deposits are illustrated in a C57BL/6J mouse with CH marrow, 24 h after the administration of immune complexes prepared with intact antibodies. On the right, 4+ glomerular deposits are illustrated in a CH mouse with C57BL/6J marrow, 24 h after the administration of immune complexes prepared with reduced and alkylated antibodies.

summarized in Table I and illustrated in Fig. 2. The degree of glomerular deposition of the injected complexes did not differ significantly in the marrow transplanted mice at 24 and at 96 h, as compared to normal C57BL/6J mice.

*Electron Microscopy.* The glomeruli of C57BL/6J mice with CH marrow at 24 h after injection of immune complexes showed electron dense deposits sparsely scattered throughout the mesangial matrix. The number of cells in the mesangial area was increased. Some cells in this area had giant lysosomes, whereas the mesangial cells, identified by the presence of subplasmalemmal microfilaments and peripheral dense bodies (12), did not contain the large lysosomes. By 96 h scattered electron dense deposits remained in the mesangial area.

When similarly transplanted mice received immune complexes with reduced and alkylated antibodies, abundant electron dense deposits were noted in the mesangial matrix at 24 h and decreased somewhat by 96 h. At 24 h increased cellularity was present in mesangial area. Many glomeruli contained 5 to 10 cells with giant lysosomes in the mesangial areas (Fig. 3A). By 96 h the number of cells in the mesangial area with giant lysosomes had decreased. Furthermore, at both time periods these cells contained electron dense deposits similar to the deposits in mesangial matrix (Fig. 3B). The cells with the morphological features of mesangial cells and without giant lysosomes contained no such electron dense deposits. The giant lysosomes were easily distinguishable from the immune deposits by the intensity and homogeneity of their staining as well as overall size. In addition material with the morphologic characteristics of immune deposits were never seen in uninjected mice.

The glomeruli of CH mice transplanted with C57BL/6J marrow at 24 h after injection of immune complexes showed electron dense deposits sparsely scattered throughout the mesangial matrix. The number of cells in the mesangial region was increased. No cells in this area had large lysosomes, in particular the cells with features of mesangial cells, did not contain large lysosomes. Abundant large lysosomes were, however, noted in endothelial cells, podocytes and proximal tubule epithelial cells. By 96 h the number of mesangial cells appeared normal, but scattered electron dense deposits remained in the mesangial matrix.

When similarly transplanted mice received immune complexes with reduced and alkylated antibodies, abundant electron dense deposits were noted in the mesangial matrix at 24 h and decreased somewhat by 96 h. No cells with the large lysosomes were seen in the mesangial area. Electron dense material comparable to the deposits in the mesangial matrix was found in the phagolysosomes of some cells, but these cells did not contain large lysosomes and had no morphological features of mesangial cells (Fig. 4).

The lack of giant lysosomes in mesangial cells of CH mice with C57BL/6J marrow after injection of immune complexes indicates that mesangial cells do not acquire lysosomes, either giant or phagocytic, as a result of a stimulus sufficient to induce morphologic evidence of phagocytosis in neutrophils or cells belonging to the mononuclear phagocyte system.

The glomeruli of control CH mice contained giant lysosomes in the cytoplasm of podocytes and endothelial cells. Giant lysosomes were not found in mesangial cells of these mice, varying in age from newborn to 9 mo old mice.

### Discussion

Removal of material from the mesangium has been postulated to occur by extracellular channels and by mesangial cell phagocytosis (13-16). Immune complex nephritis induced by administration of immune complexes suggested that phagocytosis by mesangial cells was not a common event in the early phases of the nephritis (3, 4). Because of the difficulty in differentiating between macrophages or other mononuclear cells which infiltrate the mesangium and resident mesangial cells in the presence of glomerulonephritis, the cell type(s) responsible for ingestion of the immune complexes could not be conclusively determined. The use of a specific cell marker which would not be altered during an inflammatory response was needed. The CH mouse was chosen for this reason. Even though CH inflammatory cells have abnormal

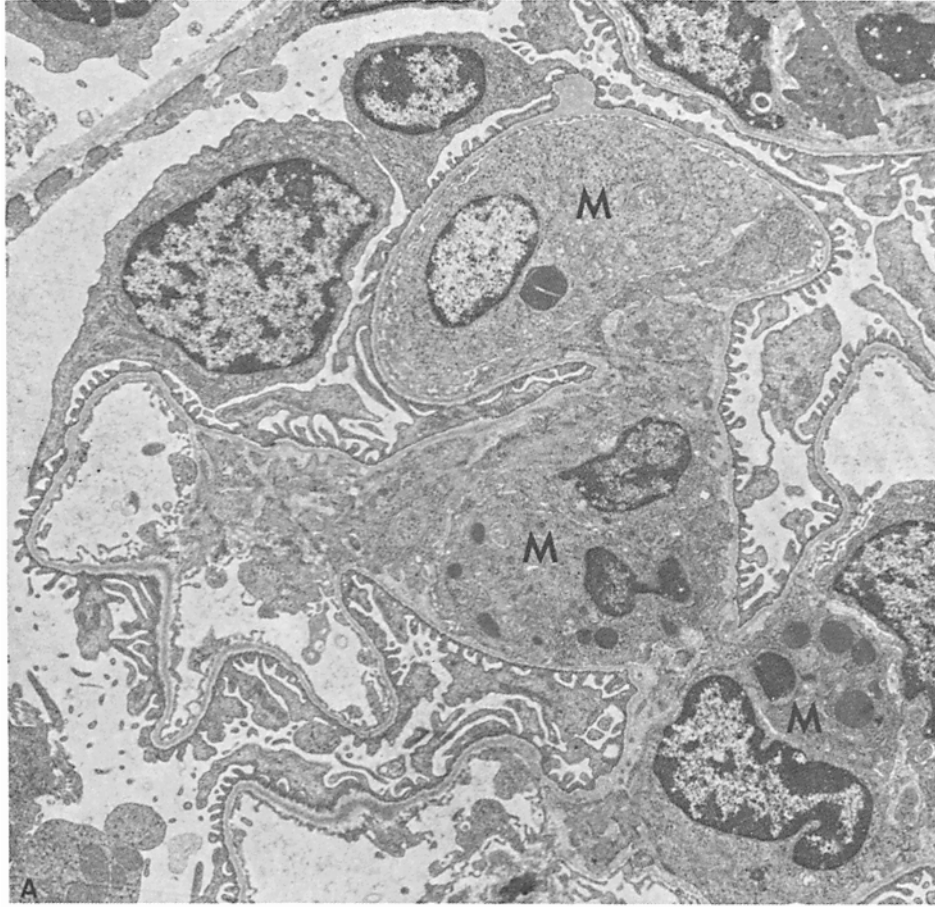


FIG. 3. Electron micrographs of glomeruli from mice 24 h after receiving 5 mg of immune complexes prepared with reduced and alkylated antibodies. These C57BL/6J mice received a CH marrow graft. The glomerular hypercellularity was restricted to the mesangial regions. Many cells in the mesangium contained giant lysosomes, indicating they derive from the marrow graft. A monocyte in the lumen (M) and two in the mesangium contain giant lysosomes indicating they derive from the marrow graft (Fig. 3A). Intracellular electron dense deposits of immune complexes (small arrow) are restricted to cells with giant lysosomes (large arrows) (Fig. 3B).

lysosomes they appear to have near normal phagocytosis and the large lysosomal granules persist in cells that arrive in areas of induced inflammation (18).

The presented data demonstrate that the marrow-derived monocytes contribute to the mesangial hypercellularity resulting from glomerular deposition of immune complexes. The data also provide evidence that the marrow-derived monocytes are involved in removal of deposited immune complexes from glomeruli by phagocytosis and that the mesangial cells do not phagocytize immune complexes deposited in the mesangial matrix. To reach this conclusion, we first observed that the large lysosomes are not seen in unstimulated CH mesangial cells whereas they are seen in other phagocytic cells of these mice. Second, we determined that the large lysosomes in CH mice are distinguishable by electron microscopy from the electron dense deposits that result from the ingestion of immune complexes. Third, in the CH mice with C57BL/

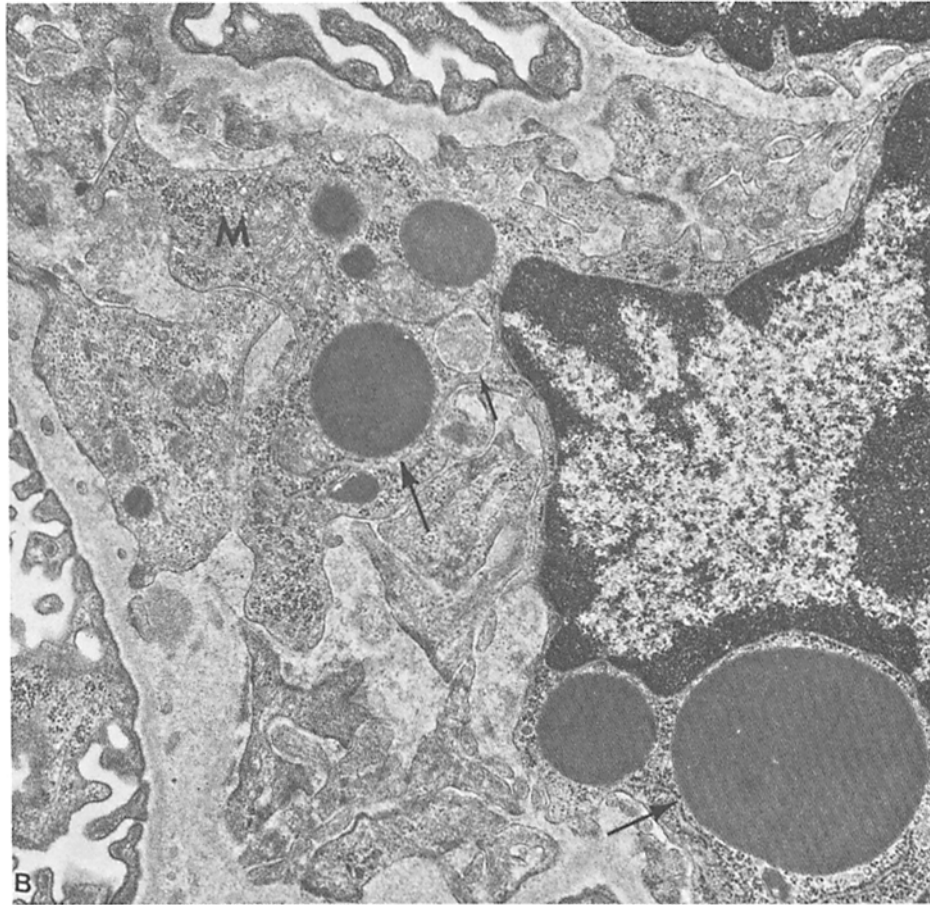


FIG. 3B.

6J marrow, cells with giant lysosomes were not seen in the mesangial area, indicating that the injection of immune complexes did not alter resident cells. In these mice the cells that contained the deposits after injection of immune complexes did not have giant lysosomes, suggesting that they originate from the marrow. Fourth, in C57BL/6J mice with CH marrow immune complexes were seen only in cells which had giant lysosomes, indicating that the phagocytic cells in the mesangium were marrow derived. Finally, the foregoing conclusions, based on morphological evidence of phagocytosis of immune complexes, do not exclude the participation of mesangial cells in the disposal of deposited immune complexes in the mesangial matrix by some other yet unrecognized mechanism. It is unlikely that the marrow-derived monocytes with injected immune complexes arrive in glomeruli after phagocytosis of these substances in the circulation, since the deposits of immune complexes were observed before increased cellularity in the mesangial matrix (4). In addition, monocytes were commonly recognized in the glomerular capillaries and while they contained giant lysosomes in CH mice, ingested immune complexes were never seen in these cells.

The fact that the clearance kinetics and mesangial localization of immune complexes in all groups were essentially identical to those of untransplanted C57BL/6J

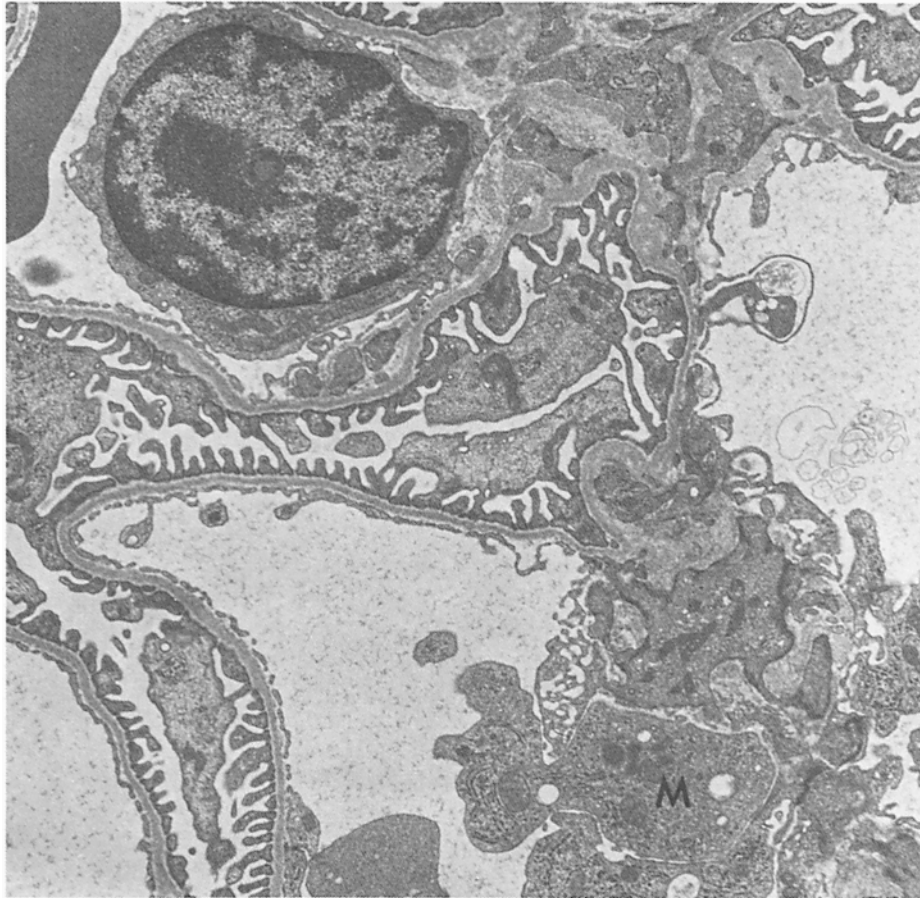

FIG. 4. Electron micrograph of a glomerulus from a CH mouse with a C57BL/6J marrow graft 24 h after receiving 5 mg of immune complexes prepared with reduced and alkylated antibodies. The mesangial region contains an increased number of cells, none of which contain giant lysosomes, resembling monocytes (M) suggesting they are derived from the marrow graft.

mice (4) suggests that the employed model has not introduced artifacts.

The role that the mesangial localization of monocytes might play in the mediation of glomerular injury is not addressed by these experiments. Schreiner et al. (19), however, recently demonstrated that monocytes contribute to the induction of proteinuria in nephrotoxic serum nephritis in the rat. As suggested by Bhan et al. (20) it is tempting to speculate that monocytes might have pathogenic significance in the model used in this study since the inflammatory response is primarily monocytic. The fact that monocytes accumulate in the mesangial region in the greatest number in response to the injection of immune complexes prepared with reduced and alkylated antibodies, supports the postulate that monocytes may be present principally because of their scavenger function (19). The deposited complexes must have caused the generation of chemotactic activity, most likely through participation of the mouse complement system, because C3 deposits were identified in glomeruli after injection of complexes prepared with reduced and alkylated antibodies (4). Fewer monocytes were present when immune complexes with intact antibodies were injected. This may



be a function of the enhanced hepatic uptake and consequent decreased glomerular deposition of large-latticed immune complexes or the brevity of stay of these complexes in the mesangium. The traffic of marrow-derived monocytes through the glomeruli was not quantified in this study, but the number of cells with giant lysosomes decreased by 96 h. The mode of exit or subsequent fate of these monocytes has not been established at this time. Furthermore the conclusion that marrow derived cells phagocytize immune complexes in the glomerular mesangium does not exclude other mechanisms in the overall removal of these materials from the glomeruli.

### Summary

Phagocytosis of intravenously administered immune complexes by cells in the mesangium was investigated. The model used was that of exchange marrow transplantation between Chediak-Higashi (CH) mice and syngeneic partners after X-irradiation. This model was chosen since marrow-derived macrophages could be differentiated from resident mesangial cells by the presence of the characteristic giant lysosomes in phagocytic cells of the CH mice. Injected immune complexes were cleared normally and localized in the glomerular mesangium in CH or C57BL/6J mice receiving either C57BL/6J or CH marrow. C57BL/6J mice with CH marrow injected with immune complexes prepared with reduced and alkylated antibodies accumulated many cells within the mesangium that contained both giant lysosomes and electron dense deposits. Deposits were not found in cells with subplasmalemmal microfilaments and peripheral dense bodies. Conversely, the cells in the mesangium of CH mice with C57BL/6J marrow that contained electron dense deposits were devoid of giant lysosomes. Based on these observations, we concluded that (a) marrow-derived monocytes contribute to mesangial hypercellularity after deposition of immune complexes and (b) phagocytosis of immune complexes localized in the glomerular mesangium was by marrow-derived monocytes rather than by mesangial cells.

We thank Greg Priestly, Richard Newton, and Isa Werny for their technical assistance and Doctors Emil Chi and Norman Wolf for advice.

*Received for publication 14 June 1978.*

### References

1. Farquhar, M. G., and G. E. Palade. 1962. Functional evidence for the existence of a third cell type in the renal glomerulus. Phagocytosis of filtration residues by a distinctive "third" cell. *J. Cell. Biol.* **13**:55.
2. Striker, G. E., and E. A. Smuckler. 1970. An ultrastructural study of glomerular basement membrane (GBM) synthesis. *Am. J. Pathol.* **58**:3.
3. Okumura, K., Y. Kondo, and T. Tada. 1971. Studies on passive serum sickness. I. The glomerular fine structure of serum sickness nephritis induced by preformed antigen-antibody complexes in the mouse. *Lab. Invest.* **24**:383.
4. Haakenstad, A. O., G. E. Striker, and M. Mannik. 1976. The glomerular deposition of soluble immune complexes prepared with reduced and alkylated antibodies and with intact antibodies in mice. *Lab. Invest.* **35**:293.
5. Evans, M. J., L. J. Cabral, R. J. Stephens, and G. Freeman. 1973. Cell division of alveolar macrophages in rat lung following exposure to NO<sub>2</sub>. *Am. J. Pathol.* **70**:199.
6. Dannenberg, A. M., M. Ando, K. Shima, and T. Tsuda. 1975. Macrophage turnover and

- activation in tuberculous granulomata. In *Mononuclear Phagocytes*. R. Van Furth, editor. Blackwell Scientific Publications, Oxford. 959-978.
7. Mannik, M., W. P. Arend, A. P. Hall, and B. C. Gilliland. 1971. Studies on antigen-antibody complexes. I. Elimination of soluble complexes from rabbit circulation. *J. Exp. Med.* **133**:713.
  8. Fleischman, J. B., R. H. Pain, and R. R. Porter. 1962. Reduction of  $\gamma$ -globulins. *Arch. Biochem. Biophys. Suppl.* **1**:174.
  9. Haakenstad, A. O., and M. Mannik. 1976. The disappearance kinetics of soluble immune complexes prepared with reduced and alkylated antibodies and with intact antibodies in mice. *Lab. Invest.* **35**:283.
  10. Root, R. K., A. S. Rosenthal, and D. J. Balestra. 1972. Abnormal bactericidal, metabolic and lysosome functions of Chediak-Higashi syndrome leukocytes. *J. Clin. Invest.* **51**:649.
  11. Lyons, R. T., and H. C. Pitot. 1978. Protein degradation in normal and beige (Chediak-Higashi) mice. *J. Clin. Invest.* **61**:260.
  12. Latta, H., A. B. Maunsback, and S. C. Madden. 1960. The centrolobular region of the renal glomerulus studied by electronmicroscopy. *J. Ultrastruct. Res.* **4**:455.
  13. Yamada, E. 1955. The fine structure of the renal glomerulus of the mouse. *J. Biophys. Biochem. Cytol.* **1**:551.
  14. Michael, A. F., A. J. Fish, and R. A. Good. 1967. Glomerular localization and transport of aggregated proteins in mice. *Lab. Invest.* **17**:14.
  15. Mauer, S. M., A. J. Fish, E. B. Blau, and A. F. Michael. 1972. The glomerular mesangium. I. Kinetic studies of macromolecular uptake in normal and nephrotic rats. *J. Clin. Invest.* **51**:1092.
  16. Elema, J. D., J. R. Hoyer, and R. L. Vernier. 1976. The glomerular mesangium: uptake and transport of intravenously injected colloidal carbon in rats. *Kidney Int.* **9**:395.
  17. Henson, J. B., J. R. Gorham, and Y. Tanaka. 1967. Renal glomerular ultrastructure in mink affected by Aleutian disease. *Lab. Invest.* **17**:123.
  18. Blume, R. S., and S. M. Wolff. 1972. The Chediak-Higashi syndrome: studies in four patients and a review of the literature. *Medicine (Baltimore)*. **51**:247.
  19. Schreiner, G. F., R. S. Cotran, V. Pardo, and E. R. Unanue. 1978. A mononuclear cell component in experimental immunological glomerulonephritis. *J. Exp. Med.* **147**:369.
  20. Bhan, A. K., E. E. Schneeberger, A. B. Collins, and R. T. McClusky. 1978. Evidence for a pathogenic role of a cell-mediated immune mechanism in experimental glomerulonephritis. *J. Exp. Med.* **148**:246.