



## CLINICAL INVESTIGATIVE STUDY

# Vagus nerve ultrasound in transthyretin familial amyloid polyneuropathy: A pilot study

Kang Du<sup>1</sup> | Ke Xu<sup>1</sup> | Xujun Chu<sup>1</sup> | Yuwei Tang<sup>1</sup> | He Lv<sup>1</sup> | Wei Zhang<sup>1</sup> |  
Zhaoxia Wang<sup>1,2</sup> | Yun Yuan<sup>1,2</sup> | Lingchao Meng<sup>1,2</sup>

<sup>1</sup> Department of Neurology, Peking University First Hospital, Beijing, China

<sup>2</sup> Beijing Key Laboratory of Neurovascular Disease Discovery, Peking University First Hospital, Beijing, China

## Correspondence

Lingchao Meng & Yun Yuan, Department of Neurology, Peking University First Hospital, 8 Xishiku St, Xicheng District, Beijing 100034, China.

Email: [lcMeng@bjmu.edu.cn](mailto:lcMeng@bjmu.edu.cn) & [yuanyun2002@126.com](mailto:yuanyun2002@126.com)

Kang Du and Ke Xu contributed equally to this work.

## Funding information

This study was supported by the Beijing Municipal Natural Science Foundation (No. 7194323).

## Abstract

**Background and Purpose:** Autonomic dysfunction is common in transthyretin familial amyloid polyneuropathy (TTR-FAP). Because ultrasonography is a powerful tool to study peripheral neuropathy, vagus nerve (VN) ultrasonography was used in our study to investigate the possible changes of the dimension of VN in TTR-FAP.

**Methods:** Eighteen patients with TTR-FAP and 17 age- and gender-matched individuals without any neuropathies were enrolled in a pilot study. The cross-sectional areas (CSAs) were measured bilaterally on transverse scans of vagus, median, and ulnar nerves. Clinical data were collected to explore the correlations with CSAs of VN.

**Results:** The median CSAs of VN in TTR-FAP were 3.5 (2.0-6.0) mm<sup>2</sup> on the right side and 2.5 (1.0-6.0) mm<sup>2</sup> on the left side, compared with 2.0 (1.0-3.0) mm<sup>2</sup> and 1.0 (1.0-2.0) mm<sup>2</sup> for healthy controls (HCs). There was a significant difference between the two groups on both sides ( $p < .001$ ). The mean VN CSAs were correlated positively with the course of disease ( $r = .7203, p = .0016$ ) (not including the patient with the longest disease course), the Composite Autonomic Symptom Score 31 ( $r = .5252, p = .0252$ ), the left ventricular posterior wall thickness ( $r = .5426, p = .0200$ ), and the interventricular septum thickness ( $r = .5103, p = .0305$ ). The cutoff values of right and left VN CSAs to identify TTR-FAP from HCs were 2.5 and 1.5 mm<sup>2</sup> and the areas under the curve were .9395 and .8856, with a high sensitivity (.889 and .889) and specificity (.941 and .765), respectively.

**Conclusion:** VN enlargement is prevalent among TTR-FAP patients. VN ultrasonography may be an important clinical tool for assessing the severity of autonomic dysfunction in TTR-FAP.

## KEYWORDS

CSA, transthyretin, TTR-FAP, ultrasonography, vagus nerve

## INTRODUCTION

Transthyretin familial amyloid polyneuropathy (TTR-FAP) is a multiple systemic disorder caused by *TTR* gene mutation and characterized by deposition of transthyretin-derived amyloid fibrils in peripheral nerves,

the heart, and other organs. Autonomic dysfunction is a common,<sup>1-4</sup> early, and distressing condition of TTR-FAP that impacts quality of life, morbidity, disease progression, and mortality of patients.<sup>5</sup> The autonomic neuropathies as initial symptoms struck 27.8% patients.<sup>1</sup> Once symptoms were present, their evolution was equivalent to the

This is an open access article under the terms of the [Creative Commons Attribution-NonCommercial-NoDerivs](https://creativecommons.org/licenses/by-nc-nd/4.0/) License, which permits use and distribution in any medium, provided the original work is properly cited, the use is non-commercial and no modifications or adaptations are made.

© 2021 The Authors. *Journal of Neuroimaging* published by Wiley Periodicals LLC on behalf of American Society of Neuroimaging



progression of the motor and sensory neuropathy. Although the clinical variability of TTR-FAP has been well characterized as neuropathies, cardiomyopathy, or mixed phenotype, the extent of autonomic involvement remains poorly understood.

Detection of autonomic neuropathy is critical to identifying TTR-FAP from adult-onset neuropathies, such as chronic inflammatory demyelinating polyneuropathy (CIDP) and diabetic peripheral neuropathy (DPN).<sup>6,7</sup> Because early differentiation of TTR-FAP from other peripheral neuropathies is of vital importance for early treatment, a number of studies related to detection of autonomic neuropathy have been performed for differential diagnosis, such as the eutectic mixture of local anesthetics test, laser Doppler flowmetry for vasomotor aspects,<sup>8</sup> the Sudoscan and Neuropad test for sudomotor aspects,<sup>9</sup> and skin biopsy.<sup>10</sup> However, these approaches are invasive, complicated, or expensive, thus limiting their applications in clinical practice.

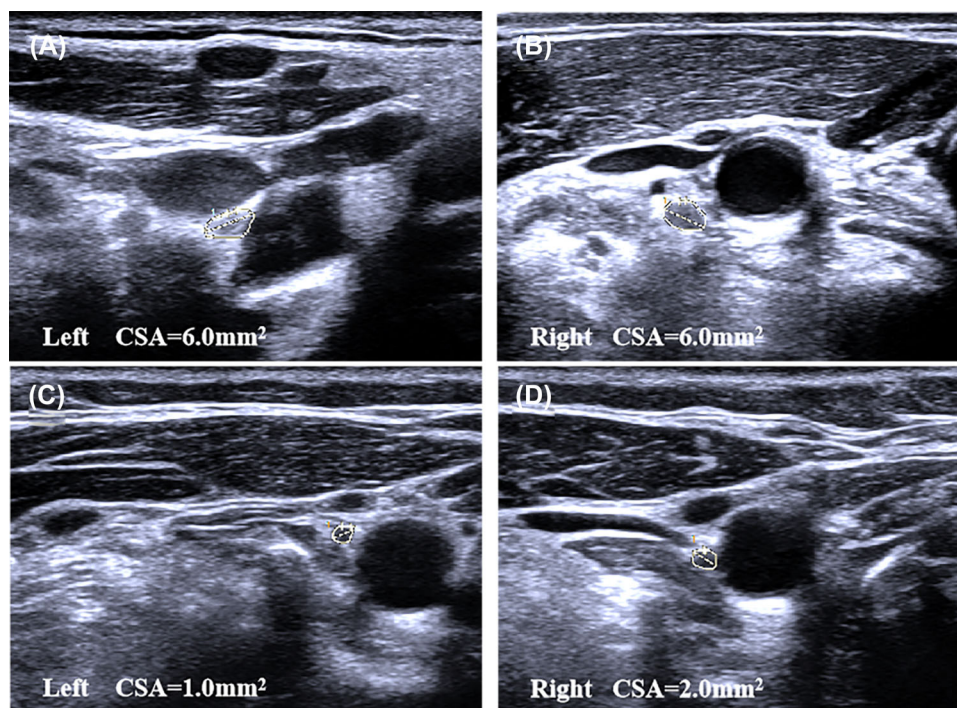
Nerve ultrasound is a painless tool for quick evaluation of peripheral nerve morphology. Previous ultrasound studies showed nerve enlargement in TTR-FAP, especially in the proximal segments of sensory and motor nerves.<sup>11,12</sup> Vagus nerve (VN) ultrasound has been studied in DPN,<sup>13</sup> CIDP,<sup>14,15</sup> multifocal motor neuropathy,<sup>16</sup> Charcot-Marie-Tooth Type 1A,<sup>14</sup> Charcot-Marie-Tooth Type 1B,<sup>17</sup> amyotrophic lateral sclerosis (ALS),<sup>18,19</sup> and Parkinson's disease.<sup>20</sup> Abnormalities of VN are observed in all aforementioned diseases except ALS. VN, containing 80% of the unmyelinated fibers in the mid-cervical area, is considered to be related to autonomic dysfunction.<sup>21</sup> Compared with other adult-onset neuropathies, autonomic dysfunction is more predominant in TTR-FAP. However, there has been no study on the VN ultrasound in

TTR-FAP so far. This study was intended to find out whether VN ultrasound may be a useful tool for evaluation of disease progression and an early sign of autonomic neuropathy in TTR-FAP.

## METHODS

### Subjects

Between June 2020 and October 2021, 18 patients (14 males and 4 females) with TTR-FAP and 17 age- and gender-matched healthy controls (HCs) (13 males and 4 females) were recruited in Peking University First Hospital. All TTR-FAP patients were diagnosed according to the diagnostic criteria.<sup>22</sup> The exclusion criteria of HCs were as follows: (1) skin numbness or paresthesia; (2) muscle atrophy or weakness; (3) other disorders of the peripheral nervous system; and (4) chronic diseases of other organs (eg, the heart, brain, eye, or kidney). The study was approved by the Ethics Committee of Peking University First Hospital. All participants provided written informed consent to participate in this study. All TTR-FAP patients with TTR gene mutations were inquired about their disease history and had a focused neurological examination and measurement scales performed, including the progressive course of disease, Coutinho stages (stage 0, no symptoms; stage I, unimpaired ambulation, mostly with mild sensory, motor, and autonomic neuropathy in the lower limbs; stage II, assistance for ambulation required, mostly with a moderate motor, sensory, and autonomic impairment of the four limbs; stage III,



**FIGURE 1** Examples of ultrasound cross-sections showing measurements of cross-sectional areas (CSAs) of vagus nerves between the two groups. (A, B) Bilateral enlargements of vagus nerves were observed in a transthyretin familial amyloid polyneuropathy patient. (C, D) The normal vagus nerve CSAs of a healthy control



wheelchair-bound or bedridden status with severe sensory, motor, and autonomic involvement of all limbs), Neuropathy Impairment Score (NIS), Norfolk Quality of Life-Diabetic Neuropathy Score (QOL-DN), and Composite Autonomic Symptom Score 31 (COMPASS 31). Cardiac parameters including serum N-terminal pro-brain natriuretic peptide (NT-pro BNP), interventricular septum thickness (IVST), and left ventricular posterior wall thickness (LVPWT) were collected.

## Ultrasonographic studies

All subjects, whose bilateral VNs were measured and recorded by using the Philips Imaging System (iU Elite, Bothell, WA, USA), underwent peripheral nerve ultrasound. To be more specific, the 10-MHz high-frequency linear array probe was used. The cross-sectional areas (CSAs) of bilateral VNs were measured by tracing just inside the hyperechoic rim of the nerve. The transducer was positioned transversely in the lateral neck, and the nerve was identified inside the carotid sheath between the internal jugular vein and carotid artery (Figure 1). The variability from side to side was defined as the “maximum CSA/minimum CSA”. The bilateral median and ulnar nerves

were also measured at 10 sites according to our previously described method.<sup>23</sup> The maximum CSA of median/ulnar nerves was defined as the maximum CSA of the 10 sites, and the mean CSA was the mean of the 10 sites.

## Statistical analysis

IBM SPSS Statistics, version 24, was used for statistical analysis. The CSAs of HCs and TTR-FAP showed an abnormal distribution (as evaluated by single sample *K-S* test). Thus, Mann-Whitney *U* test was used for evaluating differences in CSAs between TTR-FAP and HCs. Receiver operating characteristic (ROC) curve analysis was performed to evaluate the applicability of CSAs measurements to differentiation of TTR-FAP from HCs groups. The area under the curve (AUC) was calculated. The value of Youden index at its maximum was taken as the cut point for the diagnosis of TTR-FAP, and the sensitivity and specificity were calculated. Two-sided *p*-values were calculated for all analyses; *p* < .05 was considered significant. Spearman analysis was used to test the correlation between CSAs of VNs and other data.

**TABLE 1** Demographic and clinical characteristics of transthyretin familial amyloid polyneuropathy patients and healthy controls

	TTR-FAP			<i>p</i> -value	HCs	<i>p</i> -value
	Total, <i>n</i> = 18	Early-onset, <i>n</i> = 9	Late-onset, <i>n</i> = 9	Early-onset vs. late-onset	<i>n</i> = 17	Total TTR-FAP vs. HCs
Age at examination (years)	50.4 ± 11.7	43.0 ± 12.4	57.8 ± 4.2	.0035**	47.6 ± 12.8	.5182
Male, <i>n</i> (%)	14 (77.8)	7 (77.8)	7 (77.8)	>.9999	13 (76.5)	>.9999
Positive family history, <i>n</i> , (%)	13 (72.2)	9 (100.0)	4 (44.4)	.0294*	NA	
Coutinho stage I, <i>n</i> (%)	10 (55.6)	6 (66.7)	4 (44.4)	.6372	NA	
Duration of symptoms at examination, years, median (range)	2.75 (0.7, 5.0)	3.0 (0.7, 5)	1.5 (0.8, 4.0)	.6173	NA	
Height (m)	1.7 ± 0.07	1.7 ± 0.07	1.7 ± 0.08	>.9999	1.7 ± 0.7	.2537
Weight (Kg)	63.6 ± 9.7	66.1 ± 11.3	61.1 ± 7.8	.4201	66.5 ± 6.5	.2090
BMI (Kg/m <sup>2</sup> )	21.7 ± 2.7	22.1 ± 3.2	21.3 ± 2.1	>.9999	22.0 ± 1.1	.6538
Symptoms and signs						
SMPN, <i>n</i> (%)	18 (100.0)	9 (100.0)	9 (100.0)	>.9999	NA	
Dysautonomia, <i>n</i> (%)	17 (94.4)	8 (88.9)	9 (100.0)	>.9999	NA	
GI symptoms, <i>n</i> (%)	16 (88.9)	7 (77.8)	9 (100.0)	.4706	NA	
GU symptoms, <i>n</i> (%)	12 (66.7)	5 (55.6)	7 (77.8)	.6199	NA	
Postural dizziness, <i>n</i> (%)	12 (66.7)	5 (55.6)	7 (77.8)	.6199	NA	
Skin color changes, <i>n</i> (%)	8 (44.4)	4 (44.4)	4 (44.4)	>.9999		
Abnormal glandular secretion, <i>n</i> (%)	15 (83.3)	7 (77.8)	8 (88.9)	>.9999	NA	
Chronic cough, <i>n</i> (%)	8 (44.4)	5 (55.6)	3 (33.3)	.6372	NA	

Note: All the data represent mean ± standard deviation unless otherwise indicated.

Abbreviations: BMI, body mass index; GI, gastrointestinal; GU, genitourinary; HC, healthy control; *n*, numbers; NA, not available; SMPN, sensor-motor polyneuropathy.

\* and \*\* represent significant difference at .05 and .01 levels, respectively.



## RESULTS

### Clinical features of TTR-FAP

The mean age at which these TTR-FAP patients and HCs were examined was 50.4 years (29–64 years) and 47.6 years (26–68 years), respectively. There was no statistically significant difference in age ( $p = .5182$ ) or in the mean height, weight, and body mass index between the two groups (all  $ps > .05$ ) (Table 1).

Of the 18 TTR-FAP patients, 13 initially developed limb paresthesia, followed by other onset symptoms such as diarrhea and/or constipation in 2 patients, sexual dysfunction in 2 patients, and postural dizziness in 1 patient. All patients presented with sensorimotor polyneuropathy, and 17 (94.4%) of them developed autonomic neuropathy, including alternating diarrhea and/or constipation in 16 patients, sexual dysfunction or dysuria in 12 patients, postural dizziness in 12 patients, skin color changes in 8 patients, and abnormal sweating or xerostomia in 15 patients. Specifically, chronic cough was found in 8 patients (44.4%). Nine (50%) patients were early-onset patients (<50 years), and the rest were late-onset ones who were older at the time of examination than early-onset cases and had a lower rate of positive family history. However, there was no statistically significant difference in durations of disease between the early-onset and

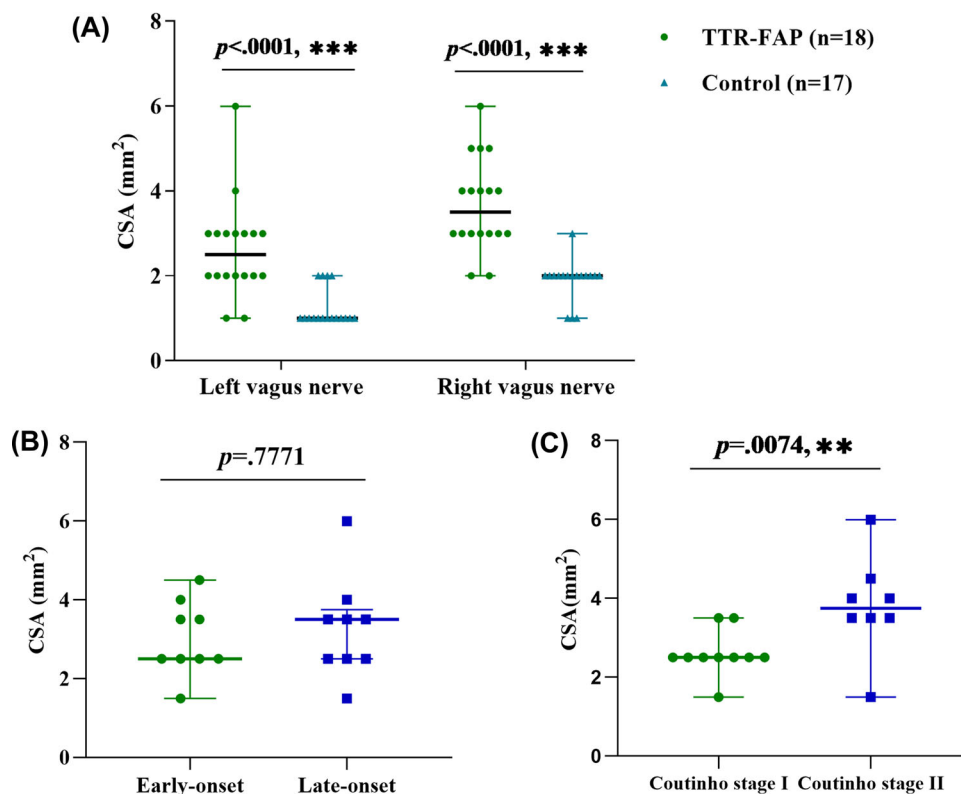
late-onset patients ( $p = .6173$ ). The two groups were not significantly different in autonomic dysfunction (all  $ps > .05$ ).

Different TTR mutations were identified by gene testing, including Val30Leu mutation in 3 patients, Gly83Arg, Lys35Asn, Val30Met, Glu61Lys, and Ala97Ser mutation in 2 patients, respectively, and Val30Ala, Glu42Gly, Ala36Pro, Phe33Val and Asp38Val mutation in 1 patient, respectively. In clinical staging, 10 of these patients were divided into Coutinho stage I, and the remaining into Coutinho stage II (Table 1).

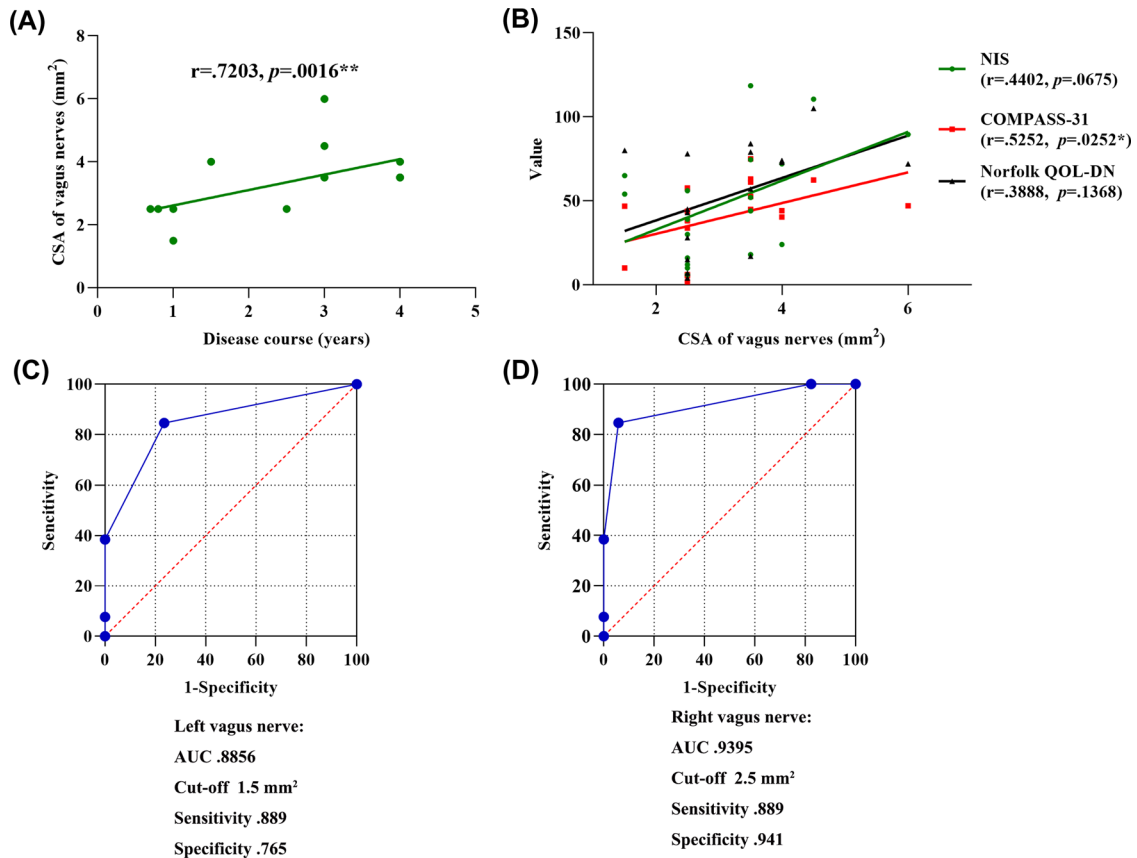
### Ultrasonographic findings

#### Comparison of VN CSAs between TTR-FAP and HCs

The median (range) CSAs of the bilateral VNs were 3.5 (2.0–6.0)  $\text{mm}^2$  (right) and 2.5 (1.0–6.0)  $\text{mm}^2$  (left) in TTR-FAP, and 2.0 (1.0–3.0)  $\text{mm}^2$  (right) and 1.0 (1.0–2.0)  $\text{mm}^2$  (left) in HCs, so there was a significant difference between the two groups (all  $ps < .0001$ ) (Figure 1). Furthermore, the median value of mean CSAs of bilateral VNs was higher in Coutinho stage II groups than in stage I groups (3.8 vs. 2.5  $\text{mm}^2$ ,  $p = .0074$ ). However, there was no significant difference between the early-onset and late-onset patients



**FIGURE 2** The cross-sectional areas (CSAs) of vagus nerves in transthyretin familial amyloid polyneuropathy (TTR-FAP) patients and controls. n, numbers. \*\* and \*\*\* represent significant difference at 0.01 and 0.001 levels, respectively



**FIGURE 3** Correlation and receiver operator characteristic curve analysis of vagus nerve cross-sectional areas (CSAs) in transthyretin familial amyloid polyneuropathy patients. AUC, area under curve; COMPASS 31, Composite Autonomic Symptom Score 31; NIS, Neuropathy Impairment Score; Norfolk QOL-DN, Norfolk Quality of Life-Diabetic Neuropathy Score. One patient of the longest course of disease was not included in the correlation between CSAs of vagus nerve and the course of disease. Norfolk QOL-DN data for two cases were not available. \* and \*\* represent significant correlation at 0.05 and 0.01 levels, respectively

( $p = .7771$ ) (Figure 2). The median variability of CSA from side to side was 1.5 (1.0-2.0) in TTR-FAP and 2.0 (1.0-2.0) in HCs, with no significant difference between TTR-FAP and HCs ( $p = .3125$ ).

### The ROC curves of VN CSAs for identifying TTR-FAP from HCs

Based on the results observed in Figure 2, the ROC curve of VN CSAs was used to differentiate between TTR-FAP and HCs. The cutoff value of right and left VN CSAs identified TTR-FAP from HCs were 2.5 and 1.5 mm<sup>2</sup> and the AUCs were .9395 and .8856, with a high sensitivity (.889 and .889) and specificity (.941 and .765), respectively (Figure 3).

### Correlation of mean VN CSAs with clinical measurement scales, cardiac parameters and CSAs of median/ulnar nerves of TTR-FAP

Correlation analysis was conducted between the mean CSAs of bilateral VNs and NIS, Norfolk QOL-DN, COMPASS 31, and duration of

disease of TTR-FAP patients. The mean VN CSAs were positively correlated with COMPASS 31 ( $r = .5252$ ,  $p = .0252$ ). It seemed that the larger CSA was accompanied by a longer disease course ( $r = .4457$ ,  $p = .0638$ ) except the longest disease course with a smaller CSA in 1 patient (Table 2). The correlation became stronger without the aforesaid patient ( $r = .7203$ ,  $p = .0016$ ) (Figure 3 and Table 2). Interestingly, mean VN CSAs were positively correlated with IVST ( $r = .5426$ ,  $p = .0200$ ) and LVPWT ( $r = .5103$ ,  $p = .0305$ ). However, mean VN CSAs were not correlated with Serum NT-pro BNP level, NIS, or Norfolk QOL-DN. Nor were mean VN CSAs correlated with either the maximum CSA or mean CSA of median/ulnar nerves (all  $ps > .05$ ) (Table 2).

### DISCUSSION

Our early study indicated that autonomic dysfunction was often observed before sensory and motor nerve dysfunction in TTR-FAP.<sup>1,2</sup> We found that autonomic dysfunction was not significantly different between early- and late-onset disease groups. Other studies indicated that early-onset patients displayed autonomic dysfunction more distinctively than late-onset ones. Most of the patients had a peripheral neuropathy with variable autonomic symptoms. We found that





**TABLE 2** Correlation analysis between mean vagus nerve cross-sectional areas (CSAs), clinical data, and CSAs of median/ulnar nerves of transthyretin familial amyloid polyneuropathy patients

Parameters	Mean VN CSAs
NIS	$r = .4402, p = .0675$
Norfolk QOL-DN	$r = .3888, p = .1368$
COMPASS 31	$r = .5252, p = .0252^*$
Course of disease	$r = .4457, p = .0638$
Course of disease <sup>a</sup>	$r = .7203, p = .0016^{**}$
Serum NT-pro BNP level <sup>b</sup>	$r = .3484, p = .1697$
IVST	$r = .5426, p = .0200^*$
LVPWT	$r = .5103, p = .0305^*$
Maximum CSA of median nerves	$r = .3854, p = .1142$
Maximum CSA of ulnar nerves	$r = .2453, p = .3264$
Mean CSA of median nerves	$r = .4445, p = .0645$
Mean CSA of ulnar nerves	$r = .3696, p = .1312$

Abbreviations: COMPASS 31, Composite Autonomic Symptom Score 31; IVST, interventricular septum thickness; LVPWT, Left ventricular posterior wall thickness; NIS, Neuropathy Impairment Score; Norfolk QOL-DN, Norfolk Quality of Life-Diabetic Neuropathy Score; NT-pro BNP, N-terminal pro-brain natriuretic peptide.

<sup>a</sup>The data of one case with the longest course of disease (6 years) were excluded in the correlation analysis between CSAs and disease duration.

<sup>b</sup>The data of one case were not available.

\* and \*\* represent significant correlation at 0.05 and 0.01 levels, respectively.

94.4% of the patients manifested autonomic neuropathy. We also confirmed that autonomic disturbance was one of the red flags for TTR-FAP and that autonomic dysfunction was one of diagnostic hallmarks of TTR-FAP.<sup>4</sup>

In our study, the median VN CSAs in normal individuals were 2.0 mm<sup>2</sup> on the right side and 1.0 mm<sup>2</sup> on the left side, which was consistent with findings in another VN study.<sup>14</sup> The normal values of Americans could reach about 5 mm<sup>2</sup>, and about 1-2.5 mm<sup>2</sup> in Asians and Europeans.<sup>13,14,24</sup> However, the VN CSAs in HCs did not vary significantly between age, gender, height, weight, and races in adults according to a systematic review and meta-analysis.<sup>25</sup>

To the best of our knowledge, this was the first time VN hypertrophy in TTR-FAP patients had been demonstrated based on nerve ultrasound. The fact that no difference in VN hypertrophy was observed between the early-onset and late-onset groups further confirmed that mean VN CSAs in TTR-FAP were positively correlated with COMPASS31 scoring. However, mean VN CSAs were not correlated with NIS or Norfolk QOL-DN, suggesting that compared with the severity of sensorimotor neuropathy and life function, VN CSAs were only associated with the severity of autonomic nervous dysfunction. The association of mean VN CSAs with myocardial thickness might indicate the consistency of amyloid deposition in the heart and VN, but it needed to be further confirmed in future larger cohort studies. In our previous study, we found that some TTR-FAP patients developed sensorimotor neuropathy many years after their autonomic dysfunction,<sup>23</sup>

suggesting that the severity and progression of autonomic neuropathy and sensorimotor neuropathy might not be parallel, indicating that the progression of autonomic neuropathy followed its own pattern that could be better reflected by the CSAs of VN. Niu et al. found a correlation between the CSAs of VN and the maximum/mean CSAs of the median/ulnar nerves in CIDP and CMT1A,<sup>14</sup> which was different from the pattern in TTR-FAP. However, we did not find any correlation in our study, which offered more evidence that the enlargement of VN in TTR-FAP might have a different pathological mechanism from other peripheral neuropathies. Our study found that the CSAs of VN were positively correlated with the course of disease if the patient with the longest course of disease was excluded. It seemed that in the early stage of TTR-FAP, VN increased in size with the prolongation of the course of disease, and then decreased in size in the later stage of the disease. However, because of the limited number of cases, we could not reach a definitive conclusion. What we could do was to recommend VN ultrasound as a monitoring index for the progression of TTR-FAP autonomic neuropathy.

Nerve ultrasound, as a noninvasive examination tool, was of great significance for the differential diagnosis of different types of diseases. Patients of late-onset and sporadic TTR-FAP were easily misdiagnosed as CIDP, DPN, and other mimics.<sup>6</sup> The enlargement of peripheral nerves of limbs and atrophy of VN were observed in DPN,<sup>13,26</sup> which might be a distinctive trait by which to distinguish TTR-FAP from DPN. Enlargement of VN could be observed in both CIDP and TTR-FAP. However, our previous study explored the difference in nerve ultrasound between CIDP and TTR-FAP in median, ulnar, tibial, sciatic, peroneal, and sural nerves,<sup>23</sup> so we highlighted the difference in the pattern of nerve enlargement and CSA variability of median nerves between CIDP and TTR-FAP. There was no significant difference in the variability of bilateral VN CSAs between TTR-FAP patients and HCs, suggesting that TTR-FAP patients had relatively symmetrical VN involvement. Future cohort studies could compare the CSAs and the CSA variability of VN between TTR-FAP and CIDP.

This study has several limitations. The sample size of TTR-FAP patients is not big enough, so more subjects will be needed in the future. In addition, the mimics of TTR-FAP and asymptomatic carriers need to be compared with TTR-FAP patients.

In conclusion, VN enlargement is prevalent in TTR-FAP patients. VN ultrasound is a useful tool for evaluation of TTR-FAP.

## ACKNOWLEDGEMENTS AND DISCLOSURE

The authors thank all patients and normal controls for their assistance in this study. The authors declare no conflict of interest.

## ORCID

Kang Du  <https://orcid.org/0000-0002-3088-8552>

## REFERENCES

1. Du K, Li F, Wang H, et al. Hereditary transthyretin amyloidosis in mainland China: a unicentric retrospective study. *Ann Clin Transl Neurol* 2021;8:831-41.



2. Meng L-C, Lyu H, Zhang W, et al. Hereditary transthyretin amyloidosis in eight Chinese families. *Chin Med J* 2015;128:2902-5.
3. González-Duarte A, Barroso F, Mundayat R, et al. Blood pressure and orthostatic hypotension as measures of autonomic dysfunction in patients from the transthyretin amyloidosis outcomes survey (THAOS). *Auton Neurosci* 2019;222:102590.
4. Dohrn MF, Röcken C, Bleecker JL, et al. Diagnostic hallmarks and pitfalls in late-onset progressive transthyretin-related amyloid-neuropathy. *J Neurol* 2013;260:3093-108.
5. Chao H-C, Liao Y-C, Liu Y-T, et al. Clinical and genetic profiles of hereditary transthyretin amyloidosis in Taiwan. *Ann Clin Transl Neurol* 2019;6:913-22.
6. Cortese A, Vegezzi E, Lozza A, et al. Diagnostic challenges in hereditary transthyretin amyloidosis with polyneuropathy: avoiding misdiagnosis of a treatable hereditary neuropathy. *J Neurol Neurosurg Psychiatry* 2017;88:457-8.
7. Ohashi N, Kodaira M, Morita H, et al. Electrophysiological demyelinating features in hereditary ATTR amyloidosis. *Amyloid* 2019;26:15-23.
8. Zouari HG, Ng Wing Tin S, Wahab A, et al. Assessment of autonomic innervation of the foot in familial amyloid polyneuropathy. *Eur J Neurol* 2019;26:10-94.
9. Fortanier E, Delmont E, Verschueren A, et al. Quantitative sudomotor test helps differentiate transthyretin familial amyloid polyneuropathy from chronic inflammatory demyelinating polyneuropathy. *Clin Neurophysiol* 2020;131:1129-33.
10. Chao C-C, Hsueh H-W, Kan H-W, et al. Skin nerve pathology: biomarkers of premanifest and manifest amyloid neuropathy. *Ann Neurol* 2019;85:560-73.
11. Granata G, Luigetti M, Coraci D, et al. Ultrasound evaluation in transthyretin-related amyloid neuropathy. *Muscle Nerve* 2014;50:372-6.
12. Podnar S, Sarafov S, Tournev I, et al. Peripheral nerve ultrasonography in patients with transthyretin amyloidosis. *Clin Neurophysiol* 2017; 128:505-11.
13. Tawfik EA, Walker FO, Cartwright MS, et al. Diagnostic ultrasound of the vagus nerve in patients with diabetes. *J Neuroimaging* 2017;27:589-93.
14. Niu J, Zhang L, Ding Q, et al. Vagus nerve ultrasound in chronic inflammatory demyelinating polyradiculoneuropathy and Charcot-Marie-Tooth disease type 1A. *J Neuroimaging* 2020;30:910-6.
15. Jang JH, Cho CS, Yang K-S, et al. Pattern analysis of nerve enlargement using ultrasonography in chronic inflammatory demyelinating polyneuropathy. *Clin Neurophysiol* 2014;125:1893-9.
16. Grimm A, Décard BF, Athanasopoulou I, et al. Nerve ultrasound for differentiation between amyotrophic lateral sclerosis and multifocal motor neuropathy. *J Neurol* 2015;262:870-80.
17. Cartwright MS, Brown ME, Eulitt P, et al. Diagnostic nerve ultrasound in Charcot-Marie-Tooth disease type 1B. *Muscle Nerve* 2009; 40:98-102.
18. Holzapfel K, Naumann M. Ultrasound detection of vagus nerve atrophy in bulbar amyotrophic lateral sclerosis. *J Neuroimaging* 2020;30:762-5.
19. Grimm A, Thomaser A-L, Peters N, et al. Neurological picture. Vagal hypertrophy in immune-mediated neuropathy visualised with high-resolution ultrasound (HR-US). *J Neurol Neurosurg Psychiatry* 2015;86:1277-8.
20. Pelz JO, Belau E, Fricke C, et al. Axonal degeneration of the vagus nerve in Parkinson's disease-A High-Resolution ultrasound study. *Front Neurol* 2018;9:951.
21. Prechtel JC, Powley TL. The fiber composition of the abdominal vagus of the rat. *Anat Embryol* 1990;181:101-15.
22. Adams D, Ando Y, Beirão JM, et al. Expert consensus recommendations to improve diagnosis of ATTR amyloidosis with polyneuropathy. *J Neurol* 2020;268:2109-22.
23. Du K, Xu K, Cheng S, et al. Nerve ultrasound comparison between transthyretin familial amyloid polyneuropathy and chronic inflammatory demyelinating polyneuropathy. *Front Neurol* 2021;12:632096.
24. Cartwright MS, Passmore LV, Yoon J-S, et al. Cross-sectional area reference values for nerve ultrasonography. *Muscle Nerve* 2008;37: 566-71.
25. Fisse AL, Katsanos AH, Gold R, et al. Cross-sectional area reference values for peripheral nerve ultrasound in adults: a systematic review and meta-analysis-Part III: cervical nerve roots and vagal nerve. *Eur J Neurol* 2021;28:2319-26.
26. Narayan S, Goel A, Singh AK, et al. High resolution ultrasonography of peripheral nerves in diabetic patients to evaluate nerve cross sectional area with clinical profile. *Br J Radiol* 2021;94:20200173.

**How to cite this article:** Du K, Xu K, Chu X, et al. Vagus nerve ultrasound in transthyretin familial amyloid polyneuropathy: A pilot study. *J Neuroimaging*. 2022;32:285–291.  
<https://doi.org/10.1111/jon.12956>