

Synchronous endometrial adenocarcinoma and carcinosarcoma in endometrial polyp

SAGE Open Medical Case Reports
Volume 6: 1–5
© The Author(s) 2018
Reprints and permissions:
sagepub.co.uk/journalsPermissions.nav
DOI: 10.1177/2050313X18777164
journals.sagepub.com/home/sco



Yanal Alnimer¹ , Osama Zaghmout² and Qazi Azher³

Abstract

Introduction: Carcinosarcoma is a rare gynecological malignancy and it usually follows an aggressive clinical course. Rarely, it can be confined to an endometrial polyp or be synchronous with another gynecological malignancy. Herein, we report a rare case of synchronous carcinosarcoma confined to an endometrial polyp and endometrioid endometrial adenocarcinoma arising from a distinct uterine wall site.

Case presentation: A 57-year-old female patient presented with heavy vaginal bleeding. She underwent hysterectomy with bilateral salpingo-oophorectomy for endometrioid endometrial adenocarcinoma that was diagnosed preoperatively through dilation and curettage. Full histopathological examination of the uterine specimen revealed carcinosarcoma confined to a 4 cm endometrial polyp in addition to a stage IA endometrioid endometrial adenocarcinoma which arose from a distinct uterine wall.

Conclusion: Having an endometrioid endometrial cancer diagnosis preoperatively through dilation and curettage and an examination of the frozen section specimen following surgical resection should not preclude the standard full histopathological examination of the uterine specimen, since this could reveal an additional uterine malignancy, such as carcinosarcoma. Such a finding would alter the post-operative management, prognosis, and outcome even if it is confined to an endometrial polyp.

Keywords

Oncology, obstetrics/gynecology, carcinosarcoma, synchronous, endometrioid endometrial adenocarcinoma

Date received: 14 December 2017; accepted: 24 April 2018

Introduction

Endometrial adenocarcinoma is the most common gynecological tumor in the United States. Women with postmenopausal vaginal bleeding are at high risk of having endometrial adenocarcinoma, with an estimated incidence of 20%.¹ Advanced age, nulliparity, polycystic ovary syndrome, family history, and prolonged estrogen exposure are well-known risk factors for endometrial cancer.² On the other hand, carcinosarcoma (malignant mixed Mullerian tumor (MMMT)) of the endometrium accounts for only 1%–2% of all gynecological malignancies.³ Carcinosarcoma and endometrial adenocarcinoma share common risk factors with the exception of pelvic radiation, which increases the risk of the former. Moreover, the clinical presentation of carcinosarcoma is similar to that of endometrial adenocarcinoma.⁴

Carcinosarcoma comprises two different components epithelial (carcinomatous) and mesenchymal (sarcomatous). The sarcomatous component is considered homologous when it consists of mesenchymal tissue elements native to the uterus, otherwise it is called heterologous.

Different histological forms are based on the elements that constitute the carcinomatous and sarcomatous components. High-grade serous carcinoma is the most common form of carcinoma, and endometrial stromal sarcoma, “a homologous type,” is the most common form of sarcoma in MMMT.⁵

Singh⁶ reported that only 1%–2% of women with a gynecological malignancy have another synchronous

¹Internal Medicine Residency, Hurley Medical Center, Michigan State University, Flint, MI, USA

²Obstetrics and Gynecology Residency, Hurley Medical Center, Michigan State University, Flint, MI, USA

³Department of Pathology, Hurley Medical Center, Michigan State University, Flint, MI, USA

Corresponding Author:

Yanal Alnimer, Internal Medicine Residency, Hurley Medical Center, Michigan State University, 1 Hurley Plaza, Flint, MI 48503, USA.
Email: YalnimeI@hurleymc.com



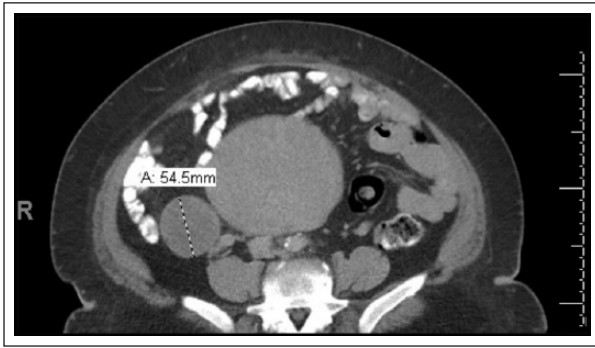


Figure 1. CT of the abdomen and pelvis demonstrating a 5.4 cm retroperitoneal mass.

gynecological cancer. Herein, we report a rare case of synchronous carcinosarcoma in an endometrial polyp and stage IA endometrioid endometrial adenocarcinoma arising from a separate uterine wall.

Case presentation

A 57-year-old female presented to the emergency department with heavy vaginal bleeding accompanied by mild dizziness. She denied any abdominal pain, distention, fever, chills, or weight loss. Her medical history was significant for end-stage renal disease on hemodialysis, hypertension, dyslipidemia, and chronic hepatitis B. Her medications included tenofovir, carvedilol, atorvastatin, calcitriol, hydralazine, isosorbide dinitrate, and nifedipine. She had a Papanicolaou smear 2 years prior to her presentation, which was normal. She never took oral contraceptive pills. She denied any history of tobacco use or alcohol consumption and her family history was non-contributory.

Her vital signs were remarkable for blood pressure of 100/60, heart rate of 105 beats per minute, respiratory rate of 15, and temperature of 36.7°C. Her initial laboratory workup showed a hemoglobin level of 6.5 g/dL, white blood cell count of 12.7 cells/ μ L, platelet count of 238 platelets/ μ L, serum creatinine of 4.6 mg/dL, blood urea nitrogen of 24 mg/dL, and serum electrolytes were within normal limits.

She initially received 2U of packed red blood cells. Bedside pelvic ultrasound at the emergency department demonstrated a heterogeneous mass-like enlargement of the uterus. The patient was admitted to the hospital and shortly thereafter she underwent hysteroscopic dilation and curettage. The latter revealed a well-differentiated endometrioid endometrial adenocarcinoma (Grade I). During her hospital stay, she continued to have vaginal bleeding, for which she received transfusion of four additional units of packed red blood cells. Computed tomography (CT) of the abdomen, which was done in the setting of preoperative evaluation of the tumor, revealed a thickened uterus with a 5.3 cm retroperitoneal mass (Figure 1).

Two days later, she underwent total abdominal hysterectomy with bilateral salpingo-oophorectomy. Intraoperatively,

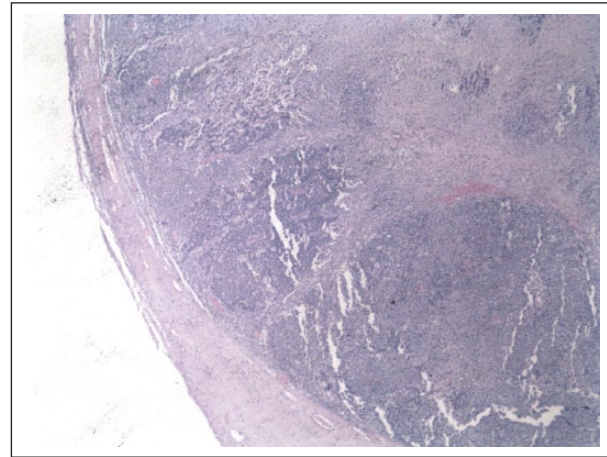


Figure 2. Endometrial polyp under gross histological examination.

the uterus was enlarged about 17–20 weeks in size, both ovaries and fallopian tubes looked healthy, and intraoperative frozen section of the uterus revealed endometrioid endometrial adenocarcinoma with superficial invasion of the myometrium. The right retroperitoneal mass had a feeding vessel from the ovarian suspensory ligament. Resection was done after clamping the feeding vessel, and frozen section of the mass revealed a necrotic leiomyoma. Examination of the full pathological specimen of the uterus demonstrated a well-differentiated endometrioid endometrial adenocarcinoma with an invasion depth of 2.5 cm out of the 8.5 cm thickness of the myometrial wall in addition to the presence of lymphovascular invasion. Moreover, there was a 4 cm polypoid mass arising from a distinct area in the posterior wall of the uterus (Figure 2), which—under pathological examination—revealed a poorly differentiated biphasic tumor containing both carcinomatous (Figures 3 and 5) and sarcomatoid components (Figures 4 and 5). The former was adenocarcinoma in differentiation, while the latter had cartilaginous differentiation with no evidence of myometrium invasion at the site of the endometrial polyp. This was consistent with heterologous carcinosarcoma that emerged from the endometrial polyp without myometrial invasion. Moreover, the retroperitoneal mass showed a well-circumscribed globally necrotic acellular lesion, likely a torsed leiomyoma.

The patient recovered from the surgical procedure uneventfully, and she was discharged from the hospital after a few days.

Discussion

In addition to being an uncommon event, it is extremely important to recognize the presence of synchronous gynecological malignancy since this could affect the prognosis and outcome.⁶ Synchronous endometrial adenocarcinoma and ovarian endometrioid adenocarcinoma are the most common

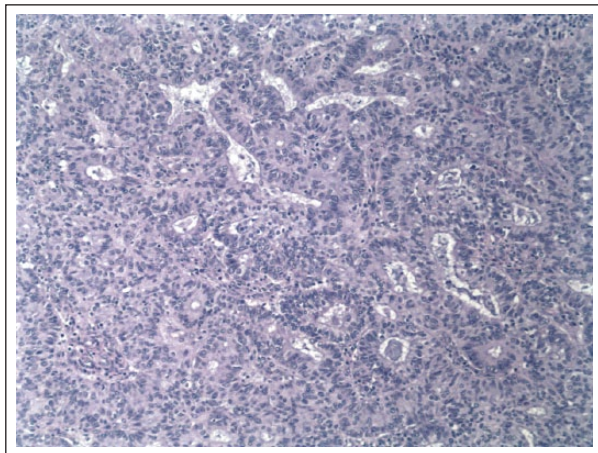


Figure 3. Carcinomatous component of the endometrial polyp.

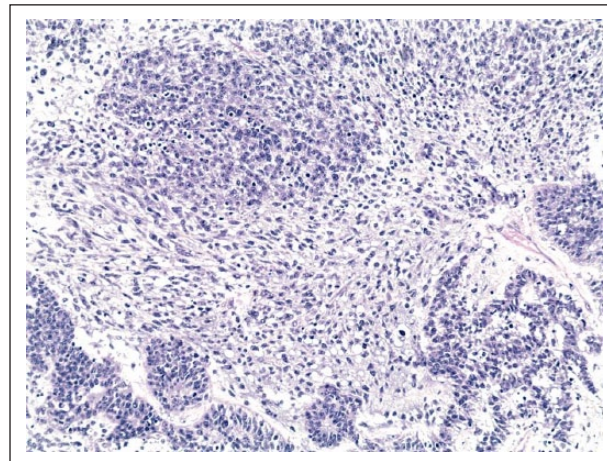


Figure 5. Carcinosarcoma of the endometrial polyp.

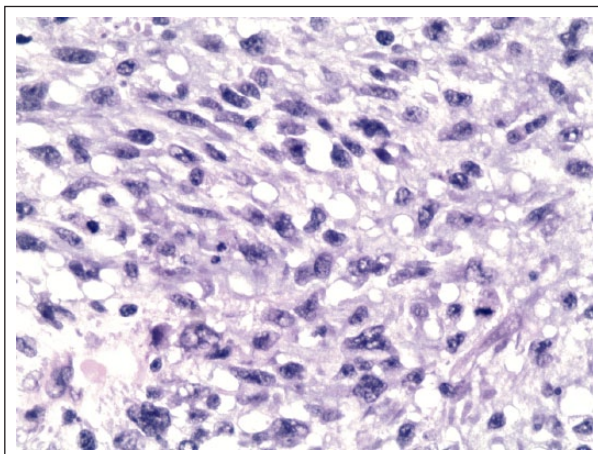


Figure 4. Sarcomatoid component of the endometrial polyp.

synchronous gynecological malignancies, which predominate in the younger age group.⁷

The presence of simultaneous low grade and stage gynecological malignancies favors synchronous tumors as opposed to a single tumor with metastasis, in which the primary tumor tends to be at an advanced stage.⁷ Thus, histopathology is the primary diagnostic tool, but other investigations like immune-histochemical staining could be used as an adjunct in difficult cases.⁷ In our case, endometrial adenocarcinoma and carcinosarcoma emerged from two distinct sites in the endometrial cavity with both being in stage I, which favors synchronous tumors rather than a single tumor with metastasis.

Since carcinosarcoma of the uterus shares similar risk factors with endometrial adenocarcinoma and there is growing evidence that the sarcoma component arises from metaplasia of the carcinoma component, some authors claim that carcinosarcoma is an aggressive form of endometrial adenocarcinoma. However, Maxwell et al.'s⁸ experiment showed greater expression of IGF2 and lower levels

of MUC1, SCGB2A1, HOXB6, and TFF3 expression in carcinosarcoma than in endometrial adenocarcinoma, which suggests a distinct cell of origin. Furthermore, Bansal et al.⁹ had proven the distinct aggressive behavior in carcinosarcoma when compared to high-grade endometrial adenocarcinoma, which further supports the fact that these tumors are biologically distinct.

Due to the improvement in cancer awareness and medical care, around 80% of the endometrial cancer cases are diagnosed at stage I.² Total abdominal hysterectomy and bilateral salpingo-oophorectomy is the main treatment for stage I-III endometrial cancer, and it is followed by adjuvant chemotherapy for stage III tumors. The risk of tumor recurrence is low in subsets of patients with stage IA tumors who lack myometrial invasion and thus adjuvant radiotherapy is not recommended. For patients with stage IA tumors with myometrial invasion and those with stage II, the benefit from adjuvant radiation depends on the presence of one of the following high-risk features: lymphovascular invasion, grade 2 or 3 tumors, or invasion of more than 50% of the myometrial thickness. Patients who are 70 years or older and have one of the high-risk features, are 50 years or older with two high-risk features, and those who are any age with three high-risk features are candidates for adjuvant radiation with or without chemotherapy.^{10,11}

Our patient was diagnosed with stage IA endometrioid adenocarcinoma of the endometrium that invaded less than 50% of the myometrial wall. The tumor was moderately differentiated with evidence of lymphovascular invasion in the pathology specimen.

Multiple theories have been proposed to explain the development of carcinosarcomas; however, epithelial-mesenchymal transition (EMT) theory, which states that metaplasia of the carcinoma component gives rise to the sarcoma element, is becoming widely accepted.¹² This theory was further supported by the monoclonal origin of both components.¹² On immunohistochemistry, both the carcinomatous

and sarcomatous components tend to stain positively for B-catenin, BCL-2, COX-2, p16, PTEN, RB-1, and vimentin, while cytokeratin, estrogen, and progesterone receptors, and epidermal growth factor receptor (EGFR) tend to be positive in the carcinomatous component only.¹²

Using the frozen section technique for specimen preparation allows rapid examination of it following surgical resection. This is particularly helpful in providing a more accurate diagnosis than the preoperative biopsy and ensures a negative surgical margin at the time of surgical resection; however, the frozen section technique has its limitations, namely that only a limited number of sections can be examined and the histologic sections produced tend to contain more artifacts than sections of formalin-based paraffin-embedded tissue. In our case, the frozen sections were prepared from the thickened endometrium and from the retroperitoneal mass, which revealed endometrioid endometrial adenocarcinoma with superficial myometrial invasion and torsed leiomyoma, respectively. Examining multiple sites of the uterus, including the endometrial polyp, after formalin fixation identified carcinosarcoma inside the endometrial polyp without any evidence of myometrial invasion. Moreover, it identified the lymphovascular invasion of the endometrioid endometrial adenocarcinoma. This highlights the importance of the standard pathological examination of the uterus even from the seemingly benign areas such as an endometrial polyp, since this could reveal an additional uterine malignancy that could not be recognized in dilation and curettage or frozen section evaluation and provides more accurate staging for the known endometrial cancer.

Carcinosarcoma tends to behave aggressively even if it is confined to an endometrial polyp. Nieves et al.¹³ reported a case of carcinosarcoma with liver metastasis despite being totally inside an endometrial polyp in the histology specimen. A preoperative CT scan for our patient did not show any evidence of distant metastasis. Due to the presence of two high-risk features of endometrial carcinoma in our patient (Grade 2 disease and lymphovascular invasion), she was classified as high intermediate risk and, therefore, she was given adjuvant pelvic radiation. The National Comprehensive Cancer Network guideline recommends treating carcinosarcoma as a high-grade endometrial carcinoma and adjuvant chemotherapy is considered optional for stage I and early stage II disease.¹⁴ The patient was offered an adjuvant chemotherapy treatment and after discussing the prognosis, outcome, and side effects of the chemotherapy, she was agreeable to it and later on was given eight cycles of adjuvant carboplatin and docetaxel. Of note, she had finished her adjuvant chemotherapy with no evidence of disease recurrence.

Conclusion

Carcinosarcoma is a rare aggressive gynecological malignancy. Rarely, it can arise from an endometrial polyp or occur along with another gynecological tumor. Histopathological

examination of the uterus through multiple specimens using the standard formalin fixation and embedding them into paraffin is of utmost importance, since this could identify such an aggressive tumor which could not be identified earlier through biopsy or frozen section examination. Moreover, identifying such an aggressive tumor would alter the post-operative management, prognosis, and outcome even if it is confined to an endometrial polyp.

Declaration of conflicting interests

The author(s) declared no potential conflicts of interest with respect to the research, authorship, and/or publication of this article.

Ethical approval

Our institution does not require ethical approval for reporting individual cases or case series.

Funding

The author(s) received no financial support for the research, authorship, and/or publication of this article.

Informed consent

Written informed consent was obtained from the patient(s) for their anonymized information to be published in this article.

ORCID iD

Yanal Alnimer 
<https://orcid.org/0000-0001-6350-3826>

References

1. American College of Obstetricians and Gynecologists. ACOG practice bulletin, clinical management guidelines for obstetrician-gynecologists, number 65, August 2005: management of endometrial cancer. *Obstet Gynecol* 2005; 106(2): 413–425.
2. Setiawan VW, Yang HP, Pike MC, et al. Type I and II endometrial cancers: have they different risk factors? *J Clin Oncol* 2013; 31(20): 2607–2618.
3. Brooks SE, Zhan M, Cote T, et al. Surveillance, epidemiology, and end results analysis of 2677 cases of uterine sarcoma 1989-1999. *Gynecol Oncol* 2004; 93(1): 204–208.
4. Pothuri B, Ramondetta L, Martino M, et al. Development of endometrial cancer after radiation treatment for cervical carcinoma. *Obstet Gynecol* 2003; 101(5 Pt 1): 941–945.
5. Gadducci A, Cosio S, Romanini A, et al. The management of patients with uterine sarcoma: a debated clinical challenge. *Crit Rev Oncol Hematol* 2008; 65(2): 129–142.
6. Singh N. Synchronous tumours of the female genital tract. *Histopathology* 2010; 56(3): 277–285.
7. Eisner RF, Nieberg RK and Berek JS. Synchronous primary neoplasms of the female reproductive tract. *Gynecol Oncol* 1989; 33(3): 335–339.
8. Maxwell GL, Chandramouli GV, Dainty L, et al. Microarray analysis of endometrial carcinomas and mixed müllerian tumors reveals distinct gene expression profiles associated with different histologic types of uterine cancer. *Clin Cancer Res* 2005; 11(11): 4056–4066.

9. Bansal N, Herzog TJ, Seshan VE, et al. Uterine carcinosarcomas and grade 3 endometrioid cancers: evidence for distinct tumor behavior. *Obstet Gynecol* 2008; 112(1): 64–70.
10. Practice bulletin no.149: endometrial cancer. *Obstet Gynecol* 2015; 125(4): 1006–1026.
11. Keys HM, Roberts JA, Brunetto VL, et al. A phase III trial of surgery with or without adjunctive external pelvic radiation therapy in intermediate risk endometrial adenocarcinoma: a gynecologic oncology group study. *Gynecol Oncol* 2004; 92(3): 744–751.
12. Semczuk A, Skomra D, Chyzynska M, et al. Immunohistochemical analysis of carcinomatous and sarcomatous components in the uterine carcinosarcoma: a case report. *Pathol Res Pract* 2008; 204(3): 203–207.
13. Nieves-Lugo L, Blanch R, Abad M, et al. Uterine carcinosarcoma arising from an endometrial polyp: assessment by 3-dimensional power Doppler angiography and positron emission tomography/computed tomography. *J Ultrasound Med* 2006; 25(5): 675–678.
14. Berton-Rigaud D, Devouassoux-Shisheboran M, Ledermann JA, et al. Gynecologic Cancer InterGroup (GFIG) consensus review for uterine and ovarian carcinosarcoma. *Int J Gynecol Cancer* 2014; 24(9Suppl. 3): S55–60.