

This is an Open Access article licensed under the terms of the Creative Commons Attribution-NonCommercial-NoDerivs 3.0 License (www.karger.com/OA-license), applicable to the online version of the article only. Distribution for non-commercial purposes only.

Chemotherapy-Induced Ischemic Colitis in a Patient with Jejunal Lymphoma

Ulrich Halm Stephan Sack Markus Zachäus

Department of Internal Medicine II, Park Hospital Leipzig, Leipzig, Germany

Key Words

Ischemic colitis · Lymphoma · Chemotherapy

Abstract

The occurrence of acute ischemic colitis may be associated with the intake of various drugs. However, colitis during antineoplastic chemotherapy usually is due to toxic effects or neutropenia and not caused by ischemia. We describe a 51-year-old man with jejunal B-cell lymphoma who developed recurrent episodes of ischemic colitis following chemotherapy with cyclophosphamide, vincristine, doxorubicine and prednisolone plus rituximab (R-CHOP). After switching chemotherapy to bendamustin plus rituximab no further episodes of colonic ischemia occurred during the following cycles of chemotherapy. In conclusion, chemotherapy of lymphoma using a standard protocol with CHOP and rituximab may cause ischemic colitis.

Introduction

Ischemic colitis is the most common form of intestinal ischemia [1]. The disease often occurs spontaneously, especially in the elder population with underlying atherosclerosis, and is caused by embolic or thrombotic occlusion of colonic vessels or by conditions leading to hypoperfusion of the colonic wall (nonocclusive form). The typical clinical presentation is sudden onset of left-sided lower abdominal pain often followed by hematochezia within 24 h. In most patients the disease is self-limiting, but the severe form of ischemic colitis, colonic gangrene, is a life-threatening disease usually requiring urgent surgery.

Multiple predisposing factors for the development of ischemic colitis have been identified. These factors include decreased cardiac output caused by shock, arrhythmias, congestive heart failure, ongoing cardiac bypass operation or aortic repair. Other reasons for colonic ischemia are coagulation disorders such as deficiency of protein C, protein S or antithrombin III, sickle cell disease, and vasculitis disorders such as systemic lupus erythematosus, polyarteritis nodosa or thromboangiitis obliterans [2].

Various drugs including digitalis, vasoconstrictors, antihypertensive drugs, psychotropic agents, nonsteroidal anti-inflammatory drugs, and antidiarrheal agents have been identified as precipitating factors for colonic ischemia. Antineoplastic drugs such as bevacizumab in combination with irinotecan and 5-fluorouracil [3] or docetaxel in combination with vinorelbine [4] may cause ischemic colitis. However, therapy for non-Hodgkin's lymphoma with cyclophosphamide, vincristine, doxorubicin, prednisolone and rituximab (R-CHOP) has not been described as a precipitating factor for ischemic colitis. Colitis occurring during antineoplastic chemotherapy is most frequently due to direct toxic effects or severe neutropenia. Both toxic effects on the colonic mucosa and neutropenic enterocolitis should be differentiated from ischemic colitis [5].

Here we report the association of recurrent episodes of colonic ischemia in relation to standard antineoplastic chemotherapy for B-cell lymphomas.

Case Report

A 51-year-old man was referred with recurrent cramping periumbilical pain. Computed tomography showed marked jejunal thickening as well as multiple abdominal and thoracic lymphomas. Histology taken 200 cm from incisors by double balloon enteroscopy established the diagnosis of jejunal B-cell lymphoma. Complete colonoscopy showed no abnormalities. Systemic antineoplastic therapy containing the monoclonal antibody rituximab 375 mg/m² (day 0), combined with cyclophosphamide 750 mg/m², vincristine 2 mg, doxorubicin 50 mg/m² (each given at day 1) and prednisolone 100 mg on days 1–5 (R-CHOP) was initiated. Mesna and ondansetron were given for prophylaxis of cyclophosphamide-induced cystitis and emesis, respectively.

Two days after the initiation of chemotherapy the patient was admitted to the emergency department because of sudden onset of left-sided lower abdominal pain followed by hematochezia. Computed tomography of the abdomen revealed, besides the small bowel lymphoma with lymph node involvement, thickening of the descending and sigmoid colon. Laboratory tests including stool analysis for enteritis pathogens were unremarkable except for an elevation of C-reactive protein to 23.5 mg/l. Colonoscopy showed inflammation with semicircular longitudinal swelling and petechial bleeding in the descending and sigmoid colon (fig. 1). Histology from the descending colon showed complete necrosis of the superficial epithelium and infiltration of the submucosal layer by polymorphonuclear neutrophilic leucocytes consistent with ischemic colitis. The patient had an unremarkable course and was discharged 5 days later. The second course of chemotherapy containing CHOP plus rituximab was well tolerated, but 4 days after the third course of chemotherapy, the patient presented again with sudden onset of diffuse abdominal pain. A new episode of colonic ischemia was diagnosed by a CT scan of the abdomen, which showed nearly complete regression of the lymphoma, but also marked thickening of the entire colon wall. Laboratory tests again showed no neutropenia, but a rise of C-reactive protein to 69.7 mg/l. The second episode of ischemic colitis was also managed conservatively.

Discussion

In the present case, differential diagnosis was difficult because the patient initially presented with abdominal pain due to jejunal lymphoma. The first episode of colonic ischemia was thought to occur spontaneously in a heavy smoker, but the occurrence of two clinically typical episodes of ischemic colitis after chemotherapy argues for the association of reduced blood supply of the colon following the application of chemotherapy. Various drugs have been described as possible triggers for the nonocclusive form of ischemic colitis [2]. However, the patient did not take drugs having a known association with ischemic colitis. Colitis associated with antineoplastic

chemotherapy is usually associated with severe neutropenia 7–10 days after completion of the course or with a direct toxic effect [5]. In contrast, colon ischemia seems rare during antineoplastic therapy. Some chemotherapeutic drugs such as bevacizumab in combination with irinotecan and 5-fluorouracil or docetaxel in combination with vinorelbine may cause colon ischemia [3, 4], but chemotherapy according to the R-CHOP protocol, which is a standard regime for treatment of non Hodgkin's lymphoma [6], has not been associated with the development of ischemic colitis.

After switching chemotherapy to bendamustine combined with prednisolone and rituximab, no episodes of colon ischemia occurred during the following three cycles. We therefore favour cyclophosphamide, doxorubicine or vincristine or the combination, respectively, as the cause for the two episodes of colonic ischemia. As illustrated in this case, clinicians should be aware of possible ischemic colitis in patients with abdominal pain during chemotherapy with the CHOP regime.

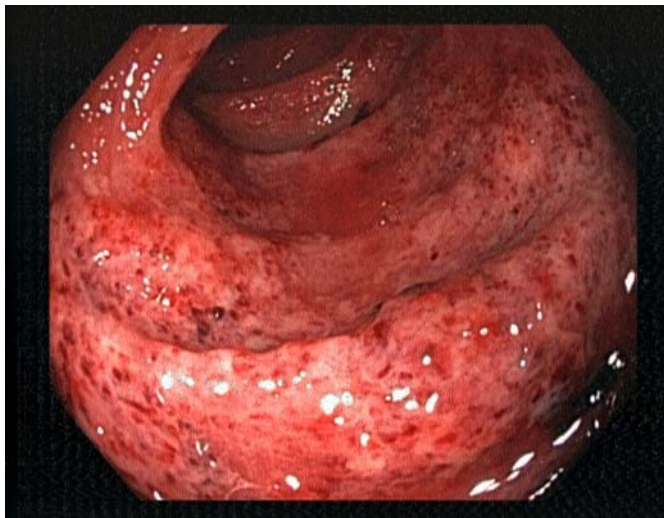


Fig. 1. Colonoscopic view into the descending colon showing mucosal edema, friability and petechial hemorrhage.

References

- 1 Higgins PD, Davis KJ, Laine L: Systematic review: the epidemiology of ischaemic colitis. *Aliment Pharmacol Ther* 2004;19:729–738.
- 2 Sreenarasimhaiah J: Diagnosis and management of intestinal ischaemic disorders. *BMJ* 2003;326:1372–1376.
- 3 Paran H, Edelstein E, Klein B, et al: Extensive colonic ischemia following treatment with bevacizumab, fluorouracil and CPT-11 in a young patient with advanced adenocarcinoma of the rectum. *Isr Med Assoc J* 2007;9:488–489.
- 4 Ibrahim NK, Sahin AA, Dubrow RA, et al: Colitis associated with docetaxel-based chemotherapy in patients with metastatic breast cancer. *Lancet* 2000;355:281–283.

- 5 Davila M, Bresalier RS: Gastrointestinal complications of oncologic therapy. *Nat Clin Pract Gastroenterol Hepatol* 2008;5:682–696.
- 6 Kahl B: Chemotherapy combinations with monoclonal antibodies in non-Hodgkin's lymphoma. *Semin Hematol* 2008;45:90–94.