



## Case report

# Medulloblastoma at the cerebello-pontine angle resembling vestibular schwannoma: A case report and review of the literature

Wafa Aqel<sup>a,\*</sup>, Ayman Salman<sup>b</sup>, Asad Aldarawish<sup>b</sup>, Izzeddin Bakri<sup>c</sup>

<sup>a</sup> Al-Quds Medical School, Jerusalem, Palestine

<sup>b</sup> Department of Neurosurgery, Al-Makassed Islamic Charitable Hospital, Jerusalem, Palestine

<sup>c</sup> Department of Pathology, Al-Makassed Islamic Charitable Hospital, Jerusalem, Palestine



## ARTICLE INFO

## Keywords:

Cerebello-pontine angle  
Medulloblastoma  
Brain tumor  
Posterior fossa  
Case report

## ABSTRACT

Cerebello-pontine angle (CPA) tumors account for only less than 10 % of intracranial tumors, it usually affects children at a young age with the midline being the most favorable location. Our adult patient demonstrated a very unusual site for medulloblastoma at the CPA. Less than 50 cases all around the world have been reported in the English literature for Medulloblastoma to be located at the CPA, and most of them in pediatric age group.

We report a 43 year old female patient who presented to our neurosurgical ward in Jerusalem with a 4 months history of progressive decreased hearing at the left side, accompanied with tinnitus, dizziness, and imbalance on walking. Medulloblastoma at the CPA was one of the differential diagnosis and was confirmed at our histopathology unit after gross total resection of the tumor, the surgery followed by radiotherapy and the patient was well after 9 months after procedure.

MB-CPA is a relatively rare tumor, and the early diagnosis make a difference in the management, prognosis, and outcomes, so it should be considered as a differential diagnosis of a lesion of the CPA.

## 1. Introduction

Tumors of the Cerebellopontine Angle (CPA) account for 5–10 % of all intracranial neoplasms [1]. Vestibular schwannoma, meningioma, followed by epidermoid tumors are the most frequent CPA primary tumors. While Medulloblastomas (MB) are among the most common primary brain tumors in children [2], till date, less than 50 cases of cerebellopontine angle (CPA) medulloblastomas have been described in the current English literature.

The incidence of medulloblastomas in adults is approximately 0.5 per million per year and decreases with age [3] with male predominance [2,4]. It is extremely rare related to other adult primary brain tumors, and account for only 0.4 % to 1.0 % [2,5].

In this article, we describe a rare case of cerebellopontine angle medulloblastoma CPA-MB in a 43-year-old woman who had complained of dizziness and headache, followed by vomiting, tinnitus and progressive left-sided hearing loss. Brain Magnetic Resonance Imaging (MRI) demonstrated a left cerebello-pontine angle (CPA) lesion with a mass effect on the brainstem. The patient we are reporting about was treated with complete resection of the tumor, more details and histological features are discussed below compared to the previously published

literature, with all criteria included in the Consensus Surgical Case REport (SCARE) 2020 Guidelines [6].

## 2. Case presentation

A 43-year-old married female with unremarkable previous illness, developed dizziness and headache, followed by vomiting. She sought an Ear, Nose and Throat (ENT) specialist's advice and was treated as a case of otitis media without improvement. Few days later, the patient started experiencing tinnitus and progressive decreased hearing at the left side noted especially on mobile conversation. Meantime, the patient reported imbalance while walking and swallowing difficulty.

Her past medical history is free, no drug history, no history of visual disturbances, no history of weight loss, no history of similar episodes before, no history of a similar condition in the family, she is non-smoker, with good socioeconomic state.

Few weeks later, the patient sought a neurosurgical advice at her area and Brain MRI was done and showed a left cerebello-pontine (CP) angle lesion compressing the brain stem (Fig. 1).

On neurological exam, the patient was seen conscious, alert, and oriented to time, place, and person, pupils were equally reactive to light

\* Corresponding author at: Al-Quds University, Main Campus, Abu Dis, P.O. Box 89, Palestine.

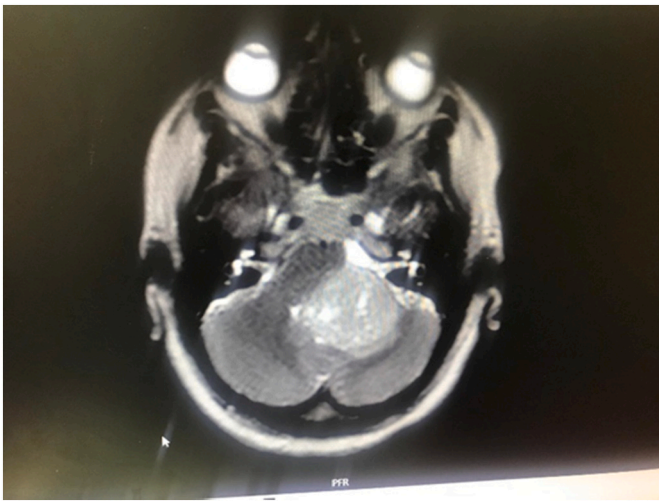
E-mail address: [wafa.aqel.a@gmail.com](mailto:wafa.aqel.a@gmail.com) (W. Aqel).

<https://doi.org/10.1016/j.ijscr.2022.107695>

Received 10 August 2022; Received in revised form 19 September 2022; Accepted 19 September 2022

Available online 21 September 2022

2210-2612/© 2022 Published by Elsevier Ltd on behalf of IJS Publishing Group Ltd. This is an open access article under the CC BY-NC-ND license (<http://creativecommons.org/licenses/by-nc-nd/4.0/>).



**Fig. 1.** Pre-operative T1 weighted MRI axial cut with GAD showing a huge left CPA enhancing, heterogeneous rounded lesion with a mass effect over the brain stem and cerebellum surrounded by vasogenic edema.

and accommodation with a size of 2 mm bilaterally. The visual field and visual acuity were intact by confrontation. However, she had both horizontal and vertical nystagmus.

In terms of cranial nerves examination, the patient had unremarkable deficits in her cranial nerves but severely depressed hearing at the left side. She also had a weak gag reflex at the left side but good reflex at the right side. The uvula was seen deviated to the right side.

In regard to motor system, the patient was seen moving her upper and lower limbs freely with a power 5/5 all over proximally and distally with a normal tone. She had hyper-reflexia all over the tendons, she had negative Hoffman and Babinski reflexes. However, she had a positive Romberg's test.

The patient also had unsteady, ataxic gait. She was unable to perform the tandem gait.

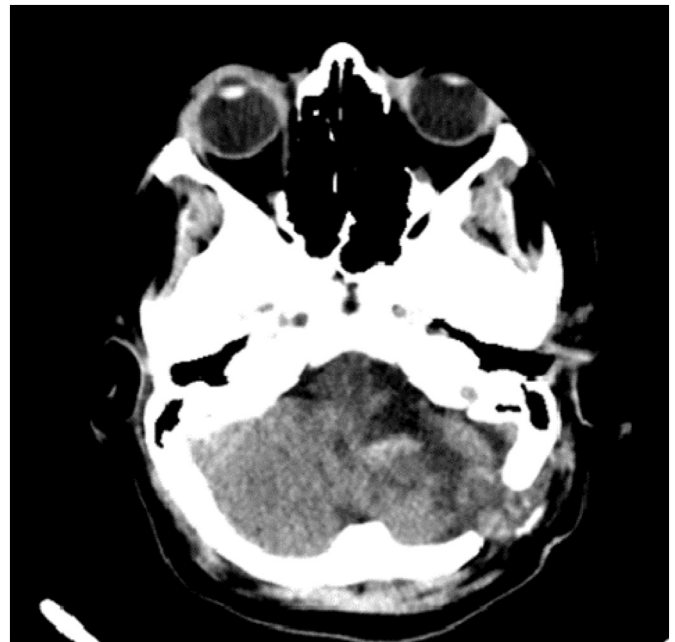
The next day of admission to our neurosurgical ward, the patient was ready for the surgery which was done by the neurosurgery team in our hospital, Dr. Asad Aldarawish in his wide experience was the supervisor. She underwent left retromastoid, retro-sigmoid craniotomy with complete resection of the left-sided CPA tumor which was compressing the brain stem. The surgery was smooth without intra-operative complications. She was smoothly extubated in the operation room (OR) and moved to the neuro Intensive Care Unit (ICU) in the same hospital, with good care and hygiene, for close observation and further management.

On neurological examination after the surgery, the patient was seen conscious, alert, and oriented to time, place, and person. She had stable vital signs. The cranial nerves were noted grossly intact except depressed hearing at the left side, weak gag reflex at the left side, uvula was seen deviated to the right side (as prior to surgery), and she also had a left-sided facial nerve palsy; House Brackmann (HB) grade 3.

The motor system and power were unchanged compared to pre-operative status.

Brain Computed Tomography (CT) scan was done the next day of surgery and showed post-operative changes with complete resection of the tumor but minimal amount of blood was seen at site of surgery (Fig. 2). Therefore, the patient was kept off anticoagulation. Doppler ultrasound for the lower limbs was done and showed no evidence of acute deep vein thrombosis (DVT) so pneumatic boots were applied.

In terms of diet, the patient started on sips of water and the amount increased gradually when she was seen tolerating the oral feeding. The patient was then moved out of neuro ICU to the ward in a good and stable condition. She was seen out of bed, with some assistance while walking due to imbalance. She was tolerating oral feeding and had no active complaints.



**Fig. 2.** Post-operative Brain CT scan showing a complete resection of the left-sided CPA tumor with minimal hematoma at site of surgery.

Brain CT scan was done 7 days post-surgery and showed decreased amount of blood at site of surgery. Clinically, the patient is doing very well, ambulating freely, tolerating oral feeding. No acute complications have occurred so far.

The patient was discharged from our unit in a good and stable condition after 9 days of surgery, she was comfort with her procedure, especially after reviewing all the operation's details and thanked the doctors. After discharge, she was given oral Dexamethasone with gradual tapering, and oral Tegretol, along with analgesic medications. Two months later, she was commenced on radiotherapy and chemotherapy and Received a total of 30 sessions of radiation and 6 cycles of chemotherapy. However, she still needs additional 5 cycles of chemotherapy to complete her management. Apart from that, she is not currently on any other regular medications.

### 3. Discussion

Medulloblastoma (MB) is one of the most common pediatric intracranial tumors, accounting for 25 % of all childhood tumors, and the posterior fossa is the most common site of origin. The etiology of medulloblastomas is still not fully understood till date [3]. According to the World Health Organization WHO-2007 classification of tumors of the central nervous system (CNS), MBs are grade IV, rare malignant embryonal tumors [7,8] and it is distinguished from other Primitive Neuro-Ectodermal Tumors (PNETs). Usually, it develops in the cerebellar vermis and the apex of the fourth ventricle, with predilection to leptomeningeal dissemination [4,9,10].

The site of origin of medulloblastomas in the cerebello-pontine angle is not fully understood [2,11]. However, it could be due to spreading from the midline cerebellum -the most common site of origin- its lateral extension through the foramina of Luschka or direct exophytic growth from the surface of external germinal layer (EGL) of cerebellum or pons. Adult medulloblastomas arise from surface of cerebellum or pons and are laterally located intra-axially or in the tentorial region [12].

CPA-MB's cellular origin has been postulated to arise from the granule cell precursor cells (GCP) from a secondary germinal zone named the external granular layer (EGL) during the development of cerebellum, and several signaling pathways are involved in this oncogenesis, like Hedgehog and Wnt. Therefore, any disruption in this

pathway can result in the development of medulloblastoma [12].

Unfortunately, there has been no clear clinical criteria or specific radiological features proposed to differentiate MB from other CPA tumors [4]. Clinically, owing to its posterior fossa location, MB is characterized by symptoms of progressive raised intracranial pressure and cerebellar dysfunction both in children and adults, manifesting as headache, vomiting, diplopia, nystagmus, ataxia and papilledema [4,10], that develop and progress rapidly over a short period of time [5,13,14].

In our patient, the clinical picture of the tumor developed gradually and rapidly over the course of few weeks, beginning with symptoms of increased intracranial pressure like dizziness and headache, followed by vomiting. Since the CPA is occupied by the CPA cistern, which harbors the trigeminal, abducent, facial, and vestibulocochlear nerves [1], a lesion in the CPA can affect such cranial nerves, as seen in our patient when she started complaining of non-pulsatile tinnitus, weak gag reflex at the left side, and decreased hearing at the left side, as well as she reported cerebellar signs; imbalance while walking and swallowing difficulty and left eye nystagmus.

As aforementioned, there are no specific radiological features for CPA MB reported in the literature [4,5,15]. The imaging modality of choice is MRI: the lesions are usually iso- to hypointense on T1WI [3,16], have variable signal on T2WI, and frequently demonstrate contrast enhancement [3].

As MB is a tumor with high rate of cellular division and densely packed cells, the diffusion of the tumor is restricted and the tumor will manifest mostly as a homogeneous enhancement with the administration of gadolinium contrast [2,9]. A Brain CT scan could be also used to detect areas of hemorrhage and mineralization around the lesion.

As per the literature, there is no specific male/female propensity in CPA-medulloblastoma. However, adult medulloblastoma exhibits a male predominance [2]. Being female, older age, total surgical resection and lateral situation of the tumor are the factors that indicate a better prognosis [5,13], with 5-year survival rates were 92 % for female patients versus 40 % for male patients, gender (favoring female patients) and age (favoring older patients) [3,17].

The fact that our patient is female, old, with rapid onset of symptoms of less than one month duration, along with the lateral location of the tumor make her prognosis is better than others.

Microscopic examination showed sheets of primitive tumor cells, typical of the “small round blue cell tumors”. Careful examination disclosed regions of slightly decreased cellularity accompanied by increased extracellular matrix. Mitoses with apoptotic bodies are readily noted. Immunohistochemical staining for GFAP highlights obviously reactive appearing astrocytes throughout most of the tumor, with rare foci demonstrating immunoreactivity within less well-developed clusters of somewhat atypical appearing cells. Synaptophysin and Neu N are positive. The ki67 labelling index approaches 90 % (Figs. 3, 4).

The treatment and prognosis of CPA medulloblastoma is still uncertain because of the small number of reported cases. Currently, the best combination of treatment modalities for medulloblastoma is aggressive surgical resection followed by radiation therapy and chemotherapy closely [5,19], as same as for pediatrics medulloblastoma [2,18]. The extent of residual disease after surgery may affect the survival of the adult patient with MB [3].

In fact, there is no enough data to compare radiotherapy alone vs with adjuvant chemotherapy to establish treatment protocol and their outcomes for adult CPA-medulloblastoma. However, high-risk adult patients often undergo chemotherapy [16].

#### 4. Conclusion

Cerebellopontine angle medulloblastoma is a rare aggressive tumor that can mostly occur in children and extremely rare in adults. The early diagnosis along with aggressive management with radiotherapy and or chemotherapy can significantly improve overall survival.



Fig. 3. 20×: INI-1 retained nuclear positivity.

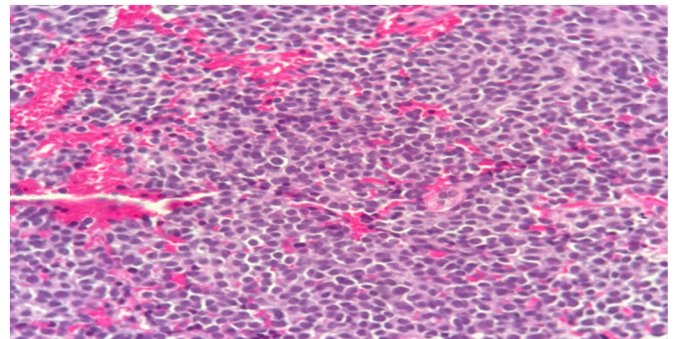


Fig. 4. Cellular tumor composed of undifferentiated cells consists of small round to carrot shaped uniform cells with hyperchromatic nuclei and wispy cytoplasm, with distinct fibrillary background.

Nonetheless, in the differential diagnosis of CPA tumors, CPA medulloblastoma should be considered. However, additional studies are necessary to determine clinical features and the exact prognosis.

#### Ethical approval

The study is exempt from ethical approval in our institution.

#### Funding

This research did not receive any specific grant from funding agencies in the public, commercial, or not-for-profit sectors.

#### Author contribution

Study concept or design: Asad Aldarawish, Izzeddin Bakri.  
Data collection and data analysis: Wafa Aqel, Ayman Salman.  
Writing the manuscript: Wafa Aqel, Ayman Salman

#### Guarantor

Wafa Aqel.

**Research registration number**

Not applicable.

**Consent**

Written informed consent was obtained from the patient for publication of this case report and accompanying images. A copy of the written consent is available for review by the Editor-in-Chief of this journal on request.

**Declaration of competing interest**

There is no conflict of interest.

**References**

- [1] M. Samii, V.M. Gerganov, Tumors of the cerebellopontine angle, in: *Handb. Clin. Neurol* 105, 2012, pp. 633–639.
- [2] E. Bahrami, S. Bakhti, S.-M. Fereshtehnejad, M. Parvaresh, M.R. Khani, Extra-axial medulloblastoma in cerebello-pontine angle: a report of a rare case with literature review, *Med. J. Islam Repub. Iran* 28 (2014) 57.
- [3] E. Pan, M.D. Prados, Adult medulloblastomas, in: *Holland-Frei Cancer Medicine*, 6th edition, BC Decker, 2003.
- [4] A. Spina, N. Boari, F. Gagliardi, A. Franzin, M. Terreni, P. Mortini, Review of cerebellopontine angle medulloblastoma, *Br. J. Neurosurg.* 27 (3) (2013) 316–320.
- [5] K.M. Akay, E. Erdogan, Y. Izci, A. Kaya, E. Timurkaynak, Medulloblastoma of the cerebellopontine angle—case report—, *Neurol. Med. Chir.* 43 (11) (2003) 555–558.
- [6] R.A. Agha, T. Franchi, C. Sohrabi, G. Mathew, for the SCARE Group, The SCARE 2020 guideline: updating consensus Surgical CASE REport (SCARE) guidelines, *Int. J. Surg.* 84 (2020), 226–23.
- [7] D.N. Louis, H. Ohgaki, O.D. Wiestler, W.K. Cavenee, P.C. Burger, A. Jouvett, et al., The 2007 WHO classification of tumours of the central nervous system, *Acta Neuropathol.* 114 (2) (2007) 97–109.
- [8] R. Noiphithak, V. Yindeedeej, C. Thamwongskul, Cerebellopontine angle medulloblastoma with extensive nodularity in a child: case report and review of the literature, *Childs Nerv. Syst.* 33 (5) (2017) 839–842.
- [9] A. Fallah, S.M. Banglawala, J. Provias, N.K. Jha, Extra-axial medulloblastoma in the cerebellopontine angle, *Can. J. Surg.* 52 (4) (2009) E101–E102.
- [10] G. Dhall, Medulloblastoma, *J. Child Neurol.* 24 (11) (2009) 1418–1430.
- [11] S.V. Furtado, P.K. Venkatesh, R. Dadlani, K. Reddy, A. Hegde, Adult medulloblastoma and the “dural-tail” sign: rare mimic of a posterior petrous meningioma, *Clin. Neurol. Neurosurg.* 111 (6) (2009) 540–543.
- [12] S.R. Goudihalli, A. Pathak, R. Brar, I. Mundi, Reappraisal of cerebellopontine angle medulloblastomas: report of a fatal case and lessons learned, *Interdiscip. Neurosurg.* 12 (2018) 20–23.
- [13] A.J. Raimondi, T. Tomita, Medulloblastoma in childhood, *Pediatr. Neurosurg.* 5 (3) (1979) 310–328.
- [14] T. Tomita, Medulloblastomas, *Neurol. Surg.* 4 (1996) 2570–2592.
- [15] A.K. Jaiswal, A. Mahapatra, M. Sharma, Cerebellopontine angle medulloblastoma, *J. Clin. Neurosci.* 11 (1) (2004) 42–45.
- [16] S.K. Singh, N. Kumar, Extraaxial cerebellopontine angle medulloblastoma with multiple intracranial metastases in adult: a rare case report with a review of literature, *Asian J. Neurosurg.* 15 (3) (2020) 695.
- [17] Q.-T. Le, M.D. Weil, W.M. Wara, K.R. Lamborn, M.D. Prados, M. Edwards, et al., Adult medulloblastoma: an analysis of survival and prognostic factors, *Cancer J. Sci. Am.* 3 (4) (1997) 238–245.
- [18] A.W. Chan, N.J. Tarbell, P.M. Black, D.N. Louis, M.P. Frosch, M. Ancukiewicz, et al., Adult medulloblastoma: prognostic factors and patterns of relapse, *Neurosurgery* 47 (3) (2000) 623–632.
- [19] P.K. Duffner, M.E. Cohen, Recent developments in pediatric neuro-oncology, *Cancer* 58 (S2) (1986) 561–568.