

Case Report

Bilateral retinitis pigmentosa with unilateral choroidal nevus: A hitherto unreported association



Rupak Roy^{a,*}; Kumar Saurabh^a; Debmalya Das^b; Preeti Sharma^b; Avirupa Ghose^b; Dhileesh P. Chandrasekharan^c

Abstract

Retinitis Pigmentosa (RP) has been reported to be associated with retinal hemangioma, retinal angiomas, polypoidal choroidal vasculopathy and vasoproliferative tumours. However there is no previous report of choroidal nevus in an eye with RP. We describe such a case in which the eye with RP had a choroidal nevus at the macula. The coexistence of these two entities in the same eye emphasizes the need of careful examination of patients with RP. The presence of choroidal nevus warrants additional investigations such as B scan ultrasonography and a close follow-up to pick up changes in the nevus size and morphology.

Keywords: Retinitis pigmentosa, Choroidal nevus, Retinal degeneration

© 2016 The Authors. Production and hosting by Elsevier B.V. on behalf of Saudi Ophthalmological Society, King Saud University. This is an open access article under the CC BY-NC-ND license (<http://creativecommons.org/licenses/by-nc-nd/4.0/>).
<http://dx.doi.org/10.1016/j.sjopt.2016.01.004>

Introduction

Retinitis Pigmentosa (RP) has been reported to be associated with retinal hemangioma, retinal angiomas, polypoidal choroidal vasculopathy and vasoproliferative tumour.^{1–4}

However there is no report of choroidal nevus in an eye with RP. We present a case of RP which also harboured a choroidal nevus at the macula.

Case report

A 50-year-old male presented with the complaint of diminution of vision in his both eyes, more in the evening hours. There was no history of similar complaints in any of his family members. The best corrected visual acuity was

20/160 in his both eyes. Anterior segment examination revealed clear cornea with posterior subcapsular cataract in both eyes. Fundus in both eyes revealed bony spicule pigmentation and retinal pigment epithelial atrophy sparing the macula. He also had retinal arterial attenuation and minimal optic nerve head pallor in both eyes. Left eye showed a blackish pigmented lesion over two disc diameter size just temporal to fovea (Fig. 1A and B). There was no subretinal fluid (SRF) or pigment overlying the lesion.

Spectral domain optical coherence tomography (Topcon 3D OCT-1000) revealed elevated contour of choroid and hyporeflectivity at the area of lesion with no overlying SRF (Fig. 2A and B). Dimension of the lesion on B scan ultrasonography (Appaswamy Marvel B scan) was 1.5 mm × 1.5 mm × 1 mm (Fig. 2C). Full field electroretinogram (Veris Science 6.3.2) revealed flat scotopic and photopic responses in both eyes (Fig. 3A and B). A diagnosis of

Received 7 March 2015; received in revised form 24 December 2015; accepted 20 January 2016; available online 17 February 2016.

^a Aditya Birla Sankara Nethralaya, 147, Mukundapur, E.M.Bypass, Kolkata 700 099, West Bengal, India

^b Shri Bhagwan Mahavir Vitreoretinal Services, 18, College Road, Sankara Nethralaya, Chennai 600 006, Tamil Nadu, India

^c Sankara Nethralaya, Kolkata, India

* Corresponding author.

e-mail addresses: rayrupak@gmail.com (R. Roy), vrfellow@gmail.com (K. Saurabh), debmalya34@gmail.com (D. Das), drpreetisharma@hotmail.com (P. Sharma), avirupa.ghose74@gmail.com (A. Ghose), dhileeshpc@gmail.com (D.P. Chandrasekharan).

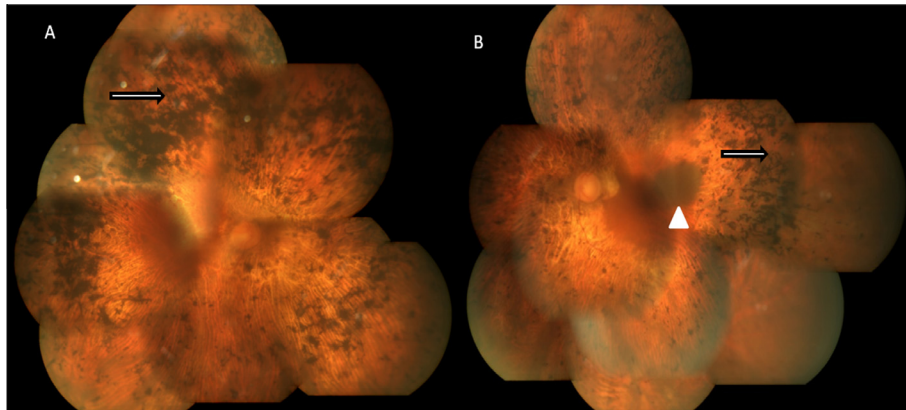


Figure 1. (A) Colour fundus montage photograph of the right eye showing multiple bony spicule pigmentation more conspicuous in the midperiphery (white arrow with black outline). (B) Colour fundus montage photograph of left eye showing multiple bony spicule pigmentation (white arrow with black outline) and choroidal nevus temporal to macula, approx. 3 DD in diameter (white arrowhead).

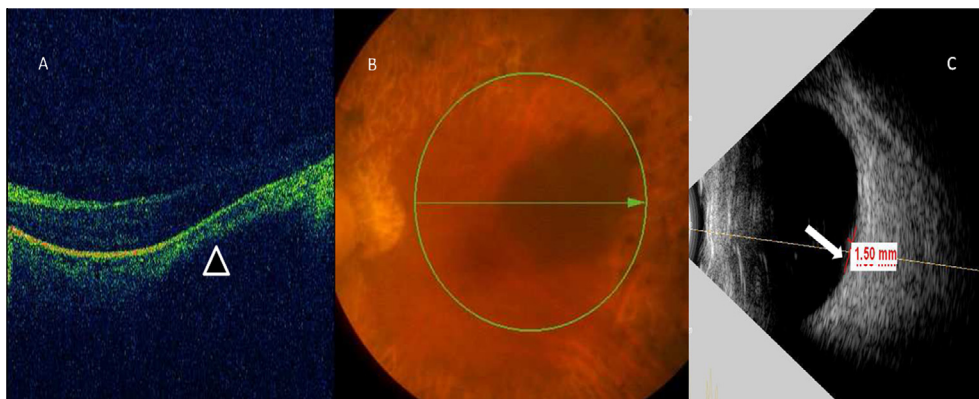


Figure 2. (A) Spectral domain optical coherence tomography of left eye with a choroidal hyporeflective mass elevating the retina (black arrowhead with white outline). (B) Colour fundus photograph of left eye showing the area through which the line scan passes. (C) Ultrasonogram B scan of left eye shows a 1.5 mm × 1.5 mm × 1 mm mass at choroidal level with high surface reflectivity and uniform internal reflectivity (white arrow).

RP with choroidal nevus was made for the left eye. As nevus had a thickness of less than 2 mm and there was no SRF or pigment over the nevus, no intervention was advised. Patient was advised to wear sunglasses for sun protection. He has been under regular follow-up for last two years with no increase in the size of the nevus. He was explained about the prognosis of RP.

Discussion

Nevus cells are considered as atypical or modified melanocytes.⁵ They are the outcome of atypical melanization of melanoblasts derived from neural crest.⁶ Decreased choroidal blood flow in eyes with RP has been linked with retinal angiomatous proliferation and polypoidal choroidal vasculopathy.^{3,4,7} However, association of choroidal nevus with RP has not been previously reported. Since conjunctival melanoma and dermal melanoma have been linked to ultraviolet radiation, our patient was advised to wear sunglasses for protection against ultraviolet rays.⁸

Autosomal dominant RP has been shown to be linked to the human peripherin/Rds locus of chromosome 6p.⁹ Choroidal melanoma has been shown to have loss of long arm (6q) and gain of the short arm (6p) in chromosome 6.¹⁰ The specific genes involved are yet to be identified. Gunduz

et al. had reported a case of choroidal melanoma with RP.¹¹ Choroidal nevi are in the same group of uveal melanocytic disorders as choroidal melanoma and could share similar genetic mechanisms. We postulate that the close proximity of the genetic loci associated with RP and possibly choroidal nevi may lead to the association that we have found. Further genetic studies are necessary to establish any genetic association between the two conditions.

The bone spicules in RP develop around retinal blood vessels due to accumulation of pigments in the retina secondary to disintegration of retinal pigment epithelium. Normal adult normal melanocytes are found in the suprachoroidal lamellae and around choroidal blood vessels whereas nevus cells are larger than normal melanocytes and have other morphological features differentiating them from normal melanocytes.⁵ Interestingly eyes with Choroidal melanoma complicated with retinal invasion occasionally display dispersed melanoma cells lining the posterior hyaloid as a preretinal pigmented membrane, termed as pseudoretinitis pigmentosa.¹² Coexistence of Nevus and RP in same eye could be coincidental or could be result of underlying common genetic alterations, which further studies can only answer.

However the coexistence of RP and choroidal nevus in the same eye emphasizes on the need for careful examination of patients with RP so that all blackish lesions in the fundus are

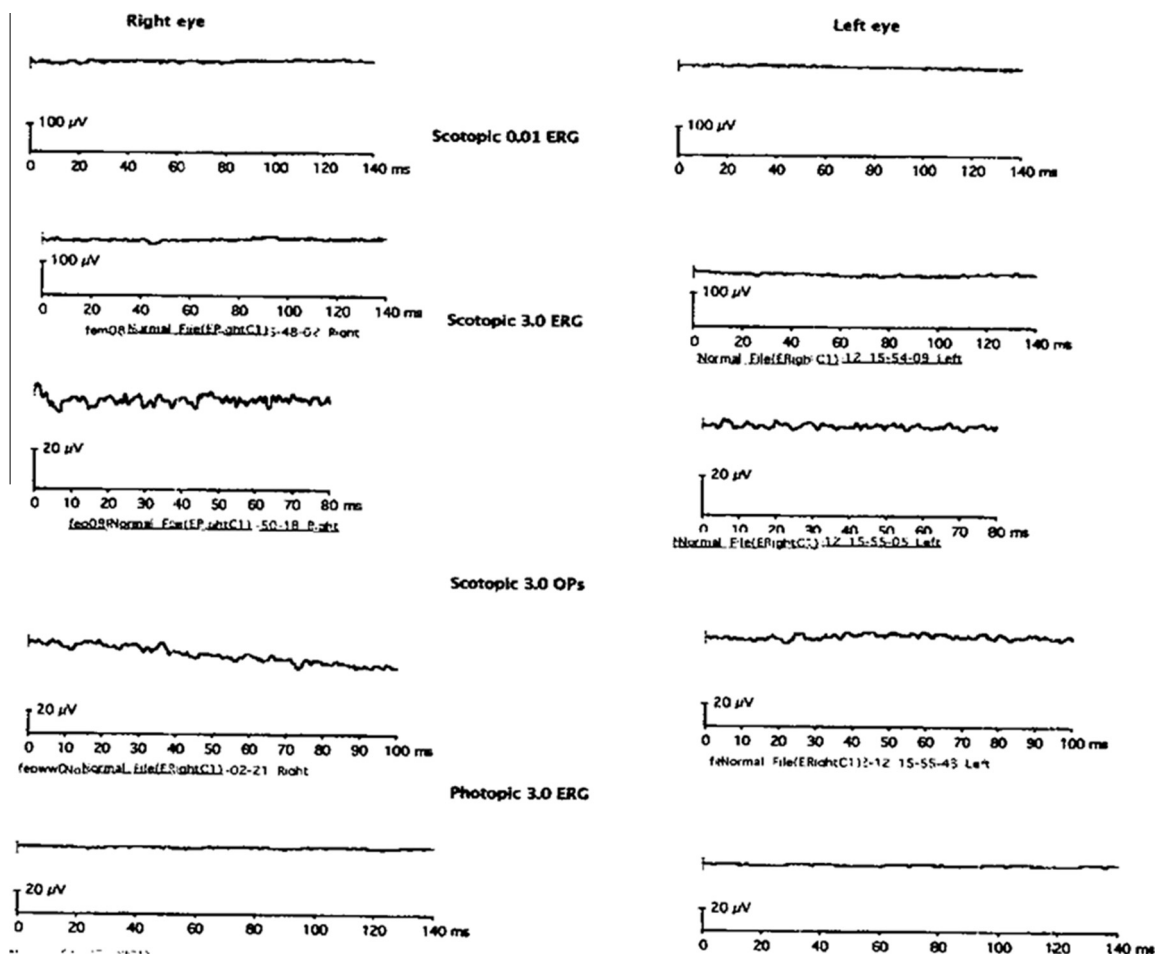


Figure 3. Full field electroretinogram of both eyes showing extinguished response.

not thought of as pigment clumps. Nevus of thickness >2 mm, present within 3 mm of optic disc and having visual symptoms, subretinal fluid, orange pigmentation, hollowness on ultrasonography and with no drusen or surrounding halo, should be carefully watched to detect enlargement. It is important not to miss a nevus because such an eye would require additional investigations such as B scan ultrasonography to assess the malignant potential and a close follow-up to pick up changes in the nevus size.

Conflict of interest

The authors declared that there is no conflict of interest.

References

1. Medlock RD, Shields JA, Shields CL, Yarian DL, Beyrer CR. Retinal hemangioma-like lesions in eyes with retinitis pigmentosa. *Retina* 1990;10(4):274–7.
2. Nagao Y, Hiramoto Y, Takahashi K. A case of retinitis pigmentosa with retinal angiomatous proliferation. *Nihon Ganka Gakkai Zasshi* 2011;115(2):147–50.
3. Ishida T, Moriyama M, Morohoshi K, Furuse Y, Fukuda T, Ohno-Matsui K. Polypoidal choroidal vasculopathy in a case with retinitis pigmentosa. *Int Ophthalmol* 2013;33(3):305–8. <http://dx.doi.org/10.1007/s10792-012-9657-7> Epub 2012 Nov 7.
4. Li HK, Shields JA, Shields CL, Maguire JI, Garg SJ. Retinal vasoproliferative tumour as the initial manifestation of retinitis pigmentosa. *Clin Exp Ophthalmol* 2008;36(9):895–7.
5. Robbins S, Cotran R, Kumar V. *Pathologic basis of disease*. Philadelphia: WB Saunders; 1984.
6. Torczynski E. Choroid and suprachoroid. In: Jakobiec F, editor. *Ocular anatomy, embryology, and teratology*. Philadelphia: Harper & Row; 1982.
7. Langham ME, Kramer T. Decreased choroidal blood flow associated with retinitis pigmentosa. *Eye* 1990;4:374–81.
8. Ayala F, Palla M, Trolio RD, Mozzillo N, Ascierio PA. The role of optical radiations in skin cancer. *ISRN Dermatol* 2013.
9. van Gils Walter, Kilica Emine. Regional deletion and amplification on chromosome 6 in a uveal melanoma case without abnormalities on chromosomes 1p, 3 and 8. *Melanoma Res* 2008;18(1):10–5.
10. Bashir R, Inglehearn CF. Exclusion of chromosome 6 and 8 locations in nonrhodopsin autosomal dominant retinitis pigmentosa families: further locus heterogeneity in adRP. *Genomics* 1992;14(1):191–3.
11. Gündüz K, Shields JA, Shields CL, Zhao DY. Choroidal melanoma in a patient with retinitis pigmentosa and Usher's syndrome. *Br J Ophthalmol* 1998;82(7):847–8.
12. Eagle Jr RC, Shields JA. Pseudoretinitis pigmentosa secondary to preretinal malignant melanoma cells. *Retina* 1982;2(1):51–5.