

## Isochromosome Mosaic Turner Syndrome: A Case Report\*

Mark Ramon Victor Llanes and May Uyking-Naranjo

*Southern Philippines Medical Center, Davao City, Philippines*

### Abstract

Turner syndrome (TS) with an isochromosome mosaic karyotype 45,X/46,X,i(X) (q10) is an unusual variant, with only an 8-9% prevalence among women with TS based on international studies and 15% of all TS in the Philippines. Clinical features are atypical and any case should be investigated to detect potential complications.

A 20-year-old female came in due to amenorrhea and alopecia. Physical examination revealed short stature, cubitus valgus and Tanner Stage 1 pubic hair and breast development. Transrectal ultrasound revealed absent ovaries and infantile uterus. Hormonal evaluation revealed hypergonadotropic hypogonadism. Bone aging was that of a 13-year-old for females with non-fusion of epiphyseal plates. Cytogenetic study revealed 45,X [37]/46, X, i (X) (q10)[13]. This is consistent with a variant Isochromosome Mosaic Turner Syndrome (IMTS).

She was screened for medical complications. Audiogram and two-dimensional echocardiography were unremarkable. She has dyslipidemia and was given a statin. She has subclinical hypothyroidism with positive test for anti-thyroglobulin antibody. Her intelligence quotient (IQ) was below average. She received conjugated estrogen and progesterone that patterned the hormonal changes in a normal menstrual cycle. On the third week of hormonal therapy, she developed breast mound and on the fourth week, she had her first menstrual period. Her alopecia spontaneously resolved.

The case is a variant of Turner Syndrome requiring supportive, medical and psychological care.

*Key words: Turner Syndrome, isochromosome, primary amenorrhea, alopecia, hypergonadotropic hypogonadism, delayed puberty*

### INTRODUCTION

Isochromosome mosaic Turner Syndrome (IMTS) is a variant of Turner Syndrome (TS) characterized by a cytogenetic profile of 1 or more additional cell lineages aside from 45,X, and the presence of a structurally abnormal X chromosome consisting of either two short or two long arms.<sup>1</sup> IMTS occurs in only 8-9% prevalence among women with TS based on international studies, and 15% of all TS in the Philippines.<sup>2</sup>

Turner Syndrome has a broad range of clinical phenotypes.<sup>3</sup> Patients may present with subtle physical manifestations to more complex conditions such as cardiovascular malformations, aortic dissection and ovarian failure. Manifestations of IMTS may vary and is less severe compared to the most common variant of TS, (pure monosomy X or 45,X).<sup>4</sup>

This report presents a 20-year-old female with primary amenorrhea and alopecia who was diagnosed with IMTS. This case emphasizes the importance of karyotyping in the diagnosis of diseases presenting with atypical

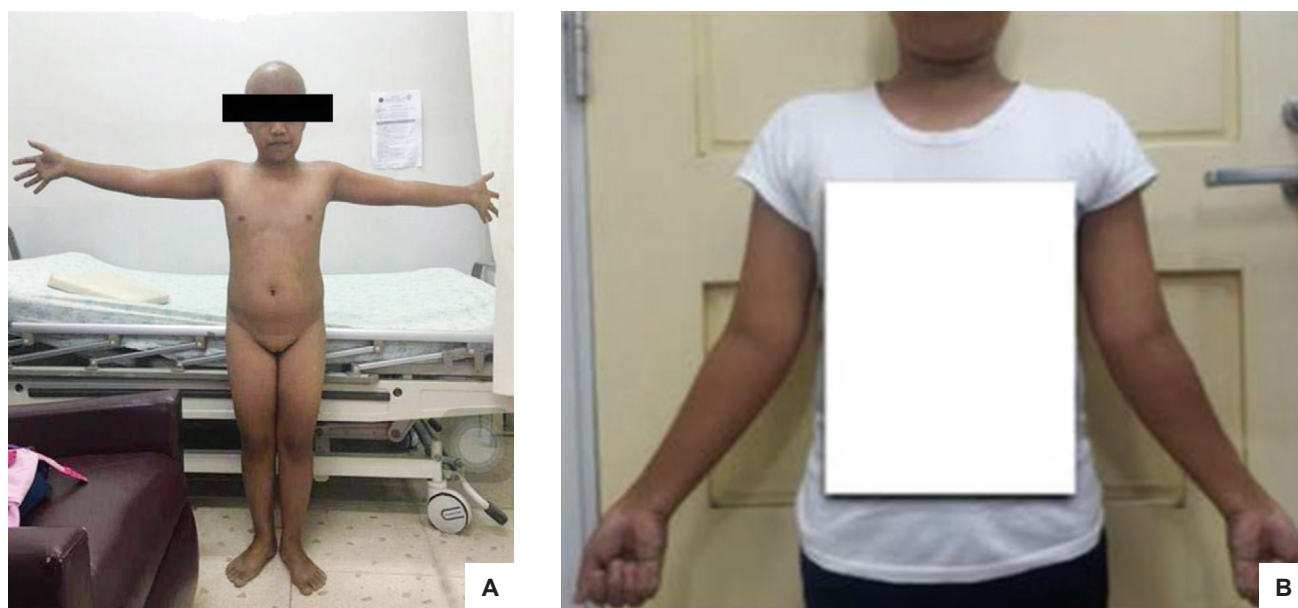manifestations, especially in TS, because clinical phenotype varies with specific karyotypes. It also highlights the need for a multidisciplinary approach in the management of Turner Syndrome to promptly detect and prevent complications.

### CASE

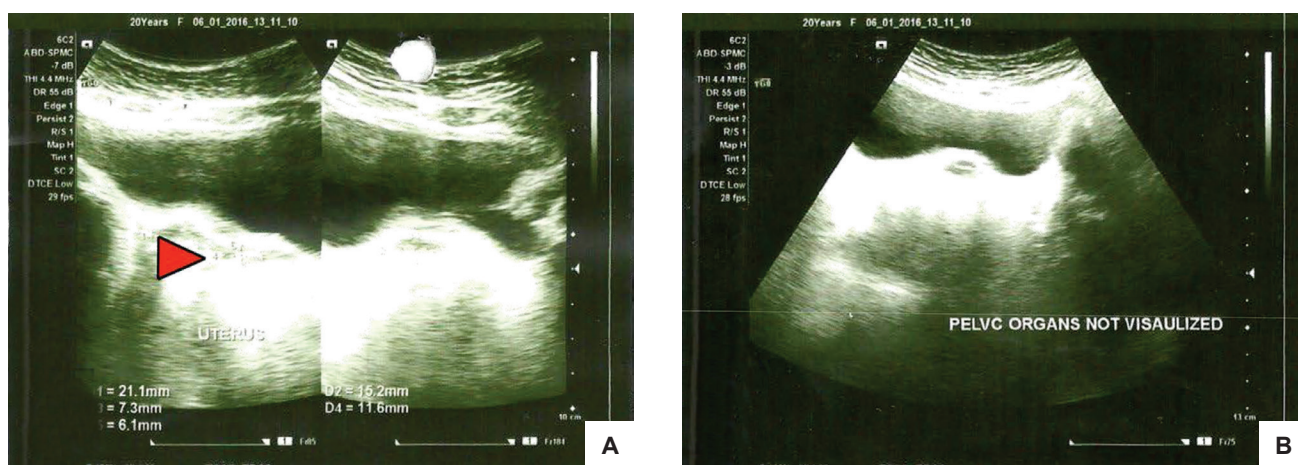
MC, a 20-year-old Filipino female was seen at our outpatient clinic because of primary amenorrhea.

One year prior to consult, the patient sought advice with an obstetrician due to amenorrhea despite reaching reproductive age. Transabdominal ultrasound revealed non-visualized ovaries and infantile uterus. No medications were prescribed and the patient was lost to follow up. One month prior to consult, she developed alopecia at the posterior scalp which gradually involved the parietal area thus prompting consultation.

Past medical history revealed no previous hospitalizations and no other comorbidities. She is the 10<sup>th</sup> child of a 41-year-old mother, born at a tertiary hospital from a



**Figure 1.** On physical examination, the patient has (A) short stature, alopecia and underdeveloped secondary sexual characteristics and (B) a wide carrying angle or cubitus valgus.



**Figure 2.** Transrectal ultrasound revealed (A) infantile uterus (red arrow) and (B) non-visualized ovaries.

non-consanguineous marriage with no known pregnancy-related complications. No newborn screening was done. There was no known heredo-familial illness, nor a family history of short stature or delay in menses of female family members. She is nulligravid with no sexual contact, and denied smoking, alcoholic beverage intake and illicit drug use. She finished high school and was assessed to be an average student.

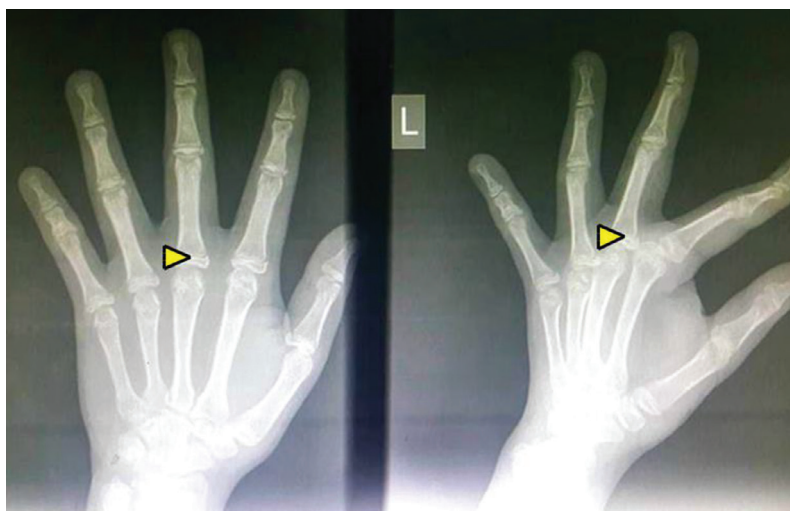
At the time of presentation, she was ambulatory with a height of 134 cm and weight of 37 kg. The patient’s height was plotted on the growth chart and revealed short stature. The computed mid-parental height was 152. 25 cm. Her arm span was 139 cm (Figure 1A), and her body mass index (BMI) was 20.67 kg/m<sup>2</sup>. Her vital signs were within normal range.

On physical examination, there was alopecia (Figure 1A) and wide carrying angle or cubitus valgus of the elbows (Figure 1B). There was no facial dysmorphism and webbing of the neck. Eyebrows and eyelashes were present and equally distributed. Otoroscopic, cardiopulmonary and


abdominal examinations were unremarkable. Her pubic hair and breast development were Tanner Stage 1, with no axillary hair. Genital examination revealed a grossly female genitalia with presence of a small clitoris at 0.3 cm and vaginal canal of 5 cm in length. No inguinal masses were palpated. She had no neurologic deficits.

Her complete blood count (CBC) and creatinine were unremarkable. Lipid profile revealed elevated cholesterol (5.70 mmol/L), high density lipoprotein (1.73 mmol/L) and low density lipoprotein (3.61 mmol/L), with normal triglycerides (0.79 mmol/L) and very low density lipoprotein (0.36 mmol/L).

Hormonal evaluation showed hypergonadotropic hypogonadism with elevated follicle-stimulating hormone (FSH) at 82.58 mIU/ml, elevated luteinizing hormone (LH) at 32.38 mIU/ml, low estradiol at <5.00 pg/ml, and low testosterone at <0.025 ng/ ml. Transrectal ultrasound showed a thin endometrium with minimal hydrometra, an infantile uterus measuring 3.6 x 1.6 x 0.8 cm and absent ovaries (Figure 2). Radiograph of the left wrist revealed



**Figure 3.** Radiograph of the left wrist revealed non-fusion of epiphyseal plates (yellow arrowheads) with bone aging for female of 13 years old by Greulich and Pyle standards.



**Figure 4.** Cytogenetic analysis showing the (A) first cell line with loss of one X chromosome, resulting in monosomy X, while (B) the second cell line with an isochromosome of the long arm of X chromosome.

non-fusion of epiphyseal plates with bone aging for female of 13 years old by Greulich and Pyle standards (Figure 3). Cytogenetic study of peripheral blood through G-banding technique revealed two cell lines present. The first cell line, seen in 37 cells, showed loss of one X chromosome, resulting in monosomy X (Figure 4A). The remaining 13 cells showed an isochromosome of the long arm of the X chromosome (Figure 4B). Her karyotype is 45,X [37]/46, X,i (X) (q10)[13]. This is consistent with the diagnosis of IMTS variant.

She was screened for potential complications and associated conditions. Her serum thyroid stimulating hormone (TSH) level was elevated at 6.65 mIU/L with normal free thyroxine (T4) and triiodothyronine (T3). Anti-thyroglobulin antibody was elevated at 936.78 IU/ml. Audiogram revealed bilateral normal hearing acuity. Ultrasound of the kidneys was unremarkable (Figure 5). Two-dimensional echocardiography revealed adequate ejection fraction, and absence of bicuspid aortic valve or

coarctation of the aorta. Test for intelligence quotient (IQ) by Culture Fair Intelligence Test Scale revealed a score of 70-79 (below average).

The benefits and risks of growth hormone (GH) therapy were discussed with the patient and her family. However, due to financial constraints, GH therapy was not initiated. She was given with oral conjugated estrogen (0.3 mg/day) on the first 6 days, titrated (0.6 mg/day) for the next 22 days. Progesterone was added for 10 days, starting on the 19<sup>th</sup> day. On the third week of hormonal therapy, she developed breast mound and on the fourth week, she had her first menstrual period. Her alopecia resolved spontaneously *within one month*. In addition, the patient also underwent counseling about her fertility status and the probability and the risks of future pregnancies.

Informed consent was also taken for the publication of this case.



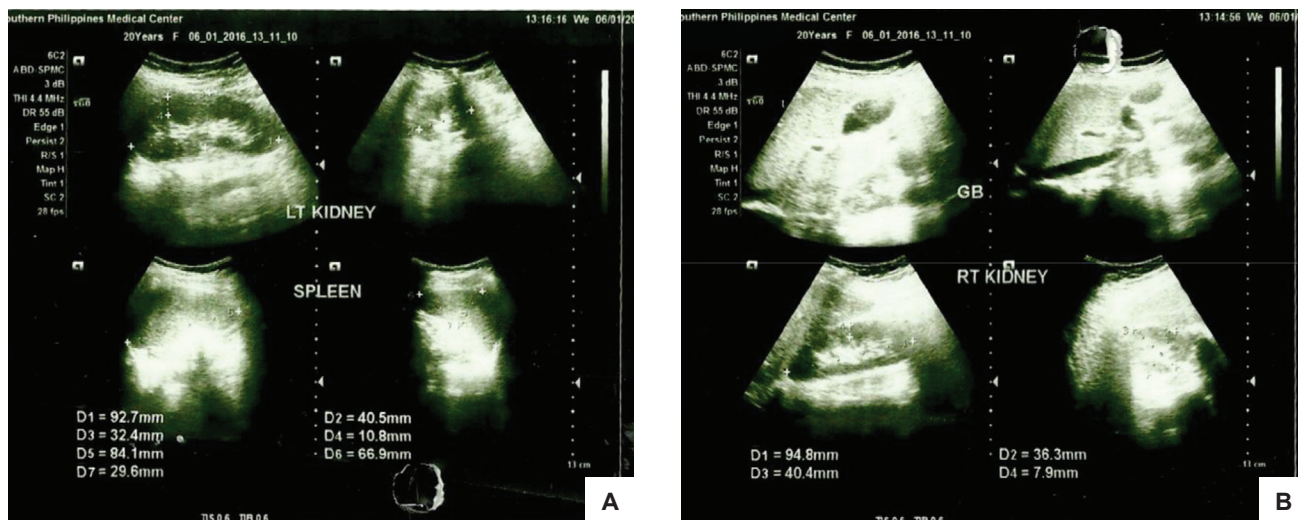


Figure 5. Ultrasound of the abdomen revealed presence of normal left (A) and right (B) kidneys.

**DISCUSSION**

Turner Syndrome (TS), or 45,X, is a condition in which a female is partly or completely missing an X chromosome. It is one of the sex chromosome disorders of sexual development (DSD)<sup>5</sup> that affects 1 in 2,500 to 1 in 3,000 female live births.<sup>1</sup> According to the karyotype, there are several variants of TS with monosomy X as the most common.<sup>6</sup> Other types include [1] deletions of the short arm (Xp) or long arm (Xq), [2] formations of ring chromosome (rX), [3] isochromosomization or duplication of the long arm to form an isochromosome (Xi), and [4] mosaicism, where a monosomy X (45,X) cell line is accompanied by one or more cell lines having a complete or structurally abnormal X chromosome.

In this case, karyotype revealed 45, X/46, X, i, (X) (q10) – a combination of mosaicism and isochromosomization. The prevalence of isochromosome mosaic karyotype is 8 - 9%.<sup>1,7</sup> In the Philippines, TS comprises about 80% of all sex chromosome abnormalities, of which 38.9% had the classic pure monosomy X while only 15% had the isochromosome mosaic variant.<sup>2</sup>

The typical manifestations for Turner Syndrome are short stature, gonadal dysgenesis, characteristic facial features, webbed neck, low posterior hairline, broad chest with widely spaced nipples, nevi all over the body, shortened metacarpals, small fingernails, poor breast development, and renal and cardiovascular anomalies. However, most of these clinical symptoms greatly vary depending on the karyotype variant. Of particular note, patients with mosaicism for 46 XX or X isochromosome, have been shown to have milder phenotypes.<sup>8</sup> Hence, for this patient, some of the typical manifestations were not evident.

Short stature is the most readily recognizable finding in women with TS. The deficit in height is caused by the haploinsufficiency of the short stature homeo-box containing gene (SHOX) located within the Xp terminal, the pseudoautosomal region of the X chromosome. Aside from short stature, many of the physical stigmata of TS are a result of structural bone defects as SHOX expression is highly localized at the elbow, knee and wrist.<sup>9</sup> Particularly,

cubitus valgus, or increased outward angulation of the arms when they are fully extended, as seen in our patient, is a result of a developmental defect of the ulnar head because of the SHOX gene haploinsufficiency.

Hypergonadotropic hypogonadism is a result of ovarian failure and the lack of feedback inhibition to the pituitary gland. In patients with TS, partial or complete absence of the X chromosome in the germ cells leads to an accelerated degeneration of oocytes and increase in ovarian stromal fibrosis; thus, the absence of ovaries on ultrasound in our patient is an expected finding.<sup>10</sup> Ovarian failure is the reason for the absence of secondary sexual characteristics of our patient.

Alopecia is an immune-related dermatological condition that is 3 times more common in women with TS.<sup>4</sup> There have only been five cases of alopecia in TS reported worldwide.<sup>8,11</sup> One case had a karyotype of 45,XX/45,X<sup>7</sup> while the specific karyotypes of the other 4 cases<sup>10</sup> were not mentioned.

Cardiovascular complications are a common cause of increased mortality in TS,<sup>12</sup> and occurs specifically in 29% of TS with isochromosome mosaicism. Bicuspid aortic valve is the most common congenital malformation affecting the heart<sup>13,14</sup> and may also occur in combination with other anomalies, particularly aortic coarctation. Two-dimensional echocardiography of our patient, however, did not reveal any of these anomalies. In addition, the incidence of developing ischemic heart disease is two-fold among adults with TS compared with the general population<sup>8</sup> and one of the risk factors is hyperlipidemia which was demonstrated to be significantly higher compared to normal controls.<sup>15</sup> This is congruent with the hyperlipidemic profile of our patient who had elevated cholesterol, HDL and LDL; hence, she was given a lipid-lowering agent.

Hypothyroidism affects 25 to 30% of adults with TS and can be attributed to an autoimmune thyroid disease.<sup>16</sup> Thyroid autoantibodies, such as antimicrosomal and antithyroglobulin antibodies, are present in 22-41% of women with TS.<sup>17,18</sup> It is noteworthy that thyroid

autoantibodies have been found to be prevalent in women with the isochromosome [46,Xi(Xq)] karyotype (83%) compared with monosomy 45,X (41%) and other karyotypes (14%).<sup>3</sup> In our patient, elevated antithyroglobulin and subclinical hypothyroidism were present. Although thyroid supplementation was not warranted as of this time, annual evaluation of thyroid function tests is recommended for monitoring.

Structural malformations in the kidneys<sup>19</sup> and the ears<sup>20</sup> are also common among patients with TS. Our patient, however, had unremarkable renal ultrasound, otoscopic examination and audiogram.

In terms of cognitive impairment and behavioral function, a significant number of women with TS have deficits in specific areas of intellectual performance and its severity has been shown to be related to the karyotype. Generally, females with TS have normal intelligence -- with the exception of those with mosaic karyotype, particularly IMTS, where 9% present with mental retardation.<sup>4</sup> Our patient's IQ was within the 70-79 range using a standardized tool. This is comparable to an individual with a below average mental ability. It was noted, however, that the subject is educable, although with limited trainability. She is fit and can be employed to fulfill simple tasks or routinized jobs; hence, although with TS, the patient can ordinarily live, work and may overcome deficits in certain aspects of learning.

### Management

After screening for and addressing the medical complications, management was aimed at maximizing adult height, development of secondary sexual characteristics and health teaching and counseling on fertility, long term plans and follow up.

Growth Hormone (GH) therapy should be considered for every patient diagnosed with Turner Syndrome. Treatment with recombinant Growth Hormone (GH) (0.375 mg/kg/week divided into seven once-daily doses), with or without oxandrolone (0.0625 mg/kg/day by mouth), is recommended to maximize patient's height.<sup>21</sup> In most cases, treatment starts at around 5-6 years of age and continues until the patients have stopped growing or when the epiphyses have already fused, at around 15-16 years.<sup>8</sup> The bone age, and not the chronological age, will determine how long she can continue to grow. In our case, bone aging revealed non-fusion of epiphyseal plates compatible with a 13-year-old female by Greulich and Pyle standards; ideally, our patient should receive GH therapy but this was not possible due to financial constraints.

For the development of secondary sexual characteristics, the current regimen for pubertal induction in girls with no spontaneous menses mandates low dose estrogen (0.3 mg) at age 14-15 years old, gradually increased to 1.25 to 2.5 milligrams and then cycled with medroxyprogesterone, or less frequently with progesterone.<sup>22</sup> Our patient was initially given low-dose oral conjugated estrogen, with uptitration of dose and addition of progesterone to pattern the physiologic hormonal elevation of normal menstrual cycle.

In terms of fertility and pregnancy, spontaneous pregnancies in women with Turner Syndrome are rare, and may be associated with higher rates of spontaneous abortions, fetal malformations and chromosomal abnormalities. Since most patients are infertile, a modality that has been used for fertility treatment include donor oocyte with in vitro fertilization. However, patients must be counseled that deaths may occur with pregnancies due to the cardiovascular complications such as aortic dissection.<sup>23</sup>

Long term plans for this patient include monitoring of the development of secondary sexual characteristics and appropriate titration of hormonal replacement therapy. Physical examination, lipid profile, fasting blood glucose, and thyroid, liver and renal function tests should be done annually, while echocardiography, bone densitometry and audiogram should also be checked every 3-5 years.

### CONCLUSION

Our case of an isochromosome mosaic variant of Turner Syndrome who presented with alopecia, primary amenorrhea, absence of secondary sexual characteristics and short stature has emphasized three points.

First, the value of a karyotyping analysis in the evaluation of patients with atypical presentations is substantial, on top of other preliminary work-ups. In this case, it has confirmed the diagnosis of an isochromosome mosaic Turner Syndrome, thus, facilitating its prompt management.

Second, this report has established that Turner Syndrome has several variants. There is a phenotypic variability in patients with TS depending on the karyotype and for isochromosome mosaicism, the manifestations are less severe compared to the more common form of pure 45,X.

Third, this has highlighted the importance of a multi-disciplinary approach, intensive work-up and thorough screening from the onset of diagnosis in a patient with TS to promptly detect and prevent complications. Understanding the pathophysiology of TS, it is recommended that physicians who handle these patients should use a holistic approach to management that would encompass the medical and psychological problems.

### Ethical Consideration

Patient consent was obtained before submission of the manuscript.

### Statement of Authorship

All authors certified fulfilment of ICMJE authorship criteria.

### Author Disclosure

The authors declared no conflict of interest.

### Funding Source

None.

### References

1. Sybert V, McCauley E. Turner's syndrome. *N Eng J Med.* 2004;351(12):1227-38. PMID: 15371580. <https://doi.org/10.1056/NEJMra030360>.
2. David-Padilla C, Cutiongco-de la Paz EM, Cadag NS, Salonga EAG, Chiong MAD. A review of the results of chromosomal analyses done at the National Institutes of Health from 1991 to 2007. *Acta Med Philipp.* 2009;43(1):4-6. Available from: <http://apamedcentral.org/search.php>

3. Lippe B. Turner syndrome. *Endocrinol Metab Clin North Am.* 1991;20(1): 121-52. PMID: 2029883.
4. Elsheikh M, Dunger DB, Conway GS, Wass JA. Turner's syndrome in adulthood. *Endocrine Rev.* 2002;23(1):120-40. PMID: 11844747. <https://doi.org/10.1210/edrv.23.1.0457>.
5. Hughes IA, Houk C, Ahmed SF, Lee PA; LWPES Consensus Group; ESPE Consensus Group. Consensus statement on management of intersex disorders. *Arch Dis Child.* 2006;91(7):554-562. PMID: 16624884. PMID: PMC2082839. <https://doi.org/10.1136/adc.2006.098319>.
6. Al Awan I, M K, Amir 1st, et al. Turner syndrome genotype and phenotype and their effect on presenting features and timing of diagnosis. *Int J Health Sci (Qassim).* 2014;8(2):195-202. PMID: 25246887. PMID: PMC4166992.
7. Akbaş E, Yazıcı FG, Durukan H, Topal H, Erdoğan NE. Cytogenetic and clinical evaluation of two cases that have 45,X/46,X,i(Xq) and 46,X,i(Xq) karyotype 45,X/46,X,i(Xq) ve 46,X,i(Xq). *J Clin Exp Invest.* 2014; 5(3):444-8. <https://doi.org/10.5799/ahinjs.01.2014.03.0436>.
8. Muntaj S, Ganale FA, Purva SV, Radhika S, Tilak P. Karyotypic variables in Turner syndrome: A case series. *Int J Sci Study.* 2015;3(4):171-5. <https://doi.org/10.17354/ijss/2015/330> Available from: [http://www.ijss-sn.com/uploads/2/0/1/5/20153321/ijss\\_jul\\_cr03.pdf](http://www.ijss-sn.com/uploads/2/0/1/5/20153321/ijss_jul_cr03.pdf)
9. Gravholt CH. Epidemiological, endocrine and metabolic features in Turner syndrome. *Eur J Endocrinol.* 2004;151(6):657-87. PMID: 15588233. <https://doi.org/10.1530/eje.0.1510657>.
10. Haber HP, Ranke MB. Pelvic ultrasonography in Turner syndrome: Standards for uterine and ovarian volume. *J Ultrasound Med.* 1999;18(4):271-6. PMID: 10206214 DOI: 10.7863/jum.1999.18.4.271.
11. Tebbe B, Golinick H, Müller R, Reupke HJ, Orfanos CE. Alopecia areata and diffuse hypotrichosis associated with Ullrich-Turner syndrome. Presentation of 4 patients. *Hautarzt.* 1993;44(10):647-52. PMID: 8225974.
12. Naeraa RW, Gravholt CH, Hansen J, Nielsen J, Juul S. Mortality in Turner syndrome. In: Albertsson-Wikland K, Ranke MB, eds. *Turner syndrome in a lifespan perspective: Research and clinical aspects.* Amsterdam: Elsevier, 1995.
13. Miller MJ, Geffner ME, Lippe BM, et al. Echocardiography reveals a high incidence of bicuspid aortic valve in Turner syndrome. *J Pediatr.* 1983;102(1):47-50. PMID: 6848727. [https://doi.org/10.1016/s0022-3476\(83\)80284-4](https://doi.org/10.1016/s0022-3476(83)80284-4).
14. Gøtzsche CO, Krag-Olsen B, Nielsen J, Sørensen KE, Kristensen BO. Prevalence of cardiovascular malformations and association with karyotypes in Turner's syndrome. *Arch Dis Child.* 1994;71(5):433-6. PMID: 7826114. PMID: PMC1030059. <https://doi.org/10.1136/adc.71.5.433>.
15. Ross JL, Feuillan P, Long LM, Kowal K, Kushner H, Cutler GB Jr. Lipid abnormalities in Turner syndrome. *J Pediatr.* 1995;126(2):242-5. PMID: 7844670. [https://doi.org/10.1016/s0022-3476\(95\)70551-1](https://doi.org/10.1016/s0022-3476(95)70551-1).
16. Sylvén L, Hagenfeldt K, Brøndum-Nielsen K, von-Schoultz B. Middle-aged women with Turner's syndrome. Medical status, hormonal treatment, and social life. *Acta Endocrinol (Copenh).* 1991;125(4):359-65. PMID: 1957555. <https://doi.org/10.1530/acta.0.1250359>.
17. Radetti G, Mazzanti L, Paganini C, et al. Frequency, clinical and laboratory features of thyroiditis in girls with Turner's syndrome. The Italian Study Group for Turner's Syndrome. *Acta Paediatr.* 1995;84(8):909-12. PMID: 7488816. <https://doi.org/10.1111/j.1651-2227.1995.tb13791.x>.
18. Elsheikh M, Wass JA, Conway GS. Autoimmune thyroid syndrome in women with Turner's syndrome—the association with karyotype. *Clin Endocrinol (Oxf).* 2001;55(2):223-6. PMID: 11531929. <https://doi.org/10.1046/j.1365-2265.2001.01296.x>.
19. Bilge I, Kayserili H, Emre S, et al. Frequency of renal malformations in Turner syndrome: Analysis of 82 Turkish children. *Pediatr Nephrol.* 2000;14(12):1111-4. PMID: 11045397. <https://doi.org/10.1007/s004670000315>.
20. Sculerati N, Oddoux C, Clayton CM, Lim JW, Oster H. Hearing loss in Turner syndrome. *Laryngoscope.* 1996;106(8):992-7. PMID: 8699915 DOI: 10.1097/00005537-199608000-00015.
21. Bondy CA. New issues in the diagnosis and management of Turner syndrome. *Rev Endocr Metab Disord.* 2005;6(4):269-80. PMID: 16311945. <https://doi.org/10.1007/s11154-005-6185-z>.
22. Turner Syndrome. In Gardner D, Shoback D, eds. *Greenspan's basic and clinical endocrinology* (Lange Medical Books), 8th ed. Philadelphia: McGraw-Hill Medical, 2007.
23. Gomez-Lobo, V, Amies Oelschlagel AM; North American Society for Pediatric and Adolescent Gynecology. Disorders of sexual development in adult women. *Obstet Gynecol.* 2016;128(5):1162-73. PMID: 27741188. PMID: PMC5119649. <https://doi.org/10.1097/AOG.0000000000001672>.

Authors are required to accomplish, sign and submit scanned copies of the JAFES Author Form consisting of: (1) Authorship Certification, that authors contributed substantially to the work, that the manuscript has been read and approved by all authors, and that the requirements for authorship have been met by each author; (2) the Author Declaration, that the article represents original material that is not being considered for publication or has not been published or accepted for publication elsewhere, that the article does not infringe or violate any copyrights or intellectual property rights, and that no references have been made to predatory/suspected predatory journals; (3) the Author Contribution Disclosure, which lists the specific contributions of authors; and (4) the Author Publishing Agreement which retains author copyright, grants publishing and distribution rights to JAFES, and allows JAFES to apply and enforce an Attribution-Non-Commercial Creative Commons user license. Authors are also required to accomplish, sign, and submit the signed ICMJE form for Disclosure of Potential Conflicts of Interest. For original articles, authors are required to submit a scanned copy of the Ethics Review Approval of their research as well as registration in trial registries as appropriate. For manuscripts reporting data from studies involving animals, authors are required to submit a scanned copy of the Institutional Animal Care and Use Committee approval. For Case Reports or Series, and Images in Endocrinology, consent forms, are required for the publication of information about patients; otherwise, appropriate ethical clearance has been obtained from the institutional review board. Articles and any other material published in the JAFES represent the work of the author(s) and should not be construed to reflect the opinions of the Editors or the Publisher.



**A new venue for publishing your original articles.**  
**Visit [www.ASEAN-endocrinejournal.org](http://www.ASEAN-endocrinejournal.org) for**  
**Instructions to Authors.**