



Contents lists available at ScienceDirect

International Journal of Surgery Case Reports

journal homepage: www.casereports.com

Giant gastric lipoma presenting as GI bleed: Enucleation or Resection?



Salah Termos*, Ossama Reslan, Omar Alqabandi, Abdullah AlDuwaisan, Saud Al-Subaie, Khalifa Alyatama, Mohammad Alali, Ahmad AlSaleh

Hepatobiliary and Transplant unit, Department of Surgery, Al-Amiri Hospital, Kuwait

ARTICLE INFO

Article history:

Received 19 September 2017

Accepted 4 October 2017

Available online 6 October 2017

Keywords:

Case report

Lipoma

Gastric lipoma

GI bleeding

Enucleation

Gastric resection

ABSTRACT

INTRODUCTION: Gastric lipomas are unusual benign lesions and account for less than 1% of all tumours of the stomach and 5% of all gastrointestinal lipomas (Thompson et al. 2003; Fernandez et al. 1983 [1,2]). Although predominantly asymptomatic and indolent; they may present with gastric outlet obstruction and upper gastrointestinal (GI) bleeding owing to size and ulceration. Only a few cases have been reported, presenting large in size with massive GI bleeding (Alcalde Escribano et al. 1989; Johnson et al. 1981 [3,4]). **PRESENTATION OF CASE:** We report the case of a 62-year-old gentleman who presented to the emergency department with massive upper GI hemorrhage. He was initially resuscitated and stabilized. Later gastroscopy showed a large submucosal tumour (Fig. 1). Biopsy revealed adipose tissue. Computed tomography (CT) scan of the abdomen and pelvis showed a huge well defined oval soft tissue lesion measuring about 16 × 8 × 8 cm. The mass noted a homogenous fat density arising from the posterior wall of stomach with no extramural infiltration (Fig. 2). The tumour was completely enucleated through an explorative gastrotomy incision (Fig. 4).

DISCUSSION AND CONCLUSION: Massive bleeding secondary to a giant gastric lipoma is a rare finding of a rare disease. The majority of cases in the literature result in major gastric resection. Familiarity with its radiological findings and a high index of suspicion can lead to proper diagnosis in the acute setting. If malignancy is carefully ruled out, stomach preserving surgery is an optimal treatment option.

© 2017 The Authors. Published by Elsevier Ltd on behalf of IJS Publishing Group Ltd. This is an open access article under the CC BY-NC-ND license (<http://creativecommons.org/licenses/by-nc-nd/4.0/>).

1. Introduction

Gastrointestinal lipomas are uncommon, slow growing benign tumours composed of mature adipose tissue surrounded by a fibrous capsule that can occur anywhere along the gut. Most are found in the colon, ileum and jejunum [5]. Lipomas found in the stomach are even more unusual, accounting for 2%–3% of all benign gastric tumours [6]. Most lipomas are found in the submucosa (95%), with a subserosal gastric lipoma being extremely rare. They are usually solitary and most commonly found in the antrum in 75% of gastric cases [7]. Although they are usually asymptomatic, it has been reported that a lipoma greater than 2 cm in size will present with abdominal pain more than 50% of the time. In previous studies, 37% of cases presented with either chronic or acute GI bleeding, obstruction, and dyspepsia [8,9]. The majority of large stomach lipomas that have been reported were treated by major gastric resection. We describe a case involving a giant gastric lipoma that presented with massive gastrointestinal bleeding and was managed by simple enucleation.

2. Case presentation

In our manuscript, we report the case of a 62-year-old gentleman, known to suffer from hypertension, who presented to the emergency department with a sudden episode of dizziness and syncope followed by hematemesis. He had a similar episode of upper gastrointestinal bleeding 5 years prior, where upper GI endoscopy documented a positive *Helicobacter pylori* induced gastric ulcer. He received triple therapy, and was then kept on long-term proton pump inhibitors. Recently the patient noted occasional post-prandial epigastric pain and fullness, associated with a weight loss of 10 kg over a span of six months. He denied any history of smoking or alcohol consumption.

On physical examination, the patient was tachycardic with a heart rate of 136, and had a blood pressure of 90/60. He was pale but conscious and orientated. Cardiovascular and respiratory examinations were normal. His abdomen was soft, non-distended, bowel sounds were present and no palpable masses were felt. His laboratory investigations showed a haemoglobin value of 6.3 g/dl and a haematocrit of 20%. The remainder of his blood investigations was unremarkable.

The patient was initially resuscitated and stabilized with intravenous fluids and three units of packed red blood cells. A nasogastric tube was inserted which produced 500 ml of fresh blood,

* Corresponding author at: Dr. Salah Termos, HPB and Transplant surgeon, Al-Amiri Hospital, 25 Arabian Gulf Street, Kuwait City, 13041, Kuwait.

E-mail addresses: dr.termos@hotmail.com, salahtermos@gmail.com (S. Termos).

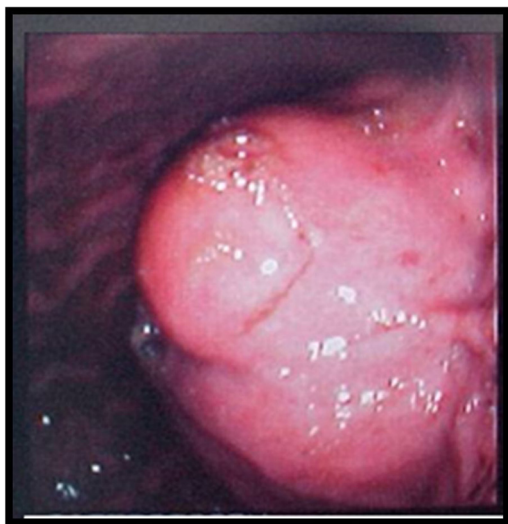

Fig. 1. Gastroscopy showing a large bulging submucosal mass.

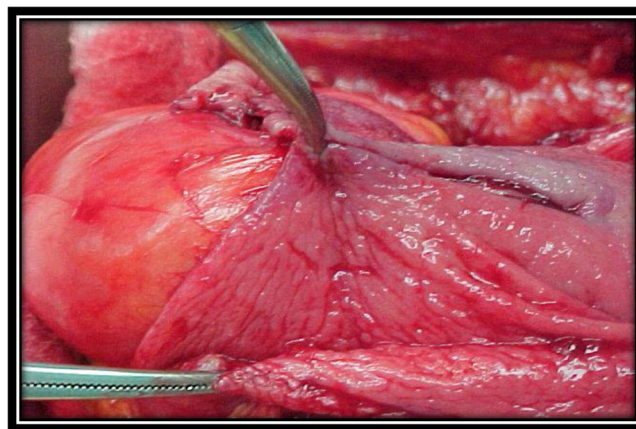


Fig. 3. Intraoperative finding of huge submucosal tumour.

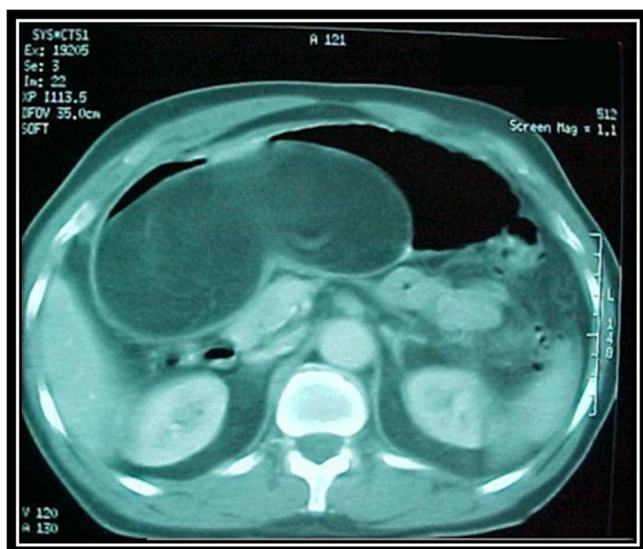


Fig. 2. CT scan showing a large well-defined oval shaped soft tissue lesion of fat density arising from the posterior wall of the stomach.

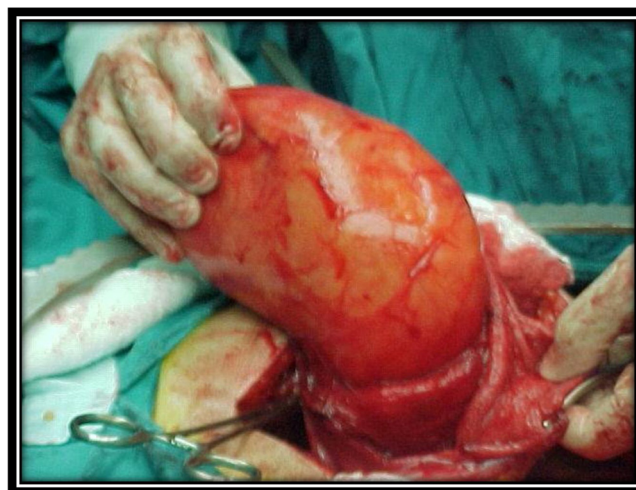


Fig. 4. Enucleation of the giant gastric lipoma.

and was then admitted to the ward under close observation. The patient underwent an urgent upper GI endoscopy which showed a large bulging submucosal tumour extending from the gastroesophageal junction to the pylorus along the lesser curvature of the stomach with a 4 cm linear ulcer over the mass (Fig. 1). No active bleeding was seen during the procedure. Multiple biopsies were taken which yielded adipose tissue with no proliferative process. A CT scan of the abdomen and pelvis showed a 17 × 9 × 8 cm well-defined oval shaped soft tissue lesion of fat density arising from the posterior wall of the stomach, with no associated lymphadenopathy (Fig. 2). The liver, spleen, and pancreas all appeared normal and tumour markers (CEA, CA 19.9) were within normal values.

Benign gastric pathology was suspected and the patient's case was discussed in a multi-disciplinary team meeting. The joint decision was to proceed with an exploratory laparotomy and resect the likely benign mass. A midline laparotomy was performed and the stomach appeared to be thin with a hard mass integrated in its wall. The stomach was incised at its body using a 10 cm incision and a huge submucosal mass was visualized with overlying ulcerated mucosa. It was well marginated, yellow in color, oval shaped, and

firm in consistency (Fig. 3). The mass was easily dissected and enucleated (Fig. 4). The stomach was refashioned with primary repair. Histological examination was suggestive of a giant mural benign lipoma of the stomach with no mitotic activity or atypical cells. The overlying mucosa revealed chronic inflammation. His post-operative course was uneventful and a follow up gastroscopy in 3 and 6 months showed no abnormal findings.

3. Discussion and conclusion

Gastric lipomas are a location-specific subtype of gastrointestinal lipomas and represent rare benign mesenchymal tumours of the stomach. They are most prevalent between the fifth and seventh decades of life, and are found mainly in women [10]. They account for 1% of all tumors [1,2] and are usually found incidentally during routine endoscopy or during the investigative work-up for another pathology. Larger lesions however may cause a wide range of symptoms, from ulceration and bleeding which may cause hematemesis or melaena, to symptoms of early satiety, indigestion and may even cause gastric outlet obstruction. The differential diagnosis of a gastric lipoma includes peptic ulcer disease, stromal tumour, liposarcoma, fibroma, gastrointestinal stromal tumour or a glomus tumour [8,9].

Diagnosis can be established by CT scan, and confirmed with endoscopy and biopsy. In the past, prior to the availability of modern imaging modalities, the diagnosis was generally made after surgical resection [11,12]. Barium studies of extra-mucosal

Table 1

Reported cases of giant gastric lipoma measuring above 8 cm, illustrating the size, clinical presentation and type of surgery.

Study group	Presentation	Size	Type of resection
Singh et al. [21]	Melena	18 × 10 × 10 cm	Subtotal gastrectomy with gastrojejunostomy
Ramaraj et al. [22]	Chronic anemia, early satiety	15 × 14 cm	Subtotal gastrectomy with gastrojejunostomy
Rao et al. [23]	Chronic anemia	15 × 12 cm	Partial gastrectomy
Priyadarshi et al. [24]	Melena	14 × 11 × 5 cm	Distal gastrectomy Bilroth I
Capell et al. [25]	Chronic anemia, early satiety	13.4 × 8.4 × 8.2 cm	Subtotal gastrectomy with partial duodenectomy and Bilroth II reconstruction
Neto et al. [26]	Upper abdominal pain	12 × 8 × 6 cm	Subtotal gastrectomy with D1 lymphadenectomy Roux-en-Y reconstruction
Hamdane et al. [27]	Epigastric pain	9 × 7.5 × 5 cm	Total gastrectomy
Capell et al. [25]	Melena	9.5 × 6.0 × 4.5 cm	Distal gastrectomy
Zak et al. [28]	Upper abdominal pain	9 × 6 cm	Open enucleation
Mouës et al. [29]	Early satiety, weight loss	9 × 5 cm	Open enucleation
Almohsin et al. [30]	Hematemesis	8.5 × 5 cm	Open enucleation
Beck et al. [31]	Hematemesis	8 × 3 × 4 cm	Open enucleation.

tumours, including lipomas, usually reveal a smooth filling defect with a “bull’s eye” appearance reflecting the mucosal ulceration that is indistinguishable from other mesenchymal tumours [6]. CT is a highly specific imaging modality used for diagnosing gastric lipomas [1,6]. In our case, CT scan showed a large well-defined oval mass with negative densitometry values of –75 Hounsfield units (HU) which corresponds to the same density of a lipoma (Fig. 2).

Gastric lipomas are radiologically pathognomonic and can be definitively diagnosed on CT scan. The attenuation values of –70 to –120 HU is usually typical of a lipoma, with the exception of mucosal ulceration leading to inflammation, which can result in soft tissue attenuation [13]. A CT scan in some cases may not be accurate in determining the involved layer of gastric wall. Endoscopic Ultrasound (EUS) provides more accurate findings of submucosal tumours with regards to their shape, size and layer of gastric wall involved, especially in small tumours and in those lying in the subserosa, where conventional endoscopic biopsy is extremely difficult [14]. However, it is operator dependent and is not widely available especially in the acute setting. EUS in our case was not utilised for several reasons which included the size of the mass and the ease with which biopsies were taken by upper endoscopy, its well recognised radiological features were and the emergent presentation of the patient.

During upper GI endoscopy, gastric lipomas appear as a sub-mucosal mass with three signs that will aid in establishing the diagnosis. They are named the tenting sign, cushion sign and naked fat sign. The tenting sign occurs when the overlying mucosa is easily separated using biopsy forceps, the cushion sign is when a soft indentation is made using biopsy forceps, and the naked fat sign is exposure of adipose tissue on biopsy sampling of the gastric mucosa [15]. Gastroscopy and biopsies were performed for our patient where the source of bleeding and underlying giant submucosal mass was easily visualized, and confirmed histologically to be a benign gastric lipoma.

Turkington in 1965, reviewed 157 cases in the literature and demonstrated that gastric lipomas may arise from every part of the stomach, but less frequently from the cardia and pylorus [16]. In our case the mass was extended from the gastroesophageal junction to the pylorus along the entirety of the lesser curvature. The occurrence of symptoms depends on the size and location of the tumour. Lesions of less than 2 cm are usually asymptomatic. In patients with larger lesions, the most common symptoms are hemorrhage, anemia, abdominal pain, pyloric obstruction, and dyspepsia. Additional symptoms may include diarrhea, constipation, weight loss and intussusception [5,16]. Our patient documented significant weight loss and presented with severe gastrointestinal bleeding that required resuscitation, admission, extensive work-up to rule out malignancy and urgent management.

The treatment modalities for gastric lipomas have changed in tandem to advances in endoscopic and imaging techniques. Asymptomatic incidental lipomas usually only require observation. Small

symptomatic lesions around 2 cm in size can be successfully treated with endoscopic management using techniques such as aspiration lumpectomy or strip biopsy [17]. Larger lipomas, 4 cm or greater, can be removed endoscopically with the unroofing technique [18]. Only a few cases involving huge gastric lipomas had been reported in the literature and few of them presented with massive gastrointestinal bleeding [3,4]. Due to absence of standardization in their surgical management, we listed the cases that have been reported to be larger than 8 cm in a table illustrating the type of surgery performed (Table 1). The reported giant gastric lipomas manifested with different clinical presentations. Although they showed typical findings on radiologic studies, the majority of them could not establish a diagnosis preoperatively and hence ended with aggressive resections. We also observed in the collected data that the larger the size of the lipoma, the more radical the surgery.

Whilst there are no reported malignant transformations of a gastric lipoma, coincidental malignant lesions separate from the lipoma have been reported [19]. The pathogenesis behind this finding was previously discussed by Yamamoto et al., in 2004; sub-mucosal lipomas that have extended into the gastric lumen may provoke repeat erosions or local inflammation of gastric epithelium, which is thought to promote gastric cancer [19]. Therefore, complete diagnostic evaluation prior to surgery is needed. In our patient, pre-operative evaluation did not detect any radiological or histological features of malignancy. We proceeded for explorative gastrotomy and elected to avoid radical surgery, proceeding instead with enucleation and primary repair as the definitive treatment after careful exclusion of malignancy. To rule out any underlying concomitant pathology, a biopsy of the overlying ulcerated gastric wall was sent for frozen section which showed no malignancy.

Massively bleeding giant gastric lipoma is a rare finding in a rare disease. We believe that awareness of the disease and familiarity of the pathognomonic radiologic findings can lead to an accurate preoperative diagnosis. If malignancy is carefully ruled out, gastric preserving surgery in the form of enucleation is a viable treatment option to avoid radical surgery and major gastric resection with its associated sequelae.

Conflicts of interest

The authors declare no conflict of interest.

Funding

We have received no external funding.
We report no involvement of sponsors.

Ethical approval

The case report was approved by the local ethic committee of the Al-Amiri teaching hospital. LEC-project number 31-2017.

Consent

Written informed consent was obtained from the patient and is available upon request. No patient identifying material was used in this manuscript.

Author contribution

Data collection: Salah Termos* Khalifa Alyatama and Mohammad Alali.

Analysis and case management: Osama Reslan, Omar Alqabandi and Ahmad Al-Saleh.

Writing and revising of the final version of the manuscript: Salah Termos, Abdullah Alduwaisan, Saud Al-Subaie,

Guarantor

Salah Termos M.D. Department of surgery, Al-Amiri teaching hospital, Kuwait. 25 Arabian Gulf Street, Kuwait City, 13041

Acknowledgment

The work has been reported in line with the SCARE criteria [20].

References

- [1] W. Thompson, A. Kende, A. Levy, Imaging characteristics of gastric lipomas in 16 adult and pediatric patients, *AJR Am. J. Roentgenol.* 181 (4) (2003) 981–985.
- [2] M. Fernandez, R. Davis, P. Nora, Gastrointestinal lipomas, *Arch. Surg.* 118 (9) (1983) 1081–1083.
- [3] J. Alcalde Escribano, A. Brea Hernando, A. Molina Sánchez, J. Ildefonso Martín Heredero López, J. Bengochea Cantos, Lipoma of the stomach. Presentation of a case and a review of cases reported in Spain, *Rev. Esp. Enferm. Apar. Dig.* 76 (5) (1989) 482–484.
- [4] A. Johnson, V. DeGennaro, W. Pizzi, T. Nealon, Gastric lipomas: a rare cause of massive upper gastrointestinal bleeding, *Am. J. Gastroenterol.* 75 (4) (1981) 299–301.
- [5] A. Taylor, E. Stewart, W. Dodds, Gastrointestinal lipomas: a radiologic and pathologic review, *AJR Am. J. Roentgenol.* 155 (1990) 1205–1210.
- [6] S. Park, J. Han, T. Kim, J. Lee, S. Kim, Y. Kim, B. Choi, K. Yeon, M. Han, Unusual gastric tumors: radiologic-pathologic correlation, *Radiographics* 19 (1999) 1435–1446.
- [7] J. Saltzman, D. Carr-Locke, S. Fink, Lipoma case report, *MedGenMed* 7 (1) (2005) 16.
- [8] S. Kapetanakis, J. Papathanasiou, A. Fiska, et al., A 20-year-old man with large gastric lipoma—imaging, clinical symptoms, pathological findings and surgical treatment, *Folia Med. (Plovdiv)* 52 (4) (2010) 67–70.
- [9] F. Maderal, F. Hunter, G. Fuselier, Gastric lipomas—an update of clinical presentation, diagnosis, and treatment, *Am. J. Gastroenterol.* 79 (12) (1984) 964–967.
- [10] A. Krasniqi, F. Hoxha, B. Bicaj, S. Hashani, S. Hasimja, S. Kelmendi, L. Gashi-Luci, Symptomatic subserosal gastric lipoma successfully treated with enucleation, *World J. Gastroenterol.* 14 (2008) 5930–5932.
- [11] H. Done, Lipoma of the stomach, *Br. Med. J.* 1 (1961) 183.
- [12] D. Regge, G. Lo Bello, L. Martincich, G. Bianchi, G. Cuomo, R. Suriani, F. Cavuoto, A case of bleeding gastric lipoma: US, CT and MR findings, *Eur. Radiol.* 9 (1999) 256–258.
- [13] J. Mandell, *Core Radiology*, Cambridge University Press, 2013.
- [14] J. Guo, Z. Liu, S. Sun, S. Wang, N. Ge, X. Liu, G. Wang, W. Liu, Endosonography-assisted diagnosis and therapy of gastrointestinal submucosal tumors, *Endosc. Ultrasound* 2 (3) (2013) 125–133.
- [15] M. Hamdane, E. Brahim, M. Salah, N. Haouas, A. Bouhafa, A. Chedly-Debbiche, Giant gastric lipoma mimicking well-differentiated liposarcoma, *Gastroenterol. Hepatol. Bed Bench* 5 (1) (2012) 60–63.
- [16] R. Turkington, Gastric lipoma: report of a case and review of the literature, *Am. J. Dig. Dis.* 10 (1965) 719–726.
- [17] T. Kajiyama, K. Hajiro, M. Sakai, K. Inoue, Y. Konishi, H. Takakuwa, S. Ueda, M. Okuma, Endoscopic resection of gastrointestinal submucosal lesions: a comparison between strip biopsy and aspiration lumpectomy, *Gastrointest. Endosc.* 44 (4) (1996) 404–410.
- [18] C. Shim, I. Jung, Endoscopic removal of submucosal tumors: preprocedure diagnosis, technical options, and results, *Endoscopy* 37 (2005) 646–654.
- [19] T. Yamamoto, K. Imakiire, S. Hashiguchi, J. Matsumoto, J. Kadono, N. Hamada, T. Yoshioka, S. Kitajima, A rare case of gastric lipoma with early gastric cancer, *Intern. Med.* 43 (2004) 1039–1041.
- [20] R. Agha, A. Fowler, A. Saetta, I. Barai, S. Rajmohan, D. Orgill, the SCARE Group, The SCARE Statement: consensus-based surgical case report guidelines, *Int. J. Surg.* 34 (2016) 180–186.
- [21] K. Singh, K. Venkateshwarlu, A.K. Malik, B. Nagi, R.V. Yadav, Giant gastric lipoma presenting with fever and melena, *Indian J. Gastroenterol.* 6 (3) (1987) 181.
- [22] Ramaraj, Rajeswari, Stuart Ashley Roberts, Geoffrey Clarke, Geraint Williams, Gareth A. Thomas, A rare case of iron deficiency, *Eur. J. Gastroenterol Hepatol.* 24 (no. 1) (2012) 82–83.
- [23] Rao, Chalapathi, Surinder Singh Rana, Anupam Lal, Mahendra Kumar, Arunanshu Behera, Divya Dahiya, Kusum Joshi, Deepak Kumar Bhasin, Large gastric lipoma presenting with GI bleeding, *Gastrointest. Endosc.* 77 (3) (2013) 512–513.
- [24] Priyadarshi, Rajeev Nayan, Utpal Anand, Manish Kumar Pandey, Binita Chaudhary, Ramesh Kumar, Giant gastric lipoma presenting as gastric outlet obstruction—a case report, *J. Clin. Diagn. Res.: JCDR* 9 (10) (2015) D03.
- [25] Cappell, S. Mitchell, Charlton E. Stevens, Mitul Amin, Systematic review of giant gastric lipomas reported since 1980 and report of two new cases in a review of 117110 esophagogastroduodenoscopies, *World J. Gastroenterol.* 23 (30) (2017) 5619.
- [26] Neto, Francisco Améric Fernandes, Maria Cristina Furia Ferreira, Luiz Carlos Nascimento Bertoncello, André Amate Neto, Wilson Chubassi de Aveiro, Caroline Agnelli Bento, Gustavo Nardini Cecchino, Marco Antonio Mendes Rocha, Gastric lipoma presenting as a giant bulging mass in an oligosymptomatic patient: a case report, *J. Med. Case Rep.* 6 (1) (2012) 317.
- [27] Hamdane, Mohamed Moncef, Ehsen Ben Brahim, Mériam belhaj Salah, Nooman Haouas, Ahmed Bouhafa, Achraf Chedly-Debbiche, Giant gastric lipoma mimicking well-differentiated liposarcoma, *Pan Afr. Med. J.* 13 (1) (2012).
- [28] Zak, Yulia, Blanche Biagini, Harvey Moore, Mark DeSantis, Bimal C. Ghosh, Submucosal resection of giant gastric lipoma, *J. Surg. Oncol.* 94 (1) (2006) 63–67.
- [29] C.M. Moues, P.J.H. Steenvoorde Viersma, K. van Groningen, J.F. de Bruine, Jejunal intussusception of a gastric lipoma: a review of literature, *Dig. Surg.* 19 (5) (2002) 418–420.
- [30] Almohsin, Madina, A. Meshikhes, Gastric lipoma presenting with haematemesis, *BMJ Case Rep.* 2015 (2015).
- [31] Beck, Nam. Seon, S. Lee, H. Lee, H. Kim, Gastric lipoma in a child with bleeding and intermittent vomiting, *J. Pediatr. Gastroenterol. Nutr.* 24 (2) (1997) 226–228.

Open Access

This article is published Open Access at [sciencedirect.com](https://www.sciencedirect.com). It is distributed under the [IJSCR Supplemental terms and conditions](#), which permits unrestricted non commercial use, distribution, and reproduction in any medium, provided the original authors and source are credited.