

Received: 2015.03.20
Accepted: 2015.04.13
Published: 2015.06.25

A Clinical Investigation of Contralateral Neurological Symptom after Transforaminal Lumbar Interbody Fusion (TLIF)

Department of The Third Hospital of Hebei Medical University, Key Biomechanical Laboratory of Orthopedics, Shijiazhuang, Hebei, P.R. China

Authors' Contribution:
Study Design A
Data Collection B
Statistical Analysis C
Data Interpretation D
Manuscript Preparation E
Literature Search F
Funds Collection G

AB **Jiayue Bai**
AE **Wei Zhang**
CE **Xin Zhang**
F **Yapeng Sun**
DG **Wenyuan Ding**
CF **Yong Shen**

Corresponding Author: Wei Zhang, e-mail: Zwzw_zwei@163.com
Source of support: Departmental sources

Background: The aim of this study was to analyze treatment outcomes and morbidity of contralateral neurological symptom in patients after TLIF surgery and to explore its possible causes.





Material/Methods: A retrospective study was conducted involving a total of 476 patients who underwent TLIF from 2009 to 2012 in our hospital. These cases were divided into a symptomatic group (Group S) and a non-symptomatic group. The differences in contralateral foramen area and disc-height index(DHI) before and after surgery were compared between Group S and a random sample of 40 cases of non-symptomatic group patients (group N). In addition, according to whether the patient underwent second surgery, Group S patients were further divided into a transient neurologic symptoms group (Group T) and an operations exploration group (Group O). The time of symptom appearance, duration, and symptomatic severity (JOA VAS score) were compared between Group T and O.

Results: Among the 476 patients, 18 had postoperative contralateral neurological symptoms; thus, the morbidity was 3.7815%. The indicators in Group S were lower than in Group N in the differences in contralateral foramen area and disc-height index(DHI) before and after surgery ($p < 0.05$). Five patients (Group O) in Group S had second surgery because of invalid conservative treatment. The surgical exploration rate was 1.0504%. Compared with Group T, the symptoms of Group O patients appeared earlier, persisted longer, and were more serious ($p < 0.05$).

Conclusions: Contralateral neurological symptom is a potential complication after TLIF, and its causes are diverse. Surgical explorations should be conducted early for those patients with the complication who present with obvious nerve damage.

MeSH Keywords: **Manipulation, Spinal • Radiculopathy • Stress, Mechanical**

Full-text PDF: <http://www.medscimonit.com/abstract/index/idArt/894159>

 2721  4  4  19



Background

Transforaminal lumbar interbody fusion (TLIF) was proposed by Blume and Rojas [1] in the early 1980s, and has been widely used in the treatment of lumbar degenerative disease, spinal instability, and discogenic diseases [2]. Translational studies have demonstrated that TLIF has satisfactory clinical efficacy. In 2006, Glassman observed 497 cases of patients and reported [3] that SF-36 composite score was improved by an average of 9.9 at 1 year after TLIF and the average score was improved by 9.5 after 2 years. The overall fusion rate after TLIF surgery could reach as high as 90% [4,5]. Villavicencio [6] reported in 2007 that the long-term overall fusion rate could be 100%.

TLIF technique has been improved and developed for many times since its advent. The surgery has developed from the initial Wiltse approach [7] to posterior open approach and outer pole approach [8]. With the recent popularization and development of the Mis-TLIF, it, combined with a variety of expandable-channel technologies, has become the most mature minimally invasive spine surgery [9–11].

Compared with the traditional PLIF, TLIF technique showed advantages such as small incision, less bleeding, and little influence on spinal stability [12–15], but it is still likely to have wound infection, postoperative hematoma formation, fusion shift, cerebrospinal fluid leakage, and other surgery complications [16,17]. In addition, postoperative contralateral neurological symptoms may be a potential complication of TLIF surgery. Despite reports in previous studies [17], it has not been widely acknowledged or emphasized.

Material and Methods

Inclusion and exclusion criteria

Inclusion criteria: (1) Preoperative diagnosis was lumbar intervertebral disc herniation with unilateral nerve symptoms or lumbar spondylolisthesis $\leq 1^\circ$; (2) Invalid formal conservative treatment more than 3 months; and (3) The surgical operations was single- or double-segment TLIF.

Exclusion criteria: (1) Lumbar trauma, tumor, severe osteoporosis, or congenital malformation; (2) Lumbar intervertebral disc herniation with bilateral nerve symptoms or lumbar spondylolisthesis $\geq 1^\circ$; (3) The operation is not TLIF; (4) Combined with other serious systemic diseases or metal allergy; and (5) Incomplete or missing follow-up.

General information

Complete data of TLIF surgery and follow-up from January 2009 to December 2012 in our hospital were systematically and retrospectively analyzed. The study included 476 patients in the period from 2009 January to 2012 December who underwent surgery in single- or double-segment TLIF, including 291 males and 185 females, ages 19–68 years, and average age 55.3 years. Contralateral nerve symptoms occurred in 18 patients (Group S), including 11 males and 7 females. Forty patients (Group N) were randomly selected among the 458 patients in the non-symptomatic group, including 22 males and 18 females. The 2 groups of patients were followed up for 6–28 months, average 14.3 months. Lumbar anteroposterior and lateral X-ray and intervertebral foramen CT scan of surgical segment were taken before and after surgery or follow-up. In addition, according to whether the patients underwent second surgery, Group S were further divided into a transient neurologic symptoms group (Group T) and an operations exploration group (Group O).

Follow-up and measurement index

The difference in contralateral foramen area before and after surgery: Saidi's [18] method was used to scan the surgical segment intervertebral foramen with CT. AutoCAD2007 software was used to measure the foramen area of non-decompression side. The difference of contralateral foramen area = postoperative contralateral intervertebral foramen area - preoperative contralateral intervertebral foramen area.

The difference of disc-height index before and after surgery: Masuda's [19] method was used to measure the disc-height index. The difference of disc-height index = postoperative disc-height index of surgery segment - preoperative disc-height index of surgery segment.

The time of symptoms appearance: The time since the end of the operation until the contralateral nerve symptoms occurred.

The duration of symptoms: The time since the contralateral nerve symptoms appeared until they disappeared.

The responses to dehydration and hormone drugs: Patients in Group S had been given mannitol injection 50g + dexamethasone injection 10 mg 1/day for 3 days after symptoms occurrence. After that, the patients were given mannitol injection 50 g + dexamethasone injection 5 mg 1/day for 3 days. We then observed whether the drug was working.

The severity of symptoms: VAS and JOA scores were used to evaluate the severity of the patients' symptoms in Group S. Patients in Group O were followed up to gather determine the

Table 1. Comparisons of the difference of contralateral foramen area and DHI before and after surgery of Group S and N.

Item	S (n=16)		N (n=40)		p
	Mean	SD	Mean	SD	
The difference of contralateral foramen area (mm ²)	-0.32	11.39	+8.62	11.27	0.01
The difference of DHI	+0.01	0.16	+0.18	0.23	0.011

Table 2. Comparisons of patients conditions in group T and O.

Item	T (n=13)		D (n=5)		p
	Mean	Range	Mean	Range	
Time of symptom appearance(hrs postoperative)	86.7	26-125	28	11-58	0.007
Symptom duration (hrs postoperative)	57.4	23-78	270.6	148-377	0.001
JOA score	24.78	17-27	13.4	9-18	0.002
VAS score	2.85	1-5	6.6	5-8	0.001

Table 3. Comparison of response to dehydrating drugs in group T and O.

Item	T (n=13)	D (n=5)	p
Response to dehydrating drugs (response rate %)	84.6	0	0.002

symptom improvement rate after surgery. The symptom improvement rate after the treatment=[(score after treatment – score before treatment)/29- score before treatment]×100%.

SPSS 16.0 statistical software was used for statistical analysis. Independent-sample t test was used for comparison of the difference of contralateral foramen area and DHI before and after surgery between group S and group N. The time of symptom appearance, duration, severity (JOA score, VAS score) were compared using 2-sample rank sum test. Fisher's exact test was used to analyze the responses to dehydrating drugs. P<0.05 was considered as statistically significant.

Results

Our institute performed 476 TLIF surgeries from 2009 to 2012, of which 372 were open TLIF and 104 were MIS-TLIF. Eighteen patients displayed postoperative contralateral neurological symptoms, including 14 open TLIF cases and 4 MIS-TLIF cases. Hence, the overall incidence rate was 3.7815%, the incidence rate of open TLIF was 3.7634%, and the incidence rate of MIS-TLIF was 3.8462%. Five symptomatic patients had surgical explorations due to ultimately ineffective conservative treatment; therefore, the rate of surgical exploration was 1.0504%.

Group S (2 cases were excluded due to obvious nerve compression, n=16), compared with group N (n=40), showed significant differences in the contralateral foramen area (Group S +1.7 mm 2±10.1, Group N +5.8 mm 2±4.5) and DHI (Group S 0.01±0.16, Group N 0.18±0.23) (p<0.05) (Table 1).

The differences in time of symptom appearance (group T mean was 86.7 h postoperative; group O mean was 28 h postoperative), duration (group T mean 57.4 h; group O mean 270.6 h), response to dehydrating drugs (response rate of group T was 88.9%; response rate of group O was 0%), symptom severity (group T JOA mean was 24.78, VAS mean was 2.85; group O JOA mean was 13.4, VAS mean was 6.6), and other indicators were all statistically significantly different between group T (n=13) and group O (n=5) (p <0.05). Diagnostic nerve root block was effective for group T patients, but not for patients in group O patients (Tables 2, 3). Follow-up visits to group D of patients at 1 year after the surgery showed that the postoperative symptoms (JOA score) improvement rate was 95.42% (Table 4).

Discussion

Compared with PLIF technique, TLIF technology can achieve better decompression, fusion, and internal fixation, meanwhile avoiding damage to the rear stable structure of the spine. TLIF surgery by Wiltse approach can reduce the excessive dissection

Table 4. Detailed information of 5 symptomatic patients who had surgical explorations due to ultimately ineffective conservative treatment.

Case No.	Sex	Age	Surgery approach	Postoperative situation			Response to dehydrating drugs	Diagnostic nerve root block	Secondary surgery	
				Appearance time (post-operative)	Duration (post-operative)	Severity			Intraoperative observation	1 year follow-up visits
Case 1	M	37	Minimally invasive TLIF	20 h	148 h	JOA score: 9 VAS score: 7	Ineffective	Not done	Displacement of pedicle screw at the left side of the lumbar vertebral disc 5, compressing nerve root (Figure 2)	JOA score: 27 VAS score: 1
Case 2	F	46	Open TLIF	58 h	377 h	JOA score: 13 VAS score: 8	Ineffective	Not done	Free bone graft in the right inside of intervertebral gap between lumbar vertebral disc 5 and sacral 1 (Figure 3)	JOA score: 25 VAS score: 2
Case 3	M	55	Open TLIF	40 h	340 h	JOA score: 12 VAS score: 5	Ineffective	Not done	Postoperative change of intervertebral gap between lumbar vertebral disc 4 and 5, narrow intervertebral foramen.	JOA score: 27 VAS score: 1
Case 4	M	57	Open TLIF	11 h	196 h	JOA score: 18 VAS score: 6	Ineffective	Ineffective	Postoperative change of intervertebral gap between lumbar vertebral disc 4 and 5, narrow intervertebral foramen.	JOA score: 28 VAS score: 0
Case 5	F	66	Open TLIF	18 h	292 h	JOA score: 15 VAS score: 7	Ineffective	Ineffective	Postoperative change of intervertebral gap between lumbar vertebral disc 5 and sacral 1; narrow intervertebral foramen (Figure 4)	JOA score: 26 VAS score: 2

of the rear spinal muscle and soft tissue [7]. In recent years, with the development of minimally invasive techniques, there have been an increasing number of TLIF surgeries assisted by various expandable channels [11–13]. Because TLIF not only meets the surgical requirements of decompression, fusion, and internal fixation, but also allows minimally invasive operation with a smaller incision and less bleeding, it is being more widely used [12–15].

Intensive case studies revealed that TLIF technique can achieve rather good surgical outcome [3–6], but its development is still restricted by postoperative complications. Complications that have been frequently reported in previous studies are nerve damage at the decompressed side, wound infection, unalleviated postoperative limb pain, and cerebrospinal fluid leakage [17]. In addition, there are increased rates of pseudarthrosis and Kirschner (K)-wire or Jamshidi needle fracture in the MI-TLIF approach[18]. However, contralateral neurological symptom as a potential complication after TLIF surgery happens in clinical practice. In 2007, Hunt published a

case report [17] and described this particular complication for the first time. The paper claimed that this phenomenon has been confirmed by several experienced clinicians, and the incidence rate can reach 2.5%. However, cases reported in the paper are all transient neurological symptom, which was significantly alleviated after conservative treatment. Hunt believed that the situation of intervertebral foramina and nerve root at the non-decompression side after TLIF may not remain unchanged, as assumed previously. This complication may be associated with excessive distraction of surgical decompression side and oversized cage implantation at the decompression side during surgery, as well as foramen deformation of the non-surgical decompression side, which is caused by surgery recovery lordosis curvature. However, given the technical characteristic that surgical decompression is carried out only at the symptomatic side during TLIF surgery, the situation in the lateral lumbovertebral canal and nerve root remain elusive during and after the surgery. The causes of contralateral neurological symptom are also not clear, especially when using minimally invasive techniques [19]. Thus, the contralateral

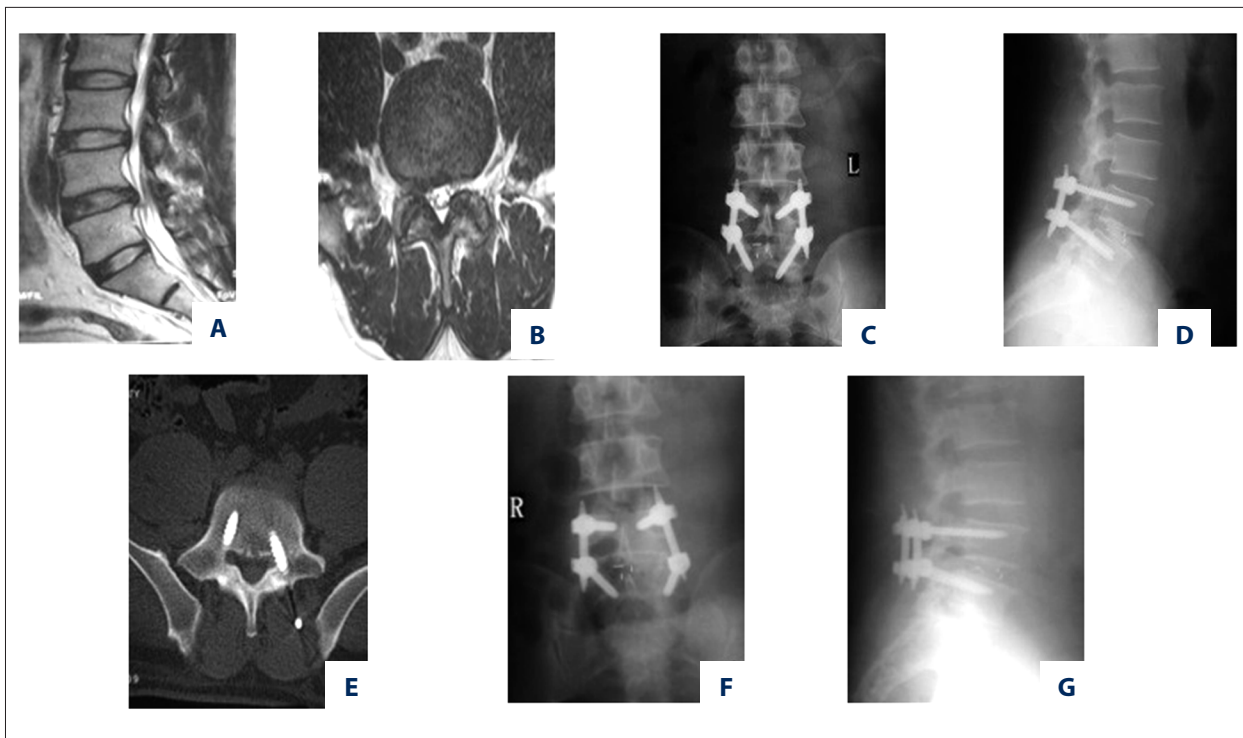


Figure 1. (A, B) Case 1 Preoperative Imaging: right-back herniation of lumbar vertebral disc 4–5 and right foramen narrowed. (C, D) Case 1 – direct and lateral X-ray photograph of lumbar vertebra after surgery. (E) Continuous CT scans of Case 1 – lumbar vertebra after surgery, pedicle screw displacement at the left side of vertebral disc 5, narrowing the lateral recess and compressing the nerve root. (F, G) Case 1 – direct and lateral X-ray images of the lumbar vertebra after second surgery.

neurological symptom after TLIF surgery has not yet been received great attention.

As the first large-scale case study for this particular complication, through retrospective analysis of 476 TLIF surgery cases in our hospital, we observed that this complication has a high incidence and is possibly associated with other obvious nerve damage besides transient neurological symptom. Thirteen of the 18 patients in the symptomatic group had transient neurological symptom, which was significantly alleviated with conservative drug treatment, while the other 5 cases were complicated with neurological damage, failed in conservative therapy, and the symptoms were alleviated only after secondary surgical treatment. The overall incidence of the complication was 3.78%, similar to the rate in a previous report [17]. The totally different treatment approaches in these 2 groups of patients make the identifications particularly important. Therefore, a proper understanding and evaluation of this complication, which will guide effective and timely treatment in clinical practice, is of great significance.

The results of this study show that group T and D were significantly different in terms of time of symptom appearance, duration, symptom severity, and response to dehydration (Tables 3, 4). This implies that mechanical compression at the

contralateral nerve root should be considered for patients who have contralateral neurological symptom that is earlier, longer in duration, and more severe, and who have poorer response to dehydrating drugs, as well as typical signs of nerve root compression, such as the positive contralateral Lasègue's test, decreased muscle strength, and skin sensory loss in the corresponding nerve root dominated region. Further CT imaging is therefore of higher diagnostic value. In Case 1 in group D, for example, a lateral X-ray showed that pedicle screw position was acceptable after the first surgery, but CT showed there was a bias in pedicle screw placement, thus compressing the nerve root (Figure 1). CT results of Case 2 showed a shift of the intervertebral bone graft, which caused nerve compression (Figure 2). In addition, there was an obvious reduction of the contralateral foramen area in Cases 3, 4, and 5 before and after surgery (Figure 3). This suggests that when signs and symptoms are consistent, CT scans of surgical segment pedicle, intervertebral foramen, and space should be carried out. The fixation location, intervertebral foramen morphology, and condition of decompressing bone implantation should also be examined. Furthermore, for those cases in which signs and symptoms are not typical and imaging examinations cannot determine the nature of the pain, diagnostic nerve root block can serve as a good diagnostic basis.

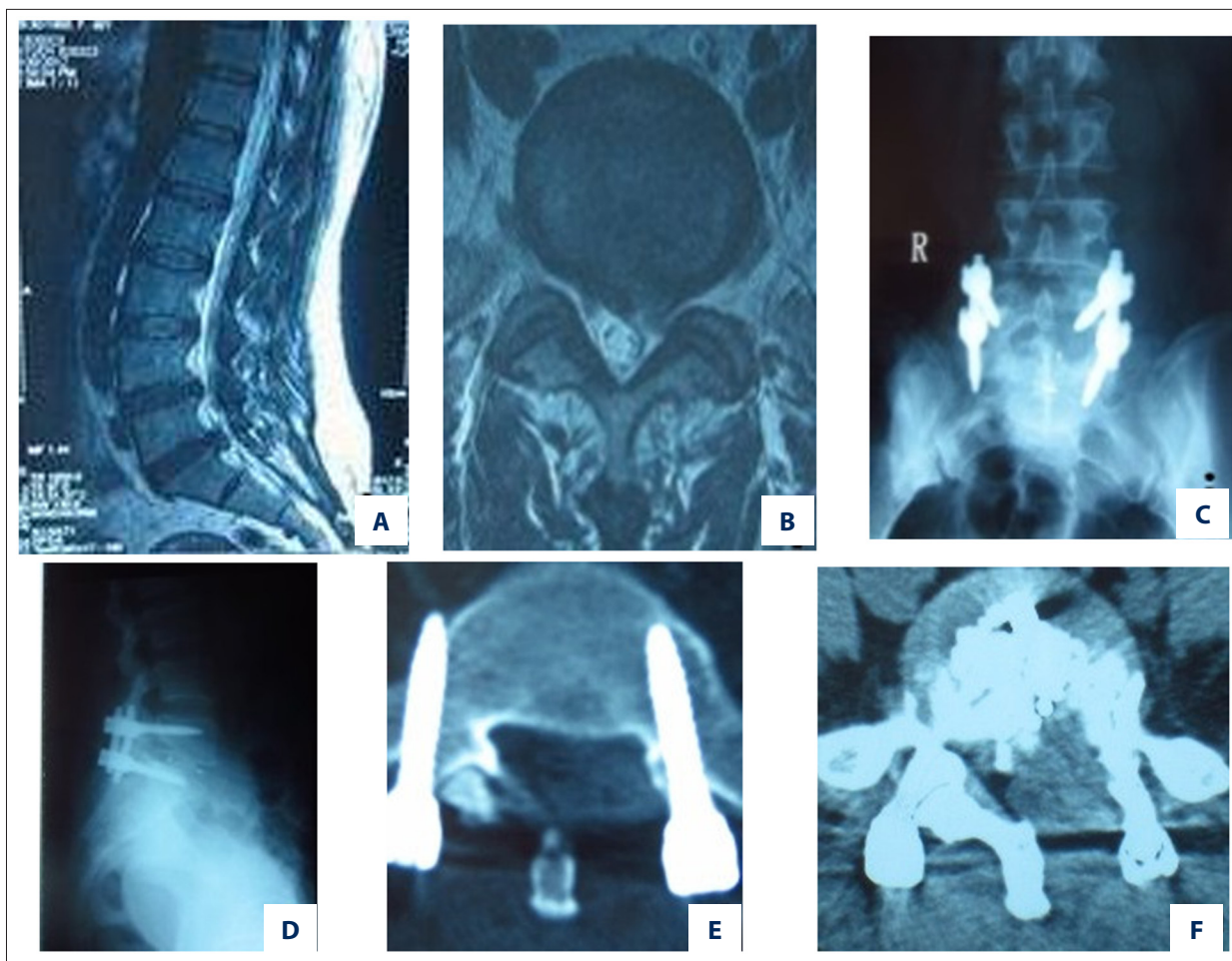


Figure 2. (A, B) MRI of Case 2 – preoperative lumbar intervertebral herniation between L4 and first sacral, most severe at lumbar vertebral disc 5 – sacral 1, sacral spinal stenosis. (C, D) Case 2 – direct and lateral X-ray image of lumbar vertebra after surgery. (E) Case 2 – postoperative CT scan showed that pedicle screw position was acceptable. (F) CT scan of Case 2 – postoperative intervertebral foramen showed a free graft at the right side of L5 – sacral 1 gap, causing nerve root compression of the right side.

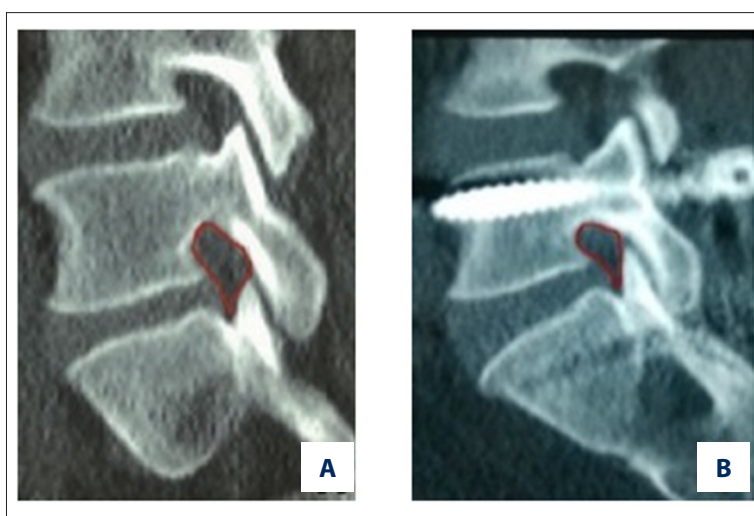


Figure 3. (A) Case 5 – preoperative non-decompression side foramen area was 72.51 mm². (B) Case 5 – non-decompression side foramen area was 56.11 mm², which was significantly reduced compared with preoperative area.

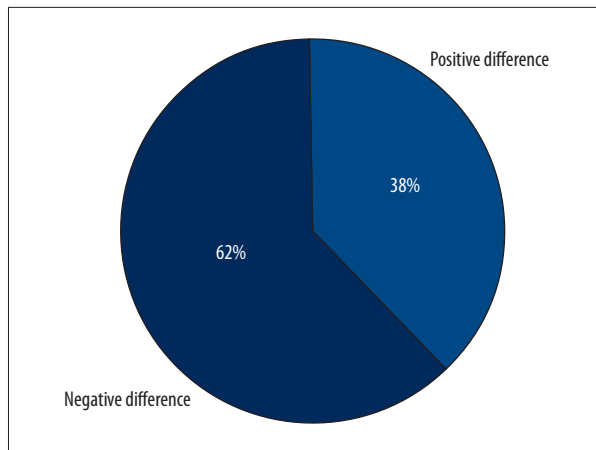


Figure 4. Group S patients (n=16) – foramen area change before and after the operation (postoperative – preoperative) composition.

Through the intensive analysis of clinical features of patients in the symptomatic group, we determined that the causes of the complications vary greatly.

For transient contralateral neurological symptom, which has the characteristics of late occurrence, short duration, mild symptom, and good response to dehydrating drug treatment, we hypothesize that its appearance may be associated with intraoperative or postoperative bleeding that results in chemical stimulation on the nerve root spreading from spinal to the contralateral side, severe tissue adhesion in the nerve root compression region, and postoperative nerve root edema response caused by excessive intraoperative traction on the nerve root, all of which spread to the contralateral nerve root and result in contralateral neurological symptom. A patient in group T, for example, had preoperative treatment by intraspinal injection many times. Severe intraoperative spinal tissue adhesion was found during the surgery, which made it very difficult and time-consuming to dissect the nerve root. The patient displayed postoperative contralateral neurological symptom, which was gradually alleviated after conservative drug treatment.

Given that the contralateral nerve damages are usually associated with earlier neurological symptom occurrence, longer duration, severe symptoms, poor response to dehydrating drugs, and nerve root block therapy, its causes should be considered as mechanical compression, which, however, may be due to a variety of reasons.

Firstly, it may be caused by mechanical compression of the internal fixation, i.e., unsatisfactory position of the pedicle screw at the non-pressure side, which breaks through the pedicle cortex and causes direct mechanical compression to the nerve root. In Case 1 in group B, the lumbar vertebral body pedicle

screw was deflected towards the inside at the non-decompression side and broke into the spinal canal, resulting in direct mechanical compression of the nerve root. The symptom was relieved after surgical treatment by re-implanting the pedicle to erase the compression (Figure 1).

The second reason could be the compression from free bone graft, i.e., free graft caused by careless surgical handling reaches the contralateral side through the spinal canal or intervertebral space, causing compression damage to the nerve root. In Case 2 in group B, for example, postoperative CT imaging revealed a visible free bone graft in the intervertebral segment of the non-surgical spinal decompression side, oppressing the nerve root (Figure 2). After a bone fragment was removed by decompression surgery, the symptom was significantly relieved.

Except for the 2 cases mentioned above, which are clear in their nerve compression sources, no apparent reasons were found through imaging examinations for the rest of the patients in this group. Regarding these findings, Hunt suggested that it may be related to excessive distraction of the surgical decompression side and oversized cage implantation at the decompression side during surgery, as well as foramen deformation of the non-surgical decompression side caused by surgery recovery lordosis curvature [17].

This study analyzed and compared the difference in contralateral foramen area and DHI before and after surgery between the symptomatic group and non-symptomatic group. The results show that patients in the symptomatic group had smaller contralateral foramen area and DHI (Table 1). The comparison of the intervertebral foramen area change before and after surgery in the symptomatic group showed that the postoperative contralateral foramen area was not generally increased, as previously thought, but instead, most of them were reduced (Figure 4).

Therefore, we have reasons to believe that the contralateral neurological symptom may also be attributed to the unsatisfactory intervertebral height restoration, excessive closure caused by intervertebral height variation, and contralateral foraminal stenosis. As in Cases 3, 4, and 5 in group B, postoperative CT examinations showed foraminal stenosis at the non-surgical decompression side, which was alleviated by contralateral foraminal surgical decompression (Figure 3). This result is inconsistent with the theory of oversized implantation proposed by Hunt. We believe that although an oversized cage can cause variations in intervertebral space width, the occurrence of this symptom is associated with the possibility that implantation position is too biased towards the symptomatic side. If the cage is appropriately implanted and intervertebral height recovers well, this symptom would not occur. In addition, in Case 5 in group B, foramen area at the

non-decompression side before surgery was 72.51 mm² and after surgery it was 56.11 mm², which reminds us that if contralateral foramen stenosis already exists preoperatively, the intraoperative over-closure may exacerbate the narrowness, resulting in contralateral nerve root compression and contributing to neurological symptoms (Figure 3).

Based on the above analysis, the causes of TLIF postoperative contralateral neurological symptom can be divided into 2 categories: stimulus from edema or blood, and mechanical compression. The former often leads to transient neurological symptom, while the latter is prone to induce neurological damage. These 2 categories can be differentiated by the time of symptom appearance, duration, severity, and response to dehydrating drugs. CT examination and diagnostic nerve root block also provide a reliable diagnostic basis. For patients

diagnosed with contralateral neurological symptom caused by nerve damage from mechanical compression, exploratory decompression surgery should be conducted as early as possible to improve the prognosis.

Conclusions

Contralateral neurological symptom is a potential complication after TLIF, and its causes are diverse. Surgical explorations should be conducted early for those patients with the complication who presented with obvious nerve damage.

Conflict of interest

The authors declare no conflict of interest.

References:

- Blume H, Rojas C: Unilateral lumbar interbody fusion (posterior approach) utilizing dowel graft. *J Neurol Orthop Surg*, 1981; 2: 171–75
- Harms J, Rolinger H: Die operative Behandlung der Spondylolisthese durch dorsale Aufrichtung und ventrale Verblockung. *Zeitschrift für Orthopädie und ihre Grenzgebiete* 1982; 120: 343–47 [in German]
- Glassman S, Gornet MF, Branch C et al: MOS short form 36 and Oswestry Disability Index outcomes in lumbar fusion: a multicenter experience. *Spine J*, 2006; 6: 21–26
- Ames CP, Acosta FL Jr, Chi J et al: Biomechanical comparison of posterior lumbar interbody fusion and transforaminal lumbar interbody fusion performed at 1 and 2 levels. *Spine (Phila Pa 1976)*, 2005; 30(19): E562–66
- Kettler A, Schmoelz W, Kast E et al: *In vitro* stabilizing effect of a transforaminal compared with two posterior lumbar interbody fusion cages. *Spine (Phila Pa 1976)*, 2005; 30: E665–70
- Villavicencio AT, Burneikiene S, Nelson EL et al: Safety of transforaminal lumbar interbody fusion and intervertebral recombinant human bone morphogenetic protein-2. *J Neurosurg Spine*, 2005; 3(6): 436–43
- Wiltse L, Spencer C: New uses and refinements of the paraspinous approach to the lumbar spine. *Spine (Phila Pa 1976)*, 1988; 13(6): 696–706
- Ozgun BM, Aryan HE, Pimenta L, Taylor WR: Extreme Lateral Interbody Fusion (XLIF): a novel surgical technique for anterior lumbar interbody fusion. *Spine J*, 2006; 6: 435–43
- Mummaneni PV, Rodts GE Jr: The mini-open transforaminal lumbar interbody fusion. *Neurosurgery*, 2005; 57: 256–61
- Ozgun BM, Hughes SA, Baird LC, Taylor WR: Minimally disruptive decompression and transforaminal lumbar interbody fusion. *Spine J*, 2006; 6: 27–33
- Gu G, Zhang H, Fan G et al: Comparison of minimally invasive versus open transforaminal lumbar interbody fusion in two-level degenerative lumbar disease. *Int Orthop*, 2014; 38: 817–24
- Schizas C, Tzinieris N, Tsiridis E, Kosmopoulos V: Minimally invasive versus open transforaminal lumbar interbody fusion: evaluating initial experience. *Int Orthop*, 2009; 33: 1683–88
- Peng CW, Yue WM, Poh SY et al: Clinical and radiological outcomes of minimally invasive versus open transforaminal lumbar interbody fusion. *Spine (Phila Pa 1976)*, 2009; 34: 1385–89
- Tian NF, Wu YS, Zhang XL et al: Minimally invasive versus open transforaminal lumbar interbody fusion: a meta-analysis based on the current evidence. *Eur Spine J*, 2013; 22: 1741–49
- Perez-Cruet MJ, Hussain NS, White GZ et al: Quality-of-life outcomes with minimally invasive transforaminal lumbar interbody fusion based on long-term analysis of 304 consecutive patients. *Spine (Phila Pa 1976)*, 2014; 39: E191–98
- Figueiredo N, Martins JW, Arruda AA et al: TLIF: transforaminal lumbar interbody fusion. *Arq Neuropsiquiatr*, 2004; 62(3B): 815–20
- Hunt T, Shen FH, Shaffrey CI, Arlet V: Contralateral radiculopathy after transforaminal lumbar interbody fusion. *Eur Spine J*, 2007; 16(Suppl.3): 311–14
- Osman SG, Nibu K, Panjabi MM et al: Transforaminal and posterior decompressions of the lumbar spine. A comparative study of stability and intervertebral foramen area. *Spine (Phila Pa 1976)*, 1997; 22: 1690–95
- Masuda K, Imai Y, Okuma M et al: Osteogenic protein-1 injection into a degenerated disc induces the restoration of disc height and structural changes in the rabbit anular puncture model. *Spine*, 2006; 31: 742–54