

Comparison of oral fiberoptic intubation via a modified guedel airway or a laryngeal mask airway in infants and children

Elsa Varghese, Nagaraj R¹, Shwethapriya R

Department of Anaesthesiology, Kasturba Medical College, Manipal, Manipal University, Karnataka, ¹Department of Anaesthesiology, Govt Mohan Kumaramangalam Medical College, Salem, Tamil Nadu, India

Abstract

Background: Though fiberoptic intubation (FOI) is considered the gold standard for securing a difficult airway in a child, it may be technically difficult in an anesthetized child. The hypothesis for this study was that it would be easier to perform FOI via a laryngeal mask airway (LMA) than a modified oropharyngeal airway with the advantage of maintaining anesthesia and oxygenation during the process.

Materials and Methods: 30 children aged 6 months to 5 years undergoing elective surgery under general anesthesia were randomized to two groups to have fiberoptic bronchoscope (FOB) guided intubation either via a modified Guedel airway (FOB-ORAL) or a classic LMA (FOB-LMA). In the FOB-LMA group, the LMA was removed when a second smaller endotracheal tube was anchored to the proximal end of the tracheal tube in place.

Results: Oral fiberoptic intubation was successful in all children. The first attempt success rate was 11/15 (73.33%) in the FOB-LMA group and 3/15 (20%) in the FOB-ORAL group ($P = 0.012$). Subsequent attempts at intubation were successful after 90° anticlockwise rotation of the endotracheal tube over the FOB. The time taken for fiberoptic bronchoscopy was significantly less in FOB-LMA group (59.20 ± 42.85 sec vs 108.66 ± 52.43 sec). The incidence of desaturation was higher in the FOB-ORAL group (6/15 vs 0/15).

Conclusion: In children, fiberoptic bronchoscopy and intubation via an LMA has the advantage of being easier, with shorter intubation time and continuous oxygenation and ventilation throughout the procedure. Removal of the LMA following intubation requires particular care.

Key words: Difficult, equipment, fiberoptic bronchoscope, intubation, laryngeal mask airway, modified oropharyngeal Guedel airway, tracheal

Introduction

Tracheal intubation of infants and children with a difficult airway is challenging for the anesthesiologist. Fiberoptic bronchoscopic intubation (FOI) is a standard technique to secure the airway especially in patients with difficult airway. In children with a difficult airway, unlike in adults, intubation has to be performed under deep sedation or general anesthesia. During the process it is important to ensure that the patient

is adequately oxygenated as well as anesthetized. General anesthesia causes the soft palate, tongue, and epiglottis to prolapse backwards, which results in reduction in the space in the oropharynx and difficulty in maneuvering of the fiberoptic bronchoscope (FOB). To overcome this problem maneuvers like the jaw lift, insertion of an oropharyngeal device or an LMA have been recommended.^[1] Desaturation is likely if the duration of intubation is prolonged.

The laryngeal mask airway (LMA) has been described as a conduit for FOI in case reports.^[2-9] Blind intubation via the LMA is not recommended in children as it can cause airway trauma. FOI via an LMA has the added advantage of having a conduit for oxygenating and maintaining anesthesia during the procedure.^[10] Once the endotracheal tube (ETT) is in place via the LMA, ventilating the patient can be difficult unless the LMA is withdrawn as the length of pediatric endotracheal tubes and LMA are similar.

The aim of this study was to evaluate oral FOI via a modified

Address for correspondence: Dr. Shwethapriya R,
Department of Anaesthesiology, KMC,
Manipal – 576 104, Karnataka, India.
E-mail: drshwethapriya@gmail.com

Access this article online	
Quick Response Code:	Website: www.joacp.org
	DOI: 10.4103/0970-9185.105797

Guedel airway and an LMA in infants and children under general anesthesia in a randomized controlled manner.

Materials and Methods

Following approval by the hospital ethics committee and written informed consent from the parents, the study was conducted in 30 ASA physical status 1 and 2 children, aged six months to five years, scheduled for elective surgery under general anesthesia requiring ETT placement. Children with anticipated difficult airway, congenital heart disease, congenital anomalies of the airway, and those at increased risk for pulmonary aspiration or gastric regurgitation were excluded. Using a randomization table, patients were randomized to two groups: FOI-ORAL (FOI intubation via a modified Guedel's airway) or FOI-LMA (FOI intubation via LMA). Either oral or intravenous (IV) midazolam premedication was administered. Monitoring included electrocardiogram, noninvasive blood pressure, precordial stethoscope, pulse oximeter, end tidal carbon dioxide, end tidal anesthetic agent, axillary temperature, and neuromuscular monitoring.

Anesthesia was induced either by inhalation of increasing concentrations of halothane in oxygen via a facemask or by thiopental sodium 5 mg/kg IV. Vecuronium bromide 0.1 mg/kg, glycopyrrolate 0.01 mg/kg, and fentanyl 1 mcg/kg IV were administered and anesthesia was maintained with oxygen and halothane (1-1.5% endtidal concentration) via a facemask. A Mapleson F circuit was used if the child weighed <15 kg and a Bain's circuit if >15 kg. Sand bags were positioned on either side of the head for stabilization.

In the FOI-ORAL group, following the absence of train of four responses, a 2.2-mm diameter intubating fiberoptic (Pentax^R FB-15P, Pentax Corporation, Tokyo, Japan) premounted with an appropriate-sized ETT was introduced via the mouth through a modified Guedel airway (cut through its entire dorsal length to facilitate the removal of the FOB—Figure 1) and its tip was advanced till just above the carina. The oropharyngeal airway was removed, maintaining the FOB in position, and the trachea intubated. If resistance was encountered, partial withdrawal and 90° anticlockwise rotation and reinsertion of ETT was performed. In the event of hypoxia ($SpO_2 < 92\%$) or lighter plane of anesthesia, the FOB was removed and facemask ventilation was provided with oxygen and halothane (1-1.5%), till the condition stabilized. A maximum of two attempts were made at FOI with the technique. If the above technique failed, an appropriate-sized LMA was inserted and FOB intubation attempted via the LMA.

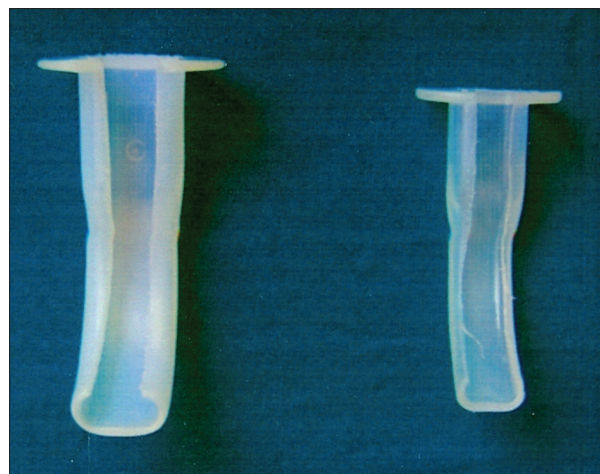


Figure 1: Modified Guedel airway. Guedel oropharyngeal airway was modified by cutting it through its entire dorsal length to facilitate the removal of the fiberoptic

In the FOB-LMA group, an appropriate-sized LMA was inserted by the standard technique and the cuff inflated. The anesthetic circuit was connected to the LMA via a swivel connector; position of the LMA confirmed by adequate chest expansion on assisted ventilation and presence of a capnograph trace. The LMA was secured and anesthesia maintained with halothane (1-1.5%) in oxygen. The FOB was inserted via the swivel connector till the tip lay just above the carina and the trachea intubated. The proximal end of the ETT *in situ* was stabilized with a smaller-sized ETT; the LMA was withdrawn over both ETTs using a two handed technique, while stabilizing the ETT in the mouth. All interventions were done by a single anesthesiologist with more than fifteen years of experience in performing pediatric FOI.

FOB was graded as (i) easy—if the vocal cords were easily visualized or (ii) difficult—if manipulation of the modified Guedel airway or LMA repositioning was required to locate the vocal cords. The time taken for FOB (time from insertion of the FOB into the oral airway or the LMA to placement above the carina) and the time taken from visualization of the carina to confirmation of endotracheal intubation were noted. The total time taken for FOI was taken as the time from insertion of the FOB via the oral airway or LMA to the time of confirmation of endotracheal intubation.

Unpaired Student's t-test was used for analysis of demographic data and for comparison of time taken for FOB and FOI. The Chi-square test was used to compare ease of FOB and FOI, maneuvers required for FOI and incidence of desaturation. *P* value of < 0.05 was considered to be statistically significant. For a 50% difference in the first attempt success rate for

intubation between the two groups with 15 patients in each group, the power of the study was 87%.

Results

Thirty children (25 males, 5 females) were included, 15 in each group. The demographic data were comparable between the two groups [Table 1].

FOB was significantly easier in the FOI-LMA (13/15, 86.7%) as compared with FOI-ORAL group (5/15, 33.3%, $P = 0.03$). FOB was unsuccessful after two attempts with the technique in two children, one in each group, in the initial part of the study. However, subsequently FOB was successful after crossing over to the other group. The time taken for FOB was significantly less in the FOB-LMA group compared to that in the FOB-ORAL group [Table 2].

FOI was successful in all children. FOI via the LMA was achieved in 11/15 (73.33%) children in the first attempt (without maneuvers) compared with 3/15 (20%) children in the FOB-ORAL group ($P = 0.012$). Difficulty in negotiating the ETT into the larynx was overcome with partial withdrawal and 90° anticlockwise rotation and reinsertion in 4 children in the FOB-LMA group. This maneuver allowed successful intubation via the modified Guedel's airway in 11 children. However, in one child in the FOB-ORAL group, intubation could be achieved only after flexing the neck in addition to the above maneuver. The difference in the total time taken for intubation between the two groups was not statistically significant ($P = 0.053$) [Table 2]. Desaturation did not occur

in any child in the FOB-LMA group. Transient desaturation to <92% occurred in 6/15 children in FOB-ORAL group ($P = 0.006$). The LMA was successfully removed following intubation, without any incidence of accidental extubation in all children in the FOB-LMA group.

Discussion

This study was done to evaluate the ease of oral FOI via a modified Guedel airway and LMA. Due to the non-availability of an Ovassapian pediatric oral airway, we devised a modification of pediatric Guedel airway size 0 and 1. After removing the bite block, a slit was made along the entire dorsal aspect and the edges smoothed. This modified Guedel airway made it easier to insert the FOB into the mouth in the midline. The slit enabled easy removal of the airway once the FOB was positioned in the trachea. Despite this, visualizing the larynx and trachea was difficult in 10/15 children but was eventually successful in 14/15 children with manipulation of the FOB or the jaw lift maneuver. In the one child in whom FOB was unsuccessful in this group, it was achieved via the LMA.

The LMA is now routinely used in children in preference to endotracheal intubation.^[11-17] LMA guided FOI in the child with a difficult airway has gained popularity over the years, as it allows for oxygenation and provision of inhalation anesthetic.^[2-9] LMA has been used to facilitate ETT placement with the help of guides such as catheters and guidewires.^[14,15] In this study, when the FOB was introduced via the LMA, locating the trachea and larynx was easy in majority of the children. Repositioning of the LMA was required in 3/15 children before the laryngeal structures could be visualized. In one child, intubation with FOB via an LMA failed and it was eventually successfully passed via the modified Guedel airway. These findings highlight the possibility of failure to visualize the larynx with the FOB regardless of the technique.

Despite successful FOB, the smooth insertion of the ETT over the FOB may be obstructed at the level of the arytenoid cartilages, frequently by the right arytenoid cartilage, requiring some maneuvers to overcome the obstruction.^[18] We encountered this in 16/30 (53.3%) children in this study, the majority in the FOB-ORAL group. This may be because of the more acute angle for the ETT to negotiate orally compared to the curvature of the LMA shaft.

An LMA has to be removed over the ETT before it can be connected to the anesthetic circuit. Pediatric ETTs are short in comparison with the length of the LMA, especially when the distal end extends beyond the LMA. Various methods

Table 1: Demographic data

Parameter	FOB-ORAL n=15 mean±SD (range)	FOB-LMA n=15 mean±SD (range)	P value
Age (years)	3.21±1.13 (1-5)	3.18±1.50 (0.7-5)	0.487 NS
Weight (kg)	12.36±1.56 (10-15)	12.62±2.95 (9-16)	0.863 NS
Gender			
Male	12	13	
Female	3	2	

NS: Not significant

Table 2: Time taken for Fiberoptic intubation

Event	FOB-ORAL n=15 mean±SD (range)	FOB-LMA n=15 mean±SD (range)	P value
FOB (seconds)	108.66±52.43 (19-242)	59.20±42.85 (19-182)	0.005 HS
FOI (seconds)	33.53±13.53 (16-68)	55.40±18.76 (33-68)	0.001 HS
Total intubation time (seconds)	142.00±55.37 (38-268)	114.60±50.19 (78-242)	0.053 NS

HS: Highly significant, NS: Not significant

have been described to circumvent this problem. We used the technique described by Weiss *et al.* and found the technique easy to use and did not encounter accidental extubation in any child.^[19] Other described techniques include using a pediatric airway exchange catheter,^[20,21] guidewire,^[22] and a gum elastic bougie.^[23] These devices have the advantage of reducing the chances of accidental extubation during the above manipulations. We did not have any of these devices and hence used the technique described by Weiss *et al.*

There was no desaturation in any child when intubated via the LMA. All the children could be adequately anesthetized and oxygenated during the airway manipulations. In the children intubated via the oropharyngeal airway, there was a higher incidence of desaturation because of the longer time taken to visualize the larynx while they were apneic and not oxygenated. The procedure had to be interrupted in these children and they had to be ventilated via a face mask.

The limitations of our study were that our sample size was small—only 30 children with 15 in each arm. We did not calculate the sample size or the power of the study as we considered this a preliminary study. However, the power of the study was calculated retrospectively.

FOI and intubation can be clinically successful through both modified oropharyngeal Guedel airway and LMA in infants and children under general anesthesia. FOB through the LMA in children has the advantage of shorter bronchoscopy time and easier FOI with less manipulation. It has the added advantage of continuous ventilation throughout the procedure and therefore less chance of desaturation during manipulation.

References

- Auden SM. Flexible fiberoptic laryngoscopy in the pediatric patient. In: Riazi J, editor. The difficult pediatric airway. *Anesthesiol Clin North Am* 1998;16:763-93.
- Yang YS, Son CS. Laryngeal mask airway guided fiberoptic tracheal intubation in a child with a lingual thyroglossal duct cyst. *Pediatr Anesth* 2003;13:829-31.
- Walker RW, Allen DL, Rothera MR. A fiberoptic intubation technique for children with mucopolysaccharidoses using the laryngeal mask airway. *Pediatr Anesth* 1997;7:421-6.
- Patel A, Venn PJ, Barham CJ. Fiberoptic intubation through a laryngeal mask airway in an infant with Robin sequence. *Eur J Anaesthesiol* 1998;15:237-9.
- Hasan MA, Black AE. A new technique for Fiberoptic intubation in children. *Anaesthesia* 1994;49:1031-3.
- Heard CM, Caldicott LD, Fletcher JE, Selsby DS. Fiberoptic guided endotracheal intubation via the laryngeal mask airway in pediatric patients: A report of a series of cases. *Anesth Analg* 1996;82:1287-9.
- Selim M, Mowafi H, Al-Ghamdi A, Adu-Gyamfi Y. Intubation via LMA in pediatric patients with difficult airways: Brief clinical reports. *Can J Anaesth* 1999;46:891-3.
- Graham DC, Andrew JW, David LC. The 3.5/4.5 modification for the fiberscope-guided tracheal intubation using the laryngeal mask airway. *Anesth Analg* 1992;75:307-8.
- Yamashita M. Longer tube length eases endotracheal intubation via the laryngeal mask airway in infants and children. *J Clin Anesth* 1997;9:432-3.
- Johr M, Berger TM. Fiberoptic intubation through the laryngeal mask airway (LMA) as a standardized procedure. *Pediatr Anesth* 2004;14:614.
- Chadd GD, Crane DL, Phillips RM, Tunell WP. Extubation and reintubation by the laryngeal mask airway in a child with the Pierre-Robin syndrome. *Anesthesiology* 1992;76:640-1.
- Beveridge ME. Laryngeal mask anesthesia for repair of cleft palate. *Anaesthesia* 1989;44:656-7.
- Markakis DA, Sayson SC, Schreiner MS. Insertion of the laryngeal mask in awake patients with the Robin sequence. *Anesth Analg* 1992;75:822-4.
- Maekawa H, Mikawa K, Tanaka O, Goto R, Obara H. The laryngeal mask may be a useful device for fiberoptic airway endoscopy in pediatric anesthesia. *Anesthesiology* 1991;75:169-70.
- Hasan MA, Black AE. A new technique for fiberoptic intubation in children. *Anaesthesia* 1994;49:1031-3.
- Allison A, McCrory J. Tracheal placement of a gum elastic bougie using the laryngeal mask. *Anaesthesia* 1990;45:419-20.
- Ebata T, Nishiki S, Masuda A, Amaha K. Anesthesia for Treacher Collins syndrome using a laryngeal mask airway. *Can J Anesth* 1991;38:1043-5.
- Asai T, Shingu K. Difficulty in advancing a tracheal tube over a fiberoptic bronchoscope. Incidence, causes and solution. *Br J Anaesth* 2004;92:870-81.
- Weiss M, Gerber AC, Schmitz A. Continuous ventilation technique for laryngeal mask airway removal after fiberoptic intubation in children. *Pediatr Anesth* 2004;14:936-40.
- Peter B, Thomas, Martin PG. The difficult paediatric airway: A new method of intubation using the laryngeal mask airway, Cook® airway exchange catheter and tracheal intubation fiberscope. *Pediatr Anesth* 2001;11:618-21.
- Dasgupta D, Jain A, Baxi V, Parab A, Budhakar A. Fiberoptic intubation using LMA as a conduit and Cook® airway catheter as an exchanger in a case of Tessier 7 facial cleft syndrome. *Indian J Anaesth* 2009;53:230-2.
- Walburn MB, Cornes J, Ryder IG. Fiberoptic intubation through a laryngeal mask airway facilitated by a guide wire. *Anaesthesia* 2000;55:1027-8.
- Rajan GR. Fiberoptic wire guided transoral and through the laryngeal mask airway intubation technique using modified gum elastic bougie. *Anesth and Analg* 2005;101:1880-94.

How to cite this article: Varghese E, Nagaraj R, Shwethapriya R. Comparison of oral fiberoptic intubation via a modified guedel airway or a laryngeal mask airway in infants and children. *J Anaesthesiol Clin Pharmacol* 2013;29:52-5.
Source of Support: Nil, **Conflict of Interest:** None declared.