

# Endocarditis in Cameroon

K. BLACKETT, MD, FRCP

Department of Medicine, CUSS, University of Yaoundé, Cameroon

In the pre-antibiotic era, infective endocarditis was a uniformly fatal disease affecting mainly young adults, often those with underlying rheumatic heart lesions [1]. By 1986, however, the incidence of infective endocarditis in England and Wales had fallen to 16 per million with a 30% mortality rate, the mean age having risen to 51.4 years, and the underlying cardiac pathology being calcific aortic valve disease, prolapse of the mitral valve or a congenital heart defect. The portal of entry was most commonly associated with poor dental hygiene, and the organism in 80% of cases was a streptococcus [2].

In Cameroon, rheumatic heart disease is still common. The cardiomyopathies are a major cause of cardiac pathology, and most cases of congenital heart disease have not as yet been surgically corrected [3]. Clinically, endocarditis may be difficult to diagnose since the symptoms may be non-specific, or confused with a worsening of the cardiac state. However, blood cultures should be taken in all such suspicious cases. Although in early cases there may be no change in valve morphology on echocardiography, and difficulties may arise in distinguishing valve thickening and calcification from endocarditis, in late cases echocardiography can be useful in demonstrating changing valve morphology and in visualising vegetations. We undertake routine echocardiography in all patients referred with valvular and congenital heart disease, as well as those with cardiomyopathies. This paper reports the findings in a group of 20 consecutive patients with infective endocarditis who also had echocardiographic changes.

## Patient selection

The study was undertaken in the medical unit of CHU (Centre Hospitalier et Universitaire), Yaoundé, Cameroon, from 22 May 1984 to 24 October 1986. Subjects over 8 years of age presenting with clinical features suggestive of endocarditis (fever, deteriorating general health, weight loss, sweating, anaemia, clubbing, splenomegaly), and in whom echocardiography showed thickening of valve, changing valve morphology, or vegetations, had blood cultures undertaken on at least three occasions. If these were positive, or if all other clinical and paraclinical features of endocarditis were present in spite of negative blood cultures, the patients were entered into the series. Blood cultures

were repeated on days 1, 3, 7, 14 and 28. Full blood count, sedimentation rate, serum creatinine and electrolytes, and liver function tests were examined before treatment, and weekly thereafter. Urine was also examined weekly for cells, casts, protein and albumin. A standard PA chest X-ray was taken and 12-lead ECG recorded at entry and repeated as clinically indicated.

Two-dimensional (2D) and 'M' mode echocardiography studies were performed by the author before, during and after treatment. The 2D echocardiographs were performed with a Sonel 400 machine, and the 'M' mode studies with an Echovideorex machine (Compagnie Generale de Radiologie) and transducers appropriate to the patient's size.

The patients were subsequently entered into a collaborative drug trial in which ceftriaxone was administered by short (30 min) once daily intravenous infusion, the results of which have been previously reported [4]. The dose was 2 g daily in adults and 1 g daily in children under 12 years, given for 28 days.

The group consisted of 20 patients with a mean age of 26.8 years (median 24 years, range 8–70 years): 11 males (mean age 24 years) and 9 females (mean age 28 years); 15 patients were aged under 15 years; 10 patients had received antibiotics before admission, and in a further 3 cases patients had received unknown therapy which may have included an antibiotic (Table 1). In spite of this, blood cultures were positive in 17 cases, including 5 of the patients who had received antibiotics before admission. The results of the blood cultures are shown in Table 2.

The underlying cardiac pathology was rheumatic heart disease in 17 patients, endomyocardial fibrosis in 2 patients and submitral valve aneurysm in 1 patient. The mitral valve was affected alone in 8 patients, the aortic alone in 5 patients, and in a further 5 patients there was a combined lesion. There were two cases of

Table 1. Antibiotics administered before admission.

Antibiotic	No. of patients
Penicillin G	6
Ampicillin	4
Gentamycin	1
Lincomycin	1
Bactrim	1

10 patients definitely received antibiotics before admission.

7 patients had no therapy before admission.

3 patients had unknown therapy before admission.

Address for correspondence: Dr K. Blackett, Department of Medicine, CUSS, University of Yaoundé, Cameroon, Africa.



endocarditis of a bio-prosthetic valve, one of the mitral and another of the aortic valve. In the patient with a bio-prosthetic aortic valve, presentation was due to embolisation to the popliteal and brachial arteries. Twelve patients presented because of 'fever', six because of general ill health and worsening of their cardiac state, and coma was the presenting feature in a child aged 8 years with concomitant otitis media and meningitis.

### Portal of entry

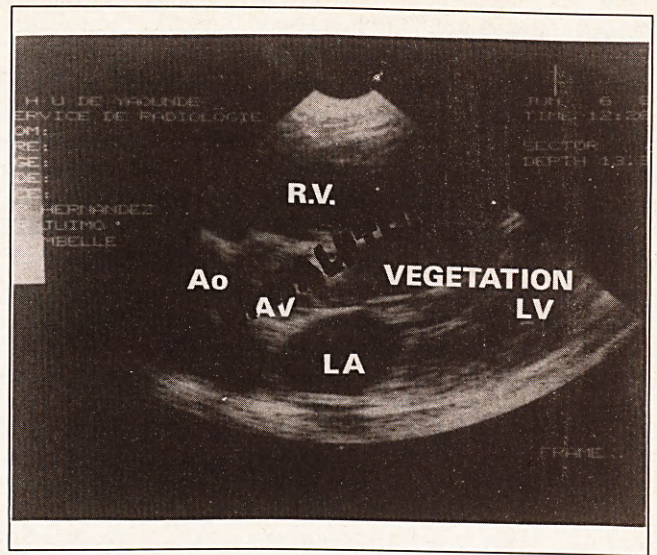
There was no history of recent dental treatment in any patient. In one patient infection may have followed pregnancy and delivery, and in another patient there was pelvic inflammatory disease which may have acted as the focus of infection. Skin scarification was a universal finding.

The mean temperature on admission was 38.56°C (range 36.5–40.0°C) and this had fallen to a mean of 37.6°C on day 1 and 36.8°C by the end of the treatment. Similarly the mean pulse rate of 103/min on admission had fallen to 90/min by the end of the treatment. There was no significant change in the blood pressure during the treatment period. The mean  $\pm$  SD haemoglobin before treatment was 10.4  $\pm$  2.4 g/dl and had risen to 11.4  $\pm$  1.7 g/dl at the end of the treatment, whereas the white cell count fell from 9.6  $\pm$  2.9  $\times 10^9$ /litre to 6.8  $\pm$  2.1  $\times 10^9$ /litre during the same period, with the leukocyte percentage falling from 59  $\pm$  17 to 45  $\pm$  16. Blood cultures became negative within 24 h in all but two cases. In one of these it became negative within 3 days; in the other case infection was due to a resistant organism (actinobacter). Echocardiographic findings at entry were of large vegetations in 8 cases, with thickening of the valve and/or small vegetations suggestive of endocarditis in 12 patients (Fig. 1). A torn mitral valve cord was seen in 1 case, and pericardial effusions were recorded in 4 cases. In 7 patients vegetations had disappeared from the affected valve by the end of the treatment period, and in a further 9 cases there was a diminution in the size of the vegetation. In only one case who completed treatment was the echocardiographic finding unchanged.

**Table 2.** Blood culture results in the patients studied.

Bacteria	No. of patients
<i>Staph. epidermidis</i>	7
<i>Staph. aureus</i>	3
<i>Streptococcus</i>	4
<i>Klebsiella pneumonia</i>	2
<i>E. coli</i>	2
<i>Proteus vulgaris</i>	1
Negative culture	3

In 5 cases the blood culture was positive in spite of antibiotics having been taken before admission.



**Fig. 1.** Two-dimensional long axis echocardiogram showing vegetation of the aortic valve (patient 7). RV, right ventricle; AO, aorta; AV, aortic valve; LA, left atrium; LV, left ventricle.

### Outcome

Only one patient died during antibiotic treatment. This was a boy of 8 years who, in addition to endocarditis of the mitral valve and pericardial effusion, also had otitis media, meningitis and left hemiplegia. He died in coma 4 days after institution of treatment. Blood cultures and CFS cultures were both sterile at the time of death.

Six 'late' deaths occurred after completion of treatment of the endocarditis. The patient with actinobacter endocarditis died from rupture of his submitral aneurysm while awaiting emergency surgery. A young man aged 24 years with severe aortic incompetence died 15 days after completion of treatment for endocarditis in severe left ventricular failure. Arterial and cerebral emboli were responsible for the death of a male patient aged 31 years who had a prosthetic aortic valve. He had endocarditis around his valve ring, with aneurysm of the aorta at that site. A female patient died suddenly while awaiting surgical replacement of her mitral valve; autopsy was refused. One patient died in France in the post-operative period after successful replacement of her aortic valve. A 14-year-old boy treated for endocarditis of his mitral and aortic valves underwent cardiac surgery but died 3 months later with acute heart failure.

Two further patients underwent valve replacement, and these together with the rest of the patients remain alive and well to date—March 1989 (Table 3).

### Discussion

Although 20 patients is a small number on which to base conclusions, it is interesting to note the marked differences between these results and those of the Royal College of Physicians study [2]. The younger age



**Table 3.** Summary of patients studied.

Case	Sex	Age (years)	Clinical diagnosis	Bacteriology	Length of treatment (days)	Outcome—as of March 1989 <sup>a</sup>
1	M	28	Aortic incompetence and mitral incompetence	<i>Staph. aureus</i>	15	Aortic valve replacement; 1 year later healed lesions only. A/W
2	F	23	Aortic incompetence, mitral valve disease, tricuspid incompetence	<i>Staph. epidermidis</i>	28	Clinical and bacteriological cure of endocarditis; patient had cardiac arrest and died 15 days later
3	M	9	Mitral incompetence, pericardial effusion, ? endomyocardial fibrosis	<i>Staph. epidermidis</i>	28	Bacteriological cure. A/W
4	M	24	Aortic incompetence, mitral incompetence	<i>Staph. aureus</i>	28	Bacteriological cure; died in acute left ventricular failure 15 days later while awaiting surgery
5	F	27	Severe mitral stenosis	<i>E. coli</i>	28	Clinical and bacteriological cure. A/W
6	M	10	Severe mitral stenosis and some incompetence	<i>Staph. epidermidis</i>	28	Healed endocarditis found at surgery 4 months later
7	F	36	Aortic incompetence	<i>Streptococcus D</i> <i>Staph. epidermidis</i>	12	Evacuated for emergency surgery; no active infection at surgery; patient died in post-operative period
8	M	46	Mitral incompetence	Gram-negative bacillus	28	Clinical and bacteriological cure
9	M	8	Mitral incompetence, pericardial effusion, otitis media, meningitis	Sterile	4	Severe case of endocarditis and meningitis secondary to otitis media; left hemiplegia; died after 4 days of treatment
10	M	14	Aortic incompetence (rheumatic), mitral incompetence (endocarditis)	Sterile	30	Evacuated for emergency mitral and aortic valve replacement; no active infection at surgery; died 3 months after surgery
11	F	26	Endocarditis or prosthetic mitral valve (rheumatic)	<i>Klebsiella pneumoniae</i>	28	Had three previous episodes of endocarditis; now free from infection for one year. A/W
12	F	12	Endomyocardial fibrosis, pericardial effusion	<i>Streptococcus</i>	28	Bacteriological cure. A/W
13	M	14	Mitral stenosis and incompetence (rheumatic)	<i>Proteus mirabilis</i> and <i>Staph. epidermidis</i>	28	Bacteriological cure. A/W
14	F	24	Aortic incompetence	<i>Staph. epidermidis</i>	28	Bacteriological cure. A/W
15	F	14	Aortic incompetence	<i>Klebsiella pneumoniae</i>	28	Bacteriological cure. A/W
16	M	58	Aortic incompetence	<i>Streptococcus D</i>	18	Emergency evacuation for aortic and mitral replacement; no active infection at surgery. A/W
17	F	70	Mitral stenosis	<i>Streptococcus F</i>	28	Bacteriological cure. A/W
18	M	31	Endocarditis of prosthetic aortic valve and aorta systemic embolisation	<i>Staph. epidermidis</i>	13	Febrile drug reaction necessitated replacing drug; died due to cerebrovascular accident
19	F	20	Mitral incompetence, pelvic infection ( <i>Klebsiella</i> in urine)	<i>Staph. epidermidis</i>	28	Bacteriological cure. A/W
20	M	27	Submitral and aortic aneurysms	<i>Actinobacter</i>	24	Actinobacter-resistant due to drug therapy; patient died due to rupture of subvalvular aneurysm

<sup>a</sup> A/W = alive and well.

group reflects the age distribution in the community in which 50% are under 15 years [5]. Rheumatic valve disease, both aortic and mitral, was the commonest (65%) underlying pathology, reflecting the high incidence of rheumatic heart disease in the community. Endomyocardial fibrosis is not uncommon in Cameroon where it is seen mainly in adolescents and young adults. The two patients affected were aged 12 and 9 years. In one case there was left-sided disease with mitral incompetence and endocarditis of the

mitral valve; in the other there was a pericardial effusion together with clot in the left atrium but no obvious valvular lesion. A young man of 27 years who presented with a 2 months history of fever and cardiac failure was shown on echocardiography to have submitral and subaortic aneurysms, with marked aortic incompetence. He is the third patient to present with subvalvular aneurysm in the past year, the other two patients being children.

The infecting agents were also different from those



expected. Streptococcal infection was rare, being present in only 4 cases. Streptococcal infections do occur in the community, as reflected in the high incidence of rheumatic heart disease. However, the patho-physiology of rheumatic fever is related to an autoimmune reaction and not to invasion by the bacterium itself. Streptococcal endocarditis is usually related to poor oral hygiene, but the excellent dental hygiene in the rural community, with its low level of refined sugars in the diet, reflected in the lack of any history of dental intervention in the patients studied, may be responsible for the low incidence of streptococcal endocarditis in the series. Staphylococcal infections however (*epidermidis* and *aureus*) were discovered in 10 patients. This has been reported in a previous study in Cameroon [6]. That these staphylococci were true aetiological agents and not contaminants was shown by their presence in more than one of the pretreatment blood cultures and their absence once treatment had been instituted. The 'native' treatment for cardiac disease often consists of skin scarification over the area of cardiac impulse accompanied by the rubbing in of herbs. All patients had received such treatment before admission, and it may be that this allowed normal skin commensals such as *Staphylococcus epidermidis* to enter the circulation and thus produce endocarditis.

The changing picture seen on echocardiography probably reflects embolisation of the vegetation as much as organisation. Micro-embolisation is an important feature of endocarditis and often passes unnoticed. It is only when there is a massive embolisation

that the condition is recognised. The occurrence of pulmonary and cerebral embolisation is often responsible for the poor outcome in patients with endocarditis in spite of the institution of effective chemotherapy. At least 3 patients in this study died due to suspected embolisation early in the treatment period before organisation of the vegetations could take place. In the 13 surviving patients there have been no further episodes of endocarditis in the 4 years follow-up period. However, improvement in outcome depends upon early diagnosis triggered by a high index of suspicion.

#### Acknowledgement

I would like to thank Roche Africa Research Foundation for supporting this work.

#### References

1. Hayward, G. W. (1973) Infective endocarditis: a changing disease. *British Medical Journal*, **11**, 706-9.
2. Bayliss, R., Clarke, C., Oakley, C. M. *et al.* (1986) Incidence, mortality and prevention of infective endocarditis. *Journal of the Royal College of Physicians*, **20** (1), 15-20.
3. National Census (Cameroon) 1976.
4. Blackett, K. (1984) The cardiomyopathies in Cameroon. *Annales Universitaires des Sciences de la Santé*, **1**, 235-40.
5. Blackett, K. (1988) La ceftriaxone dans le traitement de l'endocardite. *Medicine Afrique Noire*, Numéro special, 11-13.
6. Muna, W. F. T., Teboh, G., Kingue, S. and Dzietham, R. (1986) Impact of echocardiography in patients suspected of bacterial endocarditis; initial experience in Cameroon. *Annales Universitaires des Sciences de la Santé*, **3** (3), 198-205.



## ROYAL COLLEGE OF PHYSICIANS OF LONDON

### Conference on VIRUSES AND GENITAL CANCER

To be held at the College on 5th December 1989

The conference will include sessions on:

- Viral oncogenesis and *in vitro* transformation
- Epidemiology of cervical cancer
- Natural history of HPV infection of the cervix
- Anal carcinoma – epidemiology in relationship to HPV infection
- Genital warts – clinical manifestations and treatment
- Genital warts – detection of subclinical lesions
- Cervical screening – cost effective/how often?
- Genital viral infections: interaction with HIV
- Vaccines – are they feasible?

The registration fee of £40 includes coffee, lunch and tea

Application forms are available from The Conference Secretary,  
Royal College of Physicians, 11 St Andrew's Place, Regent's Park,  
London NW1 4LE (Telephone 01-935-1174)