

Received: 2015.06.02
Accepted: 2015.08.29
Published: 2016.02.18

Efficacy of Transforaminal Endoscopic Spine System (TESSYS) Technique in Treating Lumbar Disc Herniation

Authors' Contribution:
Study Design A
Data Collection B
Statistical Analysis C
Data Interpretation D
Manuscript Preparation E
Literature Search F
Funds Collection G

ACDG 1,2 **Zhimin Pan***
BDF 3 **Yoon Ha***
ACF 3 **Seong Yi**
BDG 1 **Kai Cao**

1 Department of Orthopaedic Surgery, The First Affiliated Hospital of Nanchang University, Nanchang, Jiangxi, P.R. China
2 Department of Orthopaedic Surgery, The First Hospital of Bijie, Bijie, Kueichou, P.R. China
3 Department of Neurosurgery, Spine and Spinal Cord Research Institute, College of Medicine, Yonsei University, Seoul, South Korea

Corresponding Author:
Source of support:

* Zhimin Pan and Yoon Ha are both considered as the first author
Kai Cao, e-mail: wangxiangrui0819@126.com; caokai0827@yeah.net

The present study was financially supported by the grants of National Natural Science Foundation of China (No. 81460405, 81260399), Research Program of Health and Family Planning Commission of Jiangxi Province (No. 20155087, 20155110)

Background: To compare efficacy and safety of percutaneous transforaminal endoscopic spine system (TESSYS) and traditional fenestration discectomy (FD) in treatment of lumbar disc herniation (LDH).


Material/Methods: A total of 106 LDH patients were divided into TESSYS group (n=48) and FD group (n=58). Visual analogue scale (VAS), Oswestry disability index (ODI), Japanese Orthopedic Association (JOA), and modified MacNab criteria were used for efficacy evaluation. Post-operative responses were compared by enzyme-linked immunosorbent assay (ELISA) based on detection of serum IL-6, CRP, and CPK levels.

Results: In the TESSYS group, compared with the FD group, we observed, shorter incision length, less blood loss, shorter hospital stay, lower hospitalization cost, shorter recovery time, lower complication rate (all $P < 0.001$), and lower VAS scores of lumbago and skelalgia at 3 days and 1, 3, and 6 months postoperatively (all $P < 0.05$). At 24 and 48 h postoperatively, CRP level was remarkably higher in the FD group compared to the TESSYS group ($P < 0.001$). Further, comparison of IL-6 levels at 6, 12, 24, and 48 h postoperatively revealed significantly higher levels in the FD group than in the FESSYS group (all $P < 0.001$).

Conclusions: TESSYS had clinical advantages over FD and entails less trauma and quicker postoperative recovery, suggesting that TESSYS is well tolerated by patients and is a better approach than FD in surgical treatment of LDH.

MeSH Keywords: **Dienestrol • Manipulation, Orthopedic • Osteoarthritis, Spine • Pain Measurement**

Full-text PDF: <http://www.medscimonit.com/abstract/index/idArt/894870>

 34830

 5

 4

 37



Background

Lumbar disc herniation (LDH) is one of the most frequently diagnosed causes of low back pain (LBP) and is a common cause of radiculopathy. LDH presents with considerable variability in LBP among patient populations [1] but patients who have LDH will commonly present symptoms of consistent radiculopathy [2]. LDH can result from general wear and tear associated with constant sitting, squatting, or driving [3]. Epidemiological evidence indicates that axial torque/twist combined with repetitive motions of flexion-extension can result in LDH [4]. Gene mutations have also been implicated in the etiology of LDH, for example, mutations leading to altered expression of proteins such as MMP2 and THBS2 [5]. Clinical treatment of a herniated lumbar disc initially follows a conservative care regimen that includes analgesics, epidural steroid injections, and physical therapy. In a case report, Birbilis et al. presented the case of a 74-year-old man presenting with a large disc herniation at L5-S1, experiencing moderate sciatic pain, and having a positive result in the straight-leg-raising test at 30 degrees. The patient was symptom-free and the spontaneous disappearance of the herniated disc fragment was revealed 1 year later through conservative treatment with medication and physical therapy, suggesting that the disc regression could have been due to dehydration, resorption as a result of an inflammatory reaction, or retraction into the intervertebral space, and underlining the need to limit surgical treatment strictly to patients with neurological deficits and severe unremitting leg pain despite conservative measures [6]. Surgery and minimally invasive procedures are recommended for patients with severe dysfunction of the nerve root or cauda equine when conservative treatments fail to control symptoms [1,7].

Among minimally invasive techniques, the percutaneous transforaminal endoscopic spine system (TESSYS) has steadily become a prevalent therapy for LDH [8,9]. Transforaminal endoscopic lumbar discectomy is popular because of its advanced endoscopic visualization and increased patient demands for minimally invasive procedures [10]. TESSYS, developed by Dr. Thomas Hoogland, made it possible to use foraminoplasty to operate inside the spinal canal and widen the foramen between vertebrae near the facet joint with special reamers [11]. TESSYS is a minimally invasive method for treating lumbar disc pathology compared to the traditional tube or open retractor procedures that rely on direct or microscopic visualization [12]. TESSYS has fewer postoperative complications than conservative surgery, with a mean complication rate of 2.8% [13,14]. For example, transient lower extremity dysesthesia or hypesthesia induced by irritation of nerve root, the most frequent complication of conventional operations, is relatively rare in TESSYS [11]. In addition, TESSYS technique has been reported to achieve high success rates in young and elderly patients due to its unique surgical approach and instrument design [15].

Fenestration discectomy (FD) is indicated primarily for treating LDH; it has several advantages, including short operation time, simple surgical procedure, fast postoperative recovery, markedly lower surgery cost, and preservation of mobility of the operation segments [16]. The purpose of the present study was to further investigate the efficacy and safety of TESSYS compared to FD in treatment of LDH.

Material and Methods

Ethics statement

The study was carried out with the approval of the Institutional Review Board of the First Affiliated Hospital of Nanchang University. Written informed consents were obtained from eligible patients and the study was designed to conform to the Declaration of Helsinki.

Subjects and study design

Between January 2009 to January 2012, 106 LDH patients were admitted to the Department of Orthopaedic Surgery, the First Affiliated Hospital of Nanchang University. From this patient pool, study subjects were randomly enrolled into the present study. The diagnosis of LDH was confirmed by clinical symptoms, lateral X-ray, and MRI examination. Based on different surgery approaches, LDH patients were divided into 2 groups: the TESSYS group and the FD group. In the TESSYS group there were 26 males and 22 females; average age was 39.5 years (range, 22~58 years); average duration was 15.5 months (range, 5 months~6 years); and average follow-up time was 16.7 months (range, 12~25 months). Clinical features were: 9 patients with central herniation, 26 with paramedian herniation, and 13 with foraminal herniation; and within the LDH patients in the TESSYS group, 4 occurred at L3-4, 31 at L4-5, and 13 at L5-S1. In the FD group there were 31 males and 27 females; average age was 42.8 years (range, 27~61 years); average duration was 22.3 months (range, 6 days~7 years); and average follow-up time was 17.3 months (range 12.5~23.5 months). The FD group had 18 patients with central herniation, 15 with paramedian herniation, and 15 with foraminal herniation; and within the LDH patients in the FD group, 5 occurred at L3-4, 34 at L4-5, and 19 at L5-S1. Patient exclusion criteria were: (1) LDH associated with other diseases, including neuropathy, incontinence, metabolic diseases, any diseases related to heart, lung, liver, or kidney, or acute/chronic inflammation; (2) multi-level disc herniation; (3) infection of spine, tumor, discitis, or vertebral tuberculosis; (4) recurrent intervertebral disc herniation; and (5) lumbar instability or spondylolisthesis at more than 2 levels.

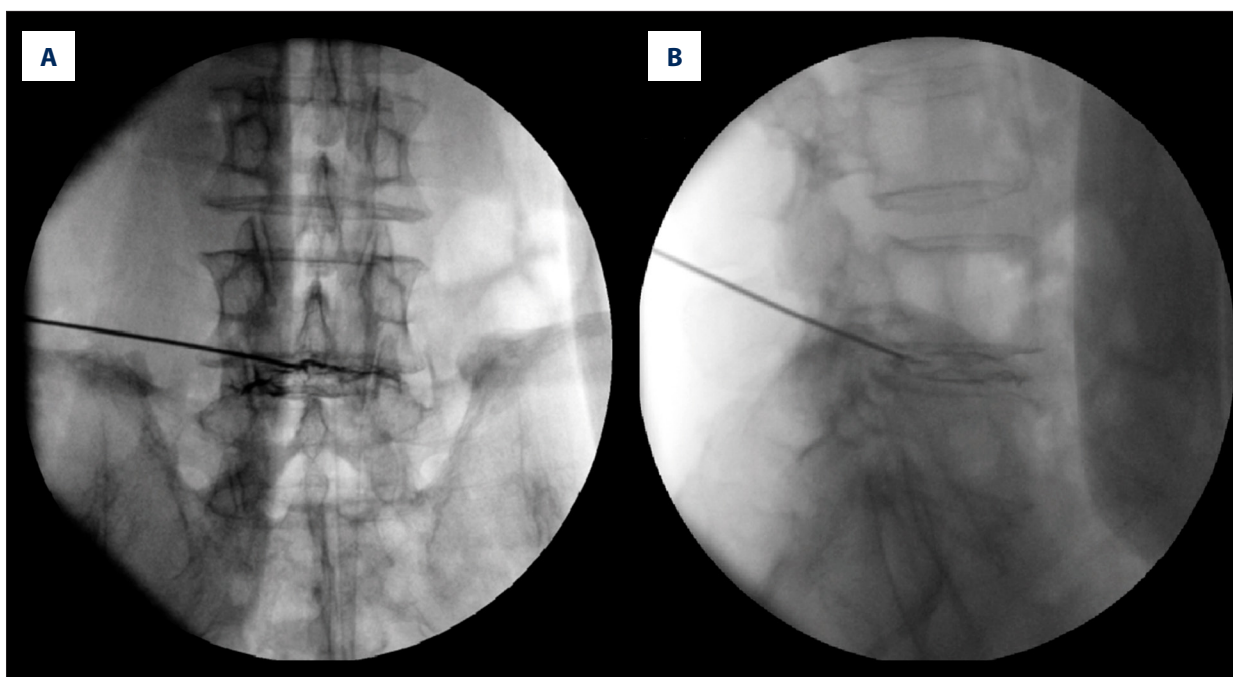


Figure 1. Anteroposterior (A) and lateral (B) x-ray film showing needle position of transforaminal endoscopic spine system procedure performed with posterolateral approach.

TESSYS procedures

Patients were arranged in lateral position with the affected side upwards, and coxa and knee bent. Using C-arm X-ray devices, the herniated disc was verified and the direction and site of puncture was marked. After being sterilized and draped, patients were given local infiltration anesthesia using lidocaine (1%) preoperatively. The procedure was performed with posterolateral approach. When the spinal needle reached the intervertebral disc through the foramen intervertebrale, acidic coeruleum methylenum (1 ml) was injected to stain the degenerated nuclear tissue (Figure 1). The amount of contrast agent was carefully controlled to avoid dye leaking to the canalis spinalis via fractured annulus fibrosus (AF). Prior to removing the spinal needle, a guide wire was inserted through the spinal needle, and then a 0.8 cm skin incision was made along the guide wire, followed by sequential dilatation of the tract, which could then make way for a working cannula. The position for the working channel was visualized and finalized under the C-arm. Then, the foramen intervertebrale was washed with continuous normal saline under an endoscope. After identification of the structures, the blue-stained degenerated nucleus pulposus (NP) was then removed using various grasping forceps and assisted by use of a microscope. After the nerve root decompression was performed, the working cannula was retracted and the skin was stitched.

FD surgery

Patients were positioned in prone position with the abdomen free, and epidural anesthesia was given with 15–18 mL of 1.5% plain lidocaine through a catheter. A 4-cm posterior midline incision was made. The sacrospinal muscle was separated along the lateral margin of the acantha and lamina after subcutaneous tissue and aponeurotic fascia were cut open. With the upper and lower lamina and zygapophyseal joints exposed, fenestration was performed by resecting partial lamina using bayonet tissue forceps and then a flavectomy was carried out to expose the dural sac and nerve root. A nerve root retractor was used for medial retraction of the spinal dura mater and nerve root and then the herniated intervertebral disc tissue was exposed. The ligamenta longitudinale posterius and AF were incised using a microknife. The herniated NP and remaining degenerated NP within the intervertebral disk were removed using an NP clamp. The canalis spinalis and nerve root canals were examined and the nerve root was loosened. The wound was washed after complete hemostasia and a drainage tube was kept in place. Finally, the incision was sutured.

Postoperative management

For the TESSYS group, patients were given antibiotic for 1–3 days to prevent infection. Anti-inflammation and dehydration protocols were implemented by giving mannitol and dexamethasone for 3 days; after complete bed recovery for 3 h, patients were allowed out-of-bed activity with assistance

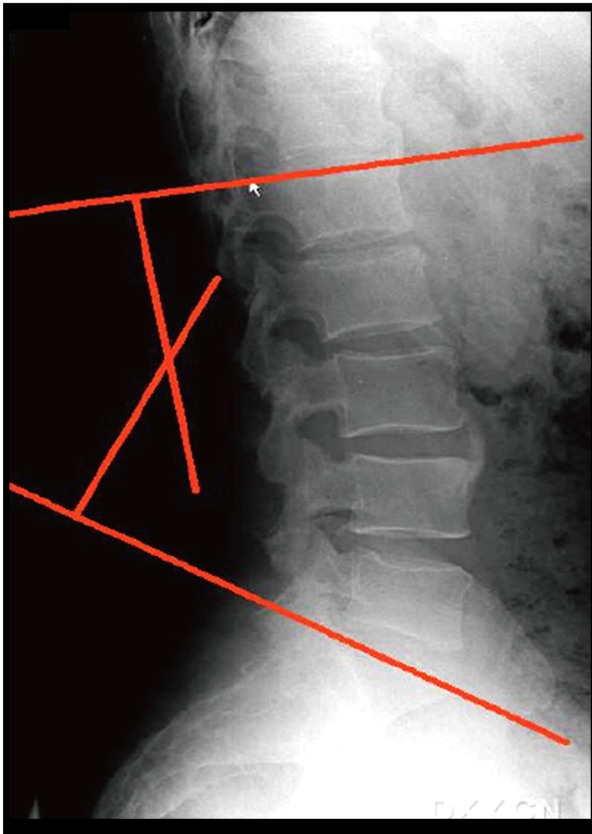


Figure 2. Measurement of lumbar lordosis angle, showing that intersection angle of perpendicular lines to the 2 tangents was the angle of the L1 and S1 by Cobb method.

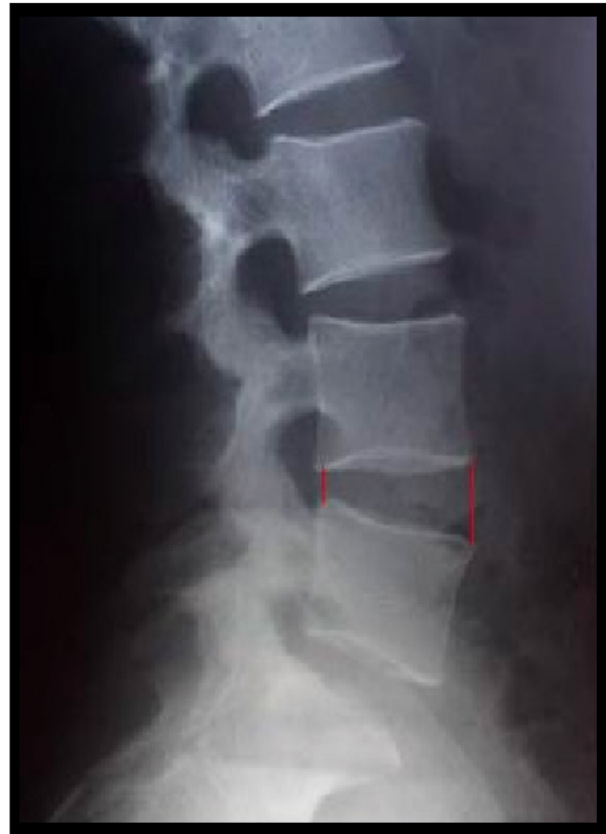

Figure 3. Measurement of the height of intervertebral space with the average value of the front distance between 2 vertebrae and the posterior distance between the 2 vertebrae by Frymoyer-Pope method.

of a girdle brace. Patients were discharged from the hospital after 3–6 days with straight leg raising exercise training to avoid adhesion of the nerve root. Patients were allowed to perform moderate lumbar and dorsal extensor exercises after 1 month. For patients in the FD group, hormone therapy, neurotrophic drugs, and drugs that ameliorate microcirculation were given. The drainage tube was removed when the drainage volume was less than 50 mL/24 h. With the help of a girdle brace, patients walked as appropriate 3–5 days after the surgery. Lumbar and back muscle exercises were recommended 2 weeks after the surgery and patients were asked to wear the girdle brace for 1 month and to avoid strenuous activities for 3 months.

Treatment efficacy assessment

Clinical data, such as time of surgery, the length of incision, volume of bleeding during surgery, and hospitalization time, were recorded. Postoperative follow-up was done by physicians who did not participate in the surgery. The evaluation of osphalgia and skelalgia condition at 1 day before the surgery and at 3 days, 1 month, 3 months, 6 months, and 12

months after the surgery were performed with the visual analogue scale (VAS) [17]. For the assessment of lumbar function, we used the Oswestry disability index (ODI) and the Japanese Orthopaedic Association (JOA) back pain evaluation questionnaire [18,19]. Clinical response was evaluated using modified MacNab criteria at the last follow-up [20]. Patients received a lateral X-ray of lumbar vertebra 6 months after the surgery. The sagittal lordosis of lumbar vertebra was presented using lumbar lordosis (LL). Cobb method was used for measurement: tangents were drawn on the superior endplate of L1 and S1 on the lateral X-ray film of lumbar vertebra, respectively. The intersection angle of lines perpendicular to the 2 tangents was the angle of the L1 and S1 (Figure 2). The ratio of the distance among vertebrae (d) and the superior vertebrae (D) (d/D) was measured to assess the change in height of the target intervertebral space. Frymoyer-Pope method was utilized for measuring the height of the intervertebral space: the average value of the front distance between 2 vertebrae and the posterior distance between the 2 vertebrae (Figure 3). All measurements were made 2 times and average values were obtained.

Enzyme-linked immunosorbent assay (ELISA) for serum IL-6, CRP, and CPK levels

Peripheral venous blood samples (5 ml) were collected in sterile tubes on the 1st morning after patients were admitted to the hospital. Additional samples in the series were collected at 1, 6, 12, and 24 h after the surgery. Within 2 h of collection, blood samples were centrifuged at 3000 r/min for 15 min at room temperature, and serum was separated and placed in sterile freezing tubes and stored at -20°C for further use. ELISA Kit (Innogen Company, Shenzhen) was used for detection of serum IL-6, CRP, and CPK following the manufacture's protocol.

Statistical analysis

Data are presented as means \pm standard deviation (SD). The 2-sample *t* test was used to inspect measurement data and the chi-square test was performed for data categories. Comparisons between groups were performed by either *t* test (with homogeneity of variance) or rank test (with heterogeneity of variance). SPSS18.0 software (SPSS Inc., Chicago, IL, USA) was used for data analysis. Statistical significance was set at *P* value less than 0.05.

Results

Comparison of surgery-related indicators

Our data collected show significantly shorter incision length, less blood loss, shorter hospital stay, lower cost of hospitalization, and shorter recovery time in the TESSYS group compared to the FD group (all $P < 0.01$). No significant differences between the 2 groups were found when surgery time and return-to-work rates were compared (both $P > 0.05$). The procedure-related complication rate for the TESSYS group and FD group were 6.3% (3/48) and 20.7% (12/58), respectively, showing a notably lower rate in the TESSYS group ($P < 0.01$). Three patients developed temporary postoperative limb paresthesia, including hyperalgesia and/or numbness, in both groups. The symptom was ultimately resolved at 1-month follow-up, following conservative treatment. In the FD group, dural laceration occurred in 2 patients and was managed by intraoperative dural repair and postoperative conservative treatment, with removal of the drainage tube when significant drainage fluid had disappeared. Limb weakness occurred in 4 patients but they regained strength to preoperative levels within 6 months after conservative treatment. Acute urinary retention was encountered in 4 patients and urinary function was restored after local massage and intermittent catheter opening. There were no reports of nerve root injury in either group (Table 1).

Comparison of clinical efficacy

VAS, JOA, ODI score, and LL were measured to compare the clinical efficacy of the TESSYS group and FD group. There was no significant difference in preoperative VAS score for osphalgia and skelalgia, JOA score and ODI score for lumbar function, or LL for sagittal lordosis of lumbar vertebra between the TESSYS group and FD group (all $P > 0.05$). The VAS, JOA, and ODI score in both groups were significantly improved postoperatively (all $P < 0.01$). The postoperative VAS score of the TESSYS group at 3 days, 1 month, 3 months, and 6 months after the surgery was significantly lower than that in the FD group at the corresponding time period (all $P < 0.05$). However, no significant differences in VAS score at 12 months after the surgery was found between the 2 groups ($P > 0.05$). As for postoperative JOA and ODI score, no notable difference was found between the 2 groups at each corresponding follow-up time point (all $P > 0.05$) (Table 2). Based on the modified MacNab, at the end of the follow-up, 95.84% of the patients in the TESSYS group and 94.82% of patients in the FD group were classified as excellent or good, with no significant differences between the 2 groups ($P > 0.05$). Some patients were reexamined by MRI post-surgery and showed significant regression or disappearance of disc herniation (Figure 4).

Change in lumbar stability

To study the lumbar stability in the TESSYS group and FD group, Cobb angle and ratio of d/D were measured. The preoperative and postoperative Cobb angle showed no evident change in the FD group ($25.38 \pm 6.89^{\circ}$ vs. $24.48 \pm 6.08^{\circ}$, $t = 0.774$, $P > 0.05$), but in the TESSYS group, postoperative Cobb angle was reduced significantly as compared with preoperative Cobb angle ($23.36 \pm 6.54^{\circ}$ vs. $26.81 \pm 7.19^{\circ}$, $t = 4.769$, $P < 0.01$). No obvious differences were found in the d/D, which was measured for changes in height of target intervertebral space in the 2 groups before and after the surgery ($P > 0.05$).

Comparison of serum CRP, CPK, and IL-6 levels

There was no statistical difference in serum CRP level between the 2 groups preoperatively and at 1, 6, and 12 h after surgery (all $P > 0.05$). However, at 24 and 48 h after surgery, CRP levels were remarkably higher in the FD group than in the TESSYS group ($P < 0.001$) (Table 3). Although CPK levels increased observably in both groups at 1, 6, 12, and 48 h after surgery, the increases in CPK level in the FD group were significantly higher when compared to the TESSYS group ($P < 0.001$) (Table 4). The differences in IL-6 levels between the 2 groups were not significant immediately following surgery ($P > 0.05$). However, at 6, 12, 24, and 48 h after surgery, the difference in IL-6 levels between the 2 groups became notable, with IL-6 levels increasing significantly faster in the FD group (all $P < 0.001$) (Table 5).

Table 1. Comparison of surgery-related indicators in lumbar disc herniation patients between transforaminal endoscopic spine system and fenestration discectomy group (\pm s).

	TESSYS	FD	P value
Operating time (min)	64.8 \pm 16.2	72.0 \pm 12.6	<i>P</i> >0.05
Incision length (cm)	0.8	3.7 \pm 0.8	<i>P</i> <0.01
Blood loss (ml)	13.8 \pm 3.6	87.2 \pm 32.3	<i>P</i> <0.01
Hospital stay (days)	7.2 \pm 1.6	12.8 \pm 3.8	<i>P</i> <0.01
Cost of hospitalization (RMB)	8732.9	11075.1	<i>P</i> <0.01
Recovery time (week)	10.2 \pm 2.7	14.4 \pm 3.1	<i>P</i> <0.01
Return-to-work rate (%)	94.7 (36/38)	95.3 (40/42)	<i>P</i> >0.05
Change in surgical approach (n)	0	0	
Complications (n)	3	12	<i>P</i> <0.01
Limb weakness	0	4	<i>P</i> >0.05
Limb paresthesia	3	3	<i>P</i> >0.05
Nerve root injury	0	0	
Dural laceration	0	2	<i>P</i> >0.05
Postoperative urinary retention	–	4	–

TESSYS – transforaminal endoscopic spine system; FD – fenestration discectomy.

Table 2. Comparison of visual analogue scale score of lumbago and skelalgia between transforaminal endoscopic spine system and fenestration discectomy group (\pm s).

Time	TESSYS		FD		TESSYS		FD	
	Osphyalgia	Skelalgia	Osphyalgia	Skelalgia	JOA	ODI	JOA	ODI
Pre-op	4.7 \pm 1.5	6.8 \pm 2.1	5.1 \pm 1.3	7.3 \pm 1.8	15.1 \pm 4.6	51.7 \pm 15.4	13.9 \pm 6.4	59.8 \pm 17.4
Post-op (3 days)	2.3 \pm 1.1 ^{1,2}	2.2 \pm 1.7 ^{1,2}	3.3 \pm 0.9 ¹	2.6 \pm 1.4 ¹	–	–	–	–
Post-op (1 month)	2.0 \pm 1.2 ^{1,2}	1.6 \pm 1.5 ^{1,2}	2.6 \pm 1.3 ¹	2.0 \pm 1.1 ¹	19.9 \pm 3.6 ^{4,5}	21.0 \pm 5.5 ^{4,5}	18.7 \pm 3.6 ⁴	26.3 \pm 8.2 ⁴
Post-op (3 months)	1.7 \pm 0.7 ^{1,2}	1.2 \pm 0.8 ^{1,2}	2.2 \pm 1.1 ¹	1.5 \pm 1.4 ¹	25.3 \pm 2.1 ^{4,5}	15.3 \pm 4.1 ^{4,5}	26.1 \pm 5.2 ⁴	15.9 \pm 6.2 ⁴
Post-op (6 months)	1.6 \pm 1.1 ^{1,2}	0.9 \pm 0.6 ^{1,2}	1.9 \pm 0.6 ¹	1.1 \pm 0.8 ¹	26.7 \pm 2.9 ^{4,5}	13.2 \pm 5.9 ^{4,5}	26.8 \pm 3.2 ⁴	12.1 \pm 4.2 ⁴
Post-op (12 months)	1.6 \pm 0.4 ^{1,3}	0.9 \pm 0.3 ^{1,3}	1.4 \pm 0.2 ¹	1.0 \pm 0.9 ¹	27.1 \pm 1.9 ^{4,5}	8.6 \pm 2.9 ^{4,5}	27.4 \pm 1.2 ⁴	10.1 \pm 1.5 ⁴

TESSYS – transforaminal endoscopic spine system; FD – fenestration discectomy; JOA – Japanese Orthopaedic Association; ODI – Oswestry Disability Index; pre-op – pre-operation; post-op – post-operation; ¹ compared with pre-operative VAS, *P*<0.01; ² compared with FD group, *P*<0.05; ³ compared with FD group, *P*>0.05; ⁴ compared with pre-operative JOA or ODI, *P*<0.01; ⁵ compared with FD group, *P*<0.05.

Discussion

Our research data suggests that both TESSYS and FD are effective in LDH treatment. However, we also uncovered significant benefits to TESSYS over those observed for FD. TESSYS proved to be minimally invasive, with lower post-operative burden and rapid recovery under the strict control of operation indication. Due to high demand for less traumatic surgical procedures, minimally invasive spine operation procedures have been commonly used in recent years. Compared with traditional open

or tube retractor surgery, TESSYS was significantly superior in many factors. First, the temporary complication rates of TESSYS are low, as measured by persistent sensory deficits (1%), dysesthesias (10%), and dural tears (0.3%), compared to traditional fenestration discectomy (FD) conducted under general anesthesia [21,22]. Moreover, TESSYS was reported to be a safe and effective treatment for LDH owing to minimal iatrogenic damage to the nerve root because of inherent features of the procedure, such as targeted posterolateral access, broadening the foramen, and more intelligent instrumentation to increase

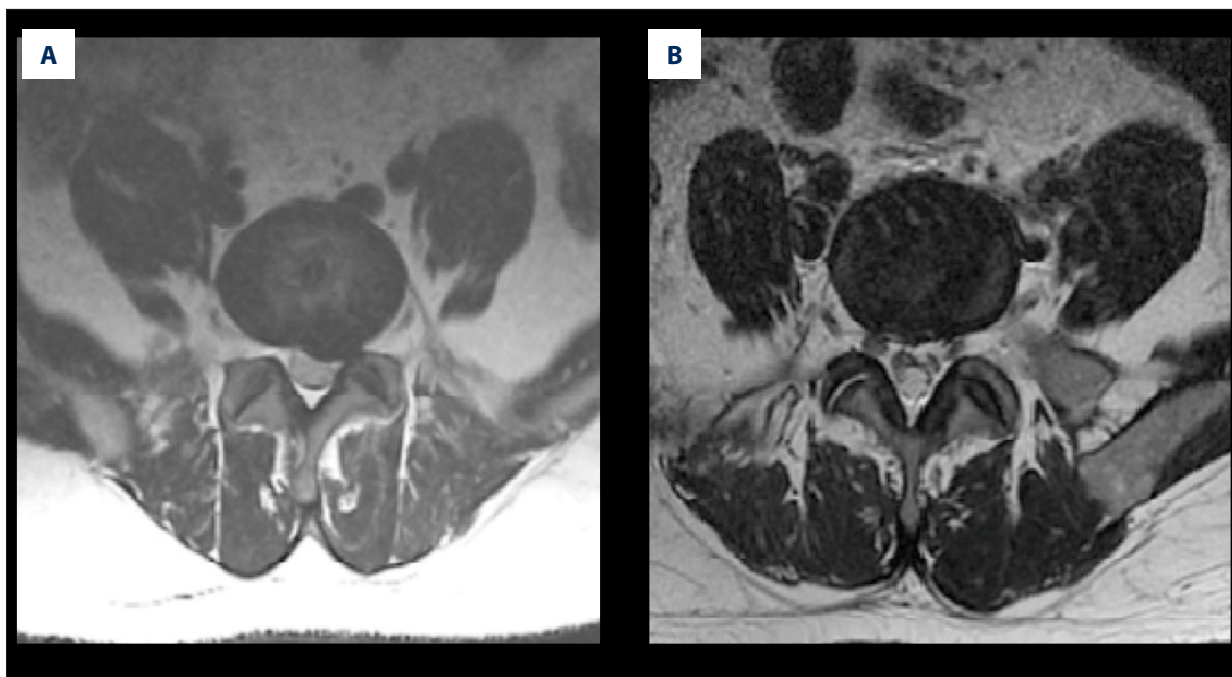


Figure 4. Axial images of preoperative MRI examination (A) showing significant regression of disc herniation and axial images of postoperative MRI examination (B) showing significant disappearance of disc herniation.

Table 3. Comparison of preoperative and postoperative C-reactive protein (CRP) level between transforaminal endoscopic spine system and fenestration discectomy group ($\pm s$).

	FD	TESSYS	F value	P value
Pre-op	0.17±0.10	0.15±0.07	0.498	0.490
Post-op (1 h)	0.22±0.09	0.16±0.07	2.526	0.129
Post-op (6 h)	0.28±0.09	0.21±0.05	4.282	0.053
Post-op (12 h)	0.29±0.11	0.26±0.06	1.035	0.322
Post-op (24 h)	1.84±0.74	0.18±0.09	48.966	<0.001
Post-op (48 h)	2.61±0.93	0.10±0.04	73.089	<0.001
F value	43.29	21.52	48.483*	
P value	<0.001	0.001	<0.001*	

TESSYS – transforaminal endoscopic spine system; FD – fenestration discectomy; pre-op – pre-operation; post-op – post-operation; # main effects between groups ($F=119.53, P<0.001$), main effects among different time ($F=43.086, P<0.001$); * interaction effects ($F=48.483, P<0.001$).

the distance between the needle and the nerve root [12,23]. Furthermore, the stability of ligamentum flavum and intracanal capsule structures was maintained during the TESSYS procedure by microscopic or direct visualization to manage the extruded disc fragment, causing less scar formation [11]. TESSYS also was clearly associated with good clinical outcomes, high quality of life, shorter hospitalization, and high satisfaction rate due to lack of rebarbative scar tissue on the skin [15]

Our study indicates that patient satisfaction in both groups was over 94% at the final follow-up. The VAS of the 2 groups had obvious improvement compared to VAS before surgery; however, there were no significant differences at 12 months after the operation. In addition, the JOA and ODI scores in the 2 groups also improved but were not statistically significant during the same follow-up period. In this study, the amount of bleeding in TESSYS was significantly lower than that of FD

Table 4. Comparison of preoperative and postoperative creatine phosphokinase (CPK) level between transforaminal endoscopic spine system and fenestration discectomy group (\pm s).

	FD	TESSYS	F value	P value
Pre-op	64.28 \pm 4.69	78.03 \pm 7.17	25.762	<0.001
Post-op (1 h)	139.87 \pm 14.15	77.04 \pm 8.17	147.800	<0.001
Post-op (6 h)	220.54 \pm 23.49	105.05 \pm 17.23	157.106	<0.001
Post-op (12 h)	298.11 \pm 26.03	121.82 \pm 22.03	267.294	<0.001
Post-op (24 h)	270.87 \pm 43.50	123.56 \pm 13.08	105.149	<0.001
Post-op (48 h)	185.5 \pm 21.06	102.41 \pm 14.68	104.762	<0.001
F value	52.85	40.16	58.390*	
P value	<0.001	<0.001	<0.001*	

TESSYS – transforaminal endoscopic spine system; FD – fenestration discectomy; pre-op – pre-operation; post-op – post-operation; # main effects between groups ($F=462.497$, $P<0.001$), main effects among different time ($F=143.219$, $P<0.001$); * interaction effects ($F=58.390$, $P<0.001$).

Table 5. Comparison of preoperative and postoperative interleukin-6 (IL-6) between transforaminal endoscopic spine system and fenestration discectomy group (\pm s).

	FD	TESSYS	F value	P value
Pre-op	0.25 \pm 0.04	0.25 \pm 0.05	0.002	0.963
Post-op (1 h)	0.30 \pm 0.02	0.33 \pm 0.05	2.948	0.111
Post-op (6 h)	0.87 \pm 0.05	0.26 \pm 0.05	684.406	<0.001
Post-op (12 h)	0.93 \pm 0.12	0.22 \pm 0.07	248.296	<0.001
Post-op (24 h)	0.98 \pm 0.09	0.26 \pm 0.05	408.912	<0.001
Post-op (48 h)	1.07 \pm 0.10	0.25 \pm 0.06	460.738	<0.001
F value	45.9	13.43	147.637*	
P value	<0.001	0.003	<0.001*	

TESSYS – transforaminal endoscopic spine system; FD – fenestration discectomy; pre-op – pre-operation; post-op – post-operation; # main effects between groups ($F=1140.072$, $P<0.001$), main effects among different time ($F=119.611$, $P<0.001$); * interaction effects ($F=147.637$, $P<0.001$).

and patients who had undergone TESSYS stopped bleeding more completely. Additionally, the direct visualization of the target in TESSYS could have contributed to the decreased fibrillation of canalis spinalis as well as the effects on cavum epidurale and nerve root, while the adhesion of cavum epidurale and nerve root may cause the postoperative leg pain.

Traditionally, minimally invasive techniques for surgical discectomy have been defined as smaller incisions, tubular retractors, microscopically assisted tissue dissection, and conservative removal of only extruded or sequestered nucleus pulposus with preservation of the annulus. The first truly minimally invasive technique was chymopapain dissolution of the nucleus pulposus,

and other percutaneous techniques followed; however, none were as efficacious as the gold standard of microlumbar discectomy until endoscopically visualized methods evolved to allow visualized mechanical discectomy through the foramen. In experienced hands, such a technique is as effective as microlumbar discectomy and results in less surgical morbidity for herniation that is appropriate for this minimally invasive endoscopic surgical portal that completely avoids traumatizing the normal anatomy of the dorsal musculature and ligamentous structures, supplying a novel therapeutic direction for LDH in the future.

Systemic wound response measurements in our study revealed that TESSYS caused less damage to local muscle tissues than

that of the open surgery, implying that patients tolerate TESSYS well and that TESSYS may be a more effective approach for treating LDH. CRP levels signify nonspecific response to tissue injury, and serum CRP is an acute-phase protein produced by hepatic synthesis [24]. Serum CRP only exists in minute quantities in healthy people, and its concentration increases rapidly in inflammation and tissue injury, and is used as an effective index to distinguish bacterial infection and virus infection [25]. CRP increases rapidly and exponentially in settings such as acute inflammation, tissue injury, myocardial infarction, surgical trauma, and radiation injury [26]. CPK is an important intracellular enzyme expressed by various tissues and cell types [27]. CPK is rarely found outside cells under normal circumstances when muscle cell membranes are intact and undamaged [28,29]. Mechanical and hypoxic ischemic injury can cause damage to the muscle cell membrane and promote release of CPK, thus increasing serum CPK activity for endocyte release into the blood [30]. Therefore, CPK is a good serum indicator for muscle damage [31]. By contrast, IL-6 is an important inflammatory cytokines in the cytokine network [32]. It can activate neutrophils and increase the production of inflammatory mediators after trauma, further promoting systemic inflammatory response syndrome after trauma. IL-6 can also promote the release of soluble TNF receptor and IL-1 receptor 2 and decrease the function of TNF- α and IL-1, mediating anti-inflammatory effects [33,34]. Compared to CRP, IL-6 is a more sensitive inflammation marker [35]. Surgery is a trauma for the body and it can cause local tissue damage and lead to systemic stress response [36]. The degree and duration of postoperative stress responses reflects the impact of the surgical procedure on the body. Therefore we used CRP, CPK, and IL-6 as our main parameters to measure postoperative responses [37].

References:

- Cowperthwaite MC, van den Hout WB, Webb KM: The impact of early recovery on long-term outcomes in a cohort of patients undergoing prolonged nonoperative treatment for lumbar disc herniation: clinical article. *J Neurosurg Spine*, 2013; 19: 301–6
- Wang JC, Dailey AT, Mummaneni PV et al: Guideline update for the performance of fusion procedures for degenerative disease of the lumbar spine. Part 8: lumbar fusion for disc herniation and radiculopathy. *J Neurosurg Spine*, 2014; 21: 48–53
- Sloan TJ, Walsh DA: Explanatory and diagnostic labels and perceived prognosis in chronic low back pain. *Spine (Phila Pa 1976)*, 2010; 35: E1120–25
- Marshall LW, McGill SM: The role of axial torque in disc herniation. *Clin Biomech (Bristol, Avon)*, 2010; 25: 6–9
- Hyun SJ, Park BG, Rhim SC et al: Progression of lumbar spinal stenosis is influenced by polymorphism of thrombospondin 2 gene in the Korean population. *Eur Spine J*, 2014; 23: 57–63
- Birbilis TA, Matis GK, Theodoropoulou EN: Spontaneous regression of a lumbar disc herniation: case report. *Med Sci Monit*, 2007; 13: CS121–23
- Manchikanti L, Singh V, Cash KA et al: A randomized, controlled, double-blind trial of fluoroscopic caudal epidural injections in the treatment of lumbar disc herniation and radiculitis. *Spine (Phila Pa 1976)*, 2011; 36: 1897–905
- Jasper GP, Francisco GM, Telfeian AE: Endoscopic transforaminal discectomy for an extruded lumbar disc herniation. *Pain Physician*, 2013; 16: E31–35
- Luhmann D, Burkhardt-Hammer T, Borowski C, Raspe H: Minimally invasive surgical procedures for the treatment of lumbar disc herniation. *GMS Health Technol Assess*, 2005; 1: Doc07
- Jasper GP, Francisco GM, Telfeian AE: A retrospective evaluation of the clinical success of transforaminal endoscopic discectomy with foraminotomy in geriatric patients. *Pain Physician*, 2013; 16: 225–29
- Xin G, Shi-Sheng H, Hai-Long Z: Morphometric analysis of the YESS and TESSYS techniques of percutaneous transforaminal endoscopic lumbar discectomy. *Clin Anat*, 2013; 26: 728–34
- Jasper GP, Francisco GM, Aghion D, Telfeian AE: Technical considerations in transforaminal endoscopic discectomy with foraminoplasty for the treatment of spondylolisthesis: Case report. *Clin Neurol Neurosurg*, 2014; 119: 84–87
- Chen ZG, Fu Q: [Percutaneous transforaminal endoscopic discectomy through different approaches for lumbar disc herniation]. *Zhongguo Gu Shang*, 2012; 25: 1057–60 [in Chinese]
- Nellensteijn J, Ostelo R, Bartels R et al: Transforaminal endoscopic surgery for symptomatic lumbar disc herniations: a systematic review of the literature. *Eur Spine J*, 2010; 19: 181–204
- Jasper GP, Francisco GM, Telfeian AE: Clinical success of transforaminal endoscopic discectomy with foraminotomy: a retrospective evaluation. *Clin Neurol Neurosurg*, 2013; 115: 1961–65

Several limitations of our study should be mentioned. TESSYS is not suitable for patients with lumbar spinal stenosis, lumbar instability, or intervertebral space stenosis. TESSYS is highly effective in a narrow set of patients and, therefore, traditional surgical procedures are still very valuable in the clinic. As lifestyles and physical activities change in society, we will need to periodically reassess our options to effectively treat LDH.

Conclusions

In summary, our study provides evidence that both TESSYS and FD are effective in the treatment of LDH, but TESSYS has the advantages of less trauma and faster postoperative recovery. TESSYS caused less damage to local muscle tissues and elicited significantly lower systemic wound response compared to that of open surgery, suggesting that a subset of patients might derive significant benefits from opting for TESSYS.

Acknowledgments

Professor Yoon Ha and Seong Yi who are working in College of Medicine, Yonsei University afforded important clinical advices to the present study.

Competing interests

We acknowledge the reviewers for their helpful comments on this paper. Professor Yoon Ha and Seong Yi who are working in College of Medicine, Yonsei University afforded important clinical advices to the present study

16. Hawker GA, Mian S, Kendzerska T, French M: Measures of adult pain: Visual Analog Scale for Pain (VAS Pain), Numeric Rating Scale for Pain (NRS Pain), McGill Pain Questionnaire (MPQ), Short-Form McGill Pain Questionnaire (SF-MPQ), Chronic Pain Grade Scale (CPGS), Short Form-36 Bodily Pain Scale (SF-36 BPS), and Measure of Intermittent and Constant Osteoarthritis Pain (ICOAP). *Arthritis Care Res (Hoboken)*, 2011; 63(Suppl.11): S240–52
17. Chen HJ, Liang L, Wang JX et al: Lumbar discectomy for lumbar disc herniation. *Orthop Surg*, 2014; 6: 168–69
18. Fukui M, Chiba K, Kawakami M et al: Japanese Orthopaedic Association Back Pain Evaluation Questionnaire. Part 2. Verification of its reliability: The Subcommittee on Low Back Pain and Cervical Myelopathy Evaluation of the Clinical Outcome Committee of the Japanese Orthopaedic Association. *J Orthop Sci*, 2007; 12: 526–32
19. Fairbank JC, Pynsent PB: The Oswestry Disability Index. *Spine (Phila Pa 1976)*, 2000; 25: 2940–52; discussion 2952
20. Lee SH, Choi WG, Lim SR et al: Minimally invasive anterior lumbar interbody fusion followed by percutaneous pedicle screw fixation for isthmus spondylolisthesis. *Spine J*, 2004; 4: 644–49
21. Gibson JN, Cowie JG, Ipreburg M: Transforaminal endoscopic spinal surgery: the future 'gold standard' for discectomy? – A review. *Surgeon*, 2012; 10: 290–96
22. Ahn Y, Lee HY, Lee SH, Lee JH: Dural tears in percutaneous endoscopic lumbar discectomy. *Eur Spine J*, 2011; 20: 58–64
23. Gotfryd A, Avanzi O: A systematic review of randomised clinical trials using posterior discectomy to treat lumbar disc herniations. *Int Orthop*, 2009; 33: 11–17
24. C Reactive Protein Coronary Heart Disease Genetics Collaboration (CCGC), Wensley F, Gao P, Burgess S et al: Association between C reactive protein and coronary heart disease: mendelian randomisation analysis based on individual participant data. *BMJ*. 2011; 342: d548
25. Hall WA, Nickleach DC, Master VA et al: The association between C-reactive protein (CRP) level and biochemical failure-free survival in patients after radiation therapy for nonmetastatic adenocarcinoma of the prostate. *Cancer*, 2013; 119: 3272–79
26. Prins RC, Rademacher BL, Mongoue-Tchokote S et al: C-reactive protein as an adverse prognostic marker for men with castration-resistant prostate cancer (CRPC): confirmatory results. *Urol Oncol*, 2012; 30: 33–37
27. Tsitsimpikou C, Kioukia-Fougia N, Tsarouhas K et al: Administration of tomato juice ameliorates lactate dehydrogenase and creatinine kinase responses to anaerobic training. *Food Chem Toxicol*, 2013; 61: 9–13
28. Leibowitz A, Klin Y, Gruenbaum BF et al: Effects of strong physical exercise on blood glutamate and its metabolite 2-ketoglutarate levels in healthy volunteers. *Acta Neurobiol Exp (Wars)*, 2012; 72: 385–96
29. Alexanderson H, Lundberg IE: Exercise as a therapeutic modality in patients with idiopathic inflammatory myopathies. *Curr Opin Rheumatol*, 2012; 24: 201–7
30. Cirioni O, Weimer LE, Fragola V et al: Sustained increase of serum creatine phosphokinase levels and progressive muscle abnormalities associated with raltegravir use during 32-week follow-up in an HIV-1 experienced patient on simplified HAART regimen, intolerant to protease inhibitors and abacavir: a case report. *West Indian Med J*, 2013; 62: 377–79
31. Mirzaii-Dizgah I, Jafari-Sabet M: Unstimulated whole saliva creatine phosphokinase in acute myocardial infarction. *Oral Dis*, 2011; 17: 597–600
32. Scheller J, Chalaris A, Schmidt-Arras D, Rose-John S: The pro- and anti-inflammatory properties of the cytokine interleukin-6. *Biochim Biophys Acta*, 2011; 1813: 878–88
33. Cortez-Cooper M, Meaders E, Stallings J et al: Soluble TNF and IL-6 receptors: indicators of vascular health in women without cardiovascular disease. *Vasc Med*, 2013; 18: 282–89
34. Liu Y, Ho RC, Mak A: Interleukin (IL)-6, tumour necrosis factor alpha (TNF-alpha) and soluble interleukin-2 receptors (sIL-2R) are elevated in patients with major depressive disorder: a meta-analysis and meta-regression. *J Affect Disord*, 2012; 139: 230–39
35. Neurath MF, Finotto S: IL-6 signaling in autoimmunity, chronic inflammation and inflammation-associated cancer. *Cytokine Growth Factor Rev*, 2011; 22: 83–89
36. McGregor CG, Sodergren MH, Aslanyan A et al: Evaluating systemic stress response in single port vs. multi-port laparoscopic cholecystectomy. *J Gastrointest Surg*, 2011; 15: 614–22
37. Pan L, Zhang P, Yin Q: Comparison of tissue damages caused by endoscopic lumbar discectomy and traditional lumbar discectomy: a randomised controlled trial. *Int J Surg*, 2014; 12: 534–37