



## Case report

## Soft tissue reconstruction on the very late presenting neglected acromioclavicular dislocation Rockwood type IV. A case report

Renaldi Prasetya<sup>a,\*</sup>, Hans Kristian<sup>b</sup>, Agus Hadian Rahim<sup>a</sup>, Yoyos Dias Ismiarto<sup>a</sup>, Hermawan Nagar Rasyid<sup>a</sup><sup>a</sup> Department of Orthopaedics and Traumatology, Faculty of Medicine, Universitas Padjadjaran, Bandung, West Java, Indonesia<sup>b</sup> General Practitioner, Faculty of Medicine, Maranatha Christian University, Bandung, West Java, Indonesia

## ARTICLE INFO

## Keywords:

Acromioclavicular joint  
 Acromioclavicular dislocation  
 Rockwood type IV  
 Soft tissue reconstruction  
 AC and CC reconstruction  
 Case report

## ABSTRACT

**Introduction and importance:** Acromioclavicular (AC) joint dislocation Rockwood type IV is a rare condition characterized by the posterior displacement of the distal clavicle and soft tissue damage. The rate of soft tissue healing markedly decreases as time from injury increases. In this case report, we had a very late presenting neglected AC joint dislocation Rockwood type IV successfully treated by AC and coracoclavicular (CC) reconstruction.

**Case presentation:** A 24-year-old female presented with pain around her right shoulder since a motorcycle accident four years prior to current presentation. She was diagnosed with a posterior AC joint dislocation and suggested undergoing surgery, but she refused and chose to seek an alternative treatment. The patient felt pain chronically and could not elevate her shoulder, and she decided to come to our hospital. We performed a physical and radiograph examination that showed an AC joint dislocation Rockwood type IV. The management, suggested to the patient, was AC and CC soft tissue reconstruction.

**Clinical discussion:** The advantages of using this procedure were to restore effective anatomy and avoid bone-to-bone contact between the clavicle and acromion. The disadvantages were increased cost and needed to be evaluated for long-term results. We considered the idea of maintaining AC joint reduction by biologic soft tissue healing of the graft and augmentation fixation to replace the CC ligaments. We could not rely on biological soft tissues healing themselves due to the chronicity.

**Conclusion:** AC and CC reconstruction can be an option of treatment in neglected AC joint dislocation Rockwood type IV with excellent clinical and radiographic results.

## 1. Introduction

Acromioclavicular joint dislocation Rockwood type IV is rare and characterized by the posterior displacement of the distal clavicle with extreme deformity [1–4]. The incidence of acromioclavicular joint dislocation is only 1.8–2 cases per 10,000 inhabitants per year and 5–8.5 times more common in men than in women [5–8]. It is usually caused by direct trauma. It most likely occurs from direct force applied to the lateral end of the clavicle as in fall onto the anterolateral aspect of the shoulder [1,2]. These injuries can result in dislocation or disruption of the acromioclavicular (AC) joint and complete tears of the AC and coracoclavicular (CC) ligament. In particular, Rockwood type IV injuries result from a complete disruption of the periosteal tube with the posterior and superior translation of the metaphysis [1].

The definition of neglected dislocation is not getting treatment at all or getting treatment that is not appropriate by nonmedical personnel. It can be more severe deformity or extreme displacement and soft tissue damage. AC and CC ligaments healing markedly decrease as time from injury increases [9]. Therefore, neglected AC joint dislocation is challenging to treat [10].

Neglected AC joint dislocation Rockwood type IV will interfere with daily activity. Therefore, comprehensive treatment is needed. It should be considered for operative treatment due to deformity and severe soft tissue damage [1,6]. It included open techniques until the most recent arthroscopic advances for soft tissue reconstruction [10]. AC and CC reconstruction procedures are one of the options and have been shown to have good clinical and radiographic outcomes [11]. In our case, we presented neglected AC joint dislocation Rockwood type IV very late,

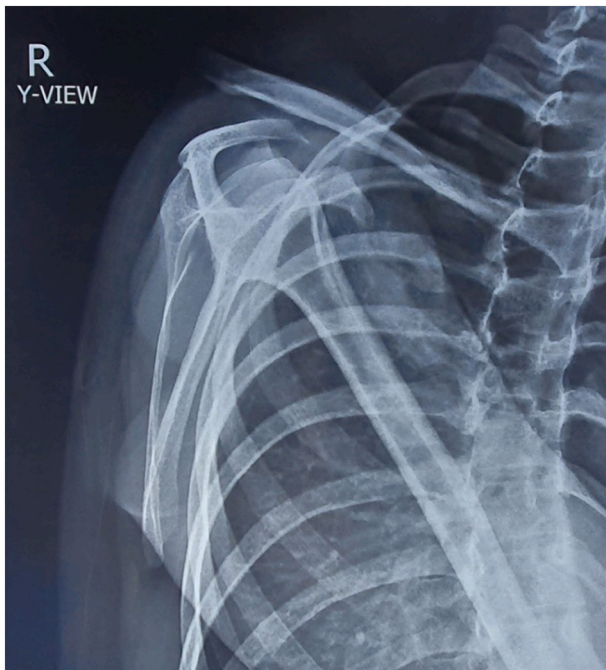\* Corresponding author.

E-mail address: [renaldi@unpad.ac.id](mailto:renaldi@unpad.ac.id) (R. Prasetya).<https://doi.org/10.1016/j.ijscr.2022.107171>

Received 1 April 2022; Received in revised form 2 May 2022; Accepted 3 May 2022

Available online 6 May 2022

2210-2612/© 2022 The Authors. Published by Elsevier Ltd on behalf of IJS Publishing Group Ltd. This is an open access article under the CC BY-NC-ND license (<http://creativecommons.org/licenses/by-nc-nd/4.0/>).



**Fig. 1.** Preoperative initial radiograph of the patient showed a disruption of AC joint with posterior dislocation of the clavicle.

which was successfully treated by AC and CC reconstruction procedures. Written informed consent was obtained from the patient for publishing this paper. This case report has been reported in line with the SCARE 2020 criteria [12].

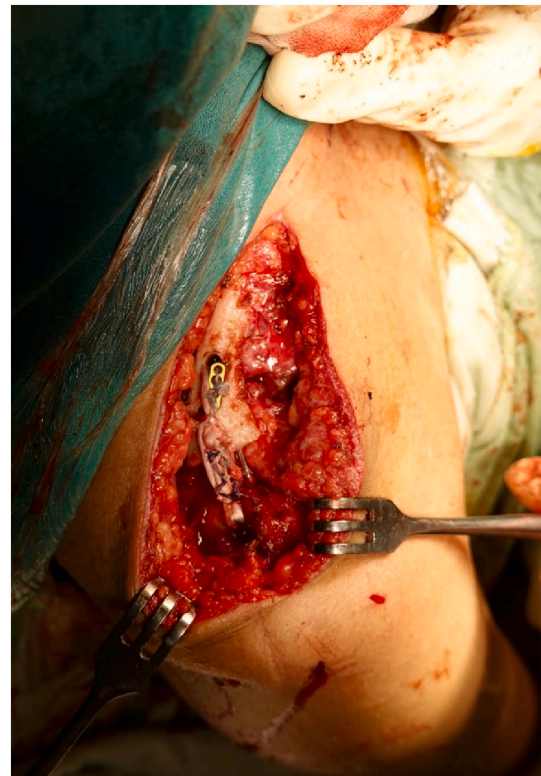
## 2. Case presentation

A 24-year-old female presented to the hospital outpatient department with pain around her right shoulder spread to her back and right neck. It is accompanied by a lump behind the upper right shoulder. Four years before admission, she had a motorcycle accident with her body weight resting on the right shoulder. She was taken to the hospital after the accident, and the doctor had diagnosed her with a posterior AC joint dislocation. The doctor had suggested undergoing surgery, but she refused and chose to seek an alternative treatment. After four years, the patient felt pain chronically and could not elevate her shoulder, and she decided to come to our hospital for surgery.

On examination, there was a marked deformity on the right back. The right shoulder range of motion was limited due to pain and resistance. The neurovascular examination was normal. Radiograph examination (scapular Y view) showed a disruption of the AC joint with the posterior clavicle dislocation (Fig. 1). The patient was diagnosed with neglected AC joint dislocation Rockwood type IV and was advised to receive further treatment with AC and CC reconstruction procedures followed by physical therapy.

### 2.1. Surgical technique

The guarantor author did the surgical procedure. The beach chair was used for AC and CC reconstruction surgery to ensure optimal reduction. The ipsilateral knee was prepared for hamstring autograft harvest, and a tourniquet was placed on the proximal thigh. A skin incision was created over the pes anserine, and the soft tissue was dissected to the level of the sartorius fascia. Performed a reverse L-fashioned release subperiosteally. The gracilis and semitendinosus tendons were visualized and bluntly dissected. The tendons and graft were released from distal muscle-tendon junctions using a tendon stripper. Pre-tensioning was applied on a traction device with clamps. The



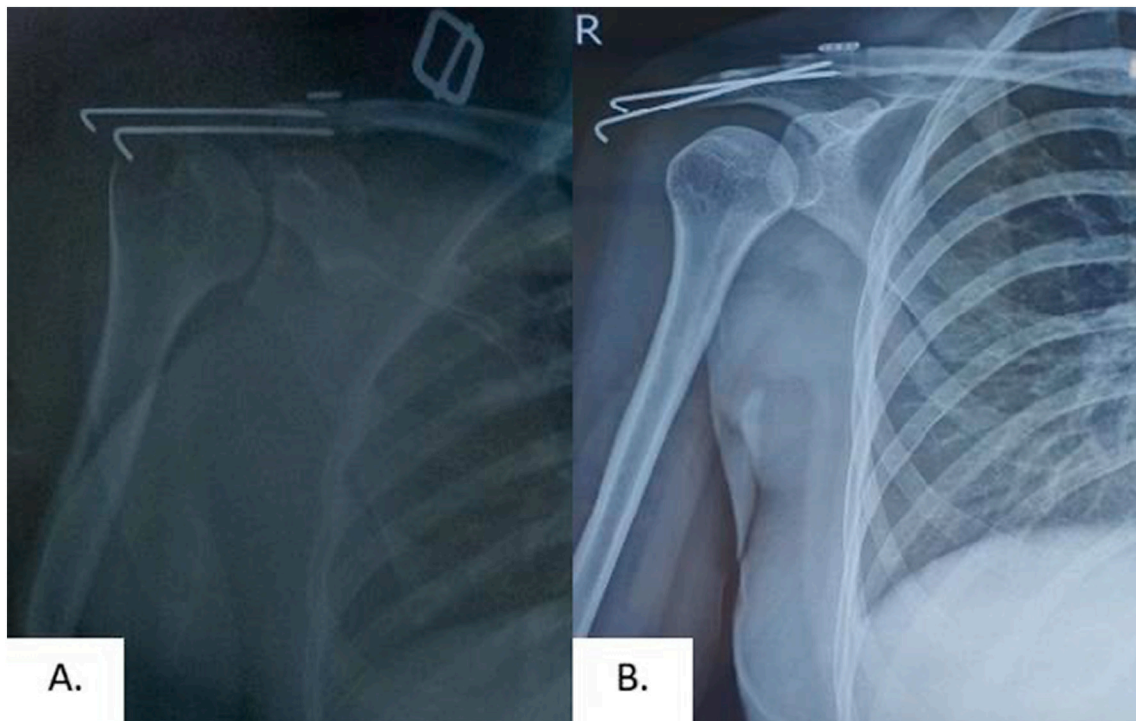
**Fig. 2.** The graft was stitched upon itself using a UHMWPE suture, after both graft end limbs were tied to create a square knot.

proximal ends of the graft were whip-stitched with no. 2 polyester suture (Ethibond, Ethicon Inc., Somerville, NJ, USA). The length and diameter for both grafts were approximately 240–290 mm and 4,5–5,5 mm.

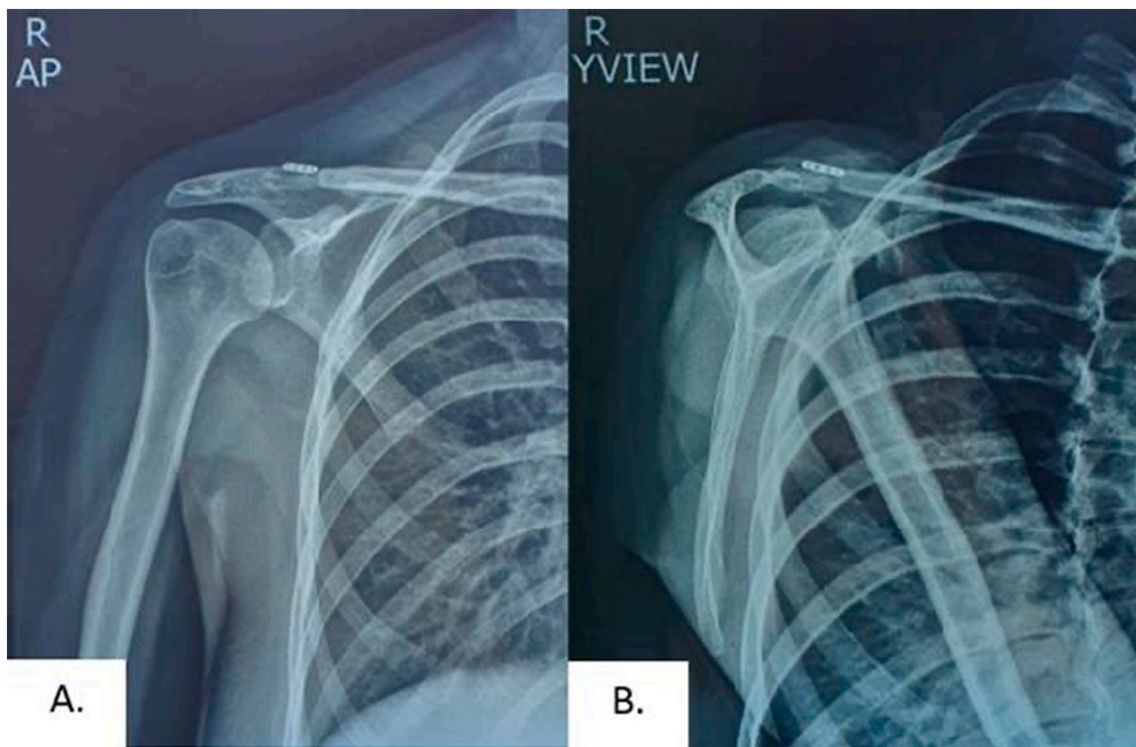
For the AC and CC joint management, an incision was made approximately 4–5 cm on the superior surface of the clavicle closer to its anterior border extending laterally 1 cm beyond the AC joint and completed the exposure of the clavicle, AC, and CC joint from any soft tissues that are preventing reduction. Soft tissue is cleaned from the clavicle's anterior, lateral, and posterior borders for better mobilization of the clavicle to help in graft passage and AC joint reduction. Made a distal resection of the lateral 5 mm of the clavicle. A trial reduction was performed by pushing up on the elbow to elevate the scapulohumeral complex and pushing down the clavicle using a blunt and wide-ended device like a tunnel dilator positioned medial to the lateral end holes. After successful AC joint reduction, temporary fixation was performed using a Kirschner (K) wire.

Prepared the graft sling passage. The undersurface of the coracoid process was exposed, and a roughened surface was created. The no. 5 polyester suture (Ethibond, Ethicon Inc., Somerville, NJ, USA) was passed under the coracoid process from the medial side close to the bone. At the same time, the graft was looped around the base of the coracoid process. Thus, the suture loop is placed under the coracoid process. Then, the semitendinosus-gracilis autograft was pulled under the coracoid process. For the graft passage fixation using a no. 2 polydioxanone (PDS) suture as shuttle relay, the graft is crossed, and the medial end was pulled through the lateral tunnel and vice versa. The length of the graft, passing the most lateral tunnel (trapezoid tunnel).

An ultra-high-molecular-weight polyethylene suture (Ultrabraid no. 5, Andover, MA, USA) and Endobutton (Changzhou Kanghui Medical Innovation Co., Ltd) were used to provide fixation augmentation and to avoid tissue cut-through. The Endobutton should be firmly positioned on the clavicle using forceps during knot-tying to maintain reduction. The graft was stitched upon itself using a UHMWPE suture, after both graft end limbs were tied to create a square knot (Fig. 2). Good closure was



**Fig. 3.** Postoperative radiograph of the patient showed well correction of AC joint dislocation: A) 1-day postoperative follow-up; B) 1-month postoperative follow-up.

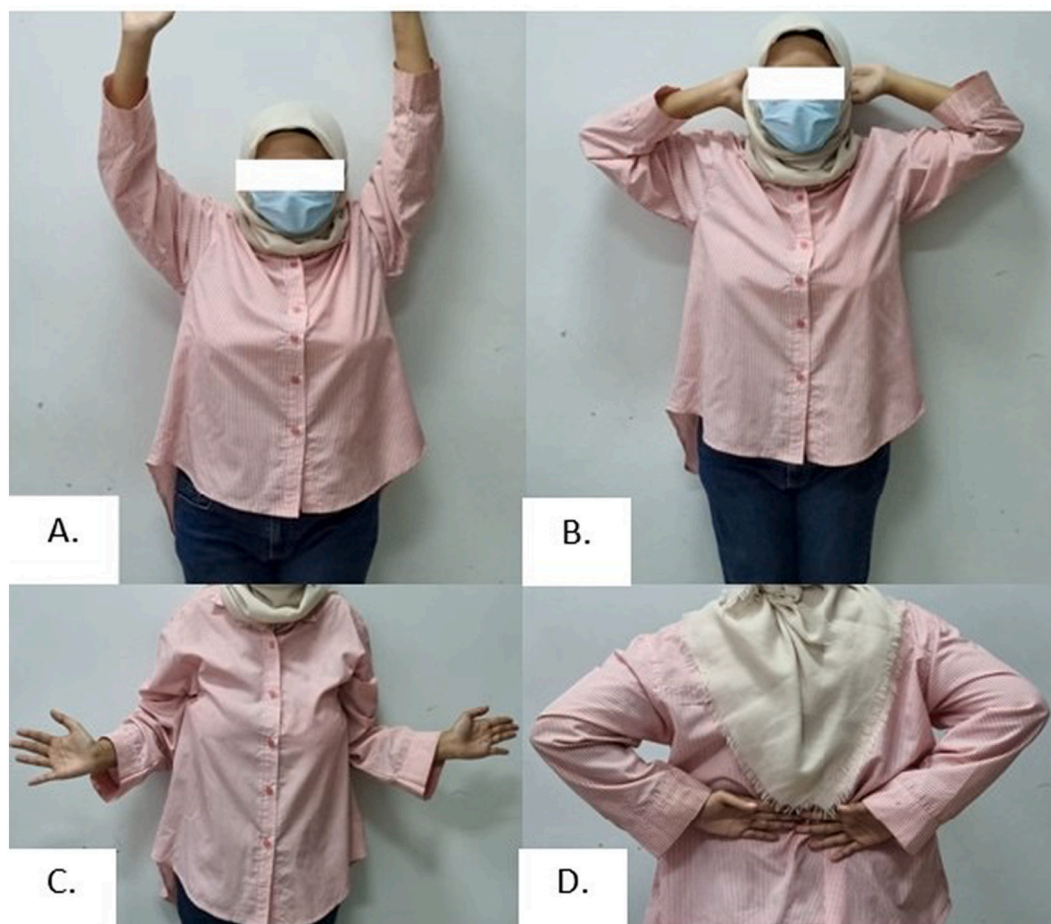

**Fig. 4.** A 6-month postoperative radiograph showed intact fixation: A) AP view; B) scapular Y view.

done for the deltatrapezial fascia to achieve additional stability. These procedures reconstruct the AC and CC ligaments and provide AC joint reduction.

### 2.2. Outcome and follow-up

On 1-day postoperative follow-up, the patient was pain-free, and the radiograph showed an AC and CC correction and fixation (Fig. 3A). On 1-month postoperative follow-up (Fig. 3B). On a 6-month follow-up, the patient had showed intact fixation in radiograph (Fig. 4) and regained



**Fig. 5.** The clinical picture of the patient's shoulder ROM: A) forward flexion; B) external rotation in the abduction; C) external rotation in adduction; D) internal rotation; a 6-month postoperative follow-up showed regained normal ROM.

functional ROM (Fig. 5). There are no complications that have been observed. This work has been reported in line with the SCARE 2020 criteria [12].

### 3. Discussion

After surgical reconstruction, AC joint dislocation recurrence rates range between 20% and 30% or even higher [13]. There are several techniques or methods for AC joint dislocation, and an optimal treatment was still debated. Until now, none of the techniques have been confirmed as the gold standard [11]. Nonetheless, with neglected AC joint dislocation for four years, achieving rigid fixation becomes a challenge.

As reported by Weinstein et al., chronic AC and CC injuries have poorer results in healing because the biological capabilities are compromised. Therefore, mechanical stabilization alone without biological augmentation may be insufficient. AC and CC ligaments are the primary static AC joint stabilizers. They lose the potential to heal more than three weeks after injury [9]. Disruption of these ligaments can cause vertical and horizontal instability. The key to AC joint reconstruction's surgical and functional outcome success is an effective anatomic restoration [14].

To achieve rigid anatomic restoration, it may be necessary to provide mechanical stability or biological support depending on the severity of the dislocation. Mazzocca et al. described reconstructing the CC (conoid and trapezoid) ligaments using a free tendon graft, resulting in a construct that displayed almost equal time zero biomechanical conditions compared with the native joint. Naziri et al. reported that the

added fixation material provided by a UHMWPE suture augmented tendon graft for both AC and CC ligament reconstruction increased time zero load to failure strength by 356% [15].

We decided to do AC and CC reconstruction using a temporary K-wire, an autologous tendon graft (gracilis and semitendinosus tendons) with a UHMWPE suture augmentation, and Endobutton. These act as a cortical augmentation to provide adequate stability, maintain reduction, and avoid fracture or tissue cut-through at the clavicle by increasing the surface area of pressure distribution [16]. Lee et al. reported a comparative biomechanical study. Only the semitendinosus tendon survived two loading cycles and concluded that it could be clinically used as a strong and stable biologic option [17]. The advantages of these procedures were restoring effective alignment between the clavicle and acromion, reconstructing the AC and CC ligament, and avoid bone-to-bone contact between the clavicle and acromion [11,16]. The disadvantages were increased cost and needed to be evaluated for long-term results [16].

Given these chronic circumstances, we considered maintaining AC joint reduction by biologic soft tissue healing of the graft and augmentation fixation to replace the coracoclavicular ligaments. We cannot rely on biological soft tissues healing themselves due to chronicity.

### 4. Conclusion

AC and CC reconstruction can be an option of treatment in neglected AC joint dislocation Rockwood type IV that can restore effective anatomy and avoid bone-to-bone contact, with excellent clinical and radiographic results.

### Sources of funding

The study was supported by an Academic Leadership Grant Universitas Padjadjaran no 1959/UN6.3.1/PT.00/2021.

### Ethical approval

The patient received an explanation of the procedures and possible risks of surgery and gave written informed consent. Ethical approval has been granted in this study. The privacy and personal identity information of all participants were protected in accordance with the Declaration of Helsinki.

### Consent

The patient received an explanation of the procedures and possible risks of the surgery and gave written informed consent. My manuscript does not contain any individual person data. Written informed consent was obtained from the patient for publication of this case report and accompanying images. A copy of the written consent is available for review by the Editor-in-Chief of this journal on request.

### Author contribution

Renaldi Prasetya: Surgeon, Conceptualization, Visualization, Methodology, Writing and Supervision.

Hans Kristian: Writing.

Agus Hadian Rahim: Surgeon and Writing.

Yoyos Dias Ismiarto: Surgeon and Writing.

Hermawan Nagar Rasyid Surgeon, Conceptualization, Writing and Supervision.

### Research registration

1. Name of the registry: Research Registry.
2. Unique identifying number or registration ID: researchreg-istry6130.
3. Hyperlink to your specific registration (must be publicly accessible and will be checked): <https://www.researchregistry.com/browse-theregistry#home/registrationdetails/5f8c00dea40aed00178160b9/>.

### Guarantor

The guarantor in this study is Renaldi Prasetya.

### Provenance and peer review

Not commissioned, externally peer-reviewed.

### Declaration of competing interest

The authors declare that there is no conflict of interest regarding the

publication of this paper.

### Acknowledgments

The study underwent grammar correction by Enago.

### References

- [1] C.A. Rockwood, M.A. Wirth, E.V. Fehring, Rockwood and Matsen's the shoulder E-book, in: Elsevier Health Sciences, 2016.
- [2] T.F. Wisniewski, Posterior acromioclavicular dislocation with clavicular fracture and trapezius entrapment: case study and literature review, *Eur. J. Trauma* 30 (2004) 120–123.
- [3] S. Lee, U. Jeong, K. Park, Neglected type IV acromioclavicular joint injury, *J. Korean Shoulder Elbow Soc.* 11 (2008) 185–188.
- [4] P. Sondergard-Petersen, P. Mikkelsen, Posterior acromioclavicular dislocation, *J. Bone Joint Surg. Ser. B* 64 (1982) 52–53.
- [5] C. Chillemi, V. Franceschini, L. Dei Giudici, A. Alibardi, F. Salate Santone, L. J. Ramos Alday, et al., Epidemiology of isolated acromioclavicular joint dislocation, *Emerg. Med. Int.* 2013 (2013) 1–5.
- [6] P.C. Nolte, L. Lacheta, T.J. Dekker, B.P. Elrick, P.J. Millett, Optimal management of acromioclavicular dislocation: current perspectives, *Orthop. Res. Rev.* 12 (2020) 27–44.
- [7] A.D. Mazzocca, R.A. Arciero, J. Bicos, Evaluation and treatment of acromioclavicular joint injuries, *Am. J. Sports Med.* 35 (2007) 316–329.
- [8] J.S. Nordin, O. Olsson, K. Lunsjö, Acromioclavicular joint dislocations: incidence, injury profile, and patient characteristics from a prospective case series, *JSES Int.* 4 (2020) 246–250.
- [9] D.M. Weinstein, P.D. Mccann, S.J. McIlveen, E.L. Flatow, L.U. Bigliani, Surgical treatment of complete acromioclavicular dislocations, *Am. J. Sports Med.* 23 (1995) 324–331.
- [10] J.A. Cano-Martínez, G. Nicolás-Serrano, J. Bento-Gerard, F.P. Marín, J.A. Grau, M. L. Antón, Chronic acromioclavicular dislocations: multidirectional stabilization without grafting, *JSES Int.* 4 (2020) 519–531.
- [11] B. Chernchujit, R. Prasetya, The arthroscopy-assisted anatomical reconstruction of acromioclavicular and coracoclavicular ligament in chronic acromioclavicular joint dislocation, *Intraarticular Fract.* (2019) 87–96.
- [12] R.A. Agha, T. Franchi, C. Sohrabi, G. Mathew, A. Kerwan, A. Thoma, et al., The SCARE 2020 guideline: updating consensus Surgical CAse REport (SCARE) guidelines, *Int. J. Surg.* 84 (2020) 226–230.
- [13] M. Scheibel, A. Ifesanya, S. Pauly, N.P. Haas, Arthroscopically assisted coracoclavicular ligament reconstruction for chronic acromioclavicular joint instability, *Arch. Orthop. Trauma Surg.* 128 (2008) 1327–1333.
- [14] D. Banaszek, M. Pickell, E. Wilson, M. Ducsharm, D. Hesse, R. Easteal, et al., Anatomical evaluation of the proximity of neurovascular structures during arthroscopically assisted acromioclavicular joint reconstruction: a cadaveric pilot study, *Arthrosc. J. Arthrosc. Relat. Surg.* 33 (2017) 75–81, <https://doi.org/10.1016/j.arthro.2016.05.041> [Internet]. Available from.
- [15] Q. Naziri, N. Williams, W. Hayes, B.H. Kapadia, D. Chatterjee, W.P. Urban, Acromioclavicular joint reconstruction using a tendon graft: a biomechanical study comparing a novel “sutured throughout” tendon graft to a standard tendon graft, *Sicot-J.* 2 (2016).
- [16] B. Chernchujit, P. Parate, Surgical technique for arthroscopy-assisted anatomical reconstruction of acromioclavicular and coracoclavicular ligaments using autologous hamstring graft in chronic acromioclavicular joint dislocations, *Arthrosc. Tech.* 6 (2017) e641–e648, <https://doi.org/10.1016/j.eats.2017.01.009> [Internet]. Available from.
- [17] S.J. Lee, E.P. Keefer, M.P. McHugh, I.J. Kremenec, K.F. Orishimo, S. Ben-Avi, et al., Cyclical loading of coracoclavicular ligament reconstructions: a comparative biomechanical study, *Am. J. Sports Med.* 36 (2008) 1990–1997.