

Available online at www.sciencedirect.com

ScienceDirect

journal homepage: www.elsevier.com/locate/ihj

Case Report

Pacemaker lead Candida endocarditis: Is medical treatment possible?



Syamasis Bandyopadhyay^a, P.K. Tiwary^a, Susobhan Mondal^a,
Shilpa Puthran^{b,*}

^a Apollo Gleneagles Hospital, Kolkata, India

^b MSD Pharmaceuticals Private Ltd, Mumbai, India

ARTICLE INFO

Article history:

Received 7 December 2013

Accepted 16 November 2015

Available online 23 December 2015

Keywords:

Pacemaker lead

Candida

Endocarditis

Caspofungin

Echinocandins

1. Introduction

Fungal pacemaker lead endocarditis is a fatal disease. Here we present a case where an early diagnosis by blood culture and transesophageal echocardiography resulted in a successful outcome with antifungal therapy, without surgical explantation.

2. Case report

An eighty-six-year old immunocompetent diabetic male with permanent pacing for 3 years was admitted with generalized weakness and fever for one week. Baseline investigations revealed total leukocyte count of 10,000 (70% neutrophils) and raised CRP. Blood culture grew *Candida tropicalis* sensitive to

flucytosine, amphotericin B, fluconazole, voriconazole, and caspofungin. Transthoracic echocardiography showed multiple large masses on the pacemaker electrode in the right atrium and ventricle, which were highly suggestive of vegetation. A subsequent transesophageal echocardiography confirmed these findings (Fig. 1). In view of advanced age and high risk of surgical mortality associated with explantation of pacemaker lead, both the patient and his family refused surgery and opted for aggressive antifungal therapy instead. The patient was treated with intravenous caspofungin 70 mg on Day 1 and 50 mg daily for 10 days followed by intravenous fluconazole for 15 days. He was subsequently put on oral fluconazole (200 mg b.i.d) for two months. A repeat transesophageal echocardiography during a follow-up visit, two months post-discharge, showed no intracardiac mass (Fig. 2) and the patient remained asymptomatic.

* Corresponding author.

E-mail address: shilpaputhran41@gmail.com (S. Puthran).

<http://dx.doi.org/10.1016/j.ihj.2015.11.025>

0019-4832/© 2015 Cardiological Society of India. Published by Elsevier B.V. All rights reserved.

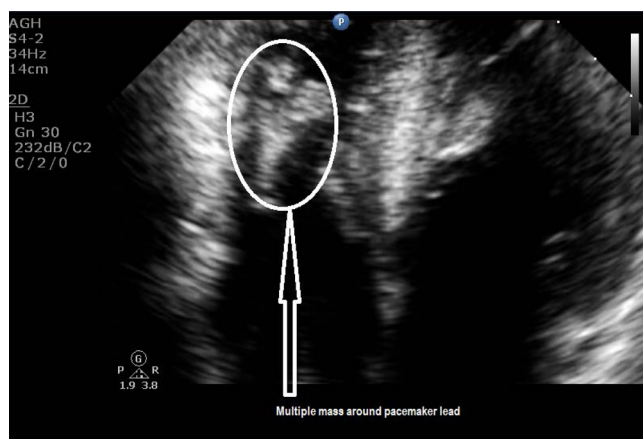


Fig. 1 – Echocardiography showing multiple mass around pacemaker lead.

3. Discussion

The overall incidence of associated infections post pacemaker surgeries has been quoted as 0–12.6%,^{1,2} with rates ranging from 0.13% to 19.9% for permanent pacemakers (PPMs) and 0.2% to 7.2% for implantable cardioverter-defibrillators (ICDs).³ Cardiac rhythm management device (CRMD) related endocarditis accounted for 10% of such infections.^{2,3} Fungal infections, though rare, are found documented in random case reports and *Candida* species were found to be the major pathogens in such cases.³

Excluding our current case, a literature search in the PubMed database elicited eighteen published cases of *Candida* endocarditis with indwelling PPMs and ICDs. Fifteen of these cases were summarized in a review by Ahmad Halawa et al.,³ covering publications from 1969 to 2009. The sixteenth case was published in 2013 by Tascini et al.,² and Rivera et al. reported the eighteenth case in 2014.¹⁴ Our review did not include cases of prosthetic valve fungal endocarditis without CRMDs.

An overview of the sixteen cases has been summarized in this report mainly from the findings of Halawa et al.³ and Tascini et al.² There were fifteen males between 38 and 87 years and one

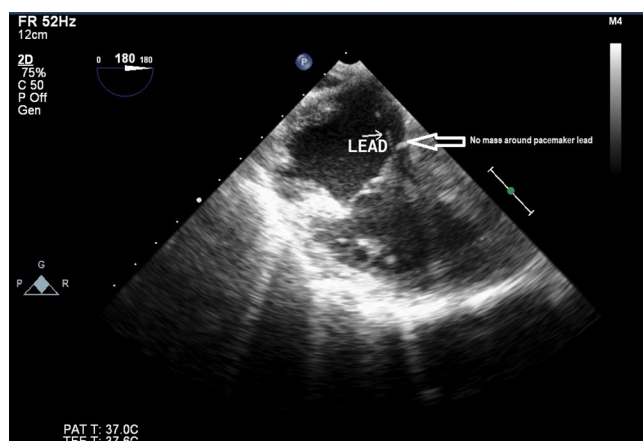


Fig. 2 – Echocardiography showing complete resolution of mass around pacemaker lead.

female aged 75 years. Lead vegetations were detected by echocardiography in fifteen patients and during autopsy in one. There was equal prevalence of *Candida albicans* and non-*albicans* pathogens (8 patients each). Amongst the non-*albicans*, *C. parapsilosis* was isolated in four cases (25%), *C. tropicalis* in two cases (12.5%), and *C. glabrata* in two cases (12.5%). Mixed infections were present in two patients (12.5%), one with *C. albicans* and *C. glabrata* and the other with *C. albicans* and *S. epidermidis*. Thirteen of the sixteen cases received specific antifungal treatment with amphotericin B, fluconazole, 5-flucytosine, and echinocandins either alone or in combinations. Four patients were treated with only amphotericin B. Three patients were treated with only fluconazole. Two patients received a combination of amphotericin B with fluconazole and two others a combination of amphotericin B, 5-flucytosine and fluconazole. In the two patients treated with echinocandins, one received caspofungin followed by fluconazole and posaconazole, whereas the other was initially treated with fluconazole followed by micafungin. Three of the sixteen patients had no documentation of being treated with antifungals, as therapy was undefined for two patients and one received only antibiotics. Survival rate in these sixteen cases was 50% with eight patients surviving. However, it should be noted that the cause of death in two cases was postsurgical complications and bacteremia and not primarily fungal endocarditis. In contrast to our current case, it is interesting to note that none of the above sixteen cases were treated solely by medical management for *Candida* endocarditis. Surgical device explantation was performed in thirteen cases; one patient refused surgery who later died of multiorgan failure, one patient was considered medically unfit for surgery who subsequently died of a fatal stroke, and one died due to congestive heart failure prior to any planned intervention.^{2,3}

The more recent eighteenth published case in 2014 by Rivera et al.¹⁴ was of a 60-year-old female with an ICD and a blood culture positive for *C. albicans*. The patient underwent device removal and was managed with micafungin for 2 weeks followed by fluconazole for 6 weeks.¹⁴

Our search also revealed five cases of noncandidial fungal pacemaker endocarditis. Four were females between 30 and 80 years and one was a male aged 65 years. Four were cases of *Aspergillus* infections and one was infected with *Petriellidium boydii*. Amongst the *Aspergillus* infections, speciation was documented in only two cases, one each with *Aspergillus fumigatus* and *Aspergillus flavus*, respectively. Other than the lone case of *A. fumigatus*, which was treated with amphotericin B, none of the other four patients received antifungals. Device explantation was performed in two cases, one of which was the case diagnosed with *A. fumigatus* infection. Death occurred in all cases except the lone case of *A. fumigatus*, which was treated with amphotericin B.⁴⁻⁸

Additionally, we also found another case reported in 1977 of a 70-year old female with pacemaker who underwent device explantation for infection and subsequently expired due to pulmonary embolism. The patient was neither diagnosed nor treated for fungal infections. Postmortem analysis of the pacemaker thrombus revealed fungi. However, there was no documentation of either the genus or species of fungus.^{6,9}

Diagnosis of fungal endocarditis is difficult due to low positivity rates of blood cultures.^{4,10} Speciation should be

considered routinely in culture positive cases due to high prevalence of non-albicans. Decisions to investigate further and treat should be based on a high index of suspicion in the presence of indwelling cardiac devices, unexplained fever, increasing age, and associated clinical risk factors even in culture negative cases. Some of the risk factors often cited are immunosuppression, diabetes mellitus, use of oral anticoagulants, indwelling cardiac device manipulation, lack of perioperative antimicrobial prophylaxis, and *Staphylococcus aureus* bacteremia.^{2,4,6,10,11} Transthoracic and transesophageal echocardiography are also important diagnostic tools, which should be used more effectively in routine clinical settings for picking up presence of suspect vegetations on implanted devices.

The IDSA 2009 guidelines for management of *Candida* endocarditis recommend LFAmB 3–5 mg/kg, with or without 5-FC 25 mg/kg qid, or AmB-d 0.6–1 mg/kg daily, with or without 5-FC 25 mg/kg qid, or an echinocandin followed by a step-down therapy to fluconazole 400–800 mg daily in stable patients with negative blood culture. However, the guidelines strongly recommend surgical removal of the infected device along with a daily dose of fluconazole 400–800 mg for long-term suppression.¹²

The ESCMID 2012 guidelines also recommend surgical explantation of infected devices along with liposomal amphotericin B or caspofungin, either singly or in combination with flucytosine followed by a suppression therapy with fluconazole. In cases where surgery was contraindicated due to presence of comorbidities, caspofungin and liposomal amphotericin B were used successfully with or without subsequent life-long suppressive therapy with fluconazole.¹³

A recent scientific statement by the American Heart Association (AHA) published in 2015 recommends complete device and lead removal for all patients with cardiovascular implantable electronic device (CIED) infection followed by at least 14 days of appropriate antimicrobial therapy after CIED removal for bloodstream infection. It also advocates considering long-term suppressive therapy for patients who have CIED infection and are not candidates for complete device removal. This is in reference to those who have a limited life expectancy or have refused device removal, as was the case with our patient.¹⁵

A limitation of this case report is that the patient was lost to follow-up 3 months post-discharge due to which long-term implications on leaving the device in situ cannot be commented upon. However, the last echocardiogram and routine laboratory investigations did not depict presence of any obvious infection during the follow-up period.

4. Conclusion

Cases of fungal pacemaker endocarditis are on the rise due to increasing usage of in vivo cardiac devices and can no longer be considered a rare occurrence. Though surgical removal of the infected device combined with medical management still remains the mainstay of treatment, a high index of clinical suspicion based on presence of risk factors, prompt diagnosis by microscopy, and echocardiography along with early initiation of antifungal agents can result in complete resolution and

decreased mortality by medical management alone, especially in those patients who have a limited life expectancy or have refused device removal. However, periodic long-term follow-up of such patients for evaluation of CIED infections becomes imperative.

Conflicts of interest

The authors have none to declare.

REFERENCES

- Choo MH, Holmes Jr DR, Gersh BJ, et al. Permanent pacemaker infections: characterization and management. *Am J Cardiol.* 1981;48:559–564.
- Tascini C, Grazia Bongiorni M, Tagliaferri E, et al. Micafungin for *Candida albicans* pacemaker-associated endocarditis: a case report and review of the literature. *Mycopathologia.* 2013;175:129–134.
- Halawa A, Henry PD, Sarubbi FA. *Candida* endocarditis associated with cardiac rhythm management devices: review with current treatment guidelines. *Mycoses.* 2010;54:e168–e174.
- Gilhotra Harpreet S, Mahant TS, Bagai Maneesh K. Late lead fungal endocarditis of automatic implantable cardioverter defibrillator. *Indian Heart J.* 2011;63:287–288.
- Kothari A, Pillai BS, Bhan A. Pacing lead endocarditis due to *Aspergillus fumigatus*. *Indian J Med Microbiol.* 2010;28:72–73.
- Moorman JR, Steenbergen C, Durack DT, et al. *Aspergillus* infection of a permanent ventricular pacing lead. *Pacing Clin Electrophysiol.* 1984;7:361–366.
- Kramer L, Rojas-Corana RR, Sheff D, et al. Disseminated aspergillosis and pacemaker endocarditis. *Pacing Clin Electrophysiol.* 1985;8:225–229.
- Davis WA, Isner JM, Bracey AW, et al. Disseminated *Pettriellidium boydii* and pacemaker endocarditis. *Am J Med.* 1980;69:929–932.
- Klugmann S, Silvestri F, Giarelli F, et al. Thrombosi micotica intracardiaca in corso di stimolazione endocardica permanente. *G Ital Cardiol.* 1997;7:625.
- Davis JM, Moss AJ, Schenk EA, et al. Tricuspid *Candida* endocarditis complicating a permanently implanted transvenous pacemaker. *Am Heart J.* 1969;77:818–821.
- Kurup A, Naik Janardhan M, Yong Seng T. *Candida tropicalis* pacemaker endocarditis. *J Infect.* 2000;41:275–276.
- Pappas PG, Kauffman CA, Andes D, et al. Clinical practice guidelines for the management of candidiasis: 2009 update by the Infectious Diseases Society of America. *Clin Infect Dis.* 2009;48:503–535.
- Cornely OA, Bassetti M, Calandra T, et al. ESCMID guideline for the diagnosis and management of *Candida* diseases 2012: non-neutropenic adult patients. *Clin Microbiol Infect.* 2012;18:19–37.
- Rivera NT, Bray N, Wang H, et al. Rare infection of implantable cardioverter-defibrillator lead with *Candida albicans*: case report and literature review. *Ther Adv Cardiovasc Dis.* 2014;8:193–201.
- Baddour LM, Epstein AE, Erickson CC, et al. Update on cardiovascular implantable electronic device infections and their management. A scientific statement from the American Heart Association. Endorsed by the Heart Rhythm Society. *Circulation.* 2010;121:458–477.