

Case Report

Beta Lactamase Producing *Clostridium perfringens* Bacteremia in an Elderly Man with Acute Pancreatitis

Rashmi Mishra,¹ Nupur Sinha,² and Richard Duncalf¹

¹Division of Pulmonary and Critical Care Medicine, Bronx Lebanon Hospital Center, 1650 Grand Concourse, Bronx, NY 10457, USA

²Division of Pulmonary and Critical Care, Community Hospital of the Monterey Peninsula, 23625 Pacific Grove-Carmel Highway, Monterey, CA 93942, USA

Correspondence should be addressed to Rashmi Mishra; rashmi_mishra1987@yahoo.com

Received 12 November 2015; Accepted 4 January 2016

Academic Editor: Zsolt Molnar

Copyright © 2016 Rashmi Mishra et al. This is an open access article distributed under the Creative Commons Attribution License, which permits unrestricted use, distribution, and reproduction in any medium, provided the original work is properly cited.

Clostridium perfringens bacteremia is associated with adverse outcomes. Known risk factors include chronic kidney disease, malignancy, diabetes mellitus, and gastrointestinal disease. We present a 74-year-old man admitted with confusion, vomiting, and abdominal pain. Exam revealed tachycardia, hypotension, lethargy, distended abdomen, and cold extremities. He required intubation and aggressive resuscitation for septic shock. Laboratory data showed leukocytosis, metabolic acidosis, acute kidney injury, and elevated lipase. CT scan of abdomen revealed acute pancreatitis and small bowel ileus. He was started on vancomycin and piperacillin-tazobactam. Initial blood cultures were positive for *C. perfringens* on day five. Metronidazole and clindamycin were added to the regimen. Repeat CT (day 7) revealed pancreatic necrosis. The patient developed profound circulatory shock requiring multiple vasopressors, renal failure requiring dialysis, and bacteremia with vancomycin-resistant enterococci. Hemodynamic instability precluded surgical intervention and he succumbed to multiorgan failure. Interestingly, our isolate was beta lactamase producing. We review the epidemiology, risk factors, presentation, and management of *C. perfringens* bacteremia. This case indicates a need for high clinical suspicion for clostridial sepsis and that extended spectrum beta lactam antibiotic coverage may be inadequate and should be supplemented with use of clindamycin or metronidazole if culture is positive, until sensitivities are known.

1. Introduction

Clostridium species are Gram-positive, spore-forming, obligate anaerobic bacilli. Malignancies, renal insufficiency, and other chronic illnesses have been associated with *Clostridium perfringens* (*C. perfringens*) bacteremia [1]. This entity is associated with adverse outcomes, especially if not clinically suspected early in the course of disease [1]. We present a rare case of resistant *C. perfringens* bacteremia associated with acute pancreatitis. The purpose of this case report is to alert physicians to suspect *C. perfringens* bacteremia in elderly patients presenting with abdominal symptoms and sepsis. Additionally, providers should be aware that although rare, *C. perfringens* can produce beta lactamase which can complicate antibiotic management.

2. Case Presentation

A 74-year-old man was brought to our emergency room with altered mental status, abdominal pain, and multiple episodes of vomiting and diarrhea for one day. Review of systems was negative for any other systemic complaints including fever. His medical history was significant for hypertension. He had no prior history of diabetes or surgery and had no pertinent family history. Personal history included prior alcohol use for fifty years with a reported intake of approximately 3-4 beers daily.

On physical exam, he was tachycardic, hypotensive, and obtunded with cold extremities. His abdomen was tense and distended with sluggish bowel sounds. He was emergently intubated and aggressive resuscitation initiated for presumptive septic shock.

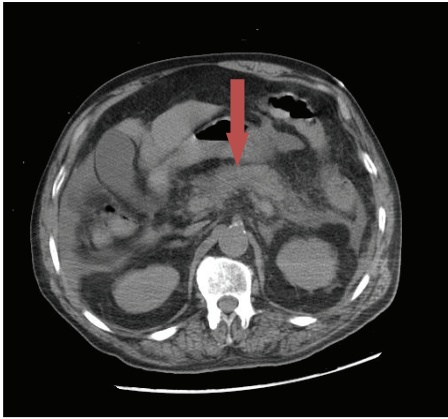


FIGURE 1: Axial cut of abdomen on day 1: arrow showing mildly edematous pancreas, with moderate peripancreatic infiltrative changes secondary to moderate acute pancreatitis.

Laboratory parameters revealed leukocytosis ($12 \times 10^3/\mu\text{L}$), anion gap metabolic acidosis (pH 7.10 with anion gap of 31), acute kidney injury (creatinine level 2.6 mg/dL), elevated lipase (1088 U/L), and mildly elevated transaminases (aspartate aminotransferase level 95 IU/L, alanine aminotransferase level 256 IU/L, and alkaline phosphatase level 195 IU/L). Mean corpuscular volume (MCV) was 98 fL and there was no evidence of hemolysis. Of note, his HbA1c was 8.4% suggesting undiagnosed diabetes mellitus. Urine toxicology screen was negative and serum ethanol level was less than 10 mg/dL. Computerized tomography (CT) scan of the abdomen (Figure 1) revealed moderate peripancreatic infiltrative changes and dilated loops of small bowel consistent with moderate acute pancreatitis and small bowel ileus.

A blood culture drawn on admission was reported to be positive for *C. perfringens* on day five. Metronidazole and clindamycin were then added to the existing regimen of vancomycin and piperacillin-tazobactam. Subsequent antibiotic sensitivity testing of the *C. perfringens* isolate revealed beta lactamase positivity; hence clindamycin was continued to treat the *C. perfringens* bacteremia. Metronidazole was also continued for suspected colitis. Stool studies including *Clostridium difficile* toxin and cultures were negative. The patient continued to require vasopressor support despite appropriate antibiotics and continued aggressive medical therapy, with worsening renal failure requiring hemodialysis.

A contrast enhanced CT of the abdomen on day seven revealed extensive acute pancreatitis with a new focus of likely necrotic pancreatitis in the pancreatic body with an associated 8.2 cm fluid collection consistent with a developing pseudocyst (Figure 2). Bilateral pleural effusions were also demonstrated. The patient's tenuous hemodynamic status precluded surgery. CT guided percutaneous aspiration of the pseudocyst fluid as well as pleural fluid was performed by interventional radiology. Cultures from these samples were subsequently negative. The remainder of the patient's hospital course was complicated by vancomycin-resistant enterococcus bacteremia and continued septic shock with worsening multiorgan failure and death.

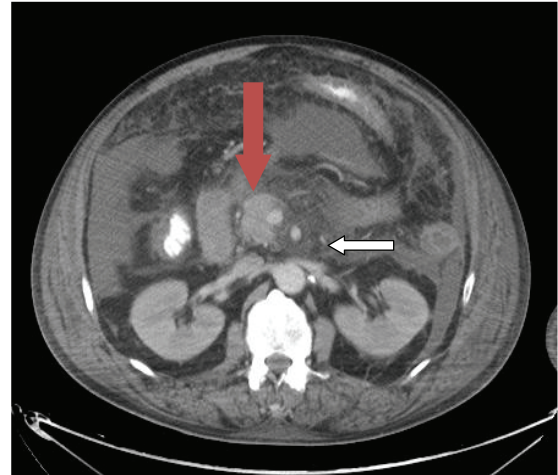


FIGURE 2: Axial cut of abdomen on day 7: red arrow pointing at a partially loculated fluid within the body of the pancreas. The white arrow shows an area of focal necrosis within the body of the pancreas.

3. Discussion

Advanced age increases the risk of clostridial infection independent of comorbidities which could be explained by age-related increase of clostridial species in the normal intestinal flora [2]. *C. perfringens* is frequently isolated from the biliary tree and gastrointestinal tract [2–4]. *C. perfringens* bacteremia has been reported after colonoscopy and gynecologic procedures [5, 6], and in association with choledocholithiasis in the absence of gallbladder stones and with normal common bile duct diameter [7].

Five subtypes of *C. perfringens* (A to E) exist and can produce as many as 12 different toxins. The 4 principal toxins of *C. perfringens* are alpha, beta, epsilon, and iota [8–10]. Alpha toxin can cause gas gangrene [11] as well as hemolysis and platelet destruction [12–14]. *C. perfringens* bacteremia has been associated with intravascular hemolysis and death [9, 10, 15, 16]. Low MCV and hemolysed samples in a patient with fever should alert the clinician to the possibility of clostridial infection. Beta toxin is associated with necrotic enteritis [17]. Epsilon toxin is known to cause fatal enterotoxemia in sheep and other animals [18]. When injected intradermally, iota toxin causes an increase in capillary permeability and intradermal necrosis in guinea-pigs. Larger doses injected intravenously are lethal in animals [18].

C. perfringens bacteremia, especially with a penicillinase producing strain, is a rare clinical entity. Epidemiological studies examining *Clostridium* bacteremia have been conducted in Taiwan, Japan, Canada, and the United States.

A study from northern Taiwan [1] demonstrated an overall annual incidence of *C. perfringens* bacteremia of 0.97 per 100,000 population. Elderly patients with comorbid illnesses, especially renal insufficiency or malignancy, were at increased risk. The 30-day and attributed mortalities were 26.9% and 8.6%, respectively. Nosocomial acquired *C. perfringens* infection was a significant predictor of 30-day mortality.

Most *C. perfringens* blood isolates were susceptible to the antibiotics tested. Resistance was observed in only seven out of ninety-three isolates, primarily to penicillin and clindamycin.

A review of all blood cultures drawn in a Japanese tertiary center from 2001 to 2009 demonstrated only 18 patients with *C. perfringens* bacteremia. Overall 30-day mortality was 27%. Septic shock at initial presentation was significantly associated with mortality [19]. A population-based surveillance of clostridial bacteremia among all residents of the Calgary Health Region (population 1.2 million) during 2000–2006 revealed a prevalence of clostridial bacteremia at 1.8/100,000 per year. Older age and multiple comorbidities, most importantly malignancy and Crohn's disease, were risk factors for acquiring *Clostridium* bacteremia. *C. perfringens* was the most common species isolated [2].

Review of blood cultures drawn in a rural hospital in Wisconsin from 1990 to 1997 yielded *Clostridium* infection in 0.12% with *C. perfringens* again, being the most common isolate (21.7%) [20].

Several studies have identified other conditions associated with the pathogenicity of *Clostridium* species and have demonstrated that failure to institute early, appropriate antimicrobial therapy may be associated with a poor outcome [2, 21, 22].

In another Taiwanese study, a review of 73 patients with clostridial bacteremia in an 11-year period identified diabetes mellitus and liver cirrhosis as the most common underlying comorbidities. Etiological species identified were *C. perfringens* (77%), *Clostridium bifermentans* (9%), and *Clostridium septicum* (4%). *Clostridium* bacteremia in patients with underlying liver cirrhosis and septic shock on initial presentation were poor prognostic factors [21].

The significance of positive blood culture for *Clostridium* was also studied in Israel. They found that growth of *Clostridium* species in blood cultures, even in the absence of one of the histotoxic syndromes, is often of clinical significance. Patients with *Clostridium* bacteremia were older, had a higher frequency of gastrointestinal disease, especially colorectal tumors, were more frequently associated with polymicrobial bacteremia, and had a higher mortality rate [22].

Our patient had several known risk factors for clostridial infection and subsequent mortality. He was older, apparently diabetic, had gastrointestinal disease, and presented in shock. However, none of the histotoxic syndromes associated with *Clostridium* infection were readily apparent. Although *C. perfringens* bacteremia was not initially suspected in our patient, he was treated with appropriate antibiotics.

Our isolate was reported to be beta lactamase producing. Based on the susceptibility report (see Table 1), our patient appeared to have a penicillinase producing organism as opposed to being a cephalosporinase producer.

The patient was initiated on piperacillin-tazobactam and vancomycin, both of which could be expected to have efficacy towards our isolate. Nevertheless, our patient deteriorated, requiring the addition of metronidazole and clindamycin. It is conceivable that penicillinase *C. perfringens* in vitro may predict cephalosporinase activity in vivo. Beta lactam resistance has been well studied in many pathogenic bacteria. In vitro

TABLE 1

Antibiotic	Interpretation	MIC mcg/mL
Ampicillin/sulbactam	S	<1
Cefotaxime	S	4
Cefoxitin	S	<2
Ceftizoxime	S	<2
Chloramphenicol	S	4
Clindamycin	S	<0.5
Metronidazole	S	<0.5
Penicillin	R	
Piperacillin	S	<4
Tetracycline	S	<0.5

susceptibility does not necessarily produce in vivo activity of an apparently appropriate antibiotic [23]. Unfortunately, we could not find any specific studies of this phenomenon related to *C. perfringens*. Early studies have demonstrated in vitro susceptibility of *C. perfringens* strains to vancomycin [24]. However a more recent study has shown that vancomycin is not bactericidal against *C. perfringens* [25].

4. Conclusion

Although rare, given the significant mortality of *C. perfringens* bacteremia, clinicians should be aware of the risk factors and presentation associated with this pathogen. We recommend immediate initiation of additional antibiotic coverage, for example, clindamycin or metronidazole, as soon as *C. perfringens* is isolated in culture, pending sensitivity. Data regarding clinical outcomes in beta lactamase producing *Clostridia* are scarce and may warrant further subgroup analysis. Furthermore, more microbiologic studies are required exploring in vitro and in vivo susceptibility patterns.

Abbreviations

C. perfringens: *Clostridium perfringens*
 CT: Computerized tomography
 MCV: Mean corpuscular volume.

Conflict of Interests

None of the authors has a financial relationship with a commercial entity that has an interest in the subject of the paper. No financial support was used for this case report.

References

- [1] C.-C. Yang, P.-C. Hsu, H.-J. Chang, C.-W. Cheng, and M.-H. Lee, "Clinical significance and outcomes of *Clostridium perfringens* bacteremia—a 10-year experience at a tertiary care hospital," *International Journal of Infectious Diseases*, vol. 17, no. 11, pp. e955–e960, 2013.
- [2] J. Leal, D. B. Gregson, T. Ross, D. L. Church, and K. B. Laupland, "Epidemiology of *Clostridium* species bacteremia in Calgary, Canada, 2000–2006," *Journal of Infection*, vol. 57, no. 3, pp. 198–203, 2008.

- [3] G. Hill, S. Osterhous, and H. Willet, "Histotoxic clostridia," in *Zinsser Microbiology*, W. Joklik, H. Willet, and D. Amos, Eds., pp. 697–706, Appleton-Century-Crofts, Norwalk, Conn, USA, 1984.
- [4] S. Gorbach, "Clostridium perfringens and other clostridia," in *Infectious Diseases*, S. Gorbach, J. Bartlett, and N. Blacklow, Eds., W.B. Saunders, Philadelphia, Pa, USA, 1998.
- [5] A. N. Kunz, D. Riera, and P. Hickey, "Case of *Clostridium perfringens* bacteremia after routine colonoscopy and polypectomy," *Anaerobe*, vol. 15, no. 5, pp. 195–196, 2009.
- [6] S. Halawa, A. Kassab, and R. Fox, "Clostridium perfringens infection following endometrial ablation," *Journal of Obstetrics & Gynaecology*, vol. 28, no. 3, p. 360, 2008.
- [7] A. Atia, T. Raiyani, P. Patel, R. Patton, and M. Young, "Clostridium perfringens bacteremia caused by choledocholithiasis in the absence of gallbladder stones," *World Journal of Gastroenterology*, vol. 18, no. 39, pp. 5632–5634, 2012.
- [8] C. M. Miller, S. Florman, L. Kim-Schluger et al., "Fulminant and fatal gas gangrene of the stomach in a healthy live liver donor," *Liver Transplantation*, vol. 10, no. 10, pp. 1315–1319, 2004.
- [9] W. Hübl, B. Mostbeck, H. Hartleb, H. Pointner, K. Kofler, and P. M. Bayer, "Investigation of the pathogenesis of massive hemolysis in a case of *Clostridium perfringens* septicemia," *Annals of Hematology*, vol. 67, no. 3, pp. 145–147, 1993.
- [10] A. Merino, A. Pereira, and P. Castro, "Massive intravascular haemolysis during *Clostridium perfringens* sepsis of hepatic origin," *European Journal of Haematology*, vol. 84, no. 3, pp. 278–279, 2010.
- [11] J. Sakurai, M. Nagahama, and M. Oda, "Clostridium perfringens alpha-toxin: characterization and mode of action," *Journal of Biochemistry*, vol. 136, no. 5, pp. 569–574, 2004.
- [12] G. C. Diaz, T. Boyer, and J. F. Renz, "Survival of *Clostridium perfringens* sepsis in a liver transplant recipient," *Liver Transplantation*, vol. 15, no. 11, pp. 1469–1472, 2009.
- [13] B. Eigenberger, I. Königsrainer, H. Kendziorra, and R. Riessen, "Fulminant liver failure due to *Clostridium perfringens* sepsis 9 years after liver transplantation," *Transplant International*, vol. 19, no. 2, pp. 172–173, 2006.
- [14] D. L. Stevens and A. E. Bryant, "The role of clostridial toxins in the pathogenesis of gas gangrene," *Clinical Infectious Diseases*, vol. 35, supplement 1, pp. S93–S100, 2002.
- [15] G. Rajendran, P. Bothma, and A. Brodbeck, "Intravascular haemolysis and septicaemia due to *Clostridium perfringens* liver abscess," *Anaesthesia and Intensive Care*, vol. 38, no. 5, pp. 942–945, 2010.
- [16] S. D. Boyd, B. C. Mobley, D. P. Regula, and D. A. Arber, "Features of hemolysis due to *Clostridium perfringens* infection," *International Journal of Laboratory Hematology*, vol. 31, no. 3, pp. 364–367, 2009.
- [17] M. R. Popoff and P. Bouvet, "Clostridial toxins," *Future Microbiology*, vol. 4, no. 8, pp. 1021–1064, 2009.
- [18] J. L. McDonel, "Clostridium perfringens toxins (type A, B, C, D, E)," *Pharmacology and Therapeutics*, vol. 10, no. 3, pp. 617–655, 1980.
- [19] H. Fujita, S. Nishimura, S. Kurosawa, I. Akiya, F. Nakamura-Uchiyama, and K. Ohnishi, "Clinical and epidemiological features of *Clostridium perfringens* bacteremia: a review of 18 cases over 8 year-period in a tertiary care center in metropolitan Tokyo area in Japan," *Internal Medicine*, vol. 49, no. 22, pp. 2433–2437, 2010.
- [20] P. M. Rechner, W. A. Agger, K. Mruz, and T. H. Cogbill, "Clinical features of clostridial bacteremia: a review from a rural area," *Clinical Infectious Diseases*, vol. 33, no. 3, pp. 349–353, 2001.
- [21] Y.-M. Chen, H.-C. Lee, C.-M. Chang, Y.-C. Chuang, and W.-C. Ko, "Clostridium bacteremia: emphasis on the poor prognosis in cirrhotic patients," *Journal of Microbiology, Immunology and Infection*, vol. 34, no. 2, pp. 113–118, 2001.
- [22] B. Benjamin, M. Kan, D. Schwartz, and Y. Siegman-Igra, "The possible significance of *Clostridium* spp. in blood cultures," *Clinical Microbiology and Infection*, vol. 12, no. 10, pp. 1006–1012, 2006.
- [23] D. M. Livermore, "Beta-lactamases in laboratory and clinical resistance," *Clinical Microbiology Reviews*, vol. 8, no. 4, pp. 557–584, 1995.
- [24] F. L. Sapico, Y. Y. Kwok, V. L. Sutter, and S. M. Finegold, "Standardized antimicrobial disc susceptibility testing of anaerobic bacteria: in vitro susceptibility of *Clostridium perfringens* to nine antibiotics," *Antimicrobial Agents and Chemotherapy*, vol. 2, no. 4, pp. 320–325, 1972.
- [25] K. L. Tyrrell, D. M. Citron, Y. A. Warren, H. T. Fernandez, C. V. Merriam, and E. J. C. Goldstein, "In vitro activities of daptomycin, vancomycin, and penicillin against *Clostridium difficile*, *C. perfringens*, *Fingoldia magna*, and *Propionibacterium acnes*," *Antimicrobial Agents and Chemotherapy*, vol. 50, no. 8, pp. 2728–2731, 2006.