

Viewpoints and debate

Complete response of leptomeningeal carcinomatosis secondary to breast cancer

Idriss Troussier^{a, b}, Charles Canova^b, Guillaume Klausner^{c, *}^a Radiation Oncology Department, Hospital University of Geneva, Avenue de La Roseiraie 53, 1205, Genève, Suisse, Switzerland^b Radiation Oncology Department, Centre de Haute Energie, 10 Boulevard Pasteur, 06000, Nice, France^c University Pierre and Marie Curie, Paris Sorbonne University, 91-105 Boulevard de L'Hôpital, 75013, Paris, France

ARTICLE INFO

Article history:

Received 23 November 2020

Accepted 26 November 2020

Available online 28 November 2020

Keywords:

Meningeal carcinomatosis
Metastatic breast neoplasms
CDK4/6 cell-cycle inhibitors
Hippocampal-avoidance whole brain
radiotherapy
Abemaciclib

ABSTRACT

Leptomeningeal carcinomatosis (LC) is an unmet medical need associated with death in 4–6 weeks without treatment, delayed by 4 months in some patients with favorable prognosis and aggressive multimodal therapy. Unfortunately, most clinical trials excluded patients with LC, and the best management remains unknown.

Here we present the first report of a LC secondary to HR positive breast cancer with a complete response to CDK4/6 inhibitors abemaciclib, letrozole and hippocampal-avoidance whole-brain radiotherapy.

© 2020 Published by Elsevier Ltd. This is an open access article under the CC BY-NC-ND license (<http://creativecommons.org/licenses/by-nc-nd/4.0/>).

This report could rise new hope and pave the way for innovative therapeutic approaches in the management of LC secondary to HR positive breast cancer. Prevalence of such response as well as safety profile need to be evaluated prospectively to fully assess impact of abemaciclib in this setting.

Leptomeningeal carcinomatosis (LC) in patients with breast cancers is an unmet medical need associated with morbidity and death in 4–6 weeks without treatment, delayed by 4 months in some patients with favorable prognosis and aggressive multimodal therapy [1]. Therapeutic options include intra-cerebra-spinal fluid chemotherapy, systemic therapy, radiation therapy and best-supportive care. Unfortunately, most clinical trials excluded patients with central nervous system metastases, and the best management remains unknown. Currently, treatment strategy is individualized, uni or multimodal approach selected on a case-by-case bases, but even so therapeutic response is generally disappointing.

Here we present the first report, to our knowledge, of a leptomeningeal carcinomatosis secondary to breast cancer with a complete response at 1 year to inhibitor of cyclin-dependent

kinases 4 (CDK4) and 6 (CDK6) abemaciclib, letrozole and hippocampal-avoidance whole-brain radiotherapy (HA-WBRT).

A 58-year old woman, menopausal woman with no medical history had an oncologic breast conservative surgery with sentinel lymph node biopsy for a malignant neoplasm of the right breast discovered by mammogram screening. Histological examination revealed a moderately differentiated non-specific invasive carcinoma of 15 mm, estrogen receptors (ER) 90%, progesterone receptors (PR) 20%, HER2 negative (score 0), grade II (2 + 3+1), Ki67 35%, without lympho-vascular invasion (LVO), with perineural invasion (Pn1), negative resection margin (R0). Tumor was stage as pT1bN0M0 luminal B breast cancer according to the 7th edition of the TNM.

During the third course of adjuvant chemotherapy including anthracycline and cyclophosphamide, she presented painkiller-resistant headaches and transient loss of consciousness. Brain magnetic resonance imaging (MRI) revealed disseminated meningeal gadolinium contrast-enhancement associated with nodular contrast-enhancement at meningeal onset and adjacent parenchymal extension that were consistent with nodular LC (Fig. 1A). Spinal MRI was negative for spinal cord or meningitis extension. ¹⁸Fluorodeoxyglucose positron emission tomography – computed tomography (FDG TEP-CT) and chest CT-scan did not find any distant metastasis.

Given poor prognosis of LC and absence of standard

* Corresponding author. Université Pierre et Marie Curie, Paris Sorbonne University, 47-83 Boulevard de L'Hôpital, 75013, Paris, France.

E-mail addresses: idriss.troussier@che-nice.com (I. Troussier), canovacharles@gmail.com (C. Canova), guillaume.klausner@gmail.com (G. Klausner).

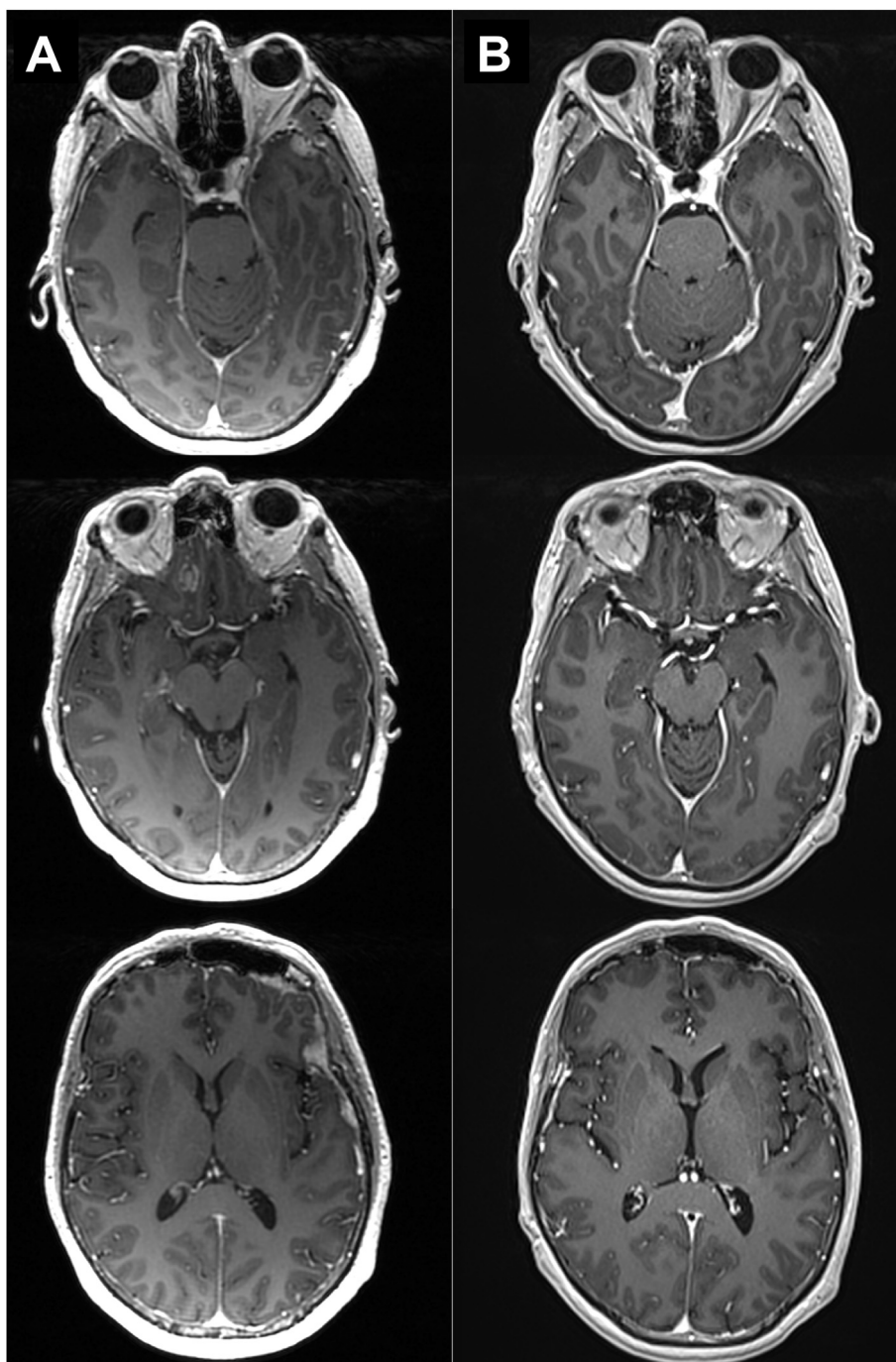


Fig. 1. Diagnostic brain magnetic resonance imaging (MRI) showing the nodular lesions of leptomeningeal carcinomatosis secondary to hormone receptors positive, HER2 negative breast cancer compared to the brain MRI at 3 months after completion of radiotherapy.

management in this setting, and after having obtained patient consent, we proposed a multimodal approach including CDK4/6 inhibitors, standard endocrine therapy (aromatase inhibitor) and HA-WBRT. Because of the disease progression during chemotherapy, a combination of a CDK4/6 inhibitor with hormone therapy was selected considering the expected advantage in progression-free survival [2].

Based on preliminary results of a recent phase II study in patients with brain metastases secondary to hormone receptors positive, HER2 negative metastatic breast cancer, we initiated abemaciclib, orally administered 150 mg two times a day and

letrozole 2.5 mg per day [2]. Because central nervous system-specific efficacy of CDK4/6 inhibitors was uncertain, and the patient suffered from disabling headaches, painkiller-resistant, we associated HA-WBRT to systemic treatments. Intensity-modulated radiation therapy (IMRT) was used to deliver the dose of 30 Gy in 10 fractions in whole-brain parenchyma, excluding the hippocampal region defined as bilateral hippocampal gyri, expanded by a three-dimensional margin of 5 mm. No boost was added to the nodular lesions due to proximity with the optic nerves and the chiasm. Corticosteroid therapy using prednisone 40 mg per day was prescribed before and concurrently with HA-WBRT and was

stopped fifteen days after the completion of the radiotherapy.

Three months after completion of radiotherapy and ongoing treatment by letrozole and abemaciclib at the same dosage, she presented to our institution without any symptom especially without headaches. The treatment was well-tolerated, the patient maintained a performance status of 0 according to Eastern Cooperative Oncology Group (ECOG) and the physical examination was perfectly normal. Brain MRI at 3 months showed a complete response (Fig. 1B). After 1 year of follow-up, these results were maintained, and brain MRI confirmed the continuation of a complete response.

To our knowledge, we reported for the first time a complete response at 1 year of a LC secondary to hormone receptors positive, HER2 negative breast cancer treated with abemaciclib, letrozole and HA-WBRT. Because of its high incidence, breast cancer is the first etiology of LC, which still carries a very poor prognosis, with a median survival ranging from 4 weeks to 4 months depending on age, performance general status, luminal subtype and therapy available [3]. Our report is uncommon for two reasons. Histological subtype is not lobular invasive or triple-negative carcinoma while they represent the large majority of LC (approximately 75%) in the setting of breast neoplasm. Furthermore, LC appeared very early after the diagnosis while it's commonly a late complication concurrently to progressive metastatic cancer (approximately 70% of cases). Considering these two points and the patient characteristics (ECOG score, age, absence of distant metastases and patient desire), we have chosen an innovative multimodal approach.

Pre-clinical data suggested penetration of abemaciclib across the blood–brain barrier in rat orthotopic xenograft model. In addition, abemaciclib brain levels were reached at lower doses than palbociclib and were potentially on target for a longer period of time [4]. Early clinical data confirmed that abemaciclib could penetrate the blood brain barrier, while no data existed using palbociclib [5]. A phase II study assessing abemaciclib orally administered 200 mg two times a day in brain metastases from HR positive HER2 negative breast cancer included heavily pretreated patients who central nervous system progression occurred on endocrine therapy. The preliminary results were encouraging with 25% of complete response or partial response or stable disease longer than 6 months and a median progression-free survival of 4.4 months without additional toxicity [2]. However, to maximize local control of symptomatic nodular lesions, we added HA-WBRT using IMRT in order to preserve cognitive function and patient's autonomy following the NRG protocol [6]. Pre-clinical report revealed a potential synergistic effect between CDK inhibitors and radiotherapy, and a recent retrospective study of 42 HR positive breast cancer lesions that received palbociclib or abemaciclib and radiotherapy showed 5% of radionecrosis and did not report any neurological adverse events [7].

This report could rise new hope and pave the way for innovative therapeutic approaches in the management of LC secondary to

breast cancer primary hormone receptors positive. However, in order to fully assess the impact of the combination of abemaciclib, letrozole and HA-WBRT on central nervous system metastases, prevalence of such response and safety profile need to be evaluated prospectively in larger cohort.

Ethics statement

Abemaciclib and letrozole in this patient with HR positive, HER2 negative metastatic breast cancer were provided as a first-line treatment in the metastatic setting in line with national regulations and did not require ethics committee approval. The patient provided written informed consent prior to initiation of treatment. Written informed patient consent was also obtained for publication of the data contained in this case report.

Legend: Gadolinium-enhanced T1-weighted axial slices illustrating three nodular contrast-enhancement of leptomeningeal carcinomatosis on diagnosis brain MRI (A) that fully disappeared 3 months after completion of radiotherapy (B).

Role of funding source

None.

Declaration of competing interest

None.

The authors declare that they have no conflict of interest.

References

- [1] Franzi MA, Hortobagyi GN. Leptomeningeal carcinomatosis in patients with breast cancer. *Crit Rev Oncol Hematol*. 1 mars 2019;135:85–94.
- [2] Anders CK, Le Rhun E, Bachelot TD, Yardley DA, Awada A, Conte PF, et al. A phase II study of abemaciclib in patients (pts) with brain metastases (BM) secondary to HR+, HER2- metastatic breast cancer (MBC). *J Clin Oncol*. 20 mai 2019;37(15_suppl). 1017-1017.
- [3] Corbin ZA, Nagpal S. Leptomeningeal metastases. *JAMA Oncol*. 1 juin 2016;2(6):839-839.
- [4] Raub TJ, Wishart GN, Kulanthaivel P, Staton BA, Ajamie RT, Sawada GA, et al. Brain exposure of two selective dual CDK4 and CDK6 inhibitors and the anti-tumor activity of CDK4 and CDK6 inhibition in combination with temozolomide in an intracranial glioblastoma xenograft. *Drug Metab Dispos* sept 2015;43(9):1360–71.
- [5] Nguyen LV, Searle K, Jerzak KJ. Central nervous system-specific efficacy of CDK4/6 inhibitors in randomized controlled trials for metastatic breast cancer. *Oncotarget* 29 oct 2019;10(59):6317–22.
- [6] Brown PD, Gondi V, Pugh S, Tome WA, Wefel JS, Armstrong TS, et al. Hippocampal avoidance during whole-brain radiotherapy plus memantine for patients with brain metastases: phase III trial NRG Oncology CC001. *J Clin Oncol*. 14 févr 2020;38(10):1019–29.
- [7] Figura NB, Potluri TK, Mohammadi H, Oliver DE, Arrington JA, Robinson TJ, et al. CDK 4/6 inhibitors and stereotactic radiation in the management of hormone receptor positive breast cancer brain metastases. *J Neurooncol*. sept 2019;144(3):583–9.