

# Difficult airway management and emergency tracheostomy in a patient with giant goiter presenting with respiratory arrest: A case report

HAYRIYE CANKAR DAL

Department of Intensive Care Unit, University of Health Sciences, Ankara City Hospital, 06800 Ankara, Turkey

Received April 16, 2022; Accepted May 24, 2022

DOI: 10.3892/etm.2022.11426

**Abstract.** Giant goiter is commonly asymptomatic or progresses with nonspecific symptoms, such as pain, hoarseness and dysphagia. In rare cases, enlargement of the thyroid may cause compression of the trachea and lead to life-threatening complications. As a result of iodization programs implemented throughout the world to address iodine deficiency disorders, giant goiter is rare today. Although not common, the disease may result in a difficult airway in cases of tracheal compression. The present study shares our experience of a giant retrosternal goiter in a patient presenting with respiratory arrest who underwent emergency tracheostomy after multiple attempts at orotracheal intubation and then thyroidectomy during an intensive care stay due to the development of tracheomalacia.

## Introduction

As a result of iodization programs implemented throughout the world to address iodine deficiency disorders, giant goiter is rare today (1). The incidence of endemic goiter has decreased to 1% worldwide thanks to those iodization programs (2). The presence of giant goiter is among the causes of difficult airway management. Advanced airway procedures may be necessary in cases requiring intubation. The published literature mainly covers airway management during thyroid surgery in patients with goiter, but reports of giant goiter cases requiring emergency intubation at the intensive care unit (ICU) are scarce. The present study aimed to share our experience with a type of case that is rarely seen and may lead to mortal complications if not well managed. The present report describes a patient with giant retrosternal goiter presenting with respiratory arrest who underwent emergency tracheostomy after multiple attempts at

oro-tracheal intubation and then thyroidectomy during the ICU stay due to the development of tracheomalacia.

## Case report

A 63-year-old male patient was admitted to Ankara City Hospital (Ankara, Turkey) in November 2021 with respiratory arrest. The patient with known hypertension had anterior neck swelling for 5 years and hoarseness symptoms that developed in the last months. During resuscitation, oro-tracheal intubation was not successful despite multiple attempts, including video laryngoscopy and fiberoptic intubation. According to the difficult airway management algorithms (3), an emergency tracheostomy was performed. The emergency percutaneous tracheostomy was performed with the Griggs method by ear nose throat surgeons and an intensivist. Tracheostomy was performed by creating an opening between the 2nd-3rd tracheal rings, above the thyroid isthmus. An 8-mm tracheostomy cannula was inserted. After the patient responded to cardiopulmonary resuscitation and his vital signs became stable, computed tomography (CT) imaging of the neck was performed. Oropharyngeal, hypopharyngeal and laryngeal stenoses were evident. At the supraglottic level, the laryngeal air column was completely obliterated. The tracheal lumen caliber was markedly narrow along the tracheostomy cannula and the tracheal stenosis extended up to the supracarinal level (Fig. 1). An extension of the enlarged thyroid gland into the mediastinal intrathoracic area was observed.

Monitoring of the patient indicated low tidal volumes and respiratory distress, necessitating an emergency bronchoscopy. It was observed that the inserted size 8 mm tracheostomy cannula was insufficient to access the trachea due to thyroid enlargement. The cannula was replaced with a size 8 mm spiral-embedded endotracheal tube. On the first day of ICU follow-up, no additional conditions were detected and the patient was conscious and cooperative. Thyroid function tests indicated the following: Thyroid-stimulating hormone, 0.50 mU/l (normal range, 0.55-4.78 mU/l); free triiodothyronine (T3), 2.34 ng/l (normal range, 2.3-4.2 ng/l); and free thyroxine (T4), 1.13 ng/dl (normal range, 0.89-1.76 ng/dl). However, the goiter caused compression; thus, the patient was evaluated for surgery and a total thyroidectomy was planned. Because of the urgency of the process, it was not possible to

---

*Correspondence to:* Dr Hayriye Cankar Dal, Department of Intensive Care Unit, University of Health Sciences, Ankara City Hospital, 1 Bilkent Street, Cankaya, 06800 Ankara, Turkey  
E-mail: hayriyecankar@hotmail.com

**Key words:** giant goiter, difficult airway, thyroidectomy, tracheostomy, tracheomalacia

explore the mobility of the vocal cords prior to thyroidectomy. Due to the retrosternal extension of the enlarged thyroid tissue, both general surgery and thoracic surgery teams were present during the operation including total thyroidectomy via sternotomy. Bilateral recurrent laryngeal nerves were carefully identified during thyroidectomy and intraoperative nerve monitoring was performed. The removed right lobe of the thyroid gland was 19x13x9 cm in size and weighed 295 g and the left lobe was 23x14x8.5 cm and weighed 465 g (Fig. 2). The surgical specimens sent for pathology examination were reported as compatible with the diagnosis of multinodular goiter.

The patient remained stable during the post-operative follow-up at the ICU and the spiral-embedded endotracheal tube in the tracheostomy was replaced with a size 8 mm tracheostomy cannula without any complications. The patient was then placed on a mechanical ventilator in spontaneous mode. Post-operative fiberoptic laryngoscopy was performed to examine vocal cord movements and bilateral vocal cord motions were normal. On the postoperative first day he was conscious and cooperative and oral intake was normal. Post-operative control CT and bronchoscopy were evaluated together with the thoracic surgery clinicians (Fig. 3). Due to tracheomalacia, it was decided to discharge the patient with the tracheostomy. The patient was discharged with a home mechanical ventilator, and rehospitalized one month later for follow-up controls and weaning trial. The CT of the neck and bronchoscopy control indicated no abnormality. After successful weaning trials, the tracheostomy tube was decannulated on the post-operative 45th day. No complications or oxygen demand occurred after the weaning and the patient was discharged with full recovery.

## Discussion

Retrosternal goiter is common among females and in the fifth decade of life. The condition is asymptomatic in 15-50% of patients (4). Giant goiter frequently causes dyspnea, hoarseness and dysphagia, but may also lead to life-threatening complications (5).

A difficult airway is a clinical situation encountered at the ICU due to various reasons and may result in mortality if not managed well (6). Video laryngoscopy, fiberoptic intubation or emergency tracheostomy may be applied in patients with upper airway obstruction (UAO) as per the algorithms of difficult airway management (3). The preferred method may vary depending on the size of the thyroid gland, and the level and location of tracheal obstruction. Emergency tracheostomy stands out as a life-saving maneuver in UAO but may also be risky in cases where enlarged thyroid tissue prevents access to the trachea (7). Selecting the most appropriate method in line with the algorithms is crucial for patient safety.

In a study on retrosternal goiter, White *et al* (8) reported tracheomalacia in 50% of their cases, one-third of which underwent tracheostomy. In patients with giant goiter, it is crucial to plan surgical intervention at an early phase once airway patency is achieved. Emergency thyroidectomy is recommended in the literature for goiters with severe compression (9). It has been

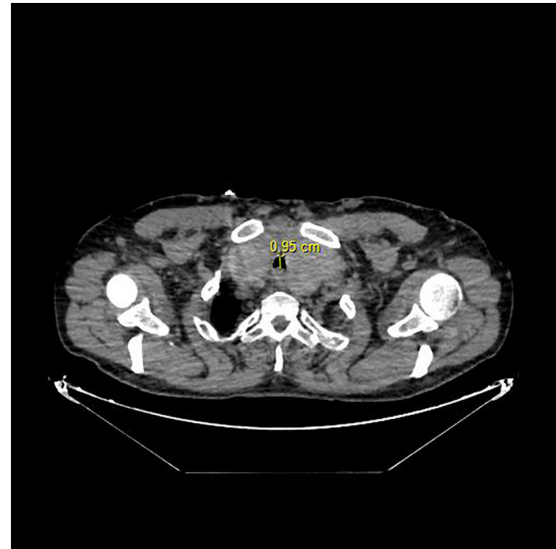


Figure 1. Computed tomography of the neck illustrating enlarged thyroid gland. The tracheal lumen diameter was 0.95 cm at the narrowest point.

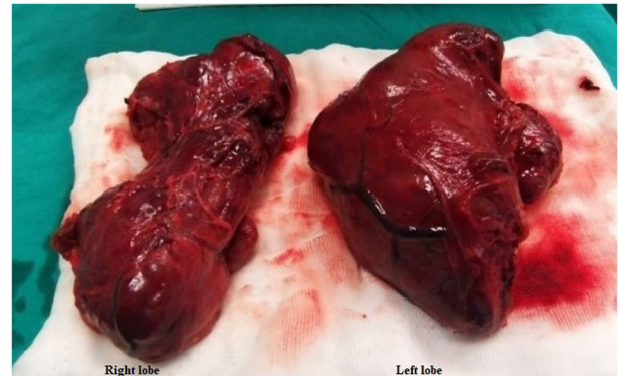


Figure 2. Post-thyroidectomy specimen. The removed right lobe of the thyroid gland was 19x13x9 cm in size and the left lobe was 23x14x8.5 cm.

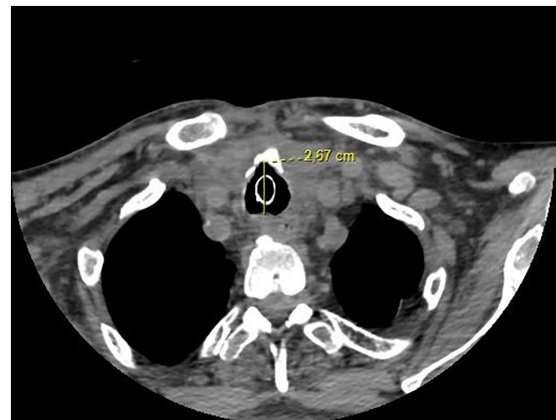


Figure 3. Computed tomography of the neck after total thyroidectomy operation. The tracheal lumen diameter was 2.67 cm.

reported that acute airway obstruction is observed in patients with giant goiter due to intrathyroid hemorrhage, tracheal compression or tumor invasion of the lumen in thyroid

malignancies, and <1% of these patients require emergency thyroidectomy (10). During the post-operative period, patients should be carefully evaluated for extubation. Tracheomalacia and tracheal collapse may develop due to softening of the tracheal tissue and loss of tone, particularly after prolonged tracheal compression. If tracheomalacia is present, early extubation after thyroidectomy may result in severe respiratory distress (8). However, the published literature provides no standard recommendations for weaning from ventilation in patients with tracheomalacia. The physician should keep in mind that tracheomalacia may have developed and therefore, gradual and controlled weaning should be provided in these patients.

#### Acknowledgements

Not applicable.

#### Funding

No funding was received.

#### Availability of data and materials

The datasets used and/or analyzed during the current study are available from the corresponding author on reasonable request.

#### Authors' contributions

HCD conceptualized the study. HCD analyzed patient data and provided critical revisions. HCD obtained the medical images and made substantial contributions to data interpretation. HCD confirmed the authenticity of all the raw data and read and approved the final manuscript.

#### Ethics approval and consent to participate

Not applicable.

#### Patient consent for publication

The patient provided written informed consent regarding treatment interventions, and the collection and publication of images and other clinical data.

#### Competing interests

The author declares that she has no competing interests.

#### References

1. Zimmermann MB and Boelaert K: Iodine deficiency and thyroid disorders. *Lancet Diabetes Endocrinol* 3: 286-295, 2015.
2. Vanderpump MP: The epidemiology of thyroid disease. *Br Med Bull* 99: 39-51, 2011.
3. Higgs A, McGrath BA, Goddard C, Rangasami J, Suntharalingam G, Gale R and Cook TM; Difficult Airway Society; Intensive Care Society; Faculty of Intensive Care Medicine; Royal College of Anaesthetists: Guidelines for the management of tracheal intubation in critically ill adults. *Br J Anaesth* 120: 323-352, 2018.
4. Doulaptsi M, Karatzanis A, Prokopakis E, Velegrakis S, Loutsidi A, Trachalaki A and Velegrakis G: Substernal goiter: Treatment and challenges. Twenty-two years of experience in diagnosis and management of substernal goiters. *Auris Nasus Larynx* 46: 246-251, 2019.
5. Wong WK, Shetty S, Morton RP, McIvor NP and Zheng T: Management of retrosternal goiter: Retrospective study of 72 patients at two secondary care centers. *Auris Nasus Larynx* 46: 129-134, 2019.
6. Duwat A, Turbelin A, Petiot S, Hubert V, Deransy V, Mahjoub Y and Dupont H: French national survey on difficult intubation in intensive care units. *Ann Fr Anesth Reanim* 33: 297-303, 2014 (In French).
7. Bontempo LJ and Manning SL: Tracheostomy emergencies. *Emerg Med Clin North Am* 37: 109-119, 2019.
8. White ML, Doherty GM and Gauger PG: Evidence-based surgical management of substernal goiter. *World J Surg* 32: 1285-1300, 2008.
9. Wong P, Chieh Liew GH and Kothandan H: Anaesthesia for goitre surgery: A review. *Procee Singapore Healthcare* 24: 165-170, 2015.
10. Testini M, Logoluso F, Lissidini G, Gurrado A, Campobasso G, Cortese R, De Luca GM, Franco IF, De Luca A and Piccinni G: Emergency total thyroidectomy due to non traumatic disease. Experience of a surgical unit and literature review. *World J Emerg Surg* 7: 9, 2012.



This work is licensed under a Creative Commons Attribution-NonCommercial-NoDerivatives 4.0 International (CC BY-NC-ND 4.0) License.