




Since January 2020 Elsevier has created a COVID-19 resource centre with free information in English and Mandarin on the novel coronavirus COVID-19. The COVID-19 resource centre is hosted on Elsevier Connect, the company's public news and information website.

Elsevier hereby grants permission to make all its COVID-19-related research that is available on the COVID-19 resource centre - including this research content - immediately available in PubMed Central and other publicly funded repositories, such as the WHO COVID database with rights for unrestricted research re-use and analyses in any form or by any means with acknowledgement of the original source. These permissions are granted for free by Elsevier for as long as the COVID-19 resource centre remains active.

Available online at www.sciencedirect.com

ScienceDirect

journal homepage: <http://www.journals.elsevier.com/indian-journal-of-tuberculosis/>

Case report

“Disseminated multidrug-resistant tuberculosis and SARS-CoV-2 co-infection in a child with IL-12R β 1 deficiency”[☆]

Daniel San-Juan ^{a,*}, Misael Pérez Melgoza ^b, Oscar Zavaleta Martínez ^c, Raúl Aguilar López ^d, Alvaro Contreras Salazar ^e, Jesús del Moral Bastida ^e, Raúl Miranda Ojeda ^e

^a Epilepsy Clinic, National Institute of Neurology and Neurosurgery Manuel Velasco Suárez, Mexico City, Mexico

^b Infectology, Maternal and Child Hospital Institute of Social Security of the State of Mexico and Municipalities (ISSSM&M), Tomas Alva Edison S/n, Delegación San Lorenzo Tepaltitlán I, Delegación San Lorenzo Tepaltitlán, 50160 Toluca de Lerdo, Mexico

^c Immunology, Maternal and Child Hospital (ISSSM&M), Tomas Alva Edison S/n, Delegación San Lorenzo Tepaltitlán I, Delegación San Lorenzo Tepaltitlán, 50160 Toluca de Lerdo, Mexico

^d Neurosurgery, Maternal and Child Hospital (ISSSM&M), Tomas Alva Edison S/n, Delegación San Lorenzo Tepaltitlán I, Delegación San Lorenzo Tepaltitlán, 50160 Toluca de Lerdo, Mexico

^e Faculty of Medicine, Autonomous University of the State of Mexico, Av Paseo Tollocan, C. Jesús Carranza, Moderna de La Cruz, 50180 Toluca de Lerdo, Mexico

ARTICLE INFO

Article history:

Received 18 November 2021

Accepted 24 April 2022

Available online xxx

Keywords:

Primary immunodeficiency diseases

IL-12

Central nervous system

Tuberculosis

Pediatric

ABSTRACT

Mendelian Susceptibility to Mycobacterial Disease describes a spectrum of inherited defects, of which complete deficiency of the interleukin-12 receptor β subunit 1 (IL-12R β 1) is the most common cause. This condition results in a predisposition to severe disease caused by mycobacteria. We report a case of disseminated multidrug-resistant tuberculosis with extensive central nervous system affection with SARS-CoV-2 co-infection, in a 4-year-old child with IL-12R β 1 complete deficiency.

© 2022 Tuberculosis Association of India. Published by Elsevier B.V. All rights reserved.

[☆] All authors contributed to the writing of the final manuscript and acquisition of data.

* Corresponding author. Av. Insurgentes Sur 3877, Col. La Fama, Tlalpan, Ciudad de México, 14269, Mexico. Tel.: +52 5556063822

E-mail addresses: dsanjuan@innn.edu.mx (D. San-Juan), mpmisa@gmail.com (M. Pérez Melgoza), zavaletadr@yahoo.com.mx (O. Zavaleta Martínez), raulaguilarneuro@gmail.com (R.A. López), alvarooow98@hotmail.com (A.C. Salazar), mandodmb98@hotmail.com (J.M. Bastida), ral.miranda@outlook.com (R.M. Ojeda).

<https://doi.org/10.1016/j.ijtb.2022.04.008>

0019-5707/© 2022 Tuberculosis Association of India. Published by Elsevier B.V. All rights reserved.

1. Introduction

Complete deficiency of the interleukin-12 receptor β subunit 1 (IL-12R β 1 or MIM:614891) is the most common genetic etiology of Mendelian Susceptibility to Mycobacterial Disease (MSMD).¹ To present, only 213 patients from 164 families worldwide have been reported to have complete IL-12R β 1 deficiency and possibly many others may have been diagnosed.² Mycobacterial disease is the most prevalent infection in IL-12R β 1 deficiency due to an increased susceptibility to the manifestation of severe type infection in these patients and has been reported in 80% of them.^{2,3} Complete IL12R β 1 deficiency has incomplete clinical penetrance; In other words, some patients are asymptomatic.⁴

Each year, 1 million children contract tuberculosis (TB), of whom 210,000 die because of the disease. Approximately 10% of all TB cases have been reported to occur in children, and in this age group deaths are usually caused by Central Nervous System (CNS) TB or disseminated disease.⁵

To our knowledge, only three patients with IL-12R β 1 deficiency and disseminated multidrug-resistant tuberculosis with CNS TB have been reported.^{3,6,7}

We reported a child with disseminated multidrug-resistant tuberculosis and SARS-CoV-2 co-infection due to IL-12R β 1 deficiency.

2. Case report

A 4-years-old child, born in March 2021, the second son of a non-consanguineous marriage, from Tenango del Valle, México. He was premature (32 weeks). Neonatal screening test of congenital hypothyroidism, galactosemia, adrenal hyperplasia, phenylketonuria, and biotinidase deficiency, was normal and his sibling is healthy. Neurodevelopment was normal. History of non-specified severe infections in her family and any other relevant medical information.

He received BCG vaccine at birth, and 3 months later a local edema appeared, which self-resolved one month later without treatment. Seven months later, showed 2 retro auricular masses that got resolved without treatment. In June 2019 (at 2 years), a regional left armpit lymphadenitis due to BCGitis was diagnosed, and received rifampicin for unknown time without improvement.

On April 2020, the patient was remitted for the first time to our hospital and a ganglionic tuberculosis was diagnosed by a lymph node biopsy. Blood cell count analysis showed leukocytosis, neutrophilia, and lymphocytosis and was treated for nine months with isoniazid (6 mg/kg/day), rifampicin (12mg/kg/day), pyrazinamide (32mg/kg/day), and ethambutol (24mg/kg/day). On January 3rd 2021, at the age of 3 years, presented non-productive cough, rhinorrhea and odynophagia, treated with symptomatic drugs. Ten days later, arrived to our hospital presenting tachypnea, tachycardia, fever, and oxygen desaturation (84%) and then SARS-CoV-2 infection was detected by a quantitative polymerase chain reaction on January 19th. The patient had a favorable evolution and did not require invasive mechanical ventilation nor aminergic support.

After recovering from SARS-CoV-2 infection, the patient had persistent fever and paroxysmal hemoptysis requiring blood transfusion on January 21st; and ceftriaxone IV 75mg/kg/12hrs was initiated. Simple and contrasted computed tomography (CT) scans found bilateral pleural effusions and brain abscesses, so thoracentesis, gastric liquid sampling and drainage of brain abscesses were done on January 22nd. Bacilloscopy and GenExpert analysis were positive to *Mycobacterium tuberculosis* resistant to rifampicin and isoniazid in the brain abscess and pleural effusions. Serology for HIV, HBV, HCV and adenosine deaminase in pleural liquid, were normal. Levofloxacin (20mg/kg/day), amoxicillin with clavulanic acid (75mg/kg/day), linezolid (20mg/kg/day), propionamid (18mg/kg/day), cicloserin (18mg/kg/day) and fluconazole (6mg/kg/day) were given.

Additional 15ml of drainage of a brain abscess was done on February 5th 2021. Another head CT done on February 11th found a new brain abscess nearby the ventricular wall (15.7 × 22.25mm). On February 15th, Chronic granulomatous disease was ruled out after negative results of the reduction of nitroblue tetrazolium and dihydroergotamine techniques. A flow cytometry showed a low count of CD4 and CD3 lymphocytes.

On March 13th, the patient developed intracranial hypertension by hydrocephalus; and a third ventricle ventriculostomy was performed the next day without improvement, therefore a ventriculoperitoneal shunt was performed the same day. On March 24th another microsurgical resection of brain abscesses was done without any incident.

On April 29th the expression of IL-12R and Interferon gamma receptor 1 (IFN- γ R1) was assessed in the patient and in his family members using flow cytometry. Expression of IFN- γ R1 and IL-12R β 2 were normal. However, no expression of IL-12R β 1 was found in the patient's CD3+ T lymphocytes, and was minor in his family compared to control.

Functionality of the IL-12R was assessed measuring IFN- γ production in response to recombinant human interleukin 12 (rhIL12) and phytohemagglutinin (PHA) (Fig. 1). The patient and his parents showed decreased production of IFN- γ in response to any of the given stimuli compared to control, especially with the combination of rhIL12 and PHA. Interestingly, his sibling showed increased basal production of IFN- γ and higher response to PHA and rhIL12 given alone compared to control.

Functionality of the IFN- γ R was assessed measuring tumoral necrosis factor alpha (TNF- α) production in response to lipopolysaccharide and IFN- γ at different concentrations (Fig. 2). All the subjects showed adequate response to any of the given stimuli.

In summary, an IL-12R β 1 receptor complete deficiency was diagnosed in our patient.

Subsequently, right tempo-parieto-occipital tuberculomas were found and resected on May 11th and June 12th 2021. On July 1st, the patient was re-admitted to our hospital and a magnetic resonance imaging (MRI) of the head showed multiple brain abscesses (Fig. 3). On July 7th, the patient went through a non-successful resection of a fourth ventricle tuberculoma (Fig. 3).

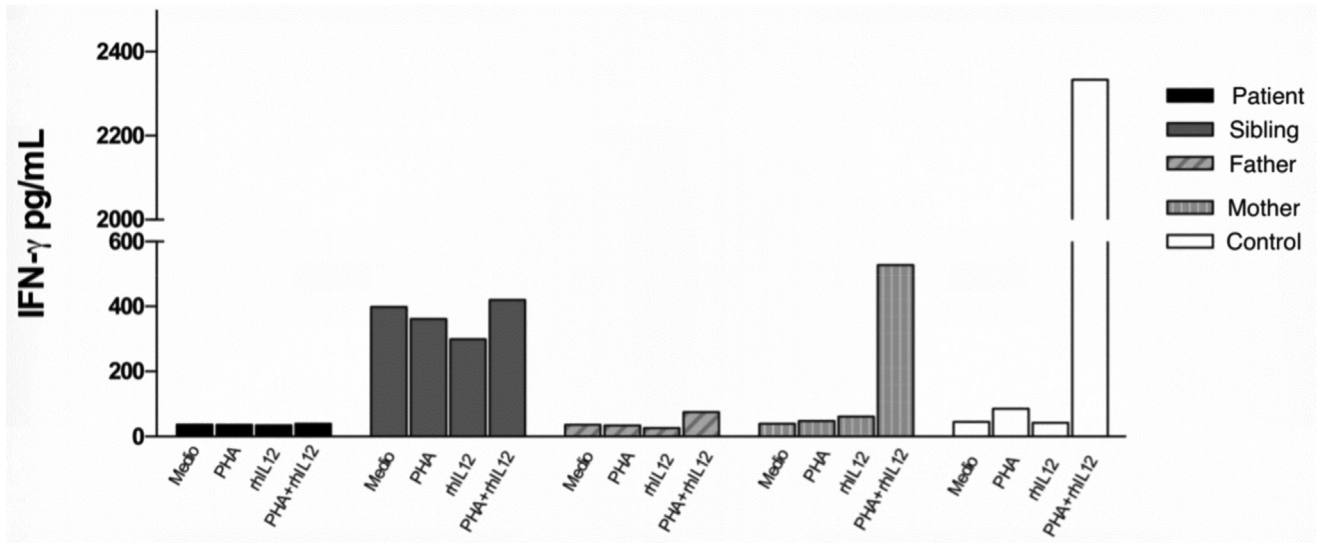


Fig. 1 – Evaluation of the functionality of IL-12R by IFN- γ production. The patient showed decreased production of IFN- γ demonstrating defects in the function of the IL-12R.

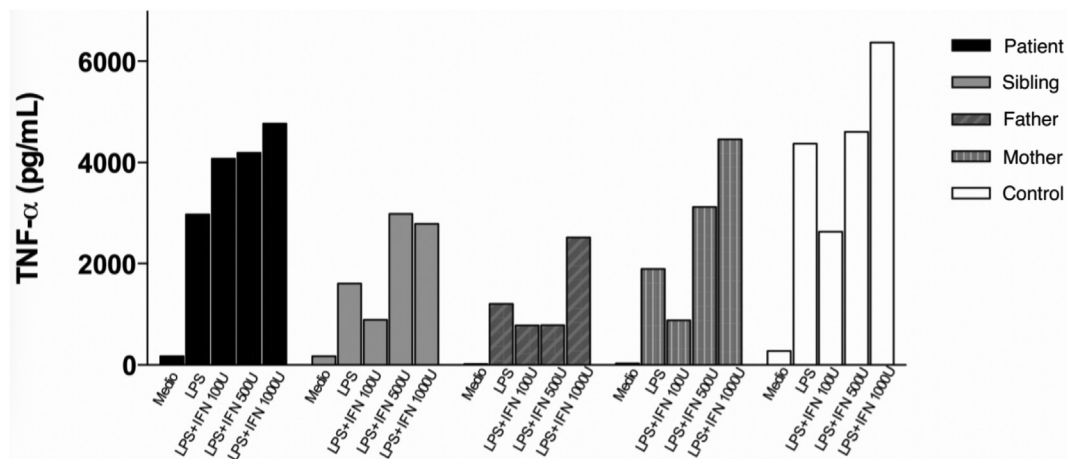


Fig. 2 – Evaluation of the functionality of IFN- γ R by TNF- α production. The patient showed adequate production of TNF- α demonstrating correct function of the IFN- γ R.

3. Discussion

We present the diagnosis and clinical evolution of a child with complete IL-12 R β 1 deficiency. CNS TB is one of the most devastating clinical manifestations of TB and is associated with higher mortality.⁸ Tuberculomas, together with leptomeningitis, are the most frequent tuberculous lesions. They are responsible for 10–30% of intracranial expansive processes in endemic countries, and a higher risk of CNS TB is described in children younger than 5 years and patients under immunosuppression, such as HIV-positive patients or any other cause of immunodeficiency such as MSMD.⁶

Previously, a six-year-old child from a town nearby our patient's residence presenting defects in the IL12/IL-23/IFN- γ

axis, as well as disseminated TB was reported.⁴ It is important to detect if there is a founder effect in the immunological deficiency between both patients. Similarly, there are three cases reported in India, Iran and Turkey with similar neurological pictures due to TB infection because of MSMD.^{3,6,7}

However, unlike previously published cases, our patient showed substantially more severe neurological manifestations which have led him to be surgically intervened by the neurosurgery service on multiple occasions. All the patients reported above were vaccinated with BCG and had developed BCGitis.^{3,4,6,7}

The basic model is that macrophages are infected by mycobacteria, leading to the elaboration of IL-12 by the infected cell. IL-12 acts on the IL-12 receptor on T and NK cells to elaborate interferon-gamma (IFN γ). IFN- γ , in turn, acts on

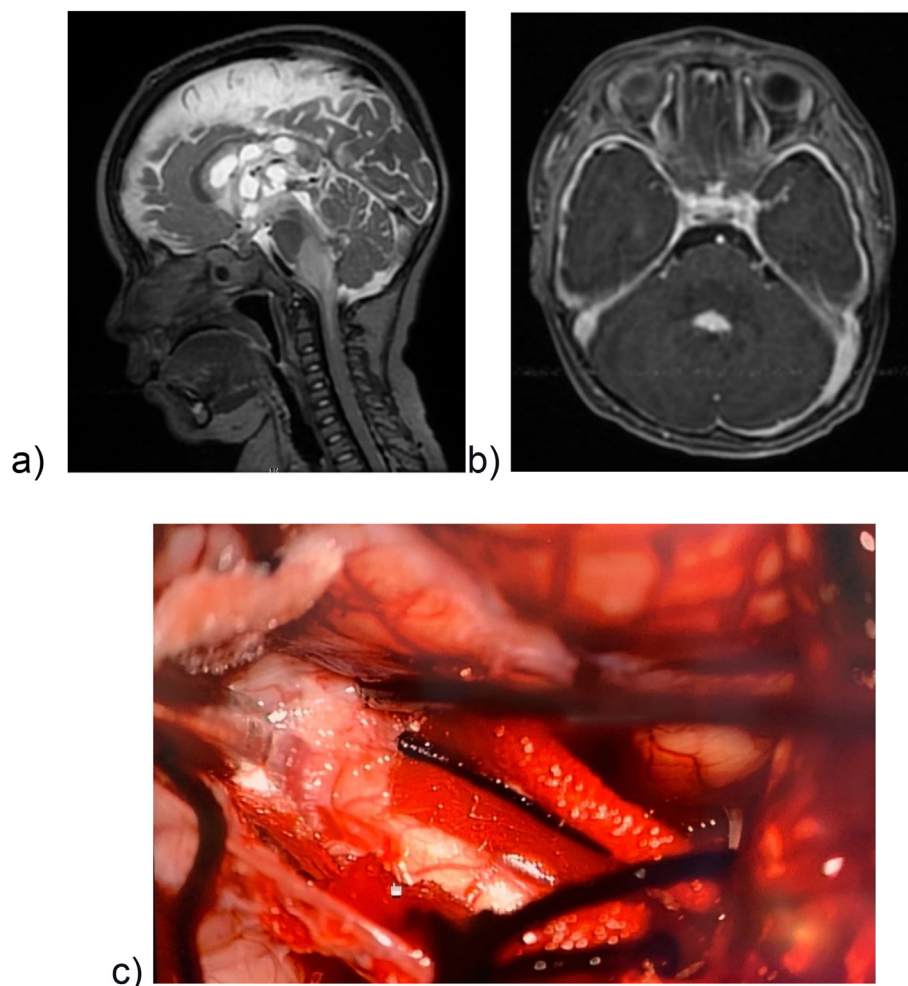


Fig. 3 – Brain abscesses and fourth ventricle tuberculoma. a) Sagittal T2 MRI showing multiple brain abscesses b) Transverse MRI enhanced with Gd showing a tuberculoma located in the fourth ventricle. c) Intraoperative visualization of the tuberculoma.

the initiating macrophage through its interferon-gamma receptor phosphorylating the signal transducer and activator of transcription 1 (STAT1) and upregulating IFN γ responsive genes. Co-expression of both β 1 and β 2 subunits is required for IL-12 binding and high-affinity signaling.⁹ IL-12R β 1 also combines with IL-23R to transmit the IL-23 signal, and therefore, mutations in IL-12p40 and IL-12R β 1 affect IL-23 signaling as well.^{3,4}

There are multiple ways in which diagnosis of complete deficiency IL-12R can be made. Among the options is the evaluation of the expression of IL-12R β 1 by Real-time PCR. Another option is a whole-exome sequencing revealing where the molecular alteration lies.²

There is a standardized procedure for the evaluation of the IL-12R β 1 expression by fluorescence-activated cell sorting and stimulation of T cells by rhIL12 and PHA to assess the production of IFN- γ .¹⁰ These are the methods whereby diagnosis was achieved in our patient.

Treatment remains in debate because no evidence demonstrates the superiority of any treatment against others. In some cases, it has been reported the use of IFN- γ , prophylactic antimicrobials, and hematopoietic progenitor cell transplantation.¹¹

However, due to the lack of solid evidence, none of the treatments mentioned above was implemented in our patient.

4. Limitations

Unfortunately, due to limitations in processing samples in our institution, the precise genetic mutation in our patient could not be identified. However, IL-12R β 1 deficiency could be addressed by assessing the expression and function of the IL-12R and IFN- γ R1 in the patient's CD3+ T lymphocytes.

Conflicts of interest

All authors have none to declare.

REFERENCES

1. Bustamante J. Mendelian susceptibility to mycobacterial disease: recent discoveries. *Internet Hum Genet*; 2020 Jun 1

- [cited 2021 Jul 11];139(6–7):993–1000. Available from: <https://pubmed.ncbi.nlm.nih.gov/32025907/>.
- Rosain J, Oleaga-Quintas C, Deswarte C, et al. A variety of Alu-mediated copy number variations can underlie IL-12R β 1 deficiency. *Internet J Clin Immunol*; 2018 Jul 11 [cited 2021 Jul 21];38(5):617–27. Available from: <https://pubmed.ncbi.nlm.nih.gov/29995221/>.
 - Merchant RH, Ahmed J, Ahmad N. XDR TB in a case of IL12R β 1 deficiency: a case report of Mendelian Susceptibility to Mycobacterial Disease from India. *Indian J Pediatr*. 2013 Sep;80(9):781–782.
 - Allen-Manzur JG, Espinosa-Padilla SE, Bustamante J, Blancas-Galicia L, Mendieta-Flores E. Infección diseminada por vacuna con bacilo de Calmette-Guérin y coinfección por SARS-CoV-2 en paciente con deficiencia de la subunidad β 1 del receptor de IL-12. *Internet Rev Alerg Mex*; 2020 Feb 1 [cited 2021 Jul 8];67(4):401–7. Available from: <https://revistaalergia.mx/ojs/index.php/ram/article/view/798>.
 - Lamb G, Starke J. Tuberculosis in infants and children. *Internet Microbiol Spectr*; 2017 Jan 1 [cited 2021 Jul 11];5(2):553–7. Available from: <https://pubmed.ncbi.nlm.nih.gov/28387193/>.
 - Alinejad Dizaj M, Mortaz E, Mahdavian SA, et al. Susceptibility to mycobacterial disease due to mutations in IL-12R β 1 in three Iranian patients. *Immunogenetics*. 2018 Jun;70(6):373–379.
 - Akar H, Kose M, Ceylan O, et al. Congenital IL-12R1 β receptor deficiency and thrombophilia in a girl homozygous for an IL12RB1 mutation and compound heterozygous for MTFHR mutations: a case report and literature review. *Internet European journal of microbiology & immunology*. 2014;4. *Eur J Microbiol Immunol (Bp)* <https://pubmed.ncbi.nlm.nih.gov/24678409/> [cited 2021 Jul 19]. p. 83–7. Available from:..
 - Leonard JM. Central nervous system tuberculosis. *Internet*. In: Schlossberg D, ed. *Microbiol Spectr*; 2017. Mar 10 [cited 2021 Jul 9];5(2). Available from: <https://pubmed.ncbi.nlm.nih.gov/28281443/>.
 - Holland SM. Interferon gamma, IL-12, IL-12R and STAT-1 immunodeficiency diseases: disorders of the interface of innate and adaptive immunity. *Immunol Res*. 2007;38(1) [Internet]. 2007 Jun 7 [cited 2021 Jul 8];38(1):342–6. Available from: <https://link.springer.com/article/10.1007/s12026-007-0045-8>.
 - Pourakbari B, Hosseinpour Sadeghi R, Mahmoudi S, Parvaneh N, Keshavarz Valian S, Mamishi S. Evaluation of interleukin-12 receptor β 1 and interferon gamma receptor 1 deficiency in patients with disseminated BCG infection. *Allergol Immunopathol*. 2019 Jan 1;47(1):38–42.
 - Patel S, Uppuluri R, Vellaichamy Swaminathan V, Ravichandran N, Melarcode Ramanan K, Raj R. Mendelian susceptibility to mycobacterial disease-Challenges in hematopoietic stem cell transplantation. *Pediatr Blood Cancer*. 2020 May;67(5), e28187.