

RESEARCH

Open Access



Morphometric assessment of spleen dimensions and its determinants among individuals living in Arba Minch town, southern Ethiopia

Solomon Demissie^{1*}, Prasad Mergu², Tadiwos Hailu³, Getachew Abebe¹, Mengistu Warsa⁴ and Teshale Fikadu⁵

Abstract

Introduction: The spleen is a vital lymphoid soft organ that demands constant attention from the clinical point of view. It is a multi-dimensional organ that enlarges in its all dimensions during some disease condition. The detection of the spleen by palpation is not an indicator of an enlarged spleen because normal spleen may be palpable. Therefore, this study aimed to assess the morphometry of spleen dimensions and its determinants among individuals living in Arba Minch town by sonographic examinations.

Methods and materials: Community-based cross-sectional study was conducted in Arba Minch town from February 1 to March 30, 2020. Seven hundred and eight study participants were selected using a multi-stage systematic random sampling technique. Data were checked for completeness, edited, coded and entered into Epi-Data version 3.1 and exported to STATA software version 16 for analysis.

Result: The mean splenic length, width, thickness and volume were 10.24 cm, 4.79 cm, 3.93 cm, and 109.34 cm³, respectively. The mean spleen length, width, thickness and volumes among males were 10.64 cm, 4.92 cm, 4.05 cm and 119.81 cm³ and among females were 9.75 cm, 4.63 cm, 3.78 cm and 96.50 cm³ respectively. As age increased by one year the mean spleen length, width, thickness and volume was decreased by 0.032 cm, 0.018 cm 0.004 cm and 0.012 cm respectively. As height increased by 1 cm the mean spleen width and volume were increased by 0.096 cm and 0.052 cm respectively. As we go from male to female the mean spleen length decreased by 0.294 cm.

Conclusion: The spleen dimensions were higher in males than females. Splenic length was determined by age & sex, the spleen width was determined by age & height, the spleen volume was determined by age & height and the spleen thickness was determined by age.

Keywords: Morphometry, Spleen dimensions, Arba Minch

Introduction

The spleen is the largest lymphoid organ located in the left hypochondrium between the fundus of the stomach and the diaphragm where it is entirely covered by the inferior thoracic rib cage [1]. It extends from the 9th–11th ribs on the left side with its long axis runs parallel to the 10th rib [2, 3]. Its shape is ovoid-like with a convex outer diaphragmatic surface and an indented inner

*Correspondence: sol12162129@gmail.com

¹ Department of Clinical Anatomy, College of Medicine and Health Science, Arba Minch University, Arba Minch, Ethiopia
Full list of author information is available at the end of the article



visceral surface related to the stomach, left kidney, pancreatic tail, left suprarenal gland and left colic flexure [4]. The apex lies in line with the spine of the 10th thoracic vertebra about 4 cm from the midline and the base does not descend beyond the midaxillary line [4].

The spleen is an encapsulated intraperitoneal organ entirely covered with peritoneum except for its hilum where the splenic branches of the splenic artery and vein enter and leave [5]. It is supported by a phrenico-colic ligament from the bottom. It is anchored to the stomach by gastro-splenic ligament and to the left kidney by a lien renal ligament [6].

In diseases condition spleen enlarges at different rates in its all dimensions. A variety of diseases condition alters spleen dimensions, where splenomegaly and its consequence becomes a primary clinical concern in developing countries [7]. It is commonly seen in about 63% of patients with Pulmonary arterial hypertension [8], Infectious Mononucleosis [9], malaria [10], lymphoma [11], kala-azar [12], typhoid fever [13], liver disease (hepatitis and cirrhosis) [14], haematological diseases, metabolism diseases and cancer [15]. The altered splenic dimensions and structure during these diseases result in asymptomatic enlargement and complications such as hematoma formation, rupture, hypersplenism, ectopic spleen, and torsion that affect other adjacent organs [16].

Splenic atrophy is also another common problem seen in diseases like sickle cell anaemia where the progressive atrophy as a result of repeated attacks of vaso-occlusion and infarction caused by these diseases leads to auto splenectomy [17].

The average dimensions of the spleen are 12.5 cm, 7.5 cm and 2.5 cm in length, width and thickness respectively and 150–200 g in weight, but its dimensions vary considerably [18]. The literature revealed that spleen dimensions are affected by geographical differences, races, nutritional status and anthropometric measurements [19–21].

In clinical practice, palpation is commonly used to detect spleen enlargement. However, detection of spleen by palpation is not reliable or (not accurate) and might lead to misdiagnosis [2, 22, 23]. Palpable spleen is not pathological for some individuals [24]. Moreover, enlarged spleen below 40% increment might not be detected by palpation [25].

Although, literatures indicates radiological imaging modalities like ultrasound can detect the extent, complications, and classify the severity of cases, yet enough attention is not given in clinical practice [26]. On sonographic examinations, the spleen is crescent-shaped with smooth and convex outer margin and irregularly indented inner margin. Its echotexture is homogeneous isoechogenic and is the same or very similar to that of the

healthy liver tissue, and similar to or slightly lower than the echotexture of the renal cortex, or markedly higher than that of the renal medulla [27].

Even though there are several studies in which the spleen dimensions have been analysed in many countries, there is still a lack of adequate information in African populations including Ethiopia. Therefore, the study was aimed to assess the morphometry of spleen dimensions and to determine its variations with sex, age, height, weight, body mass index (BMI), and body surface area (BSA) among individuals living in Arba Minch town.

Methods and materials

The community-based cross-sectional study was conducted from February 1 to March 30, 2020, in Arba Minch town, Southern Nations, Nationalities and Peoples Region (SNNP) which is located at an altitude of 1285 m above sea level and 437 km south of Addis Ababa (capital city of Ethiopia).

The data was collected using data collection checklist. The data collection checklist was developed in English after reviewing different literature and the face validity was assessed by a public health specialist, radiologist and anatomist. The checklist was composed of socio-demographic factors (age and sex); anthropometric measurements (height, weight, BSA and BMI) and spleen dimensions (length, width, thickness and volume).

Seven hundred and eight individuals (390 males and 318 females) fulfilling inclusion criteria were selected by multi-stage systematic random sampling technique. During the procedures, individuals were first selected randomly at household levels by distributing questionnaires which include the inclusion criteria. Then the individuals fulfilling the inclusion criteria were sent to the nearest health center or selected private clinics for clinical and sonographic examination. During examinations, history and physical examination of individuals were taken before sonographic examination by physician. Then sonographic examinations were performed by two radiology technologists using portable and stationary ultrasound machines equipped with 3.5 MHz convex probes. During sonographic examination, the subjects were examined in the supine or right oblique positions. After assessment of overall abdominal sonographic examinations, the spleen dimensions measurements were performed for those with no case findings. The measurement was performed during suspended respiration. The splenic length was measured in a longitudinal plane between the dome of the spleen and the splenic tip [3, 28] (Fig. 1). The splenic width was also measured in a longitudinal plane perpendicular to the length between the medial and lateral borders of the spleen [20] (Fig. 1). The splenic thickness

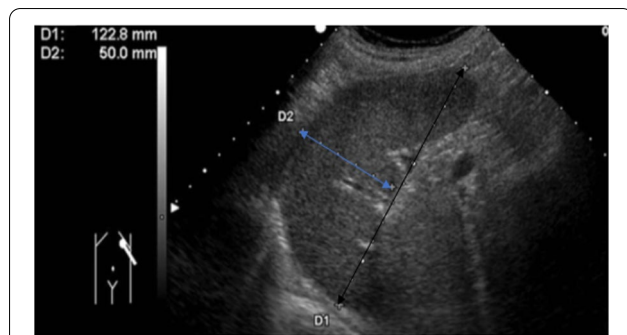


Fig. 1 Spleen length (black arrow) and width (blue arrow) measured on longitudinal ultrasound scan

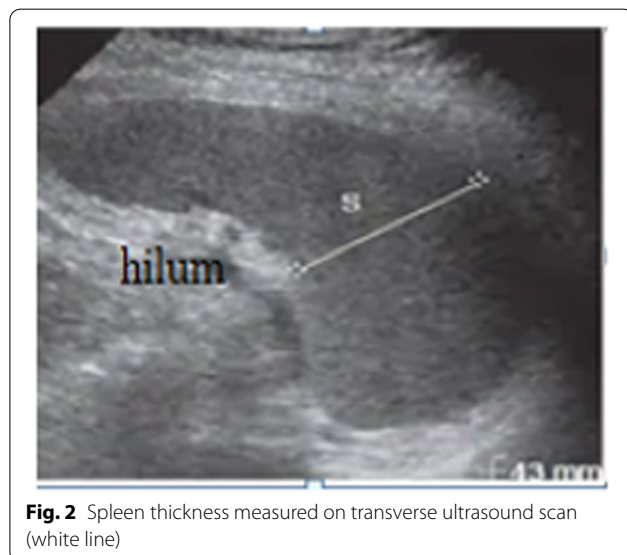

Fig. 2 Spleen thickness measured on transverse ultrasound scan (white line)

was measured on the transverse plane from the posterior margin to the anterior margin [18] (Fig. 2). The volume was calculated using the ellipsoid formula during the analysis [29, 30]. The spleen dimensions were measured three times and recorded on the checklist then the average value was taken during analysis [31]. Finally, the baselines data including age and sex were recorded for all participants. The height and weight were measured with the stadiometer and weighing machine for all participants respectively. BSA and BMI were calculated during the analysis.

Inclusion and exclusion criteria

Inclusion criteria

All apparently healthy individuals and age greater than 13 years [32].

Exclusion criteria

- Individuals with a recurrent clinical history of malaria
- Recurrent history of typhoid fever
- Individuals with a history of infections (infectious mononucleosis, kala-azar, endocarditis, sarcoidosis, toxoplasmosis).
- Recent history of upper abdominal surgery
- Individuals with any case finding on sonographic examinations (cirrhosis, melanoma, lymphoma, metastasis, any cystic or solid massive lesions)
- Individuals with Diabetic Mellitus (DM) cases.
- Hypertensive individuals
- Individuals with a history of heart disease
- Individuals with a recent abdominal traumatic condition (within the previous 6 months)
- Pregnant women
- History of sickle cell anaemia
- Very old age

Operational definitions

Apparently healthy individuals: is defined as the absence of disease based on clinical signs and symptoms of individuals assessed by history, physical evaluation and sonographic examinations [33, 34].

Data analysis

Data was checked for completeness, edited, coded and entered into Epi-Data version 3.1 and exported to STATA software version 16 for analysis. A descriptive summary was used to present the result. Independent-Samples t-test was conducted to compare the mean spleen dimensions among sex and one-way ANOVA was conducted to compare the mean spleen dimensions among age groups. T and F statistics were calculated and $p < 0.05$ was taken as statistically significant. Linear regression model were fitted to identify determinants of spleen dimension. Square root and logarithmic transformation were used for thickness and volume respectively to full fill the assumption of linear regression.

Result

A total of 708 participants were included in the current study with a 100% response rate. The mean splenic length, width, thickness, and volume were 10.24 ± 1.45 cm, 4.79 ± 0.99 cm, 3.93 ± 1.05 cm, and 109.34 ± 61.68 cm³, respectively (Table 1).

Table 1 Average spleen dimensions of study participants living in Arba Minch town, 2020

Variable	n	Mean	SD	[95%_CI]	
Length	708	10.24	1.45	10.14	10.35
Width	708	4.79	0.99	4.72	4.86
Thickness	708	3.93	1.05	3.85	4.01
Volume	708	109.32	61.69	104.77	113.87

Table 2 Socio demographic characteristics of study participant living in Arba Minch town, 2020

Variable	Frequency	Percent
Sex of the respondent		
Male	390	55.08
Female	318	44.92
Age of the respondent		
11–20	130	18.36
21–30	278	39.27
31–40	154	21.75
41–50	66	9.32
≥50	80	11.30
BMI of the respondent		
Under weight	40	5.65
Normal weight	584	82.49
Over weight	84	11.86

Table 3 Anthropometric measurement of the study participants living in Arba Minch town, 2020

Variable	N	Mean	SD	Min	Max
Height	708	167.56	6.69	150	188
Weight	708	61.75	8.23	44	89
BMI	708	21.98	2.53	14.82	30.675
BSA	708	1.44	0.23	0.95	2.213

Table 4 Comparison of spleen dimensions by sex among individuals living in Arba Minch town, 2020

	Male(1)	Female(2)	Mean1	Mean2	Difference	SE	t value	p value
Length	390	318	10.64	9.75	0.89	.104	8.55	0.01
Width	390	318	4.92	4.63	0.28	.074	3.75	0.01
Thickness	390	318	4.05	3.78	0.27	.079	3.45	0.01
Volume	390	318	119.77	96.50	23.27	4.581	5.1	0.01

Socio-demography

The mean age of the study participant was 32.28 ± 13.17 years. More than one half of the respondent were males (55.08%) and more than one third

(39.3%) were between the age group of 21–30 years. Majority of participants (82.49%) had normal BMI (Table 2).

Anthropometric measurements

The mean height, weight, BMI, and BSA were 167.56 ± 6.69 cm, 61.75 ± 8.23 kg, 21.98 ± 2.53 , and 1.44 ± 0.23 respectively (Table 3).

Comparison of spleen dimensions by sex

The mean spleen length, width, thickness and volume among males were 10.64 cm, 4.92 cm, and 4.05 cm and among females were 9.75 cm, 4.63 cm, 3.78 cm and 96.50 cm³ respectively. Significant differences were observed in spleen dimensions among males and females (Table 4).

Comparisons of spleen dimensions with different age groups

Significant variations were observed in all spleen dimensions among age categories of study participants. Bonferroni test for multiple comparisons found that the change in spleen length was significantly higher for 31–40 years compared to 11–20 years old ($0.62, p=0.002$), 11–20 year compared to >50 years ($0.87, p=0.001$), 21–30 years compared to 41–50 years ($0.66, p=0.006$), 21–30 years compared to >50 years ($1.02, p=0.001$), and 31–40 years compared to 41–50 years ($1.04, p=0.001$). The change in spleen width was significantly higher for 11–20 years compared to >50 years old ($0.55, p=0.001$), 21–30 year compared to >50 years ($0.51, p=0.001$), and 31–40 years compared to >50 years ($0.66, p=0.006$). The change in spleen thickness was significantly higher for 31–40 years compared to 41–50 years old ($0.47, p=0.022$), 11–20 year compared to >50 years ($0.44, p=0.030$), and 31–40 years compared to >50 years ($0.64, p=0.001$). The change in spleen volume was significantly higher for 31–40 years

compared to 41–50 years old ($29.82, p=0.009$), 21–30 year compared to >50 years ($23.34, p=0.025$), and 31–40 years compared to >50 years ($39.75, p=0.001$) (Table 5).

Table 5 Comparison of spleen dimensions with age groups among the study participants living in Arba Minch town, 2020

	Age	Mean	SD	F	p-value	Bonferroni comparison			
						11–20	21–30	31–40	41–50
Length	11–20	10.14	1.21	16.53	0.001				
	21–30	10.38	1.31			0.24			
	31–40	10.76	1.49			0.62	0.38		
	41–50	9.72	1.57			0.42	0.66	1.04	
	≥50	9.36	1.56			0.78	1.02	1.40	0.36
Width	11–20	4.90	0.90	6.43	0.001				
	21–30	4.85	0.92			0.05			
	31–40	4.91	1.08			0.01	0.06		
	41–50	4.54	1.04			0.36	0.32	0.37	
	≥50	4.35	1.08			0.55	0.51	0.56	0.19
Thickness	11–20	4.00	0.87	5.98	0.001				
	21–30	3.90	1.00			0.09			
	31–40	4.20	1.21			0.20	0.30		
	41–50	3.73	1.09			0.27	0.17	0.47	
	≥50	3.56	1.05			0.44	0.35	0.64	0.17
Volume	11–20	109.61	51.77	6.56	0.001				
	21–30	109.65	54.88			0.04			
	31–40	126.05	71.30			16.44	16.40		
	41–50	96.23	69.10			13.38	13.42	29.82	
	≥50	86.30	64.18			23.30	23.34	39.75	9.93

Determinants of spleen dimensions

The splenic length was determined by age and sex, as age increased by one year the mean spleen length was decreased by 0.032 cm. when we compare males and females spleen length the mean spleen length decreased by 0.294 cm in case of female. The splenic width was determined by age and height. As age increased by one year the mean spleen width was decreased by 0.018 cm. As height increased by 1 cm the mean spleen width was increased by 0.096 cm. The splenic thickness was determined by age only. As age increased by one year the mean spleen width was decreased by 0.004 cm. The splenic volume was determined by age and height. As age increased by one year the mean spleen volume was decreased by 0.012 cm. Also as height increased by 1 cm the mean spleen volume was increased by 0.052 cm (Table 6).

Discussion

This study describes the morphometry of spleen dimensions; compare the presence of a significant difference between sex and age. The study also assesses the determinant factors of spleen dimensions. The sonography assessment of spleen dimensions provides essential inputs for clinicians in daily clinical practice for the proper diagnosis of splenomegaly [21, 35, 36]. This study

provides estimates of spleen to help radiologist for the diagnosis of diseases related to splenomegaly and atrophy also used for haematologist and immunologist for the diagnosis of various gastrointestinal and haematological diseases in addition to forensic studies [37–39].

In this study the mean spleen length was 10.24 cm which is consistent with studies conducted in Russia and Kashmir [40, 41]. But, less than from studies conducted in Turkey, Bangladesh, Jordan and North India [29, 42–44]. It is greater than from studies conducted in Nepal, Nigeria, Sudan and Northern Ethiopia [18, 19, 45, 46].

The mean spleen width was 4.79 cm which is less than studies conducted in Bangladesh, Nepal, Kashmir, North India and Nigeria [41, 42, 44–47]. It is greater than from studies conducted in Sudan and Northern Ethiopia [18, 19].

The mean spleen thickness in the current study was 3.93 cm which is consistent with the study conducted in Northern Ethiopia [18]. But, it is less than studies conducted in Russia, Bangladesh, Jordan, Nepal, north India, and Nigeria [29, 40, 42, 44, 45, 47] and it is greater than from a study conducted in Sudan [19].

The mean spleen volume was 109.34 cm³ which is less than studies conducted in Saud Arabia, Russia, Jordan and Nepal [29, 40, 46, 48, 49] and greater than from the studies conducted in Sudan and Ethiopia [18, 19].

Table 6 Determinants of spleen dimensions among individuals living in Arba Minch town, 2020

Length	Coef	SE	t-value	p-value	[95% Conf	Interval]	Sig
Age	-0.032	0.004	-9.15	0.000	-0.039	-0.025	***
Male	Ref						
Female	-0.294	0.095	-3.10	0.002	-0.481	-0.108	***
Height	0.067	0.055	1.21	0.225	-0.041	0.176	
Weight	0.392	0.324	1.21	0.227	-0.245	1.028	
BMI	-0.294	0.369	-0.80	0.425	-1.019	0.43	
BSA	-9.521	8.82	-1.08	0.281	-26.838	7.796	
Width							
Age	-0.018	0.003	-6.54	0.000	-0.023	-0.012	***
Male	0						
Female	0.096	0.074	1.30	0.196	-0.049	0.241	
Height	0.094	0.043	2.18	0.029	0.009	0.178	**
Weight	0.217	0.252	0.86	0.388	-0.277	0.711	
BMI	-0.06	0.286	-0.21	0.833	-0.622	0.502	
BSA	-7.17	6.847	-1.05	0.295	-20.614	6.273	
Thickness							
Age	-0.004	0.001	-5.28	0.000	-0.005	-0.002	***
Male	0						
Female	0.02	0.02	0.98	0.33	-0.02	0.059	
Height	0.017	0.012	1.44	0.15	-0.006	0.04	
Weight	0.096	0.069	1.40	0.162	-0.039	0.231	
BMI	-0.063	0.078	-0.81	0.42	-0.216	0.09	
BSA	-2.786	1.866	-1.49	0.136	-6.449	0.877	
Volume							
Age	-0.012	0.001	-8.30	0	-0.015	-0.009	***
Male	0						
Female	0.017	0.039	0.45	0.652	-0.059	0.094	
Height	0.052	0.023	2.30	0.022	0.008	0.096	**
Weight	0.216	0.132	1.64	0.102	-0.043	0.476	
BMI	-0.117	0.15	-0.78	0.436	-0.413	0.178	
BSA	-6.566	3.596	-1.83	0.068	-13.626	0.495	

*** $p < .01$, ** $p < .05$

The overall dimensional difference of the current study from other studies were probably due to age group difference, geographical differences, nutritional status, physical exercise, and race difference which were stated in different literature [21, 39, 47, 50–52].

The mean spleen length was lower among females than males. This is consistent with the studies conducted in Turkey, Saudi, Nigeria and Sudan [28, 39, 48, 53, 54]. This is due to fewer red cell mass in female and other genetic factors [20, 55]. But, inconsistent with study conducted in Egypt. The difference probably due to nutritional status, where women's gain excess weight than men due to fertility consideration in case of Egypt [56, 57].

As age increase the mean spleen length, width, thickness and volume were decreased. This result is consistent

with the studies conducted in Iraq, Nepal, and India [21, 35, 36, 58, 59]. This is may be due to the decrease of the number and size of B cell follicles of the white pulp of the spleen which decreases with a decrease of germinal center of spleen in older age groups [60–62]. But, inconsistent from the studies conducted in Pakistan, Jordan, and Nigeria [28, 29, 45, 63]. The difference is probably due to nutritional status where larger anthropometric measurements and obesity were observed in the studies of Pakistan, Jordan and Nigeria.

As height increase the mean spleen width and volume also increased. This is consistent with the studies conducted in Jordan, USA, India, and Sudan [19, 20, 29, 44]. This is the fact that as body parameters like height increase, the blood volume also increase that leads to

large spleens for filtration. But, different from the studies conducted in Turkey, Nigeria and Egypt [43, 45, 56, 63]. This may be due to nutritional status where most of the study participants in the studies of Turkey, Nigeria and Egypt were overweight and obese than ours.

Conclusion

The mean value of spleen dimensions for the Arba Minch town community was 10.24 cm, 4.79 cm, 3.93 cm, and 109.34 cm³, in length, width, thickness, and volume respectively. The mean spleen length, width, thickness and volumes among males were 10.64 cm, 4.92 cm, 4.05 cm and 119.81 cm³ and among females were 9.75 cm, 4.63 cm, 3.78 cm and 96.50 cm³ respectively. The study indicated that there is a significant morphometric difference in splenic dimensions between males and females. The mean splenic length was determined by age & sex. The mean spleen width and volume were determined by age & height and the mean Spleen thickness was determined by age only.

Limitation of the study

Despite training on spleen dimensions measurement and repeated measurement were considered it is subjected to intra & inter observer bias. Due to resource limitation presence of illness not exclude using laboratory finding and physical activities not considered in this study. The absence of gold standard (CT and MRI) for the sonographic measurement is the other limitation of the study.

Abbreviations

AOR: Adjusted odd ratio; AP: Antero-posterior; BMI: Body Mass Index; BSA: Body-surface area; CI: Confidence interval; CSA: Central statistical agency; CT scans: Computed tomography scans; IM: Infectious mononucleosis; MHz: Megahertz; MRI: Magnetic resonance imaging; *p*: *p* Value; PAH: Pulmonary arterial hypertension; R: Pearson correlation coefficient; RT: Radiologic technologists; SD: Standard deviation; SNNP: Southern Nations, Nationalities and peoples; SPSS: Statistical Package for the Social Sciences.; US: Ultrasonography; USA: United States of America.

Acknowledgements

The authors would like to acknowledge the Arba Minch University for allowing the study to be conducted and the data collectors for their willingness to collect the data. We would like also to thank Arba Minch town health office, Arba Minch town health centers and private clinics for their full cooperation to conduct our study in their institutions, facilitating study setting and for the unreserved offer of their medical equipment required for the data collection. Lastly, we would like to thank our study participants for their full cooperation to participate in our study.

Authors' contributions

SD conceptualize and designed the study, conducted the analysis, interpret and write the first draft of the paper for publication. GA and MW were involved in the data analysis and interpret the data, and reviewed the manuscript for publication. TF, PM and TH advise and involve in the overall process. All authors read and approve the final manuscript before submission.

Funding

None.

Availability of data and materials

All relevant data are included in the article. The dataset of this study are available from the corresponding authors upon reasonable request.

Declarations

Ethics approval and consent to participate

The ethical approval letter was obtained from Arba Minch University's ethical review board. The letter of cooperation was obtained from the town administration and written informed consent was obtained from the study participants. For participants less than 18 years parental written consent was obtained after informing the purpose of the study. All methods were carried out following relevant guidelines and regulations.

Consent for publication

Not applicable.

Competing interests

The authors declare that they have no competing interest.

Author details

¹Department of Clinical Anatomy, College of Medicine and Health Science, Arba Minch University, Arba Minch, Ethiopia. ²Department of Anatomy, MNR Medical College and Hospital, Sagerddy, Telangana, India. ³Department of Internal Medicine, College of Medicine and Health Science, Arba Minch University, Arba Minch, Ethiopia. ⁴Department of Medicine, Arba Minch General Hospital, Arba Minch, Ethiopia. ⁵Department of Public Health and Epidemiology, College of Medicine and Health Science, Arba Minch University, Arba Minch, Ethiopia.

Received: 9 January 2021 Accepted: 19 November 2021

Published online: 04 December 2021

References

1. Tortora GJ, Nielsen M. Principles of human anatomy: John Wiley & Sons; 2017.
2. Singh A, Chandra N, Ansari H, Das J. Measurement of the spleen width in relation with the height in the adults of Bihar—an ultrasonographic study. *J Anat Sci.* 2016;24:13–7.
3. Benter T, Klühs L, Teichgräber U. Sonography of the spleen. *J Ultrasound Med.* 2011;30(9):1281–93.
4. Moore KL, Dalley A, Agur A. Clinically oriented anatomy II. Philadelphia: Wolters Kluwer Health/Lippincott Williams & Wilkins; 2014.
5. Faiz O, Blackburn S, Moffat D. Anatomy at a glance. John Wiley & Sons; 2011.
6. Frank HN. Netter Atlas of Human Anatomy 7th Ed 2018. Elsevier; 2018.
7. Lv Y, Lau WY, Li Y, Deng J, Han X, Gong X, et al. Hypersplenism: history and current status. *Exp Ther Med.* 2016;12(4):2377–82.
8. Tonelli AR, Yadav R, Gupta A, Arrossi AV, Heresi GA, Dweik RA. Spleen size in idiopathic and heritable pulmonary arterial hypertension. *Respiration.* 2013;85(5):391–9.
9. Kinderknecht JJ. Infectious mononucleosis and the spleen. *Curr Sports Med Rep.* 2002;1(2):116–20.
10. Alkadarou T, Musa A, Alkadarou A, Mahfouz MS, Troye-Blomberg M, Elhasan AM, et al. Immunological characteristics of hyperreactive malarial splenomegaly syndrome in sudanese patients. *J Trop Med.* 2013;2013.
11. Smeltzer J, Habermann TM, Timucin T, Nagorney D, Ristow K, Colgan JP, et al. Long term clinical outcomes in patients with massive splenomegaly and non-hodgkin's lymphoma treated with splenectomy. *American Society of Hematology;* 2012.
12. Varma N, Naseem S. Hematologic changes in visceral leishmaniasis/kala azar. *Indian J Hematol Blood Transfus.* 2010;26(3):78–82.
13. Sahu N, Rath S, Padhy RN. Role of abdominal ultrasound in the diagnosis of typhoid fever in pediatric patients. *J Med Ultrasound.* 2016;24(4):150–3.
14. Chapman J, Bansal P, Goyal A, Azevedo AM. Splenomegaly. 2017.
15. Kienle DL. The spleen in hematologic malignancies. *Therapeutische Umschau Revue therapeutique.* 2013;70(3):163–9.

16. Aubrey-Bassler FK, Sowers N. 613 cases of splenic rupture without risk factors or previously diagnosed disease: a systematic review. *BMC Emerg Med.* 2012;12(1):1–14.
17. Babadoko A, Ibinaye P, Hassan A, Yusuf R, Ijei I, Aiyekomogbon J, et al. Autosplenectomy of sickle cell disease in Zaria, Nigeria: an ultrasonographic assessment. *Oman Med J.* 2012;27(2):121.
18. Tekle Y, Gudadhe DR, Abreha M, Muche A, Tegegne Z, Hiwared SD. Morphometric assessment of the normal dimensions of the adult spleen in North-west Ethiopia Region—a radiological study. *Ann Int Med Dent Res.* 2018;4(4):34.
19. Yousef M. Local Reference of splenic volume in healthy sudanese subjects sonographically. *J Biomed Eng Med Imaging.* 2018;5(4):30.
20. Chow KU, Luxembourg B, Seifried E, Bonig H. Spleen size is significantly influenced by body height and sex: establishment of normal values for spleen size at US with a cohort of 1200 healthy individuals. *Radiology.* 2016;279(1):306–13.
21. Chakraborti S, Saha N, Debbarma B, Das S, Leishram D. Normal spleen length by ultrasonography in adults of Tripura. *IOSR J Dent Med Sci.* 2016;15(1):55–60.
22. Spielmann AL, DeLong DM, Kliewer MA. Sonographic evaluation of spleen size in tall healthy athletes. *Am J Roentgenol.* 2005;184(1):45–9.
23. Stewart KR, Derck AM, Long KL, Learman K, Cook C. Diagnostic accuracy of clinical tests for the detection of splenomegaly. *Phys Ther Rev.* 2013;18(3):173–84.
24. Arkles LB, Gill GD, Molan MP. A palpable spleen is not necessarily enlarged or pathological. *Med J Aust.* 1986;145(1):15–7.
25. Blackburn C. On the clinical detection of enlargement of the spleen. *Australas Ann Med.* 1953;2(1):78–80.
26. Vancauwenberghe T, Snoeckx A, Vanbeckevoort D, Dymarkowski S, Vanhoenacker FM. Imaging of the spleen: what the clinician needs to know. *Singapore Med J.* 2015;56(3):133.
27. Lutz H, Buscarini E, Organization WH. Manual of diagnostic ultrasound/edited by Harald Lutz, Elisabetta Buscarini. Manual of diagnostic ultrasound/edited by Harald Lutz, Elisabetta Buscarini 2011.
28. Ehimwenma O, Tagbo MT. Determination of normal dimension of the spleen by ultrasound in an endemic tropical environment. *Nigerian Med J.* 2011;52(3):198.
29. Badran DH, Kalbouneh HM, Al-Hadidi MT, Shatarat AT, Tarawneh ES, Hadidy AM, et al. Ultrasonographic assessment of splenic volume and its correlation with body parameters in a Jordanian population. *Saudi Med J.* 2015;36(8):967.
30. Kodikara S, Nanayakkara B, Nanayakkara B, Ilayperuma I. Splenic morphometry in a group of Sri Lankan adult population—a preliminary cadaveric study. *Sri Lanka Anat J.* 2017;1(1):1.
31. Eze CU, Agwu K, Ezeasor D, Ochie K, Aronu A, Agwuna K, et al. Sonographic biometry of spleen among school age children in Nsukka, Southeast, Nigeria. *Afr Health Sci.* 2013;13(2):384–92.
32. Özdikici M. The relationship between splenic length in healthy children from the Eastern Anatolia Region and sex, age, body height and weight. *J Ultrasonogr.* 2018;18(7):5.
33. Organization WH. Vitamin and mineral requirements in human nutrition: World Health Organization; 2004.
34. Ustinova OI. "Apparently healthy human being"-the necessity to refine the notion. *Life Sci J.* 2014;11(10):524–6.
35. Arora N, Sharma P, Sahai A, Singh R. Sonographic measurements of the spleen in relation to age; a prospective study in north Indian adults. *J Anat Soc India.* 2010;59(2):177–81.
36. Sharma K, Lamichhane P, Sharma B, Sharma B. Sonographic measurement of spleen in relation to age: a prospective study among adult Nepalese people in Western Nepal. *J Gandaki Med College-Nepal.* 2017;10(1):11–6.
37. Okuma H, Gonoji W, Ishida M, Shiota G, Kanno S, Shintani Y, et al. Comparison of volume and attenuation of the spleen between post-mortem and antemortem computed tomography. *Int J Legal Med.* 2016;130(4):1081–7.
38. Palmiere C, Tettamanti C, Scarpelli MP, Tse R. The forensic spleen: morphological, radiological, and toxicological investigations. *Forensic Sci Int.* 2018;291:94–9.
39. Çeliktas M, Özandaç S, Göker P, Bozkir MG. Sonographic determination of normal spleen size in Turkish adults. *Int J Morphol.* 2015;33(4):1401–5.
40. Izranov V, Palvanova U, Gordova V, Perepelitsa S, Morozov S. Ultrasound criteria of splenomegaly. *Radiologist.* 2019;1(1002):3–6.
41. Gul S, Itoo MS, Jahangir M, Kamal Y. Sonologic Assessment of Dimensions of Spleen in Normal Adult Kashmiri Population and their Correlation with Weight and Height.
42. Paul FN, Taher MA, Roy SK, Sarkar S, Sultana S. Splenic volume: Correlation between ultrasonogram and standard CT measurements. *Bangladesh Med Res Counc Bull.* 2017;43(2):58–62.
43. Serter S, Ceylan C, Tunçyürek Ö, Örgüç Ş, Pabuççu Y. Sonographic evaluation of spleen size and prevalence of accessory spleen in a healthy male Turkish population. *Turk J Hematol.* 2010;27(1):25–8.
44. Asghar A, Naaz S, Agrawal D, Sharma P. Morphometric study of spleen in North Indian adult population: CT Scan image based study. *J Clin Diagn Res.* 2011;5(5).
45. Mustapha Z, Tahir A, Tukur M, Bukar M, Lee W-K. Sonographic determination of normal spleen size in an adult African population. *Eur J Radiol.* 2010;75(1):e133–5.
46. Chhetri P, Poudel S. Normal splenic volume assessment on CT in Nepalese population. *Abdom Radiol.* 2018;43:2455–61.
47. Caglar V, Alkoc O, Uygur R, Serdaroglu O, Ozen O. Determination of normal splenic volume in relation to age, gender and body habitus: a stereological study on computed tomography. *Folia Morphol.* 2014;73(3):331–8.
48. Siddiqui MA, Ali A, Serhan O. Estimation of standard splenic volume in Saudi Arabian adult population: using 3D reconstruction of Abdominal CT scan Images. *J Morphol Sci.* 2015;32(04):227–30.
49. Alhazmi D, Mazi O, Alsulami A, Abduljabbar A. Normal size and values in adult population in the western region of Saudi Arabia. *Eur J Pharm Med Res.* 2017;4(2):166–9.
50. Sonmez G, Ozturk E, Basekim CC, Mutlu H, Kilic S, Onem Y, et al. Effects of altitude on spleen volume: sonographic assessment. *J Clin Ultrasound.* 2007;35(4):182–5.
51. Purdy GM, James MA, Rees JL, Ondrus P, Keess JL, Day TA, et al. Spleen reactivity during incremental ascent to altitude. *J Appl Physiol.* 2019;126(1):152–9.
52. Shepherd RJ. Responses of the human spleen to exercise. *J Sports Sci.* 2016;34(10):929–36.
53. Yousif JM. Measurement of normal spleen in Sudanese by using ultrasonography: Sudan University of Science and Technology; 2016.
54. Udoaka A, Enyi C, Agi C. Sonological evaluation of the liver, spleen and the kidneys in an adult southern Nigerian population. *Asian J Med Sci.* 2013;5(2):33–6.
55. Murphy WG. The sex difference in haemoglobin levels in adults—mechanisms, causes, and consequences. *Blood Rev.* 2014;28(2):41–7.
56. Ahmed OF. Assessment of normal hepatosplenic span using ultrasound in Egyptian population. *Nat Sci.* 2017;15(8):215–9.
57. Galal OM. The nutrition transition in Egypt: obesity, undernutrition and the food consumption context. *Public Health Nutr.* 2002;5(1a):141–8.
58. Mittal R, Chowdhary D. A pilot study of the normal measurements of the liver and spleen by ultrasonography in the Rajsthani population. *J Clin Diagn Res.* 2010;4(4):2733–6.
59. Estephan MF, Al-Saadi WI, Funjan MM. Possible anthropometric explanation of age-related changes in splenic volume in a sample of healthy Iraqi individuals using ultrasonography. *Iraqi J Med Sci.* 2012;10(4).
60. Himamoni D, Das T, Talukdar K. Age related histological changes of human spleen. *IJHRMLP.* 2016;3(1):59–61.
61. Turner VM, Mabbott NA. Influence of ageing on the microarchitecture of the spleen and lymph nodes. *Biogerontology.* 2017;18(5):723–38.
62. Alex L, Rajan ML, Xavier B, Jacob P, Rani KD, Lakshmi GV. Microscopic study of human spleen in different age groups. 2015.
63. Khan SA, Yasmeen S, Adil H, Adil SO, Huda F, Khan S. Sonographic evaluation of normal liver, spleen, and renal parameters in adult population: a multicenter study. *J Coll Phys Surg Pak.* 2018;28(11):834.

Publisher's Note

Springer Nature remains neutral with regard to jurisdictional claims in published maps and institutional affiliations.