



ELSEVIER

Contents lists available at ScienceDirect

JSES International

journal homepage: www.jseinternational.org

Walch B2 glenoids: 2-dimensional vs 3-dimensional comparison of humeral head subluxation and glenoid retroversion

Lionel Neyton, MD^{a,*}, Falk Gröger, MD^b, Simon Rattier, MD^c, Yoshihiro Hirakawa, MD, PhD^d

^aRamsay Santé, Hôpital Privé Jean Mermoz, Centre Orthopédique Santy, Lyon, France

^bOberarzt Shoulder Care, FA Orthopädie FMH, Bern, Switzerland

^cCHU Amiens-Picardie, Amiens, France

^dDepartment of Orthopaedic Surgery, Osaka City University Graduate School of Medicine, Osaka, Japan

ARTICLE INFO

Keywords:

Shoulder arthritis
B2 glenoid
Humeral subluxation
Retroversion
2D vs 3D
Planification software

Level of evidence: Level III; Diagnosis Study

Background: The posterior subluxation and glenoid version in Walch B2 glenoids are routinely assessed by 2-dimensional (2D) computed tomography (CT). Different methods of calculation are used to analyze these parameters. Alternatively, the rising use of 3-dimensional (3D) planification tools in arthroplasty requires the clarification if the 3D measurements are equivalent to 2D. The aim of this study was to compare B2 glenoids characteristics between 2D CT assessment method and 3D automated software method.

Methods: CT scans from patients who underwent a shoulder arthroplasty were identified. In the 2D method, measurement of glenoid version was determined. Measurement of the humeral head subluxation (HHS) (scapula axis method) was determined by the percentage of the humeral head posterior to the Friedman line (scapula axis). Three-dimensional analysis allowed an automated segmentation of the humerus and scapula, definition of scapular planes, and determination of glenoid version and HHS.

Results: Fifty-one CT scans met inclusion criteria. The intraobserver and interobserver reliability of the 2D retroversion (RV) and 2D HHS intraclass correlation coefficient was excellent (intraclass correlation coefficient > 0.9). The median RV was 16° [12–20] in 2D and 19° [16–23] in 3D ($P < .0001$). The median subluxation was 71% [66–75] in 2D and 81% [78–86] in 3D ($P < .0001$). Linear regression analysis demonstrated low positive correlation between RV and subluxation in 2D and 3D ($R^2 = 0.31$ and $R^2 = 0.23$, respectively).

Discussion/Conclusion: The assessment of version and HHS in Walch B2 glenoids between 2D CT and a 3D planification were significantly different. Low correlation between RV and HHS was observed (2D and 3D assessment).

© 2022 The Authors. Published by Elsevier Inc. on behalf of American Shoulder and Elbow Surgeons. This is an open access article under the CC BY-NC-ND license (<http://creativecommons.org/licenses/by-nc-nd/4.0/>).

Initially described in 1999, B2 glenoids are a unique pattern and are part of the iconic classification universally used for characterization of the glenoid aspect and its relationship with the humeral head in primary osteoarthritis.³⁵ With the use of 2-dimensional (2D) computed tomography (CT), B2 glenoids are characterized by 1) the posterior location of the humeral head relatively to the glenoid and scapula, so-called static posterior subluxation and 2) the unique biconcave deformity of the glenoid surface, with a crest

This study was approved by Ethical Committee of the GCS Ramsay Santé for Education and Research Institutional Review Board IRB00010835—referenced under the number: COS- RGDS-2021-04-002-NEYTON-L. An informed consent was obtained in all cases.

*Corresponding author: Lionel Neyton, MD, Centre Orthopédique Santy, 24 Ave Paul Santy, 69008 Lyon, France.

E-mail address: neyton.lionel@orange.fr (L. Neyton).

<https://doi.org/10.1016/j.jseint.2022.01.005>

2666-6383/© 2022 The Authors. Published by Elsevier Inc. on behalf of American Shoulder and Elbow Surgeons. This is an open access article under the CC BY-NC-ND license (<http://creativecommons.org/licenses/by-nc-nd/4.0/>).

separating a worn posterior neoglenoid and an intact anterior paleoglenoid.^{1,35}

The amount of posterior subluxation of the humeral head has been identified as a critical factor on the results of total shoulder arthroplasty (TSA) because of the postoperative progressive recurrence of the subluxation and its detrimental consequences on the glenoid, leading to component loosening.^{12,24,37} Subsequently, an accurate identification and evaluation of the preoperative posterior subluxation is crucial. The method of calculation of the humeral head subluxation (HHS) with 2D CT has evolved over time. Initially measured relatively to the glenoid as the percentage of the humeral head being posterior to a line bisecting the glenoid anteroposterior axis (Glenohumeral Index), the subluxation can also be calculated relatively to the scapula axis (Scapulohumeral Index).^{1,22,35}

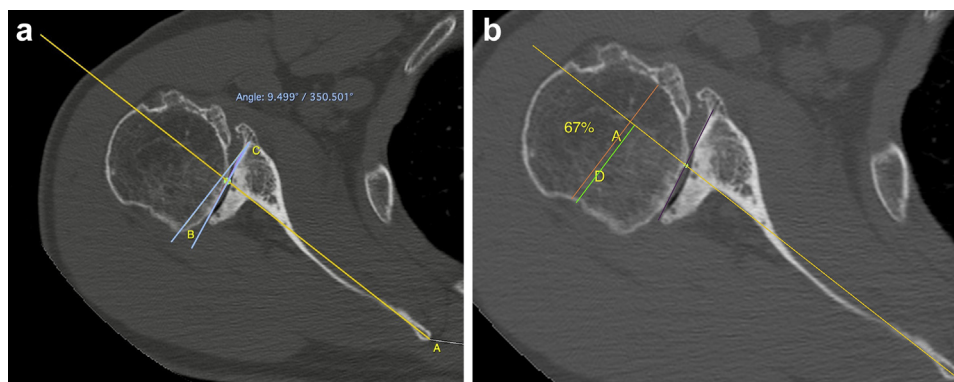


Figure 1 (a) Measurement of glenoid version according to the Friedman technique adapted to the biconcave glenoid.³² (b) Measurement of humeral head subluxation according to the Scapula axis method.^{22,37} Subluxation ratio = A/D.

The degree of glenoid retroversion (RV) is another crucial parameter for glenoid implant survivorship.¹¹ The RV method of assessment is also debated. Walch determined that the intermediate version relative to the scapular Friedman line was the most useful and reproducible.^{13,18,37} However, because the crest that separates the neo and paleoglenoid in B2 glenoids is obliquely orientated and because the degree of posterior wear is not identical from top to bottom, the glenoid version in 2D CT assessment is variable depending on the height at which the calculation is made.^{9,23}

HHS and glenoid version variability demonstrate the limits of 2D CT assessment. Several authors emphasized that 2D CT measures were not only subject to variability depending on the position of the patient in the CT scan gantry but also sensitive to image reorientation.^{6–9,16} In addition, because calculations are made only at one level at one axial cut, the specific patterns of the biconcave glenoids may not be faithfully represented in 2D.

Three-dimensional (3D) CT is emerged as an alternative, by using as reference scapular planes and considering bone volumes of the entire humeral head rather than axis (lines) and the aspect of the joint at one single level. With the rising use of 3D assessment of arthritic shoulders and arthroplasty planification, there is a need to clarify 1) if the 3D measurements are equivalent to 2D measurements and 2) are the historically accepted RV and subluxation cutoff values still relevant in 3D? Several studies have compared 2D and 3D characteristics of nonpathologic shoulders or arthritic shoulders.^{4,21,34} To our knowledge, only one study compared the two methods with a specific focus on B2 glenoids and concluded that 3D and 2D measurements (with or without reorientated images) of humeral subluxation and glenoid version were not equivalent.

The primary objective of this study was to compare B2 glenoids characteristics between routine-based 2D CT assessment method without image reorientation and 3D automated software method. Our first hypothesis was that there would be no difference in the evaluation of HHS and glenoid version when measured with 2D and 3D in B2 glenoids. The second hypothesis was that RV and subluxation were correlated in 2D and would similarly correlate in 3D.

Materials and methods

CT scans from patients who underwent a shoulder arthroplasty were identified and retrospectively extracted from an institutional anonymized database. All files were exported in a DICOM viewer (OsiriX; Pixmeo, Geneva, Switzerland) for 2D assessment and in an automated software program (Glenosys) for 3D assessment.

Exclusion criteria included etiology other than primary osteoarthritis, other than B2 glenoid according to Walch classification³⁵ and scan protocols not meeting Glenosys software instructions (available at <https://oms.tornierblueprint.com>). Patients who underwent a previous surgery or with an infection of the affected shoulder were also excluded. Each case was re-examined by 3 observers (trained shoulder fellows) and one senior author to confirm the B2 glenoid type. In case of disagreement, the final decision was taken by the senior author.

The study was approved by Ethical Committee of the GCS Ramsay Santé for Education and Research (IRB00010835). An informed consent was obtained in all cases.

Method of assessment in 2-dimension

The axial plane image immediately below the level of the tip of the coracoid process (without reorientation in the scapular plane) was used for all measurements (Fig. 1).

Measurement of glenoid version was determined according to the Friedman technique adapted to the biconcave glenoid.³²

The intermediate glenoid line was drawn from the anterior and posterior edge. The scapula axis was determined by a line drawn from the medial border of the scapula body to the midpoint of the glenoid fossa (Friedman line). A line drawn perpendicular to this was defined as a line of neutral version. The angle between that line and the scapula axis determined the glenoid version.

Measurement of humeral head subluxation (Scapula axis method). The percentage of the humeral head posterior to the Friedman line (scapula axis) was assessed at the longest anteroposterior diameter of the head on a line perpendicular to the scapula axis.^{22,37}

Method of assessment in 3-dimension

Glenosys software was used for 3D analysis (Fig. 2). It allows an automated segmentation of the humerus and scapula, definition of scapular planes, and determination of glenoid version and HHS. The version angle is automatically computed as the angulation between the scapular plane and the glenoid best-fit sphere centerline projected on the transverse scapular plane. The percentage of HHS according to the scapular plane was calculated by dividing the 3D volumetric portion of the humeral head posterior to the scapular plane by the whole volume of the humeral head. As the method uses all the points of the scapula and glenoid, there was no need to manually define any point on the 3D model.⁴

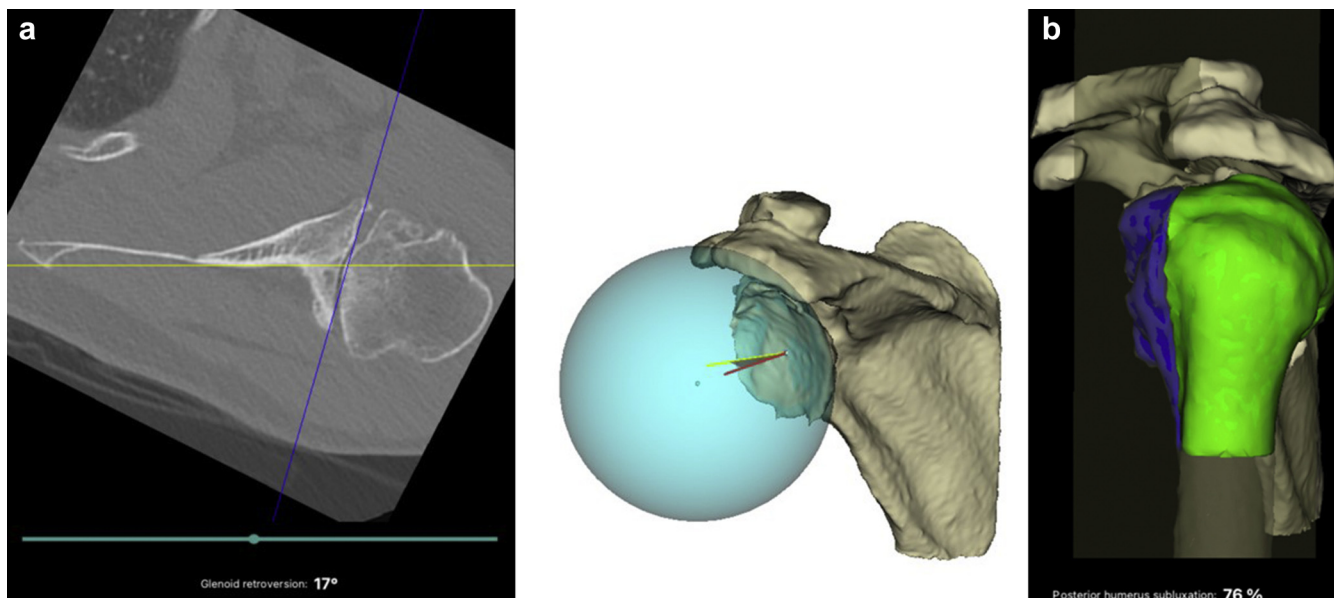


Figure 2 (a) Glenoid retroversion. The version angle is automatically computed as the angulation between the scapular plane and the glenoid best-fit sphere centerline projected on the transverse scapular plane. (b) Humeral head (HH) subluxation in 3D. The percentage of HH subluxation according to the scapular plane was calculated by dividing the 3D volumetric portion of the humeral head posterior to the scapular plane by the whole volume of the HH. 2D, 2-dimensional; 3D, 3-dimensional.

Statistical analysis

The data are described by counts and percentages for categorical variables and medians (interquartile range) for quantitative variables. Categorical variables were compared between groups using Fisher's exact test, and quantitative variables, using Wilcoxon's ranked-sum test or Kruskal Wallis test (according to the number of groups).

The Shapiro-Wilk test was used to assess whether continuous data were normally distributed. The interdependence of radiological measurements was evaluated using Pearson's or nonparametric Spearman's correlation coefficient (r) as appropriate.

The bias between radiologic measurements was estimated by using the Bland-Altman method for repeated measurements, and the limits of the Bland-Altman method are given as well [bias (1.96 SD)].^{3,27}

Intraclass correlation coefficient (ICC) were calculated using "psy" package, version 1.1, and 95% confidence intervals were generated by bootstrap method using "boot" package, version 1.3–20.

All tests were two-sided, and statistical significance was set at the 0.05 level. All analyses were performed using R software,

Table I
Intraobserver reliability.

Humeral head subluxation (n = 51)			
	ICC	ICC (95% up)	ICC (95% low)
Observer A	0.947	0.969	0.913
Observer B	0.905	0.939	0.847
Observer C	0.966	0.980	0.948
Retroversion (n = 51)			
	ICC	ICC (95% up)	ICC (95% low)
Observer A	0.971	0.987	0.946
Observer B	0.967	0.982	0.948
Observer C	0.991	0.995	0.981

ICC, intraclass correlation coefficient.

version 3.5.3 (The R Foundation for Statistical Computing, Vienna, Austria).

Results

Seventy consecutive CT scans were analyzed, and 51 CT scans met inclusion criteria.

Intraobserver and interobserver reliability

The intraobserver reliability of the 2D RV and 2D HHS measured by the ICC was excellent (>0.9) for the 3 observers. The interobserver reliability of the 2D RV and 2D HHS measured by the ICC was also excellent among 3 observers (Tables I and II).

Retroversion

The median RV was 16° [12-20] in 2D and 19° [16-23] in 3D ($P < .0001$). Linear regression analysis demonstrated strong positive correlation ($R^2 = 0.64$) between 2D and 3D RV (Fig. 3).

According to Bland-Altman, 95% of the differences observed between 2D and 3D RV were in between the limits of agreement of +4.7 and -12.4. Two-dimensional RV was systematically different from 3D by a mean of -3.8°.

Humeral head subluxation

The median subluxation was 71% [66-75] in 2D and 81% [78-86] in 3D ($P < .0001$). Linear regression analysis demonstrated mild

Table II
Interobserver reliability (n = 51).

	ICC	ICC (95% up)	ICC (95% low)
RV	0.961	0.987	0.946
HHS	0.906	0.947	0.848

HHS, humeral head subluxation; ICC, intraclass correlation coefficient; RV, retroversion.

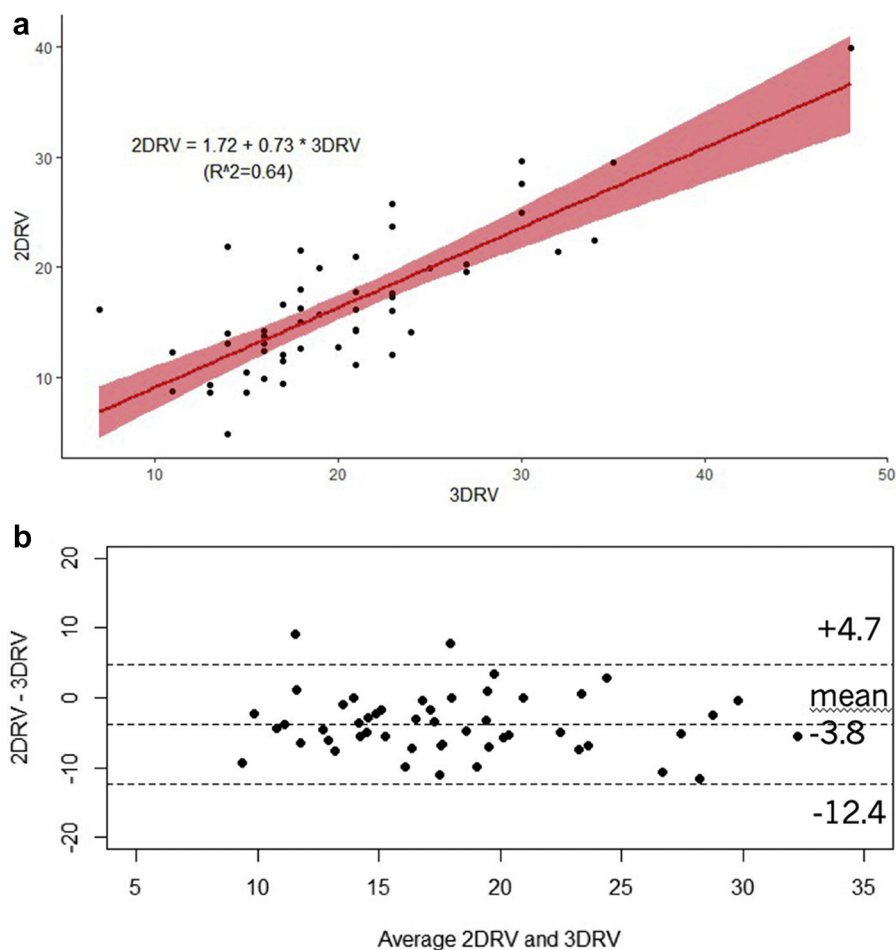


Figure 3 (a) Retroversion: correlation between 2D and 3D (Glenosys). (b) Analysis with the Bland and Altman method of concordance between 2D retroversion and 3D retroversion. 2D, 2-dimensional; 3D, 3-dimensional.

positive correlation ($R^2 = 0.51$) between 2D and 3D subluxation. According to Bland-Altman, 95% of the differences observed between 2D and 3D RV were in between the limits of agreement of +2.9 and -21. Two-dimensional subluxation was systematically different from 3D by a mean of -9.3% (Fig. 4).

Correlations between retroversion and subluxation

Linear regression analysis demonstrated low positive correlation between RV and subluxation in 2D and 3D ($R^2 = 0.31$ and $R^2 = 0.23$, respectively) (Fig. 5).

Discussion

In 3D, version and HHS in B2 glenoids were statistically different from 2D CT, rejecting our first hypothesis.

Two-dimensional vs three-dimensional methods

The 2D method of measurements is subject to variation depending on several parameters such as patient positioning in the CT scanner,⁶ beam orientation, and also the height at which the assessment is performed. We chose the level of cut in the axial plane just below the coracoid process for all cases to decrease the potential for error in the manual measurements where high degrees of interobserver and intraobserver reliability were

observed.³⁷ In 3D, semiautomated and automated software programs have proven to be effective and reliable in the evaluation of arthritic glenoids.^{4,19} Glenosys is a fully automated software program using a validated method for reference plane creation. In the present study, each observer ran each case with the software for assessment with a perfect reproducibility.

Retroversion

Walch B2 glenoid RV was significantly greater in 3D than in 2D manual assessment with the Friedman scapular and intermediate glenoid lines method.³² The 2D measures were systematically different from 3D ones by a mean of -3.8°.

Two-dimensional glenoid RV can be assessed in many ways.^{13,31,32} Rouleau demonstrated that in the presence of a B2 glenoid, the choice of an intermediate glenoid line is more reliable for version measurement. Using the intermediate glenoid line, the RV illustrates the amount of glenoid wear. Some glenoids have a deep neoglenoid (steep B2) which induces a medialization of the posterior glenoid point used for determination of the intermediate line which increases the value of the version in 2D. Conversely, a light B2 glenoid, that is, with a less steep neoglenoid, will less affect the calculation of the version because the posterior glenoid point is more lateral. Moreover, in 2D, the evaluation is assessed at one single level. This does not consider the orientation of the glenoid line which separates the neo and paleoglenoid. Knowles, using 3D

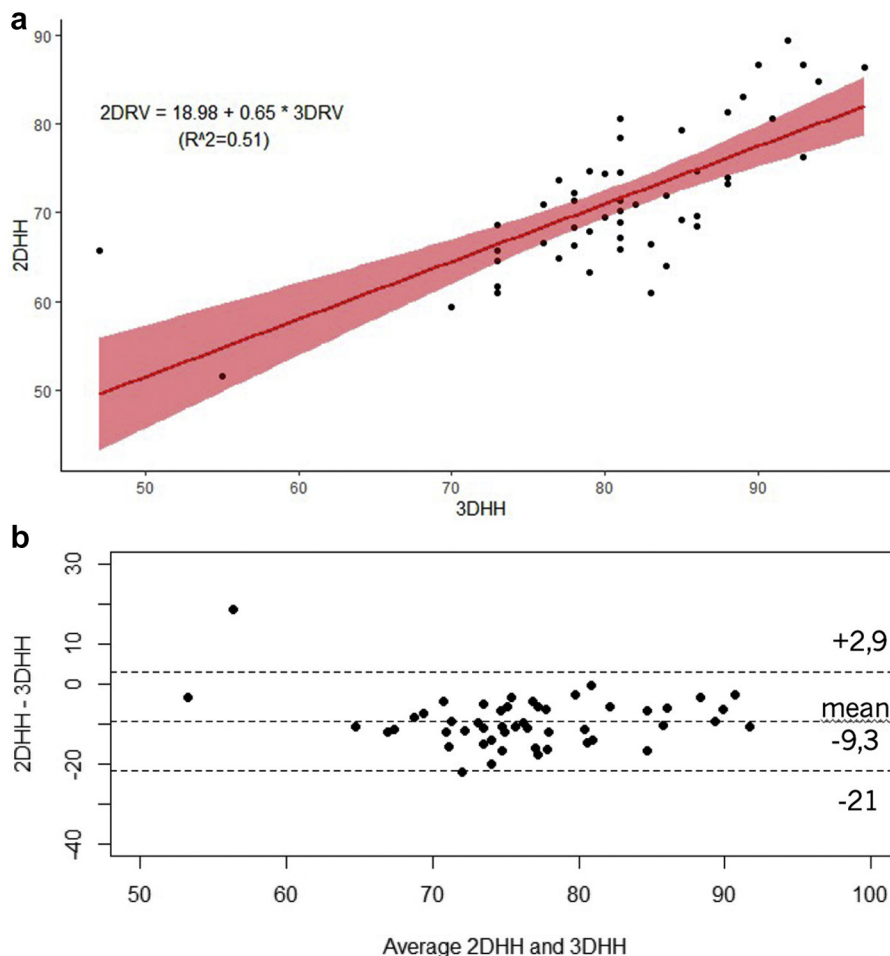


Figure 4 (a) Humeral head subluxation: correlation between 2D and 3D (Glenosys). (b) Analysis with the Bland and Altman method of concordance between 2D subluxation and 3D subluxation. 2D, 2-dimensional; 3D, 3-dimensional.

glenoid surface rendering images, observed that this line was not vertically oriented from the superior to the inferior glenoid tubercles but with a posteroinferior direction.²³ Consequently, one axial cut chosen for calculation illustrates the RV at this particular single level but not for the entire glenoid. This is consistent with the results of Chalmers who reported different values of B2 glenoids version between proximal, mid, and distal height levels.⁹ Similarly, Hoenecke reported that measurements made between adjacent CT slices introduced a mean variability of approximately 7° in glenoid version measured in the same subject.¹⁶ These differences are thought to be induced by the relative orientation of the axial 2DCT slice, the patient’s torso axis, and the scapula body axis and are considered as a potential source of error.⁷ To correct for variation in scapular positioning relative to the original CT axial cuts, multiplanar reconstructions are recommended with manual reorientation of the images. The difference in glenoid version measures between the corrected and uncorrected methods is still not unambiguous in the literature. Boileau did not find differences when studying 60 arthritic glenoids regardless of Walch type, while Chalmers found a significant difference when focusing on B2 glenoids.^{4,9}

Subluxation

The humeral head posterior subluxation in Walch B2 glenoid was significantly greater in 3D with Glenosys software than 2D

manual assessment. The 2D measures were systematically different from 3D ones by a mean of –9.3%. The 2D and 3D subluxations showed a mild positive correlation.

Historically, Walch described the B-type glenoids, with B1 subtype characterized by posterior subluxation of the humeral head without glenoid bone wear and the B2 subtype with biconcave deformity of the glenoid bone surface.³⁵ The posterior location of the head was initially assessed relatively to the glenoid (glenohumeral subluxation) and later changed to refer to the scapular axis (scapulohumeral subluxation).^{22,34} Like the version, the subluxation method of assessment has been discussed in the literature with the use of conventional 2D CT, corrected 2D CT, and finally 3D reconstructed scans. Jacxsens highlighted significant differences in cutoff values in a comparative study in healthy glenoids. Conventional CT measures showed an underestimation of the scapulohumeral subluxation in 89% of the cases.²⁰ Similarly, Terrier found 2D and 3D scapulohumeral subluxations were statistically different and were moderately correlated in arthritic shoulders, regardless of Walch glenoid type.³⁴ Our results are similar in arthritic B2 glenoids with an underestimation of the subluxation in 2D compared with 3D.

Correlation between retroversion and subluxation

The relationship between RV and subluxation is controversial. Walch first reported no correlation between version and

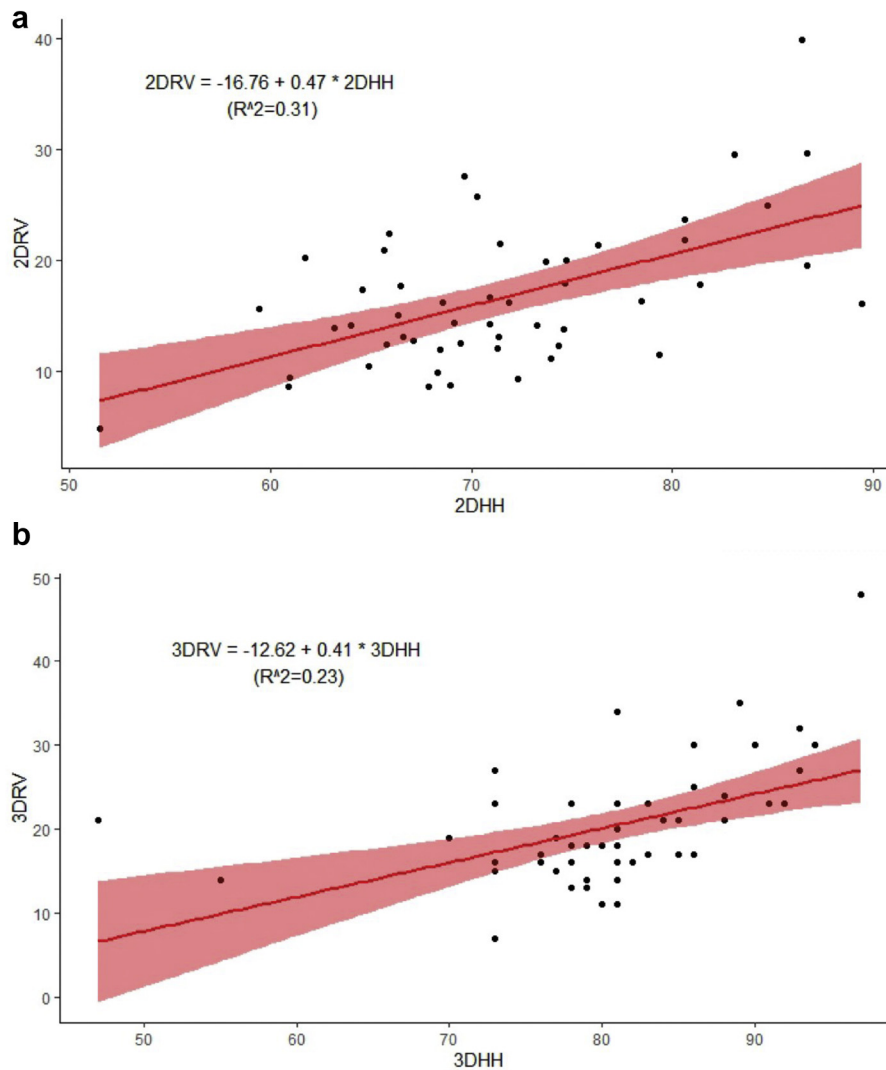


Figure 5 (a) Correlation between retroversion and subluxation in 2D. (b) Correlation between retroversion and subluxation in 3D (Glenosys). 2D, 2-dimensional; 3D, 3-dimensional.

subluxation when measuring the HHS relatively to the glenoid (glenohumeral subluxation).³⁶ Hoenecke did not find a correlation with the same 2D CT protocol as in our study in 121 shoulders regardless of Walch's type ($R^2 = 0,02$).¹⁷ Terrier reported a strong correlation ($R^2 = 0.7$ $P < .01$) between the scapulohumeral subluxation and the glenoid version in 112 osteoarthritic shoulders, regardless of the glenoid status in the Walch classification and using the same 3D protocol as in the present study.³⁴ To our knowledge, our study is the first to specifically investigate the correlation between RV and subluxation in B2 glenoids with a 3D CT protocol. Our results demonstrate a low correlation between RV and subluxation in 2D and 3D in B2 osteoarthritic glenoids, rejecting our second hypothesis.

This is illustrated by cases with RV of less than or equal to 10° with subluxation rate of 80% or higher with both methods of assessment. With these data, it is not possible to arbitrate the controversy of whether RV precedes subluxation or opposite. However, the low degree of correlation between RV and subluxation is consistent with these two factors being partially independent. In other words, the severity of glenoid erosion resulting in a high degree of intermediate RV is not systematically correlated

with a high rate of posterior subluxation. Subsequently, an attempt at correction of posterior subluxation by glenoid RV correction in anatomic TSA, whatever the option (asymmetric reaming prior to standard glenoid component implantation,^{30,37} glenoid bone grafting and standard implant,^{2,29,33} posterior augmented glenoid implants^{14,15}), may not be successful. This is consistent with the current literature which demonstrates the progressive recurrence of posterior subluxation over time as the principal mode of failure in B2 glenoids treated with TSA, suggesting its multifactorial origin.^{5,37,38} Conversely, Mizuno reported successful management of B2 glenoids with reverse shoulder arthroplasty without residual posterior subluxation.²⁶ Accordingly, the semiconstrained design of the reverse arthroplasty seems to be the sole way to counteract the recurrence of posterior subluxation. In addition, glenoid bone grafting is permitted between the eroded glenoid and the backside of the baseplate, if deemed necessary.^{26,28}

However, there are some pieces of evidence that some B2 glenoid shoulders can be successfully managed with TSA options.^{12,15,25} This could mean that cutoff values of posterior subluxation and/or glenoid RV below which TSA could be suitable and beyond which reverse shoulder arthroplasty is best indicated

remain to be determined. The threshold value of posterior subluxation to switch from anatomic to reverse prosthesis indication has been estimated with 2D CT at 80% because beyond this value the glenoid loosening rate was 20% at 77-month follow-up.³⁷ Using 3D CT preoperative assessment, Ho stated their data did not allow the determination of the amount of each variable to assist with surgical decision-making.¹⁵ Therefore, larger clinical studies are required with the use of 3D preoperative planning to determine new cutoff values, and it should already be anticipated that the previously reported cutoff value of 80% of subluxation with 2D CT cannot apply to 3D protocols.

Weaknesses and strength

The present study is not free of limitations. The sample size is limited to fifty-one CT scans although superior to a similar study.⁹ Denard reported a noticeable difference between the measurements with a different software program relying on manual identification of scapular landmarks prior to digital treatment and 3D planification.¹⁰ Therefore, the results of this study should only be considered for that specific fully automated Glenosys software and its commercial version (Blueprint).

Despite a prospective collection of the DICOM files, the analysis was retrospectively conducted and therefore suffers from inherent limitations. The manual assessment of version and subluxation in 2D could have been a source of error. We established a strict protocol, and intraobserver and interobserver reliability rates were excellent. The specific pattern of B2 glenoid can sometimes be debatable. The B2 type in the present series was checked by the 3 observers and validated by the senior author.

Conclusion

The present study demonstrates that the assessment of version and HHS between 2D CT and a Glenosys 3D fully automated planification software program are significantly different in Walch B2 glenoids. In the 3D method, glenoid version and HHS were statistically greater than with the 2D method. In addition, low correlation between RV and HHS was observed in B2 glenoids, regardless of the 2D or 3D method of assessment. Such differences should be integrated by physicians switching from 2D CT to 3D CT planification for shoulder replacement in the difficult-to-treat biconcave glenoids. Moreover, in the near future, the results of shoulder arthroplasty will mostly refer to preoperative parameters issued from 3D planification software programs. Subsequently, preoperative cutoff values and landmarks used until now with 2D CT scans for indication and choice among different replacement options may become obsolete and be revisited. Additionally, these cutoff values might be specific for each software program and preclude valuable comparison.

Disclaimers:

Funding: The statistical analysis was funded by Direction Recherche et Enseignement Ramsay Santé.

Conflicts of Interest: Dr L. Neyton has potential conflict of interest. He is a consultant for Wright and Arthrex and perceives royalties from Wright. The other authors, their immediate families, and any research foundation with which they are affiliated have not received any financial payments or other benefits from any commercial entity related to the subject of this article.

Acknowledgments

The authors thank Sebastien Kerever (Newmed Publishing Services) for providing the statistical analysis.

References

1. Badet R, Walch G, Boulahia A. Computed tomography in primary glenohumeral osteoarthritis without humeral head elevation. *Rev Rhum Engl Ed* 1998;65:187-94.
2. Bell RH, Noble JS. The management of significant glenoid deficiency in total shoulder arthroplasty. *J Shoulder Elbow Surg* 2000;9:248-56.
3. Bland JM, Altman DG. Statistical methods for assessing agreement between two methods of clinical measurement. *Lancet* 1986;1:307-10.
4. Boileau P, Cheval D, Gauci M-O, Holzer N, Chaoui J, Walch G. Automated three-dimensional measurement of glenoid version and inclination in arthritic shoulders. *J Bone Joint Surg* 2018;100:57-65. <https://doi.org/10.2106/JBJS.16.01122>.
5. Boileau P, Moineau G, Morin-Salvo N, Avidor C, Godenèche A, Lévine C, et al. Metal-backed glenoid implant with polyethylene insert is not a viable long-term therapeutic option. *J Shoulder Elbow Surg* 2015;24:1534-43. <https://doi.org/10.1016/j.jse.2015.02.012>.
6. Bokor DJ, O'Sullivan MD, Hazan GJ. Variability of measurement of glenoid version on computed tomography scan. *J Shoulder Elbow Surg* 1999;8:595-8.
7. Bryce CD, Davison AC, Lewis GS, Wang L, Flemming DJ, Armstrong AD. Two-dimensional glenoid version measurements vary with coronal and sagittal scapular rotation. *J Bone Joint Surg Am* 2010;92:692-9. <https://doi.org/10.2106/JBJS.L00177>.
8. Budge MD, Lewis GS, Schaefer E, Coquia S, Flemming DJ, Armstrong AD. Comparison of standard two-dimensional and three-dimensional corrected glenoid version measurements. *J Shoulder Elbow Surg* 2011;20:577-83. <https://doi.org/10.1016/j.jse.2010.11.003>.
9. Chalmers PN, Salazar D, Chamberlain A, Keener JD. Radiographic characterization of the B2 glenoid: the effect of computed tomographic axis orientation. *J Shoulder Elbow Surg* 2017;26:258-64. <https://doi.org/10.1016/j.jse.2016.07.021>.
10. Denard PJ, Provencher MT, Lädermann A, Romeo AA, Parsons BO, Dines JS. Version and inclination obtained with 3-dimensional planning in total shoulder arthroplasty: do different programs produce the same results? *JSES Open Access* 2018;2:200-4. <https://doi.org/10.1016/j.jses.2018.06.003>.
11. Farron A, Terrier A, Büchler P. Risks of loosening of a prosthetic glenoid implanted in retroversion. *J Shoulder Elbow Surg* 2006;15:521-6. <https://doi.org/10.1016/j.jse.2005.10.003>.
12. Favorito PJ, Freed RJ, Passanise AM, Brown MJ. Total shoulder arthroplasty for glenohumeral arthritis associated with posterior glenoid bone loss: results of an all-polyethylene, posteriorly augmented glenoid component. *J Shoulder Elbow Surg* 2016;25:1681-9. <https://doi.org/10.1016/j.jse.2016.02.020>.
13. Friedman RJ, Hawthorne KB, Genez BM. The use of computerized tomography in the measurement of glenoid version. *J Bone Joint Surg Am* 1992;74:1032-7.
14. Ghorashian M, Abboud JA, Romeo AA, Williams GR, Namdari S. Augmented glenoid implants in anatomic total shoulder arthroplasty: review of available implants and current literature. *J Shoulder Elbow Surg* 2019;28:387-95. <https://doi.org/10.1016/j.jse.2018.08.017>.
15. Ho JC, Amini MH, Entezari V, Jun BJ, Alolabi B, Ricchetti ET, et al. Clinical and radiographic outcomes of a posteriorly augmented glenoid component in anatomic total shoulder arthroplasty for primary osteoarthritis with posterior glenoid bone loss. *J Bone Joint Surg* 2018;100:1934-48. <https://doi.org/10.2106/JBJS.17.01282>.
16. Hoenecke HR, Hermida JC, Flores-Hernandez C, D'Lima DD. Accuracy of CT-based measurements of glenoid version for total shoulder arthroplasty. *J Shoulder Elbow Surg* 2010;19:166-71. <https://doi.org/10.1016/j.jse.2009.08.009>.
17. Hoenecke HR, Tibor LM, D'Lima DD. Glenoid morphology rather than version predicts humeral subluxation: a different perspective on the glenoid in total shoulder arthroplasty. *J Shoulder Elbow Surg* 2012;21:1136-41. <https://doi.org/10.1016/j.jse.2011.08.044>.
18. Iannotti JP, Jun B-J, Patterson TE, Ricchetti ET. Quantitative measurement of osseous pathology in advanced glenohumeral osteoarthritis. *J Bone Joint Surg Am* 2017;99:1460-8. <https://doi.org/10.2106/JBJS.16.00869>.
19. Iannotti JP, Weiner S, Rodriguez E, Subhas N, Patterson TE, Jun BJ, et al. Three-dimensional imaging and templating improve glenoid implant positioning. *J Bone Joint Surg* 2015;97:651-8. <https://doi.org/10.2106/JBJS.N.00493>.
20. Jaxsens M, Karns MR, Henninger HB, Drew AJ, Van Tongel A, De Wilde L. Guidelines for humeral subluxation cutoff values: a comparative study between conventional, reoriented, and three-dimensional computed tomography scans of healthy shoulders. *J Shoulder Elbow Surg* 2018;27:36-43. <https://doi.org/10.1016/j.jse.2017.06.005>.
21. Jaxsens M, Van Tongel A, Willemot LB, Mueller AM, Valderrabano V, De Wilde L. Accuracy of the glenohumeral subluxation index in nonpathologic shoulders. *J Shoulder Elbow Surg* 2015;24:541-6. <https://doi.org/10.1016/j.jse.2014.07.021>.

22. Kidder JF, Rouleau DM, Pons-Villanueva J, Dynamidis S, DeFranco MJ, Walch G. Humeral head posterior subluxation on CT scan: validation and comparison of 2 methods of measurement. *Tech Shoulder Elbow Surg* 2010;11:72-6. <https://doi.org/10.1097/BTE.0b013e3181e5d742>.
23. Knowles NK, Keener JD, Ferreira LM, Athwal GS. Quantification of the position, orientation, and surface area of bone loss in type B2 glenoids. *J Shoulder Elbow Surg* 2015;24:503-10. <https://doi.org/10.1016/j.jse.2014.08.021>.
24. Luedke C, Kissenberth MJ, Tolan SJ, Hawkins RJ, Tokish JM. Outcomes of anatomic total shoulder arthroplasty with B2 glenoids: a systematic review. *JBJS Rev* 2018;6:e7. <https://doi.org/10.2106/JBJS.RVW.17.00112>.
25. Matsen FA, Whitson AJ, Somerson JS, Hsu JE. Anatomic total shoulder arthroplasty with all-polyethylene glenoid component for primary osteoarthritis with glenoid deficiencies. *JBJS Open Access* 2020;5:e20.00002. <https://doi.org/10.2106/JBJS.OA.20.00002>.
26. Mizuno N, Denard PJ, Raiss P, Walch G. Reverse total shoulder arthroplasty for primary glenohumeral osteoarthritis in patients with a biconcave glenoid. *J Bone Joint Surg Am* 2013;95:1297-304. <https://doi.org/10.2106/JBJS.L.00820>.
27. Myles PS, Cui J. Using the Bland-Altman method to measure agreement with repeated measures. *Br J Anaesth* 2007;99:309-11. <https://doi.org/10.1093/bja/aem214>.
28. Neyton L, Boileau P, Nové-Josserand L, Edwards TB, Walch G. Glenoid bone grafting with a reverse design prosthesis. *J Shoulder Elbow Surg* 2007;16:S71-8. <https://doi.org/10.1016/j.jse.2006.02.002>.
29. Nicholson GP, Cvetanovich GL, Rao AJ, O'Donnell P. Posterior glenoid bone grafting in total shoulder arthroplasty for osteoarthritis with severe posterior glenoid wear. *J Shoulder Elbow Surg* 2017;26:1844-53. <https://doi.org/10.1016/j.jse.2017.03.016>.
30. Orvets ND, Chamberlain AM, Patterson BM, Chalmers PN, Gosselin M, Salazar D, et al. Total shoulder arthroplasty in patients with a B2 glenoid addressed with corrective reaming. *J Shoulder Elbow Surg* 2018;27:S58-64. <https://doi.org/10.1016/j.jse.2018.01.003>.
31. Randelli M, Gambrioli PL. Glenohumeral osteometry by computed tomography in normal and unstable shoulders. *Clin Orthop Relat Res* 1986:151-6.
32. Rouleau DM, Kidder JF, Pons-Villanueva J, Dynamidis S, DeFranco M, Walch G. Glenoid version: how to measure it? Validity of different methods in two-dimensional computed tomography scans. *J Shoulder Elbow Surg* 2010;19:1230-7. <https://doi.org/10.1016/j.jse.2010.01.027>.
33. Sabesan V, Callanan M, Ho J, Iannotti JP. Clinical and radiographic outcomes of total shoulder arthroplasty with bone graft for osteoarthritis with severe glenoid bone loss. *J Bone Joint Surg Am* 2013;95:1290-6. <https://doi.org/10.2106/JBJS.L.00097>.
34. Terrier A, Ston J, Farron A. Importance of a three-dimensional measure of humeral head subluxation in osteoarthritic shoulders. *J Shoulder Elbow Surg* 2015;24:295-301. <https://doi.org/10.1016/j.jse.2014.05.027>.
35. Walch G, Badet R, Boulahia A, Khoury A. Morphologic study of the glenoid in primary glenohumeral osteoarthritis. *J Arthroplasty* 1999;14:756-60.
36. Walch G, Boulahia A, Boileau P, Kempf JF. Primary glenohumeral osteoarthritis: clinical and radiographic classification. The Aequalis group. *Acta Orthop Belg* 1998;64(Suppl 2):46-52.
37. Walch G, Moraga C, Young A, Castellanos-Rosas J. Results of anatomic non-constrained prosthesis in primary osteoarthritis with biconcave glenoid. *J Shoulder Elbow Surg* 2012;21:1526-33. <https://doi.org/10.1016/j.jse.2011.11.030>.
38. Walch G, Young AA, Boileau P, Loew M, Gazielly D, Molé D. Patterns of loosening of polyethylene keeled glenoid components after shoulder arthroplasty for primary osteoarthritis: results of a multicenter study with more than five years of follow-up. *J Bone Joint Surg Am* 2012;94:145-50. <https://doi.org/10.2106/JBJS.J.00699>.