

Case Report

Catastrophic Intramedullary Abscess Caused by a Missed Congenital Dermal Sinus

Yun-Sik Dho, M.D., Seung-Ki Kim, M.D., Ph.D., Kyu-Chang Wang, M.D., Ph.D., Ji Hoon Phi, M.D.

Division of Pediatric Neurosurgery, Seoul National University Children's Hospital, Seoul National University College of Medicine, Seoul, Korea

Congenital dermal sinus (CDS) is a type of occult spinal dysraphism characterized by a midline skin dimple. A 12-month-old girl presented with fever and ascending quadriparesis. She had a midline skin dimple in the upper sacral area that had been discovered in her neonatal period. Imaging studies revealed a holocord intramedullary abscess and CDS. Overlooking CDS or misdiagnosing it as benign sacrococcygeal dimple may lead to catastrophic infection and cause serious neurological deficits. Therefore, further imaging work-up or consultation with a pediatric neurosurgeon is recommended following discovery of any atypical-looking dimples in the midline.

Key Words : Congenital dermal sinus · Intramedullary abscess · Diagnosis.

INTRODUCTION

Congenital dermal sinus (CDS) is a congenital anomaly that develops anywhere in the midline along the neuraxis¹⁾. CDS belongs to a group of disorder called occult spinal dysraphism in which skin covers most of the defect of the neuraxis and overlying tissues, except for a small skin ostium of the dermal sinus tract. In the lumbosacral area, the skin ostium of the dermal sinus tract is usually situated above the gluteal folds, which is an important clue for differentiating it from benign sacrococcygeal dimples²⁾.

CDS is a very uncommon disease. However, the clinical importance of CDS is that some patients with the anomaly can develop severe infection of the central nervous system, such as bacterial meningitis and spinal cord abscesses, through the dermal sinus tract³⁾. Therefore, pediatricians should be alert for the possibility of CDS when examining a dimple in the midline of scalp and back. Overlooking CDS or misdiagnosing the anomaly as a benign sacrococcygeal dimple may lead to a catastrophic infection and cause serious neurological deficits⁴⁾.

We encountered a 12-month-old girl who presented with a pyomyelia in the whole spinal cord. Further evaluation showed a small skin ostium in the upper sacral area and a CDS leading

into the spinal canal. Unfortunately, a detailed history report revealed that the skin ostium was detected early in her neonatal period by the parents, but they thought it was a benign skin lesion with little clinical importance. Despite surgical evacuation of the abscess and infection control, the patient showed grave neurological deficits. This case emphasizes the crucial importance of gaining knowledge of and directing clinical attention to differentiating a potentially life-threatening anomaly from benign lesions, and primary physicians are urged to be vigilant in understanding and diagnosing CDS.

CASE REPORT

A 12-month-old girl visited the emergency room with a high fever and progressive paraparesis. The patient had normal development and began to walk at approximately 10 months of age. She had developed a fever of up to 39.5°C 15 days prior to the visit. While visiting a local clinic, she was diagnosed with pharyngitis and received antibiotics and antipyretics. Her fever subsided but repetitive vomiting started 10 days prior. Five days ago, her high fever returned again. From then, she intermittently showed lethargic symptoms and was unwilling to walk. She received additional examinations for infectious disease and supportive treat-

• Received : February 28, 2014 • Revised : June 27, 2014 • Accepted : July 26, 2014

• Address for reprints : Ji Hoon Phi, M.D.

Division of Pediatric Neurosurgery, Seoul National University Children's Hospital, Seoul National University College of Medicine, 101 Daehak-ro, Jongno-gu, Seoul 110-744, Korea

Tel : +82-2-2072-3639, Fax : +82-2-744-8459, E-mail : phi.jihoon@gmail.com

• This is an Open Access article distributed under the terms of the Creative Commons Attribution Non-Commercial License (<http://creativecommons.org/licenses/by-nc/3.0>) which permits unrestricted non-commercial use, distribution, and reproduction in any medium, provided the original work is properly cited.

ment for days, and finally, the local physician decided to transfer her to our hospital, when she showed overt paraparesis.

Upon arrival at the emergency room, she was acutely ill-looking and lethargic. Her vital signs were as follows : heart rate 137 beats/min; blood pressure 123/56 mm Hg; respiratory rate 28 breaths/min; body temperature 38.6°C. She was alert but exhib-

ited quadriplegia. Her motor grade was I/I for upper extremities and 0/0 for lower extremities. She also exhibited profound hypesthesia below the C4 dermatome. Bilateral biceps jerks were weak, and bilateral knee and ankle jerks were absent. No meningeal irritation sign was observed. A palpable mass was found in her abdomen, which was determined to be a distended bladder. There was a tiny dimple in the midline of the upper sacral area (Fig. 1). It was located above the gluteal folds, approximately 6 cm away from the anus. A small amount of whitish thick discharge was squeezed from the dimple by manual pressure. A laboratory examination revealed blood leukocytosis (15500/ μ L), decreased hemoglobin (10.9 g/dL), decreased hematocrit (31.6%), and elevated C-reactive protein (5.83 mg/dL).

The febrile illness and rapidly ascending quadriplegia indicated an infectious disease of the central nervous system involving the spinal cord. The high-lying midline skin dimple with discharge added suspicion of an underlying infected dermoid. A detailed history was collected and revealed that her parents had found the skin dimple during her neonatal period, but they thought it was an innocent lesion that did not require further investigation.

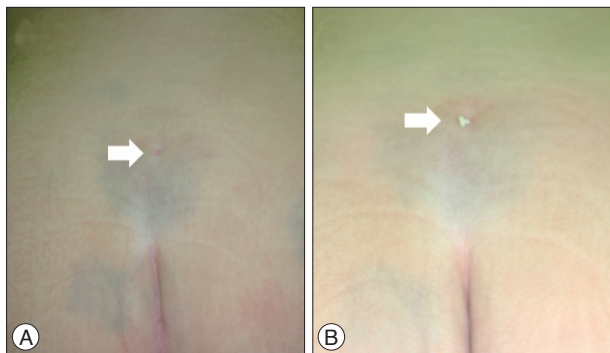


Fig. 1. Photographs of the sacral skin dimple. A : The dimple (arrow) was located far above the gluteal folds, approximately 6 cm away from anus. B : Whitish thick discharges (arrow) were squeezed out from the dimple with manual pressure.

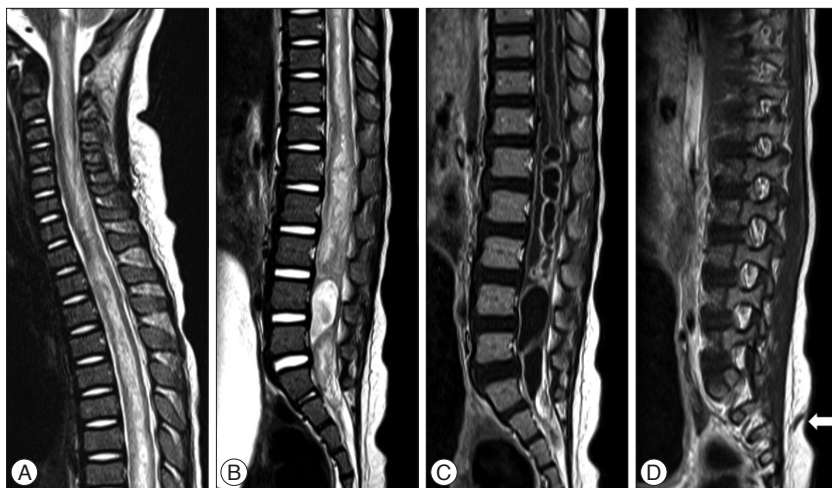


Fig. 2. A and B : Spinal MRI shows a diffuse swelling of the spinal cord and a high signal intensity up to the medulla oblongata (A) and a low-lying conus to the S3 level (B). C : On gadolinium-enhanced image, dilatation of the central canal and multiple intramedullary rim-enhancing cysts are observed. D : A dermal sinus tract (arrow) is seen from the skin dimple to a bony defect at the S3 level.

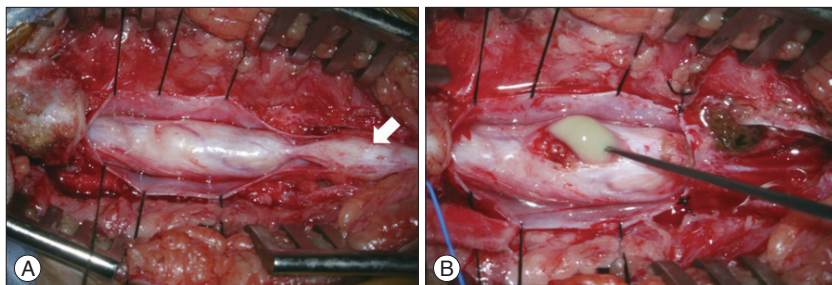


Fig. 3. Intraoperative photographs. A : After dural opening, we observed a thickened spinal cord that was connected to the dermal sinus tract containing multiple dermoid cysts (arrow). B : Green-colored pus was discharged after dorsal midline myelotomy.

Spinal magnetic resonance imaging (MRI) was immediately obtained (Fig. 2). The MRI revealed diffuse high signal intensity along the spinal cord up to the medulla oblongata. There was a low-lying conus down to the S3 level. An enlarged central canal and thick gadolinium-enhancement of the lining up to the T1 level was observed. There were multiple cystic dilatations with rim enhancement in the lumbosacral cord. A dermal sinus tract ran obliquely upward from the conus at the S3 level to the skin. An infected CDS with massive holocord pyomyelia was diagnosed.

An emergency operation for abscess evacuation and untethering was performed. The sinus tract was followed from the skin ostium. There were multiple dermoid cysts along the sinus tract entering the dural sac through the fascial and bone defect (Fig. 3). After a multi-level laminectomy, the dural sac was opened and a thickened spinal cord was observed. A dorsal midline myelotomy was made and noxious green-colored pus was discharged from the abscess. The abscess cavity and syring were flushed with saline. Finally, the sinus tract was resected just distal to the last root.

Multiple pathogens were suspected

and the patient received vancomycin and cefotaxime for empirical therapy. Later, *Peptoniphilus asaccharolyticus* and an unidentified anaerobic rod were isolated from the pus and we added metronidazole to the drug regimen. She received the triple antibiotics for 6 weeks following the operation. Her fever subsided quickly, but profound neurological deficits remained. The lower extremity weakness improved only slightly, and spasticity ensued. She had weakness in both hands (C8–T1 level). Horner syndrome in the left side with ptosis and anhidrosis of face was observed. Sensory function in the trunk and lower extremities improved slightly but incompletely. She had a neurogenic bladder and clean intermittent catheterization (CIC) was required. She was followed post-surgery for 2 years. Serial spinal MRIs showed gradual shrinkage of the residual T2 high signal intensity and enhancement in the spinal cord. In this time period, she never developed another bout of the febrile episode. She regained grasp function in both hands, particularly in the right hand. She can move her legs slightly, but she is still wheelchair-bound and needs CIC for bladder care.

DISCUSSION

CDS is a rarely encountered anomaly in clinical practice. Because of its low incidence rate, many clinical series on CDS include data accumulated over decades^{1,2}. Nonetheless, CDS is an important disorder that is emphasized in pediatric textbooks. The sinus tract can be a potential route of a life-threatening infection to the central nervous system; thus, CDS requires early detection and surgical treatment. Therefore, clinicians should be alert when examining skin dimples in the midline on the back.

One major obstacle to correctly diagnosing CDS is that there exists a benign entity called a sacrococcygeal dimple, and its incidence rate is far higher than that of CDS⁶. Sacrococcygeal dimples are innocuous lesions located just over the coccygeal area⁷. They are typically small (<5 mm in width) and are located in the midline in the gluteal folds within 2.5 cm from the anus. It is not accompanied skin stigmata, such as hemangiomas, elevated masses, tails, or hairy patches. Kriss and Desai⁷ reported that none of the 180 simple dimples satisfying these criteria were associated with occult spinal dysraphism in imaging studies. Atypical dimples located higher on the back, although not pathognomonic of occult spinal dysraphism, are of high risk and warrant further evaluation. Sometimes, whether a skin dimple is benign is not easy to determine by inspection alone⁶. In such cases, spinal ultrasonography is an easy method for resolving the problem.

In this patient, the skin dimple was clearly located high on the back away from the coccygeal area. Unfortunately, there was a chance to detect the presence of CDS and enough time to prevent the catastrophe. Currently, primary physicians are keen to diagnose hidden anomalies such as occult spinal dysraphism. Knowledge and precautions against such a disorder are common even among the general public. However, erroneous infor-

mation is still widespread and a decision-making mistake may lead to irreversible damage to the patient⁴. Ramnarayan et al.¹⁰ reported a clinical course of 9 patients with CDS. Interestingly, all the patients were previously examined by medical personnel (family doctor, pediatrician, or general practitioner) and they made no action or gave just empirical treatment with antibiotics before significant neurological deficits or meningitis developed. Inspection of the whole body is a routine for neonates and midlines in the scalp and back should be included in this procedure. For any atypical dimples, further imaging or consultation with a pediatric neurosurgeon is recommended^{8,9}. Elton and Oakes⁵ further emphasized that surgical exploration is mandatory for dermal sinus tracts located above the gluteal folds.

Spinal intramedullary abscesses are a severe complication of CDS. Among the various septic presentations of CDS, meningitis is the most common and spinal intramedullary abscess is the least common finding³. Prompt surgical drainage of the abscess cavity through a dorsal midline myelotomy is the best choice to control the infection and to enhance functional recovery. In the literature, some patients attained complete recovery of neurological functions, but others had only a partial improvement after surgery¹¹. The outcome may depend on the degree of septic involvement of the spinal cord and the time to diagnosis and surgical intervention. In the series of Ramnarayan et al.¹⁰, all patients over the age of 1 year had purulent infection or neurological deficits at presentation, and surgical morbidity paralleled the time interval to definitive treatment. Our patient had partial recovery of neurological deficits after treatment and rehabilitation. A delay in the proper diagnosis from the onset of fever and gait disturbance may prevent optimal recovery despite emergency surgical intervention.

CONCLUSION

Failure to detect a CSD may lead to catastrophic infection in the central nervous system. An early diagnosis and prompt surgical intervention are required before the onset of severe infection. Clinicians should be alert to any atypical-looking skin dimples in the midline of infants and children.

• Acknowledgements

This study was supported by a grant from Seoul National University Hospital (No. 0420120910) and a grant from the Korea Healthcare technology R&D Project, Ministry for Health, Welfare & Family Affairs, Republic of Korea (A120099).

References

1. Ackerman LL, Menezes AH : Spinal congenital dermal sinuses : a 30-year experience. *Pediatrics* 112 (3 Pt 1) : 641-647, 2003
2. Amacher AL : Intramedullary epidermoid associated with an intramedullary spinal abscess secondary to a dermal sinus. *Neurosurgery* 31 : 979, 1992
3. Benzil DL, Epstein MH, Knuckey NW : Intramedullary epidermoid associated with an intramedullary spinal abscess secondary to a dermal sinus. *Neurosurgery* 30 : 118-121, 1992

4. Drolet BA : Cutaneous signs of neural tube dysraphism. *Pediatr Clin North Am* 47 : 813-823, 2000
5. Elton S, Oakes WJ : Dermal sinus tracts of the spine. *Neurosurg Focus* 10 : e4, 2001
6. Higgins JC, Axelsen F : Simple dimple rule for sacral dimples. *Am Fam Physician* 65 : 2435, 2002
7. Kriss VM, Desai NS : Occult spinal dysraphism in neonates : assessment of high-risk cutaneous stigmata on sonography. *AJR Am J Roentgenol* 171 : 1687-1692, 1998
8. Lee CS, Phi JH, Kim SK, Cho BK, Wang KC : Spinal congenital dermal sinus with dual ostia. *J Neurosurg Pediatr* 3 : 407-411, 2009
9. Morandi X, Mercier P, Fournier HD, Brassier G : Dermal sinus and intramedullary spinal cord abscess. Report of two cases and review of the literature. *Childs Nerv Syst* 15 : 202-206; discussion 207-208, 1999
10. Ramnarayan R, Dominic A, Alapatt J, Buxton N : Congenital spinal dermal sinuses : poor awareness leads to delayed treatment. *Childs Nerv Syst* 22 : 1220-1224, 2006
11. Weprin BE, Oakes WJ : Coccygeal pits. *Pediatrics* 105 : E69, 2000