

Review

Open Access

Liver metastases of neuroendocrine tumours; early reduction of tumour load to improve life expectancy

Liesbeth M Veenendaal¹, Inne HM Borel Rinkes¹, Cornelis JM Lips² and Richard van Hilleegersberg*¹

Address: ¹Department of Surgery, University Medical Center Utrecht, The Netherlands and ²Department of Clinical Endocrinology, University Medical Center Utrecht, The Netherlands

Email: Liesbeth M Veenendaal - l.m.veenendaal@umcutrecht.nl; Inne HM Borel Rinkes - i.h.m.borelrinkes@umcutrecht.nl; Cornelis JM Lips - lips05@zonnet.nl; Richard van Hilleegersberg* - r.vanhilleegersberg@umcutrecht.nl

* Corresponding author

Published: 26 June 2006

Received: 07 April 2006

World Journal of Surgical Oncology 2006, 4:35 doi:10.1186/1477-7819-4-35

Accepted: 26 June 2006

This article is available from: <http://www.wjso.com/content/4/1/35>

© 2006 Veenendaal et al; licensee BioMed Central Ltd.

This is an Open Access article distributed under the terms of the Creative Commons Attribution License (<http://creativecommons.org/licenses/by/2.0>), which permits unrestricted use, distribution, and reproduction in any medium, provided the original work is properly cited.

Abstract

Background: Neuroendocrine tumours frequently metastasize to the liver. Although generally slowly progressing, hepatic metastases are the major cause of carcinoid syndrome and ultimately lead to liver dysfunction, cardiac insufficiency and finally death.

Methods: A literature review was performed to define the optimal treatment strategy and work-up in patients with neuroendocrine hepatic metastases. Based on this, an algorithm for the management of these patients was established.

Results: Platelet serotonin and chromogranin A are useful biomarkers for detection and follow-up of neuroendocrine tumour. Helical computed tomography and somatostatin receptor scintigraphy are the most sensitive diagnostic modalities. Surgical debulking is an accepted approach for reducing hormonal symptoms and to establish better conditions for medical treatment, but is frequently impossible due to the extent of disease. A novel approach is the local ablation of tumour by thermal coagulation using therapies such as radiofrequency ablation (RFA) or laser induced thermotherapy (LITT). These techniques preserve normal liver tissue. There is a tendency to destroy metastases early in the course of disease, thereby postponing or eliminating the surgically untreatable stage. This can be combined with postoperative radioactive octreotide to eliminate small multiple metastases. In patients with extensive metastases who are not suitable for local destruction, systemic therapy by octreotide, ¹³¹I-MIBG treatment or targeted chemo- and radiotherapy should be attempted. A final option for selective patients is orthotopic liver transplantation.

Conclusion: Treatment for patients with neuroendocrine hepatic metastases must be tailored for each individual patient. When local ablative therapies are used early in the course of the disease, the occurrence of carcinoid syndrome with end stage hepatic disease can be postponed or prevented.

Background

Carcinoids are neuroendocrine tumours that arise from neoplastic proliferation of enterochromaffin or Kulchitsky cells [1]. In 1963, carcinoids were classified according to their embryologic site of origin as foregut carcinoids (respiratory tract, stomach, duodenum, biliary system and pancreas), midgut carcinoids (small intestine, appendix, cecum, and proximal colon), and hindgut carcinoids (distal colon and rectum) [2]. According to the WHO classification in 2000, distinction was made between well-differentiated neuroendocrine tumours (benign behaviour or uncertain malignant potential, <2% Ki67 positive cells), well-differentiated neuroendocrine carcinomas (low grade malignancy, presence of metastasis and/or invasiveness), and poorly differentiated neuroendocrine carcinomas of high-grade malignancy (usually small cell, >15% Ki67 positive cells) [3]. Ki67 is an immunohistochemical biomarker for cell proliferation.

Neuroendocrine hepatic metastases represent about 10% of all hepatic metastatic neoplasm's [4]. These metastases occur in about 25–90% of patients with neuroendocrine tumours. Although these tumours run a rather indolent course, the 5-year survival of patients with neuroendocrine tumours and liver metastases is 40% compared with 75–99% in those free of liver metastases [5-7]. Neuroendocrine liver metastases often progress slowly but may cause significant symptoms due to their size and/or hormone production. Ultimately the hepatic tissue is replaced by tumour, causing mechanical pressure to surrounding tissues, liver dysfunction, cardiac failure and finally death. Manifestations of the carcinoid syndrome usually occur in patients with liver metastases due to production and release of serotonin directly in the blood stream. Classically, the carcinoid syndrome is characterised by episodic flushing, tachycardia, diarrhoea and bronchospasm [8]. Treatment of neuroendocrine hepatic metastases is aiming at symptomatic improvement and reduction of hormonal hypersecretion by elimination of the tumour. However, the most effective management and timing of treatment remains unclear [9,10]. Here, we have reviewed the literature and used our own experience to provide a balanced guideline for imaging and management of patients with neuroendocrine hepatic metastases.

Biochemical diagnosis

Neuroendocrine tumours of the small intestine produce large quantities of serotonin (5-hydroxytryptamine), reflected in raised levels of platelet serotonin and a high urinary excretion of 5-hydroxyindoleacetic acid (5-HIAA) [11,12]. The platelet serotonin concentration is more sensitive in the detection of carcinoid tumours than urinary 5-HIAA, particularly in tumours with relatively low serotonin production [13,14]. Circulating free serotonin is removed very rapidly and effectively by the liver. In con-

trast to urinary 5-HIAA, platelet serotonin is not effected by serotonin-containing diet [15]. Hence platelet serotonin is the most discriminating marker for detection of most neuroendocrine tumours. However, in hindgut carcinoids, hydroxylase and decarboxylase are absent and no serotonin is produced.

Plasma chromogranin A (CgA) has been claimed the most sensitive and specific marker of tumour volume [16]. CgA is a precursor for several peptides and is stored in secretory granules of neuroendocrine tissue [17]. Circulating CgA allows early detection of persistent or recurrent neuroendocrine tumours [18]. The highest CgA levels were noted in metastatic midgut lesions [19].

Both tumour markers, platelet serotonin and CgA, can be reliably used for diagnosis of neuroendocrine tumour and for monitoring the outcome of treatment in individual patients.

Work-up of patients with neuroendocrine hepatic metastases

Several imaging modalities are available to detect hepatic metastases and their primary neuroendocrine tumours. Conventional ultrasonography (US), computed tomography (CT), magnetic resonance imaging (MRI) and somatostatin receptor scintigraphy (SRS) are the cornerstones for the localisation of neuroendocrine tumours with sensitivities of respectively 46%, 42%, 43% and 90% [20-23]. The use of helical computed tomography (hCT) has increased the diagnostic sensitivity in the localisation of both primary (94%) and metastatic tumour (lymph node 69%, liver 94%) [24]. As somatostatin receptor subtype 2 is present in almost 80% of neuroendocrine tumours, binding ¹¹¹Indium-labelled octreotide can be used for both disease staging and to indicate whether or not somatostatin analogues can be used in the treatment of these tumours [25]. SRS is very helpful in detecting bone and lung metastases and thereby aids in confirming or refuting the presence of extrahepatic disease. Based on these considerations, both hCT and SRS should be performed in all patients prior to treatment.

Treatment modalities

Surgical resection

Surgical resection is to be considered when no extrahepatic disease is present. Hemihepatectomy or segmental resection is feasible when metastases are solitary and resection can be radical with enough functional liver tissue remaining. Symptomatic response rates have been reported to be 90% for a mean duration of 19.3 months after surgical resection [26]. Unfortunately, neuroendocrine metastases are usually multiple and diffuse and therefore resection is often impossible. Furthermore, in most patients treated by surgical resection with curative

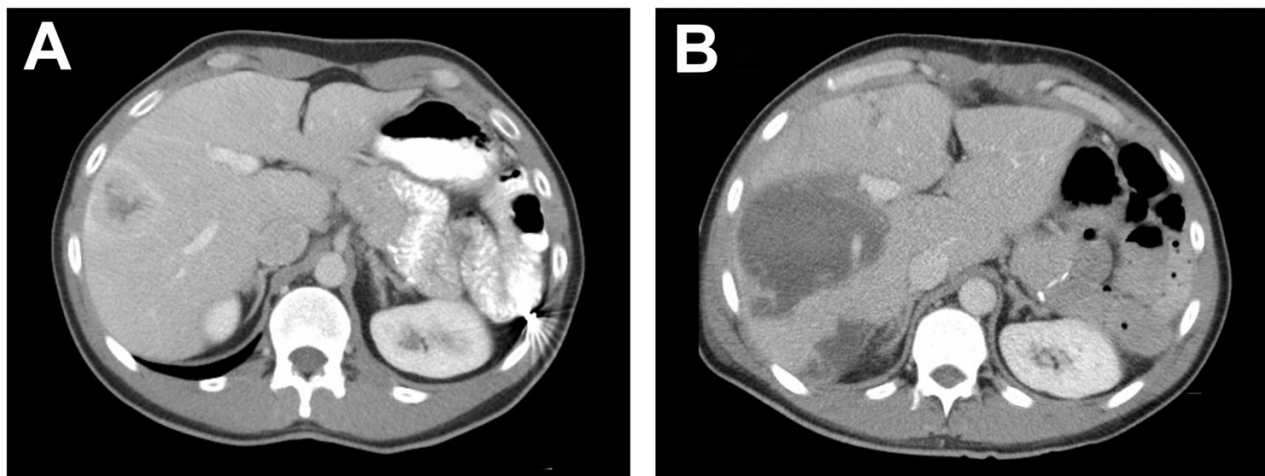


Figure 1

CT scan of the liver of a 34-year old man with metastases of a neuroendocrine tumour of the pancreas. Before LITT the CT scan shows a metastases of 4.7 cm in diameter in segment VII and a second metastases of 2.0 cm in diameter in segment VII subcapsular (not visible) of the liver (figure 2A). Control CT scan one week after LITT showing a coagulation lesion in segment VII of 9.0 cm in diameter and subcapsular in segment VII of 4.8 cm in diameter (figure 2B).

intent, additional metastases develop that presumably were occult at the time of surgery [26]. Therefore even in resectable cases, liver tissue sparing therapies should be considered, allowing future repeated treatment.

Local ablative therapy

Local therapy using radiofrequency ablation (RFA) or laser induced thermotherapy (LITT) is a well-established treatment for unresectable hepatocellular carcinomas and liver metastases from colorectal carcinomas [27,28]. A few small series and case reports have also shown good response in neuroendocrine hepatic metastases [29-33]. Up until now, a disadvantage of these therapies has been the relatively small volume of tissue that can be coagulated. Clinical trials with RFA have shown that complete tumour eradication is more likely to occur with small tumours, i.e. diameter ≤ 4 cm, than with large tumours [34]. With the use of simultaneous multiple fiber LITT or next generation bipolar RFA, we have been able to ablate tumours as large as 7 cm in diameter [35] (Figure 1). Furthermore, up to 7 lesions at one time may be ablated using specialized techniques to increase lesion size [36]. It has been reported that cytoreduction of $\geq 90\%$ is adequate for durable symptomatic relief [9]. In our most recent strategy, we aim at complete destruction of the intrahepatic tumour to prevent the occurrence of surgically untreatable disease. The largest reported study of 34 patients with neuroendocrine hepatic metastases treated with RFA showed symptom relief in 95% of these patients with significant or complete symptom control in 80%, for a mean of 10 months [29]. Even in patients with extrahe-

patic disease and liver metastases ablation may also provide symptom relief [29]. The complication rate is 5–10% and the mortality rate is about 0.5% [37-39]. Therefore these techniques are especially suitable for repeated treatment in patients in which local recurrence or new metastases developing during follow up.

All invasive procedures during surgery such as liver resection and ablation and even anaesthesia can induce hormone release and even provoke a life-threatening carcinoid crisis [40]. In the severe crisis of carcinoid syndrome the flush is usually accompanied by hypotension and occasionally shock. Injection of octreotide, the long-acting analog of somatostatin, usually prevents or aborts this vasomotor reaction [41]. Studies have shown that the use of octreotide intraoperatively for patients with metastatic carcinoid tumours undergoing surgery with manipulation of tumour is associated with a decreased frequency of intraoperative complications [42,43].

Arterial embolisation

Hepatic arterial embolisation with or without chemotherapy is a palliative option for those unresectable lesions in which the predominant mass of tumour is localised in one of the liver lobes. In the past, more radical blunt techniques to occlude the main hepatic artery were used. However, recently, superselective techniques have become available with the advantage of leaving the main segmental arteries open. Contraindications of hepatic arterial embolisation include complete portal vein occlusion, hepatic failure and previous biliary anastomoses

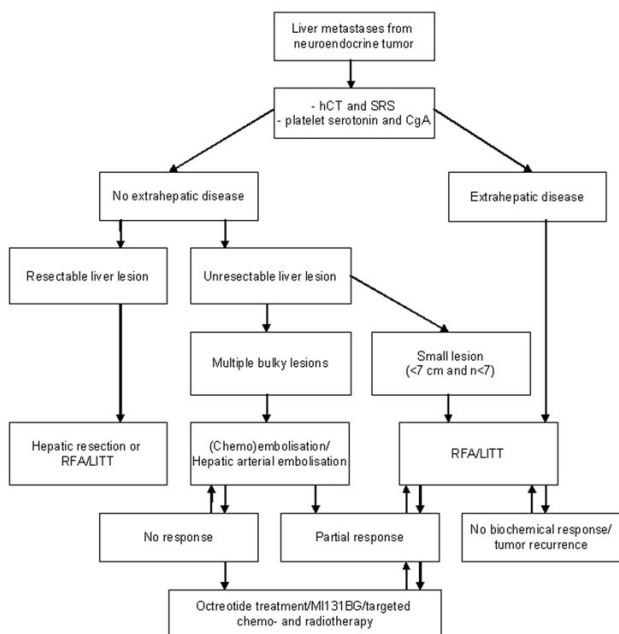


Figure 2

Protocol for management of patients with neuroendocrine hepatic metastases. CT, computed tomography; MRI, magnetic resonance imaging; SRS, somatostatin receptor scintigraphy; RFA, radiofrequency ablation; LITT, laser induced thermotherapy; ¹³¹I-MIBG, Iodine-131 metaiodobenzylguanidine.

[44]. Symptomatic improvement after hepatic arterial embolisation is reported to occur in 64–90% [45,46]. Reports on chemoembolisation show a slight better biochemical response and tumour response than hepatic artery embolisation [47]. Embolisation techniques are associated with mortality rates of about 5% and almost all patients develop the 'postembolic syndrome' (elevated liver function tests and fever) although mostly transient and in different grades of severity [48-50]. In addition, serious complications have occurred in about 10% of patients treated with hepatic embolisation for neuroendocrine tumours [51]. Complications can be reduced by prophylactic octreotide infusion during the procedure and the use of forced diuresis during and after the embolisation. In case of partial or no response, supplementary embolisation or additional RFA or LITT could be an option. In selected cases with good response to embolisation a partial hepatic resection may be considered.

Pharmacological therapy

Pharmacological therapy consists of long-lasting octreotide injections, Iodine-131 metaiodobenzylguanidine (¹³¹I-MIBG), interferon-α (IFN-α) or targeted chemo- and radiotherapy. Octreotide is a somatostatin analogue and

appears to be an efficacious treatment for carcinoid syndrome, reducing symptoms in more than 70% of patients [52,53]. Some patients with partial response after local ablation have relief of symptoms by additional treatment with octreotide [37]. Prolonged symptomatic relief can be provided by ¹³¹I-MIBG therapy. In individual cases, improved quality of life may be obtained [54]. Even improved survival was seen by symptomatic response to ¹³¹I-MIBG treatment [55]. The clinical benefit of IFN-α treatment has been limited by their modest anti-tumour effect as well as serious side-effects [56,57]. In addition, combination treatment with octreotide and IFN-α showed little advantage. Biochemical responses were observed in 72–77%, however no objective tumour regression was observed [57,58]. A promising approach is the concept of somatostatin receptor (SSTR)-mediated chemo- or radiotherapy of SSTR-expressing metastatic carcinoid. Currently, clinical trials with cytotoxic compounds, such as methotrexate and doxorubicin, linked to an analog of somatostatin are under way [59,60]. Also promising is targeted SSTR-mediated radiotherapy using radionuclides such as ⁹⁰Y and ¹⁷⁷Lu. Experimental studies in patients who have somatostatin-positive tumours show complete remission by the use of tetra-azacyclododecane tetra-acetic acid Tyr³-octreotide [61]. After surgical reduction of tumour load, repeated intermediate-dosage ⁹⁰Y, Tyr-octreotide, ¹⁷⁷Lu or ¹³¹I-MIBG treatment appears to be a reliable and well-tolerated radionuclide therapy and might be a useful adjunct in patients with malignant neuroendocrine carcinoma, providing long-lasting palliation and prolonged survival [62].

Liver transplantation

Young patients with surgically unresectable tumours, hepatomegaly and uncontrollable symptoms, in whom all other therapies have been unsuccessful, may benefit from liver transplantation [63]. However, liver transplantation for metastatic disease is controversial and in most cases even contraindicated, as the results have been poor due to complex operative procedures [64-66]. Well differentiated tumours and a low proliferation rate (Ki67<10%) are important selection criteria [67]. Overall, post-operative mortality of 19% is reported in a group of 31 patients undergoing orthotopic liver transplantation for metastatic neuroendocrine tumours [65]. In the same study, 50% of the carcinoid patients suffered from one or more major complications i.e. peritoneal bleeding, acute/chronic rejection and acute pancreatitis [65].

Conclusion

Hepatic metastases are frequently encountered in patients with digestive endocrine tumours and their presence plays an important role in quality of life and overall prognosis. Tailored multimodality treatment is the key to increase survival and achieve good palliation in patients with

hepatic metastases from neuroendocrine tumours. A flow sheet such as presented in figure 2 can be helpful in the decision of choice of treatment. Determination of platelet serotonin and plasma CgA is useful for detection of neuroendocrine tumour and to evaluate therapy efficiency. Visualisation of neuroendocrine hepatic metastases should be performed by hCT/MRI and SRS. Determination of platelet serotonin and plasma CgA is useful for detection of neuroendocrine tumour and to evaluate therapy efficiency. The proliferation marker Ki67 is a very important tool in guiding the type of treatment. Surgery is the treatment of choice for hepatic metastases however cure is frequently impossible due to the extent of disease. Treatment aimed at cytoreduction of hepatic metastasis and diminished secretion of bioactive amines may achieve good palliation. Tumour destruction by RFA or LITT provides a novel liver preserving option. These techniques will now be used more often as liver preserving option to treat patients early in the course of their disease postponing drug intervention and preventing the end stage carcinoid syndrome and thereby improving life expectancy.

Competing interests

The author(s) declare that they have no competing interests.

Authors' contributions

LV reviewed the literature and drafted the manuscript. IBR and CL critically reviewed the paper and were involved in the preparation of the final manuscript. RH was involved in the conception of the work and manuscript preparation. All authors read and approved final version for publication.

References

- Rindi G, Bordi C: **Highlights of the biology of endocrine tumours of the gut and pancreas.** *Endocr Relat Cancer* 2003, **10**:427-436.
- Williams ED, Sandler M: **The classification of carcinoid tumours.** *Lancet* 1963, **1**:238-239.
- Solcia E, Kloppel G, Sobhin LH: **Histological typing of endocrine tumours.** In *International histological classification of endocrine tumours* Springer-Verlag: New York; 2000.
- Benevento A, Boni L, Frediani L, Ferrari A, Dionigi R: **Result of liver resection as treatment for metastases from noncolorectal cancer.** *J Surg Oncol* 2000, **74**:24-29.
- Godwin JD: **Carcinoid tumors. An analysis of 2,837 cases.** *Cancer* 1975, **36**:560-569.
- McDermott EW, Guduric B, Brennan MF: **Prognostic variables in patients with gastrointestinal carcinoid tumours.** *Br J Surg* 1994, **81**:1007-1009.
- Zeitels J, Naunheim K, Kaplan EL, Straus F: **Carcinoid tumors: a 37-year experience.** *Arch Surg* 1982, **117**:732-737.
- Oates JA: **The carcinoid syndrome.** *N Engl J Med* 315:702-704. 11-9-1986
- Chamberlain RS, Canes D, Brown KT, Saltz L, Jarnagin W, Fong Y, Blumgart LH: **Hepatic neuroendocrine metastases: does intervention alter outcomes?** *J Am Coll Surg* 2000, **190**:432-445.
- Chen H, Hardacre JM, Uzar A, Cameron JL, Choti MA: **Isolated liver metastases from neuroendocrine tumors: does resection prolong survival?** *J Am Coll Surg* 1998, **187**:88-92.
- Farthing MJ: **5-Hydroxytryptamine and 5-hydroxytryptamine-3 receptor antagonists.** *Scand J Gastroenterol Suppl* 1991, **188**:92-100.
- Kema IP, de Vries EG, Slooff MJ, Biesma B, Muskiet FA: **Serotonin, catecholamines, histamine, and their metabolites in urine, platelets, and tumor tissue of patients with carcinoid tumors.** *Clin Chem* 1994, **40**:86-95.
- Meijer WG, Kema IP, Volmer M, Willemsse PH, de Vries EG: **Discriminating capacity of indole markers in the diagnosis of carcinoid tumors.** *Clin Chem* 2000, **46**:1588-1596.
- Carling RS, Degg TJ, Allen KR, Bax ND, Barth JH: **Evaluation of whole blood serotonin and plasma and urine 5-hydroxyindole acetic acid in diagnosis of carcinoid disease.** *Ann Clin Biochem* 2002, **39**:577-582.
- Kema IP, Schellings AM, Meiborg G, Hoppenbrouwers CJ, Muskiet FA: **Influence of a serotonin- and dopamine-rich diet on platelet serotonin content and urinary excretion of biogenic amines and their metabolites.** *Clin Chem* 1992, **38**:1730-1736.
- Bajetta E, Ferrari L, Martinetti A, Celio L, Procopio G, Artale S, Zilembo N, Di Bartolomeo M, Seregni E, Bombardieri E: **Chromogranin A, neuron specific enolase, carcinoembryonic antigen, and hydroxyindole acetic acid evaluation in patients with neuroendocrine tumors.** *Cancer* 86:858-865. 1-9-1999
- Hutton JC, Davidson HW, Peshavaria M: **Proteolytic processing of chromogranin A in purified insulin granules. Formation of a 20 kDa N-terminal fragment (betagranin) by the concerted action of a Ca²⁺-dependent endopeptidase and carboxypeptidase H (EC 3.4.17.10).** *Biochem J* 244:457-464. 1-6-1987
- Pirker RA, Pont J, Pohl R, Schutz W, Griesmacher A, Muller MM: **Usefulness of chromogranin A as a marker for detection of relapses of carcinoid tumours.** *Clin Chem Lab Med* 1998, **36**:837-840.
- Nobels FR, Kwekkeboom DJ, Coopmans W, Schoenmakers CH, Lindemans J, De Herder WW, Krenning EP, Bouillon R, Lamberts SW: **Chromogranin A as serum marker for neuroendocrine neoplasia: comparison with neuron-specific enolase and the alpha-subunit of glycoprotein hormones.** *J Clin Endocrinol Metab* 1997, **82**:2622-2628.
- Gibril F, Reynolds JC, Doppman JL, Chen CC, Venzon DJ, Termanini B, Weber HC, Stewart CA, Jensen RT: **Somatostatin receptor scintigraphy: its sensitivity compared with that of other imaging methods in detecting primary and metastatic gastrinomas. A prospective study.** *Ann Intern Med* 125:26-34. 1-7-1996
- Chiti A, Fanti S, Savelli G, Romeo A, Bellanova B, Rodari M, van Graafeiland BJ, Monetti N, Bombardieri E: **Comparison of somatostatin receptor imaging, computed tomography and ultrasound in the clinical management of neuroendocrine gastroentero-pancreatic tumours.** *Eur J Nucl Med* 1998, **25**:1396-1403.
- Frucht H, Doppman JL, Norton JA, Miller DL, Dwyer AJ, Frank JA, Vinayek R, Maton PN, Jensen RT: **Gastrinomas: comparison of MR imaging with CT, angiography, and US.** *Radiology* 1989, **171**:713-717.
- Termanini B, Gibril F, Reynolds JC, Doppman JL, Chen CC, Stewart CA, Sutliff VE, Jensen RT: **Value of somatostatin receptor scintigraphy: a prospective study in gastrinoma of its effect on clinical management.** *Gastroenterology* 1997, **112**:335-347.
- Panzuto F, Falconi M, Nasoni S, Angeletti S, Moretti A, Bezzi M, Gualdi G, Poletti E, Sciuto R, Festa A, Scopinaro F, Corleto VD, Bordi C, Pederzoli P, Delle FG: **Staging of digestive endocrine tumours using helical computed tomography and somatostatin receptor scintigraphy.** *Ann Oncol* 2003, **14**:586-591.
- Kwekkeboom DJ, Krenning EP, Bakker WH, Oei HY, Kooij PP, Lamberts SW: **Somatostatin analogue scintigraphy in carcinoid tumours.** *Eur J Nucl Med* 1993, **20**:283-292.
- Que FG, Sarmiento JM, Nagorney DM: **Hepatic surgery for metastatic gastrointestinal neuroendocrine tumors.** *Cancer Control* 2002, **9**:67-79.
- Liu LX, Zhang WH, Jiang HC: **Current treatment for liver metastases from colorectal cancer.** *World J Gastroenterol* 2003, **9**:193-200.
- Wong SL, Edwards MJ, Chao C, Simpson D, McMasters KM: **Radiofrequency ablation for unresectable hepatic tumors.** *Am J Surg* 2001, **182**:552-557.

29. Berber E, Flesher N, Siperstein AE: **Laparoscopic radiofrequency ablation of neuroendocrine liver metastases.** *World J Surg* 2002, **26**:985-990.
30. Hellman P, Ladjevardi S, Skogseid B, Akerstrom G, Elvin A: **Radiofrequency tissue ablation using cooled tip for liver metastases of endocrine tumors.** *World J Surg* 2002, **26**:1052-1056.
31. Wessels FJ, Schell SR: **Radiofrequency ablation treatment of refractory carcinoid hepatic metastases.** *J Surg Res* 2001, **95**:8-12.
32. Siperstein AE, Rogers SJ, Hansen PD, Gitomirsky A: **Laparoscopic thermal ablation of hepatic neuroendocrine tumor metastases.** *Surgery* 1997, **122**:1147-1154.
33. Meij V, Zuetenhorst JM, van Hillegersberg R, Kroger R, Prevoo W, van Coevorden F, Taal BG: **Local treatment in unresectable hepatic metastases of carcinoid tumors: Experiences with hepatic artery embolization and radiofrequency ablation.** *World J Surg Oncol* 2005, **3**:75.
34. de Baere T, Elias D, Dromain C, Din MG, Kuoch V, Ducreux M, Boige V, Lassau N, Marteau V, Lasser P, Roche A: **Radiofrequency ablation of 100 hepatic metastases with a mean follow-up of more than 1 year.** *AJR Am J Roentgenol* 2000, **175**:1619-1625.
35. Veenendaal LM, de Jager A, Stapper G, Borel Rinkes IHM, van Hillegersberg R: **Multiple fiber laser-induced thermotherapy for ablation of large intrahepatic tumors.** *Photomed Laser Surg* 2006, **24**:3-9.
36. Veenendaal LM, Borel Rinkes IHM, van Hillegersberg R: **Multipolar radiofrequency ablation of large hepatic metastases of endocrine tumours.** *Eur J Gastroenterol Hepatol* 2006, **18**:89-92.
37. Henn AR, Levine EA, McNulty W, Zagoria RJ: **Percutaneous radiofrequency ablation of hepatic metastases for symptomatic relief of neuroendocrine syndromes.** *AJR Am J Roentgenol* 2003, **181**:1005-1010.
38. Curley SA, Marra P, Beaty K, Ellis LM, Vauthey JN, Abdalla EK, Scaife C, Raut C, Wolff R, Choi H, Loyer E, Vallone P, Fiore F, Scordino F, De RV, Orlando R, Pignata S, Daniele B, Izzo F: **Early and late complications after radiofrequency ablation of malignant liver tumors in 608 patients.** *Ann Surg* 2004, **239**:450-458.
39. Poon RT, Ng KK, Lam CM, Ai V, Yuen J, Fan ST, Wong J: **Learning curve for radiofrequency ablation of liver tumors: prospective analysis of initial 100 patients in a tertiary institution.** *Ann Surg* 2004, **239**:441-449.
40. Wettstein M, Vogt C, Cohnen M, Brill N, Kurz AK, Modder U, Haussinger D: **Serotonin release during percutaneous radiofrequency ablation in a patient with symptomatic liver metastases of a neuroendocrine tumor.** *Hepatogastroenterology* 2004, **51**:830-832.
41. Warner RR, Mani S, Profeta J, Grunstein E: **Octreotide treatment of carcinoid hypertensive crisis.** *Mt Sinai J Med* 1994, **61**:349-355.
42. Veall GR, Peacock JE, Bax ND, Reilly CS: **Review of the anaesthetic management of 21 patients undergoing laparotomy for carcinoid syndrome.** *Br J Anaesth* 1994, **72**:335-341.
43. Kinney MA, Warner ME, Nagorney DM, Rubin J, Schroeder DR, Maxson PM, Warner MA: **Perianaesthetic risks and outcomes of abdominal surgery for metastatic carcinoid tumours.** *Br J Anaesth* 2001, **87**:447-452.
44. Roche A: **[Hepatic chemo-embolization].** *Bull Cancer* 1989, **76**:1029-1037.
45. Schell SR, Camp ER, Caridi JG, Hawkins IF Jr: **Hepatic artery embolization for control of symptoms, octreotide requirements, and tumor progression in metastatic carcinoid tumors.** *J Gastrointest Surg* 2002, **6**:664-670.
46. Carrasco CH, Charnsangavej C, Ajani J, Samaan NA, Richli W, Wallace S: **The carcinoid syndrome: palliation by hepatic artery embolization.** *AJR Am J Roentgenol* 1986, **147**:149-154.
47. Diamandidou E, Ajani JA, Yang DJ, Chuang VP, Brown CA, Carrasco HC, Lawrence DD, Wallace S: **Two-phase study of hepatic artery vascular occlusion with microencapsulated cisplatin in patients with liver metastases from neuroendocrine tumors.** *AJR Am J Roentgenol* 1998, **170**:339-344.
48. O'Toole D, Maire F, Ruszniewski P: **Ablative therapies for liver metastases of digestive endocrine tumours.** *Endocr Relat Cancer* 2003, **10**:463-468.
49. Kress O, Wagner HJ, Wied M, Klose KJ, Arnold R, Alfke H: **Transarterial chemoembolization of advanced liver metastases of neuroendocrine tumors – a retrospective single-center analysis.** *Digestion* 2003, **68**:94-101.
50. Kolmannskog F, Kolbenstvedt AN, Schrupf E, Hanssen LE: **Side effects and complications after hepatic artery embolization in the carcinoid syndrome.** *Scand J Gastroenterol* 1991, **26**:557-562.
51. Brown KT, Koh BY, Brody LA, Getrajdman GI, Susman J, Fong Y, Blumgart LH: **Particle embolization of hepatic neuroendocrine metastases for control of pain and hormonal symptoms.** *J Vasc Interv Radiol* 1999, **10**:397-403.
52. Oberg K: **Endocrine tumors of the gastrointestinal tract: systemic treatment.** *Anticancer Drugs* 1994, **5**:503-519.
53. Jacobsen MB, Hanssen LE: **Clinical effects of octreotide compared to placebo in patients with gastrointestinal neuroendocrine tumours. Report on a double-blind, randomized trial.** *J Intern Med* 1995, **237**:269-275.
54. Prvulovich EM, Stein RC, Bomanji JB, Ledermann JA, Taylor I, Ell PJ: **Iodine-131-MIBG therapy of a patient with carcinoid liver metastases.** *J Nucl Med* 1998, **39**:1743-1745.
55. Safford SD, Coleman RE, Gockerman JP, Moore J, Feldman J, Onaitis MW, Tyler DS, Olson JA Jr: **Iodine-131 metaiodobenzylguanidine treatment for metastatic carcinoid.** *Cancer* **101**:1987-1993. 28-9-2004
56. Oberg K, Eriksson B: **The role of interferons in the management of carcinoid tumours.** *Br J Haematol* 1991, **79**(Suppl 1):74-77.
57. Faiss S, Pape UF, Bohmig M, Dorffel Y, Mansmann U, Golder W, Riecken EO, Wiedenmann B: **Prospective, randomized, multicenter trial on the antiproliferative effect of lanreotide, interferon alfa, and their combination for therapy of metastatic neuroendocrine gastroenteropancreatic tumors – the International Lanreotide and Interferon Alfa Study Group.** *J Clin Oncol* **21**:2689-2696. 15-7-2003
58. Pape UF, Wiedenmann B: **Adding interferon-alpha to octreotide slows tumour progression compared with octreotide alone but evidence is lacking for improved survival in people with disseminated midgut carcinoid tumours.** *Cancer Treat Rev* 2003, **29**:565-569.
59. Schally AV, Nagy A: **Cancer chemotherapy based on targeting of cytotoxic peptide conjugates to their receptors on tumors.** *Eur J Endocrinol* 1999, **141**:1-14.
60. Nagy A, Schally AV: **Targeted cytotoxic somatostatin analogs: a modern approach to the therapy of various cancers.** *Drugs Future* 2001, **26**:261-270.
61. De Jong M, Valkema R, Jamar F, Kvols LK, Kwekkeboom DJ, Breeman WA, Bakker WH, Smith C, Pauwels S, Krenning EP: **Somatostatin receptor-targeted radionuclide therapy of tumors: preclinical and clinical findings.** *Semin Nucl Med* 2002, **32**:133-140.
62. Lam MG, Lips CJ, Jager PL, Dullaart RP, Lentjes EG, van Rijk PP, de Klerk JM: **Repeated [131I]metaiodobenzylguanidine therapy in two patients with malignant pheochromocytoma.** *J Clin Endocrinol Metab* 2005, **90**:5888-5895.
63. Florman S, Toure B, Kim L, Gondolesi G, Roayaie S, Krieger N, Fishbein T, Emre S, Miller C, Schwartz M: **Liver transplantation for neuroendocrine tumors.** *J Gastrointest Surg* 2004, **8**:208-212.
64. Penn I: **Hepatic transplantation for primary and metastatic cancers of the liver.** *Surgery* 1991, **110**:726-734.
65. Le Treut YP, Delpero JR, Dousset B, Cherqui D, Segol P, Manton G, Hannoun L, Benhamou G, Launois B, Boillot O, Domergue J, Bismuth H: **Results of liver transplantation in the treatment of metastatic neuroendocrine tumors. A 31-case French multicentric report.** *Ann Surg* 1997, **225**:355-364.
66. Lehnert T: **Liver transplantation for metastatic neuroendocrine carcinoma: an analysis of 103 patients.** *Transplantation* **66**:1307-1312. 27-11-1998
67. Ahlman H, Friman S, Cahlin C, Nilsson O, Jansson S, Wangberg B, Olsson M: **Liver transplantation for treatment of metastatic neuroendocrine tumors.** *Ann N Y Acad Sci* 2004, **1014**:265-269.