

# Maxillary third molars with horizontal impaction: A cross-sectional study using computed tomography in young Japanese patients

Shinpei Matsuda  and Hitoshi Yoshimura

## Abstract

**Objective:** To examine the anatomical characteristics of impacted maxillary third molars to help predict and prevent possible adverse events during extraction.

**Methods:** This retrospective study enrolled young Japanese patients that were assessed for third molar extraction. Patients with maxillary third molar impaction presenting with no space between the maxillary second molar and the occlusal surface of the maxillary third molar were analysed using computed tomography data.

**Results:** In this study, a total of 663 patients aged 20–29 years were examined for third molar extraction and 26 teeth in 23 patients were analysed. The mean  $\pm$  SD angle between the second and third molar axes was  $54.2^\circ \pm 7.5^\circ$  and the mean  $\pm$  SD length of the maxillary third molar was  $16.1 \pm 1.9$  mm. The maxillary third molars showed close or extensive contact with the maxillary sinus and computed tomography did not show any bone from the maxillary sinus floor. Furthermore, in all patients, the crowns of the third molars were not completely covered by the alveolar bone.

**Conclusions:** Maxillary third molars with horizontal impaction showed close or extensive contact with the maxillary sinus and their crowns were not completely covered by the alveolar bone.

## Keywords

Maxillary third molar, impacted condition, computed tomography, maxillary sinus, migration, oroantral perforation

Date received: 24 November 2021; accepted: 27 January 2022

---

Department of Dentistry and Oral Surgery, Unit of Sensory and Locomotor Medicine, Division of Medicine, Faculty of Medical Sciences, University of Fukui, Fukui, Japan

---

## Corresponding author:

Shinpei Matsuda, Department of Dentistry and Oral Surgery, Unit of Sensory and Locomotor Medicine, Division of Medicine, Faculty of Medical Sciences, University of Fukui, 23-3 Matsuokashimoaizuki, Eiheiji-cho, Yoshida-gun, Fukui 910-1193, Japan.  
E-mail: shinpeim@u-fukui.ac.jp



## Introduction

Extraction of mandibular and maxillary third molars is a common oral and maxillofacial surgical procedure. However, this procedure is an important topic of clinical research because of the range of potential complications. Clinicians performing mandibular third molar extraction procedures should be aware of the potential for nerve damage, bone fracture, emphysema and root or instrument migration;<sup>1-4</sup> and they should pay close attention to migration, infection and the formation and persistence of oroantral perforation during maxillary third molar extraction procedures.<sup>5-7</sup> An oroantral perforation is a connection between the oral cavity and maxillary sinus, and it causes maxillary sinusitis or the formation of an oroantral fistula, which is associated with oral bacterial infection.<sup>7</sup> The impacted condition and tooth development status of the maxillary third molars and the anatomical features of the maxillary sinus floor may be related to oroantral perforation.<sup>7,8</sup>

Maxillary third molars usually erupt in the late teenage years and are often considered for extraction in the patient's 20s. On the other hand, there are cases where the maxillary third molar does not erupt due to various oral conditions including dentition. According to Archer's modified classification of maxillary third molars, horizontal impaction is defined as an impacted condition with no space between the maxillary second molar and the occlusal surface of the maxillary third molar.<sup>9</sup> The maxillary third molar rarely erupts in cases of horizontal impaction. Following examination of 845 maxillary third molars, a previous study reported that the incidence of horizontal maxillary third molars was 0.5% and that the impaction depth of the maxillary third molar was associated with the possibility of oroantral perforation.<sup>10</sup> This condition can make extraction difficult and

lead to instrumentation into the maxillary sinus. At present, there are no reports providing detailed analyses of maxillary third molars with horizontal impaction. Horizontal impaction of the maxillary third molars can be confirmed by orthopantomography examination. Therefore, an anatomical analysis based on computed tomography (CT) images of this condition will provide useful clinical information to oral and maxillofacial surgeons and general dental physicians that only have access to orthopantomography.

In this study, an anatomical analysis of maxillary third molar cases with horizontal impaction was undertaken based on sagittal slices of CT images obtained from Japanese patients in their 20s, taking into account periodontitis and root formation of the maxillary second and/or third molars.

## Patients and methods

### Study participants

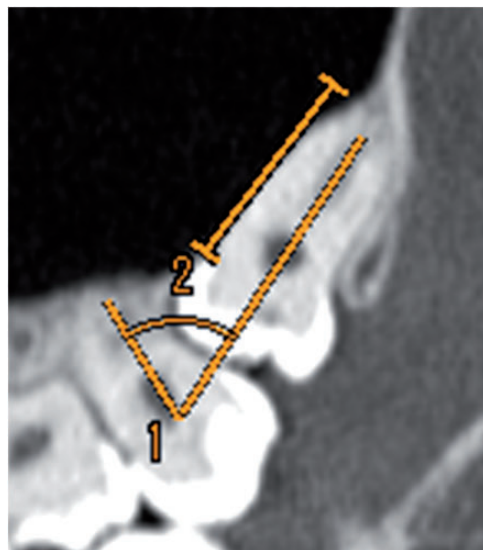
This retrospective study enrolled patients that were assessed for third molar extraction in the Department of Dentistry and Oral Surgery, Unit of Sensory and Locomotor Medicine, Division of Medicine, Faculty of Medical Sciences, University of Fukui, Fukui, Japan between January 2016 and December 2020. The inclusion criteria were as follows: (i) patients undergoing CT examination (slice width: 1 mm) for preoperative assessment for third molar extraction; (ii) Japanese individuals (male and female) aged 20–29 years; (iii) maxillary third molars (on either side) showing horizontal impaction defined by the absence of space between the maxillary second molar and the occlusal surface of the maxillary third molar. The exclusion criteria were as follows: (i) dental caries in the maxillary second and/or third molars that could influence the eruption of the maxillary third

molars; (ii) bone destruction around the maxillary third molars due to benign or malignant lesions.

This retrospective study was approved by the Institutional Research Board (Ethical Committee of the Faculty of Medical Sciences, University of Fukui, Fukui, Japan; no. 20210006). There were no ethical issues related to the conduct of this study since this was a retrospective study conducted using CT examination images obtained for clinical treatment. The authors declare that all methods were conducted in accordance with the relevant guidelines and regulations (Declaration of Helsinki). Verbal informed consent was obtained from all participants at the time of their dental examinations. The Ethical Committee of the Faculty of Medical Sciences, University of Fukui approved this procedure because the data for this retrospective study had been released to the public.

### Data extraction

The general characteristics of patients, including their sex, age and the location of the target teeth, were recorded. For anatomical assessment of the maxillary third molar based on CT images, the authors examined the following characteristics related to horizontal impaction of maxillary third molars: (i) the angle formed by the tooth axes of the maxillary second and third molars in the sagittal CT slices; (ii) the impaction depth, which was determined from the alveolar bone thickness on the crown side of the maxillary third molar; (iii) the length of the maxillary third molar, measured from the occlusal surface to the root apex in the sagittal slices; and (iv) the presence of contact between the maxillary third molar and the maxillary sinus, and the length of the contact range in the sagittal slices (Figure 1).



**Figure 1.** Sagittal computed tomography image displaying the angle formed between the tooth axis of the maxillary second and third molars (1) and the length of the contact range between the maxillary third molar and the maxillary sinus (2).

### Results

A total of 663 patients aged 20–29 years were examined for third molar extraction. Of these, 26 teeth in 23 patients were identified and selected based on the inclusion and exclusion criteria. Good visibility of the CT images was achieved in all patients. The patient sample consisted of eight men (34.8%) and 15 women (65.2%). Their mean  $\pm$  SD age was  $24.7 \pm 2.9$  years (range, 21–29 years). A maxillary third molar with horizontal impaction was found on the right side in 10 patients (43.5%), on the left side in 10 patients (43.5%) and on bilateral sides in three patients (13.0%).

The mean  $\pm$  SD angle formed by the tooth axes of the maxillary second and third molars in sagittal slices was  $54.2^\circ \pm 7.5^\circ$  (range,  $42.1$ – $68.8^\circ$ ) (Table 1). None of the patients showed alveolar bone on the side of the maxillary third molar crown.

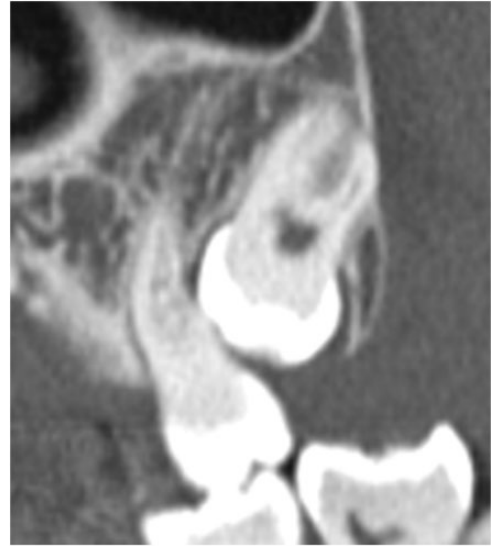
**Table 1.** Anatomical characteristics of the maxillary third molar in patients ( $n = 23$ ) identified as having maxillary third molars (on either side) showing horizontal impaction ( $n = 26$ ).

	<i>n</i>	%
Angle formed by the tooth axis of the mandibular second and third molars,		
<40.0	0	0.0
40.1–50.0	9	34.6
50.1–60.0	11	42.3
60.1–70.0	6	23.1
>70.0	0	0.0
Length of the maxillary third molar, mm		
<10.0	0	0.0
10.1–12.0	1	3.8
12.1–14.0	1	3.8
14.1–16.0	8	30.8
16.1–18.0	12	46.2
>18.0	4	15.4
Contact between the maxillary third molar and the maxillary sinus		
Present	24	92.3
Absent	2	7.7
Length of the contact range between the maxillary third molar and maxillary sinus, mm		
<5.0	3	12.5
5.1–10.0	14	58.3
10.1–15.0	5	20.8
>15.0	2	8.3

The mean  $\pm$  SD length of the maxillary third molar from the occlusal surface to the root apex was  $16.1 \pm 1.9$  mm (range, 10.8–19.1 mm). Contact between the maxillary third molar and the maxillary sinus was observed in 24 teeth (92.3%), while two teeth showed no contact (Figure 2). The mean  $\pm$  SD length of the contact range in these 24 teeth was  $8.1 \pm 3.3$  mm (range, 3.8–15.5 mm).

## Discussion

This current study clarified the anatomical features of maxillary third molars with horizontal impaction. The incidence of



**Figure 2.** Sagittal computed tomography image showing a patient with no contact between the maxillary third molar and the maxillary sinus.

bilateral horizontal impaction in this study was 13.0%. The mean  $\pm$  SD angle between the second and third molar axes was  $54.2^\circ \pm 7.5^\circ$  and the mean  $\pm$  SD length of the maxillary third molar was  $16.1 \pm 1.9$  mm. In addition, these maxillary third molars showed close or extensive contact with the maxillary sinus and the CT images did not show any bone from the maxillary sinus floor in 24 out of 26 teeth. Furthermore, in all patients, the crowns of the third molars were not completely covered by the alveolar bone.

When rare cases of maxillary third molars with horizontal impaction are confirmed by orthopantomography, surgeons must carefully assess the risk of formation and persistence of oroantral perforation. In addition, a precise surgical procedure is required to avoid damaging the maxillary sinus mucosa. The extraction socket must be closed as tightly as possible with the epithelium and dehiscence of the blood clot should be prevented. Furthermore, periodontitis and gingivitis should be prevented

by keeping the area around the second molars clean to avoid infection of the maxillary third molars, as most maxillary third molars with horizontal impaction are covered only by the gingiva. The importance of CT, including cone-beam CT, in various dental fields has been recognized in recent years.<sup>7</sup> The results of this current study further validate the suggestion that preoperative CT examination before extraction of maxillary third molars with horizontal impaction as defined in this current study could yield useful clinical information for the extraction procedure.<sup>7</sup>

The results of this current study suggest an association between horizontal impaction of the maxillary third molar and the maxillary sinus. In contrast, two teeth showed no contact between the maxillary third molar and the maxillary sinus in this current study and growth of the maxillary sinus could not be determined as a factor influencing the impacted condition of the maxillary third molar.

Extraction of horizontal maxillary third molars can be considered as a pretreatment for orthodontic treatment or in cases where third molars become infected, which demonstrates the potential clinical uses of this current report. Furthermore, obtaining data from young adult participants was valuable because aging is associated with tooth loss and alveolar bone loss due to periodontal disease and dental caries.<sup>11,12</sup>

Oral and maxillofacial surgeons that perform maxillary third molar extraction must also be familiar with how to deal with any complications including migration and persistence of oroantral perforation. The maxillary sinus is the most common site of migration of the maxillary third molar and migration into the infratemporal fossa and the buccal fat pad has also been reported.<sup>13,14</sup> Therefore, if the maxillary third molar has migrated, imaging examinations should be performed first before exploring the maxillary sinus. In cases of

oroantral perforation, closing methods, such as the buccal advancement flap, palatal rotational flap, buccal fat pad technique and a method using platelet-rich fibrin, have been reported.<sup>15</sup> To avoid the formation and persistence of oroantral perforation, dehiscence of the blood clot should be prevented with tight suturing.

This current study had several limitations. First, the number of patients included in the study was small because impacted horizontal maxillary third molars are rare. Secondly, this study only included young Japanese people, and therefore, did not account for the possibility of racial differences related to morphological differences of the maxillary jawbone and maxillary sinus.

In conclusion, maxillary third molars with horizontal impaction showed close or extensive contact with the maxillary sinus and their crowns were not completely covered by the alveolar bone.

### Declaration of conflicting interest

The authors declare that there are no conflicts of interest.

### Funding

This research received no specific grant from funding agency in the public, commercial, or not-for-profit sectors.

### ORCID iD

Shinpei Matsuda  <https://orcid.org/0000-0002-0299-7188>

### References

1. Tolstunov L, Brickeen M, Kamanin V, et al. Is the angulation of mandibular third molars associated with the thickness of lingual bone? *Br J Oral Maxillofac Surg* 2016; 54: 914–919.
2. Sklavos A, Delpachitra S, Jaunay T, et al. Degree of compression of the inferior alveolar canal on cone-beam computed tomography and outcomes of postoperative nerve

- injury in mandibular third molar surgery. *J Oral Maxillofac Surg* 2021; 79: 974–980.
3. Ohta K, Yoshimura H, Ryoke T, et al. Investigation of the electric handpiece-related pneumomediastinum and cervicofacial subcutaneous emphysema in third molar surgery. *J Hard Tissue Biol* 2019; 28: 79–86.
  4. Matsuda S, Yoshimura H, Yoshida H, et al. Breakage and migration of a high-speed dental hand-piece bur during mandibular third molar extraction: Two case reports. *Medicine (Baltimore)* 2020; 99: e19177.
  5. Lee D, Ishii S and Yakushiji N. Displacement of maxillary third molar into the lateral pharyngeal space. *J Oral Maxillofac Surg* 2013; 71: 1653–1657.
  6. Iwai T, Matsui Y, Hirota M, et al. Endoscopic removal of a maxillary third molar displaced into the maxillary sinus via the socket. *J Craniofac Surg* 2012; 23: e295–e296.
  7. Iwata E, Hasegawa T, Kobayashi M, et al. Can CT predict the development of oroantral fistula in patients undergoing maxillary third molar removal? *Oral Maxillofac Surg* 2021; 25: 7–17.
  8. Rothamel D, Wahl G, d’Hoedt B, et al. Incidence and predictive factors for perforation of the maxillary antrum in operations to remove upper wisdom teeth: prospective multicentre study. *Br J Oral Maxillofac Surg* 2007; 45: 387–391.
  9. Archer WH. *Oral and Maxillofacial surgery*. 5th ed. Saunders, Philadelphia, 1975.
  10. Lim AA, Wong CW and Allen JC Jr. Maxillary third molar: patterns of impaction and their relation to oroantral perforation. *J Oral Maxillofac Surg* 2012; 70: 1035–1039.
  11. Matsuda S, Goi T, Yoshida Y, et al. Periodontal disease in preoperative patients with digestive cancer: a retrospective, single-institution experience in Fukui, Japan. *BMC Oral Health* 2021; 21: 3.
  12. Matsuda S, Yoshida H, Yoshimura H, et al. Has the COVID-19 pandemic influenced the oral health and nutritional status of elderly patients with digestive cancer?: A retrospective study in Fukui, Japan. *Medicine (Baltimore)* 2021; 100: e27500.
  13. Gómez-Oliveira G, Arribas-García I, Alvarez-Flores M, et al. Delayed removal of a maxillary third molar from the infra-temporal fossa. *Med Oral Patol Oral Cir Bucal* 2010; 15: e509–e511.
  14. Ohba S, Nakatani Y, Kakehashi H, et al. The migration pathway of an extracted maxillary third molar into the buccal fat pad. *Odontology* 2014; 102: 339–342.
  15. Bilginaylar K. The use of platelet-rich fibrin for immediate closure of acute oroantral communications: An alternative approach. *J Oral Maxillofac Surg* 2018; 76: 278–286.