

SHORT REPORT

Disruption of a Covered Nitinol Self Expanding Stent Graft Implanted in the Common Femoral Artery

Emilie Bonnin ^{a,b}, Patrick Lermusiaux ^c, Julien Chakfé ^a, Delphine Dion ^a, Frédéric Heim ^{a,d}, Nabil Chakfé ^{a,b}, Anne Lejay ^{a,b,*}

^a GEPROVAS, European Research Group on Grafts used in Vascular Surgery, Strasbourg, France

^b Department of Vascular Surgery and Kidney Transplantation, University Hospital of Strasbourg, France

^c Department of Vascular Surgery, University Hospital of Lyon, France

^d Laboratoire de Physique et Mécanique Textile, Mulhouse, France

Introduction: Common femoral artery aneurysm is a rare condition and can be treated by open or endovascular surgery. There is a general understanding that open surgery is the recommended option because of the anatomical location and the biomechanical constraints posed by hip flexion.

Report: The case of a 66 year old man treated with an endograft for an asymptomatic abdominal aortic aneurysm followed by the implantation of a nitinol covered stent graft (Fluency™, Bard Peripheral Vascular, Temple, AZ) for a 25 mm diameter left common femoral artery aneurysm is reported. Two years later, follow up revealed a rupture of the nitinol covered stent graft, requiring an open iliofemoral reconstruction.

Discussion: Systematic analysis with protocolised cleaning, and macroscopic and microscopic evaluation (Keyence VHX-600 digital microscope) of the explanted nitinol covered stent graft showed membrane perforation at the level of an acute angle formed by the struts.

© 2020 The Author(s). Published by Elsevier Ltd on behalf of European Society for Vascular Surgery. This is an open access article under the CC BY-NC-ND license (<http://creativecommons.org/licenses/by-nc-nd/4.0/>).

Article history: Received 13 November 2019, Revised 1 April 2020, Accepted 21 April 2020

Keywords: Stentgraft, Femoral artery, Disruption

INTRODUCTION

Common femoral artery aneurysms (CFAAs) are uncommon and mostly asymptomatic. However, distal embolisation occurs in up to 26% of cases, acute thrombosis in around 15% of cases, and rupture in up to 15% of cases.¹ Open surgery including aneurysm resection and vascular reconstruction is considered the recommended option for symptomatic CFAA or CFAA larger than 25 mm diameter.¹ Prosthetic grafts such as polyethylene terephthalate (PET) or polytetrafluoroethylene grafts (ePTFE) can be used in most cases, as well as reversed saphenous vein graft particularly in the setting of associated infection.^{1,2} However, endovascular surgery might be considered as an option in the era of minimally invasive procedures. The case of a CFAA treated with a nitinol self expanding covered stent graft is reported. Systematic follow up revealed covered stent graft disruption. The patient was asymptomatic.

REPORT

A 66 year old man was referred with a 62 mm abdominal aortic aneurysm. Endovascular surgery was chosen because of his severe comorbidities including chronic heart failure (NYHA Class III — left ventricular ejection fraction 30%) and pulmonary fibrosis requiring oxygen therapy. The patient also presented with a 25 mm diameter left CFAA, but the superficial and deep femoral arteries were patent. Accordingly, the patient was simultaneously treated with an aortic endograft for his abdominal aortic aneurysm and with a covered stent graft (Fluency™, Bard Peripheral Vascular, Temple, AZ, 12 mm diameter 80 mm length) for his left CFAA. A retrograde contralateral femoral artery approach was used for the left CFAA. The procedure was successful and post-operative course uneventful. Two years later, systematic follow up computed tomography angiography examination revealed a left CFAA with a diameter of 28.4 mm with evidence of covered stent graft disruption (Fig. 1). The patient was asymptomatic and no biological or clinical sign of sepsis was found.

The patient underwent surgical revision with covered stent graft explantation followed by reconstruction with an iliofemoral prosthetic bypass using a 10 mm diameter silver impregnated PET graft (Intergard Silver, Maquet Getinge Group©). Follow up at two years was uneventful.

The retrieved specimen was sent to GEPROVAS (European Research Group on Grafts used in Vascular Surgery) as

* Corresponding author. Department of Vascular Surgery and Kidney Transplantation, Nouvel Hospital Civil, BP 426, 67091, Strasbourg Cedex. France.

E-mail address: anne.lejay@chru-strasbourg.fr (Anne Lejay).

2666-688X/© 2020 The Author(s). Published by Elsevier Ltd on behalf of European Society for Vascular Surgery. This is an open access article under the CC BY-NC-ND license (<http://creativecommons.org/licenses/by-nc-nd/4.0/>).

<https://doi.org/10.1016/j.ejvsf.2020.04.004>

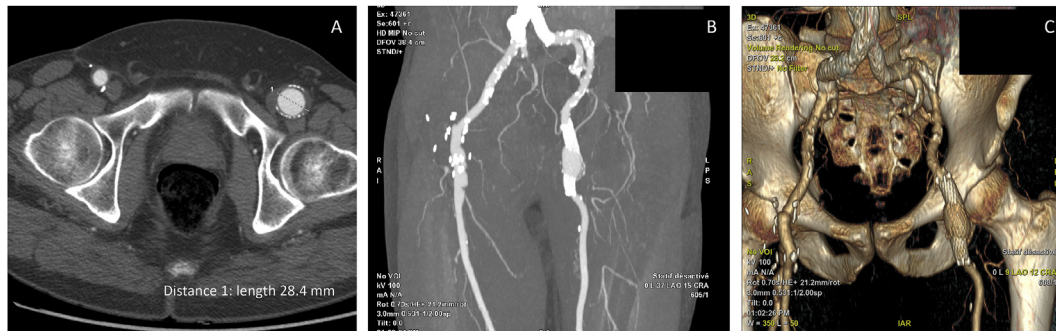


Figure 1. Follow up computed tomography angiography examination showing common femoral artery aneurysm (A) with possible covered stent disruption (B), as seen on three dimensions reconstructions (C).

part of a European explant retrieval programme and was submitted to a standardised protocol. The sample consisted of one prosthetic segment included in the aneurysmal sac (Fig. 2). The extremities of the covered stent graft kept their tubular geometry over 15 mm each, but they were not aligned. A 3 cm long rupture of both membrane and stent was observed (Fig. 2).

After cleaning, three separated areas were identified: the extremities of the covered stent graft keeping their initial tubular geometry for 15 mm length each, and the central part of the covered stent graft revealing a wide rupture with a linear tear as well as junctional tears at the apices of the struts. Both membrane and stent ruptures were observed in this central part (Fig. 3A). Other ruptures of the membrane, mostly located in the apex of the strut, were also observed (Fig. 3B). In this central part, analysis revealed that perforation of the membrane was related to deformed struts. Digital microscope pictures with magnification of $\times 100$ (Keyence VHX-600 France, Courbevoie, France) showed that the angle formed by the struts was in correspondence with the membrane perforation (Fig. 4A). Membrane shreds and broken bare struts were also observed (Fig. 4B). The breaking pattern excluded lesions that could have been performed during the surgical revision.

DISCUSSION

In the present report, the case of a nitinol self expanding covered stent graft disruption is described. Using such a device for CFAA is however not within the instructions for use, and the role of endovascular therapy for common femoral artery lesions remains a controversial area. Concerns about endovascular intervention to treat common femoral artery lesions include risk of embolisation, possible occlusion of the superficial or deep femoral artery secondary to the intervention, stent fracture with acute occlusion, and difficulty with endovascular access at the site of a previously placed common femoral artery stent graft (even if retrograde superficial femoral artery access is possible), and possibly more extensive surgery after a stent graft has been inserted and occludes compared with repair of an unstented common femoral artery. However, vascular surgeons continue to push the limits of endovascular

therapy. It has therefore been shown that endovascular interventions to the common and deep femoral arteries may be performed safely with high technical success, and that endovascular therapy may be a favoured approach for selected patients at high surgical risk, and those with wound healing considerations such as re-operative fields or those prone to infection.³ Accordingly, endovascular treatment of common femoral artery lesions might become more common in the future.

It is however important to distinguish atherosclerotic lesions from aneurysmal lesions. Nitinol flexible characteristics have been shown to be useful in locations crossing a joint, and it has now been demonstrated that stent graft deformation as the result of undue stress on the iliofemoral junction during movements of the hip should no longer be feared in the setting of atherosclerotic lesions.^{4–6} In this report, systematic analysis of the stent graft revealed that membrane perforation was located at the level of an angle formed by the struts. It might be suggested that hip flexion was responsible for textile erosion, as the bend in the struts itself could have perforated the membrane, and also because the stitches may have been frayed from repeat flexion. One could also assume that the behaviour of the stent graft might be different in an aneurysmal than in an atherosclerotic location. In an aneurysmal artery, the central part of the stent graft is free, while the proximal and

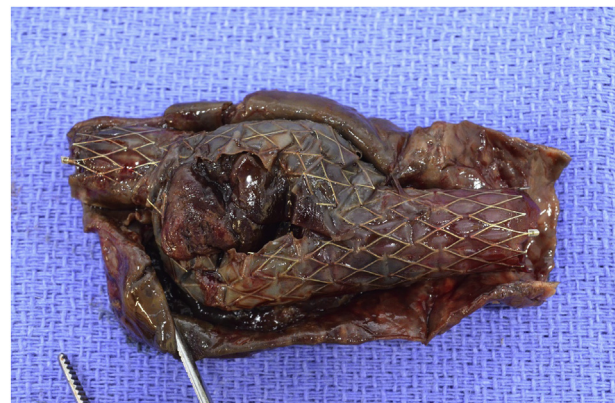

Figure 2. Explant macroscopic evaluation at reception. External encapsulation of the device into the aneurysmal sac and disruption of membrane and stent.

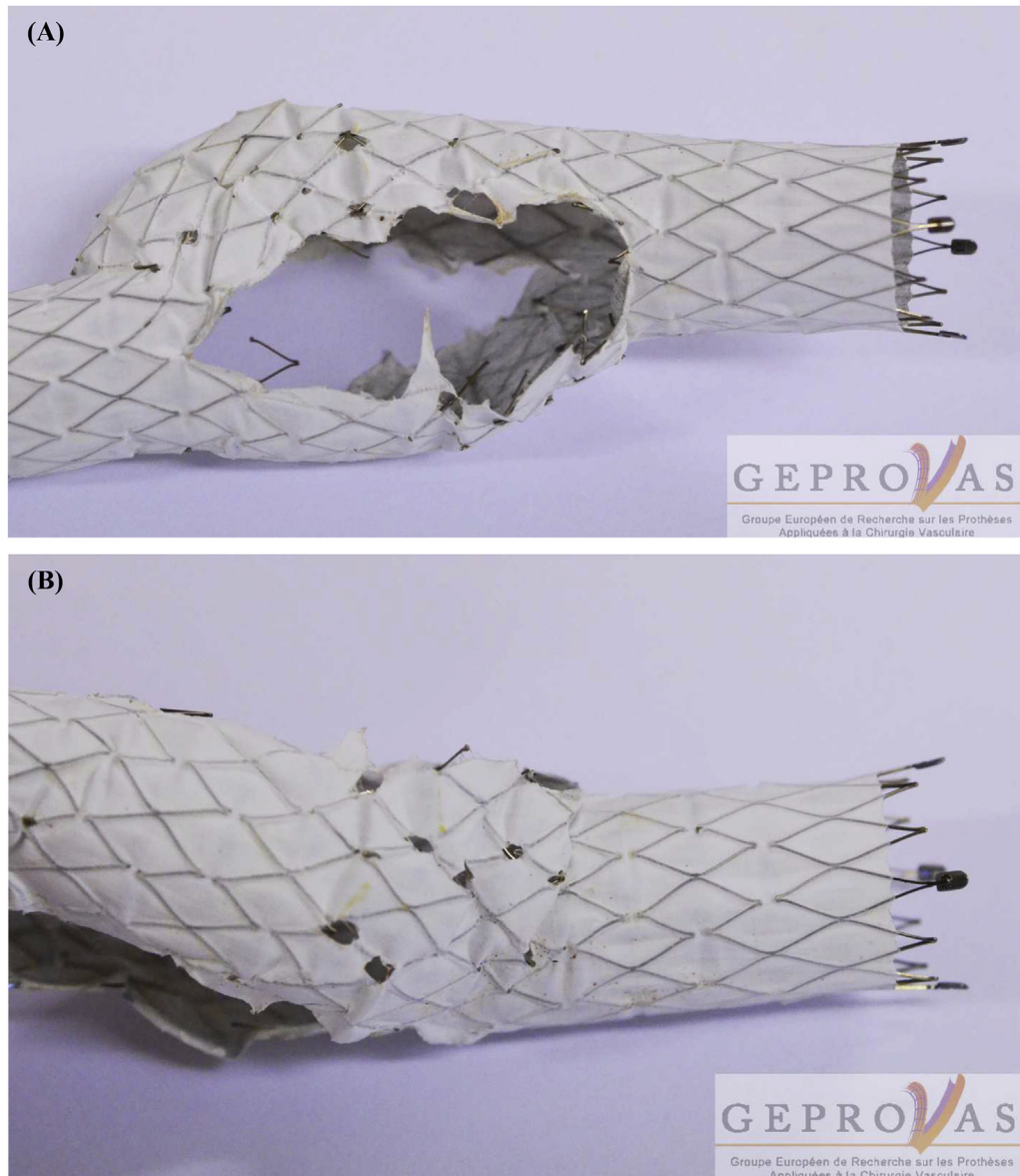


Figure 3. Macroscopic evaluation after cleaning process. Extremities of the covered stent keeping their initial tubular geometry, central part revealing a wide disruption with a linear tear (A); junctional tears at the apices of the stents (B).

distal parts of the covered stent graft do not expand to its pre-set shape, continuing to exert a chronic outward force and resist external compression. Accordingly, it could be suggested that the constraints exerted on the covered stent graft in an aneurysmal artery might not be the same as in atherosclerotic occlusive lesions where the entire device is constrained.⁷ Analysis of the explanted device revealed a wide rupture with a linear tear linked to the disruption as well as junctional tears at the apices of the stents, supposing that constraints could be different regarding the different segments.

Three points are debatable in this report: the initial endovascular indication, the choice of the device, and follow up imaging modalities. Even in the “endo era”, the indication for endovascular aneurysm repair is questionable in a 66 year old patient, despite severe comorbidities, even more so when later full open surgery could be carried out

without complications. Concerning the device, a BARD Fluency© stent graft was chosen for the CFAA, but it may have been better to choose another device, such as a GORE Viabahn® device, which has probably been used a lot more in the common femoral artery, including for salvage or even planned deployments.⁸ However, considering the conical shape of a CFAA, there might still be an incomplete expansion of the device, which could lead to an irregular internal lumen, causing stresses and deformations to the stent graft. Another option would have been to use a hybrid approach in this frail patient, introducing a stent graft into the proximal neck of the CFAA before opening of the CFAA and manual suturing of the distal part of the endograft to the native artery.⁹ The second debatable point concerns follow up modalities. The patient could have been followed by standard radiographs associated with Duplex ultrasound examinations rather than CTA in order to decrease

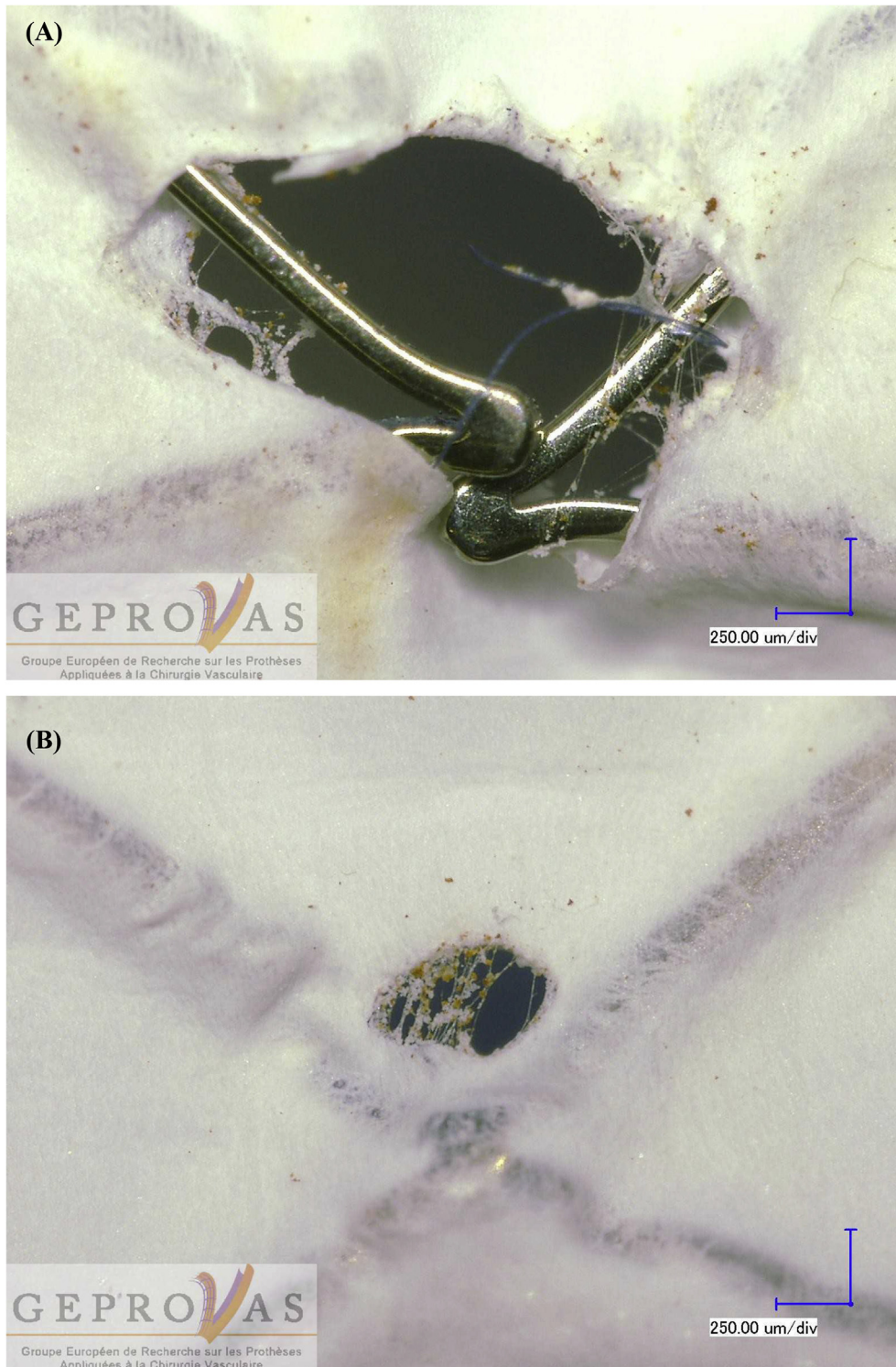

Figure 4. Microscopic evaluation ($\times 100$) Keyence® VHX-600. Stent protrusion at the level of membrane perforation (A); membrane degradation (B).

continued high radiation surveillance. Standard radiographs might have shown stent graft fracture detail much better than CTA, and this could have depicted covered stent graft disruption earlier.

In conclusion, such covered stent graft rupture is unusual. However, the use of covered stent graft in the setting of a CFAA might be at risk of disruption, due to constraints

exerted on the device. A standardised protocol of analysis can help in determining rupture profile and proposing dedicated *in vitro* protocols to understand the degradation mechanisms.¹⁰

CONFLICTS OF INTEREST

None.

FUNDING

Financial support provided by Eurometropole de Strasbourg and the Région Grand'Est.

ACKNOWLEDGEMENTS

We acknowledge the European Society of Vascular Surgery and the Société Française de Chirurgie Vasculaire et Endovasculaire, who support our explant analysis programme.

REFERENCES

- 1 Pappas G, Janes JM, Bernatz PE, Schirger A. Femoral aneurysms. Review of surgical management. *JAMA* 1964;**190**:489–93.
- 2 Chakfé N, Diener H, Lejay A, Assadian O, Berard X, Caillon J, et al. European society for vascular surgery (ESVS) 2019 clinical practice guidelines on the management of vascular graft and stent graft infections with endorsement of the European association of nuclear medicine (EANM). *Eur J Vasc Endovasc Surg* 2020;**59**:339–84.
- 3 Bath J, Avgerinos E. A pooled analysis of common femoral and profunda femoris endovascular interventions. *Vascular* 2016;**24**:404–13.
- 4 Djmal H, Maurel B, Costargent A, Chaillo P, Goueffic Y. Stenting does not change the behavior of the common femoral artery during hip flexion. *Eur J Vasc Endovasc Surg* 2019;**58**:250.
- 5 El Lhoury R, Nikanorov A, McCarroll E, Leclerc G, Guy LG, Laflamme M, et al. An animal model of human peripheral arterial bending and deformation. *J Surg Res* 2019;**241**:240–6.
- 6 Nasr B, Della Schiava N, Thaveau F, Rosset E, Favre JP, Salomon du Mont L, et al. The common femoral artery bifurcation lesions: clinical outcomes of simple versus complex stenting techniques. An analysis based on the TECCO trial. *Ann Vasc Surg* 2020;**64**:2–10.
- 7 Stoeckel D, Pelton A, Duerig T. Self-expanding nitinol stents: material and design considerations. *Eur Radiol* 2004;**14**:292–301.
- 8 Fu Q, Meng X, Li F, Wang X, Chen J, Huang W, et al. Stent-graft placement with early debridement and antibiotic treatment for femoral pseudoaneurysms in intravenous drug addicts. *Cardiovasc Intervent Radiol* 2015;**38**:565–72.
- 9 Rancic Z, Pecoraro F, Pfammatter T, Mayer D, Veith FJ, Lachat M. Less invasive common femoral artery aneurysm repair using endografts and limited dissection. *Eur J Vasc Endovasc Surg* 2013;**45**:481–7.
- 10 Lejay A, Colvard B, Magnus L, Dion D, Georg Y, Papillon J, et al. Explanted vascular and endovascular graft analysis: where do we stand and what should we do? *Eur J Vasc Endovasc Surg* 2018;**55**:567–76.