

Subacute Sclerosing Panencephalitis with An Atypical Presentation

Subacute sclerosing panencephalitis (SSPE) is a type of neurodegenerative disease caused by the persistent infection of the brain by the aberrant measles virus.^[1] The common presenting symptoms are progressive decline in cognition, changes in behavior, and focal or generalized seizures with myoclonus. It is usually seen in children and young adults occurring 7-10 years after infection with measles virus.^[2] Here we report a case of SSPE with acute onset movement disorder as the initial manifestation in a young female.

An 18-year-old female with a normal birth and developmental history, presented with the total duration of illness of 1 month with complaints of abnormal twisting movements of left upper limb followed by lower limb. Two weeks into the course of illness these twisting movements progressed to trunk and then involved the right upper and lower limb. She also developed slurring of speech, difficulty in swallowing, and needed the support of one person to walk at the time of presentation to our clinic. One week after the admission in the ward (5 weeks after onset of dystonia over the right side of body), she developed abnormal slow jerky movements of limbs, (which were proximal more than distal) trunk and neck. There was no history of cognitive decline and behavioral abnormalities. There was no history of measles. Immunization status was complete and family history was negative. There was no preceding history of any febrile illness, jaundice, trauma, drug intake, systemic involvement/constitutional features, or any such illness in the past or childhood.

MMSE and other higher mental functions were normal. Cranial nerve examination including oculi fundi facial and lower cranial nerves revealed no abnormality. Motor examination revealed asymmetrical left > right, upper limb plus lower limb and truncal dystonia, with sparing of craniofacial region, asymmetrical left > right side limb plus axial rigidity and bradykinesia with myoclonic jerks which were proximal > distal involving upper limbs, trunk, and neck occurring intermittently. Deep tendon reflexes, sensory, and cerebellar examination were normal. Pseudobulbar features were not seen. Ocular examination was normal with visual acuity of 6/6 in both eyes. Fundoscopy was normal and KF rings were absent on slit-lamp examination. Her CBC, liver and renal function tests, TSH, and MRI brain [Image 1] were normal. Serum copper, ceruloplasmin, and 24-h urinary copper levels were within normal limits. Autoimmune studies were normal. Electroencephalography (EEG) [Image 2] showed periodic high-amplitude generalized slow-wave discharges. Her CSF measles IgG was elevated more than 250 times and serum measles IgG was elevated more than 125 times, based on which a diagnosis of SSPE was made. She was treated with

intrathecal interferons, Isoprinosine, valproate, lorazepam, trihexyphenidyl, and levodopa.

DISCUSSION

SSPE is a progressive neurological disorder of childhood and early adolescence. It is caused by the persistent defective measles virus.^[3] The common presenting symptoms of SSPE are a progressive decline in cognition, changes in behavior, focal or generalized seizures with myoclonus. However atypical presentations like isolated psychiatric manifestations, uncontrolled seizures, movement disorders like dystonia, chorea, parkinsonism, and stroke-like features have also uncommonly been described in the literature.^[1] The underlying neuropathology includes extensive perivascular inflammation, demyelination, glial proliferation, and neuronal and glial intranuclear inclusions.^[3]

Extrapyramidal features like parkinsonism, dystonia, chorea, and ballism have been described in 1.6% to 5.1% of patients with SSPE worldwide.^[4] Several case reports were published in the literature highlighting the early onset of movement disorders in SSPE.^[5,6] An interesting case of PISA syndrome has also been reported in a child with SSPE.^[7]

In our case, the patient presented with rapid onset dystonia and parkinsonism and later developed myoclonus. Common treatable causes of rapid-onset dystonia parkinsonism include drug toxicities, metabolic abnormalities, Wilsons disease, and movement disorders associated with anti-neuronal antibodies. Rapid-onset dystonia-parkinsonism (RDP) is a rare genetic disorder^[8] characterized by the abrupt onset of dystonia and parkinsonism with a clear rostrocaudal gradient, and prominent bulbar findings little response to dopaminergic medications and is caused by mutations in the ATPIA3 gene.

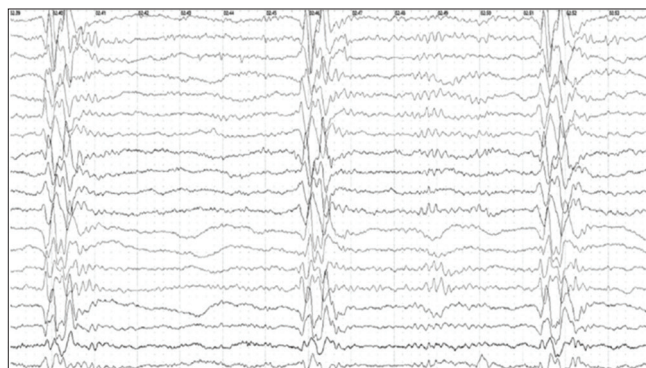


Image 1: EEG of the patient with SSPE showing high amplitude generalized periodic epileptiform discharges occurring at intervals of 4-5 seconds in longitudinal bipolar montage. MRI Brain

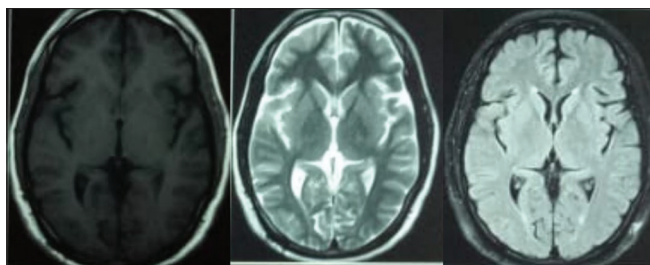


Image 2: Axial MRI brain of the patient revealing normal findings

After ruling out the possibilities of drug toxicity (from history and checking prescriptions), Wilson's disease, autoimmune etiologies, and other metabolic conditions, the patient was evaluated with an EEG, which revealed the classical periodic discharges. The levels of IgG measles antibodies were very high in cerebrospinal fluid and serum samples, which was consistent with a diagnosis of SSPE. Thus based on a classical EEG and raised antimeasles antibody titer, a diagnosis of SSPE was made with this uncommon initial presentation.

In developing countries like India where measles is still prevalent, one should be aware that of the atypical presentations of SSPE and that it can masquerade as a dystonia Parkinsonism syndrome. Movement disorders, though uncommon, can be an important clinical feature of patients with SSPE and neurologists should keep a possibility of this devastating disorder in patients presenting with movement disorders, especially in developing and underdeveloped countries.

Financial support and sponsorship

Nil.

Conflicts of interest

There are no conflicts of interest.

Ram Bhupal Reddy, Deepika Joshi, Anand Kumar

Department of Neurology, Institute of Medical Sciences, Banaras Hindu University, Varanasi, Uttar Pradesh, India

Address for correspondence: Dr. Deepika Joshi,

Department of Neurology, Institute of Medical Sciences, Banaras Hindu University, Varanasi - 221005, Uttar Pradesh, India.
E-mail drdeepikajoshi73@gmail.com

REFERENCES

1. Jafri SK, Kumar R, Ibrahim SH. Subacute sclerosing panencephalitis – Current perspectives. *Pediatr Health Med Ther* 2018;9:67-71.
2. Ibrahim SH, Amjad N, Saleem AF, Chand P, Rafique A, Humayun KN. The upsurge of SSPE--a reflection of national measles immunization status in Pakistan. *J Trop Pediatr* 2014;60:449-53.
3. Garg RK. Subacute sclerosing panencephalitis. *Postgrad Med J* 2002;78:63-70.
4. Prashanth LK, Taly AB, Sinha S, Ravi V. Subacute sclerosing panencephalitis (SSPE): An insight into the diagnostic errors from a tertiary care university hospital. *J Child Neurol* 2007;22:683-8.
5. Al-Gethami H, Al-Rifai ET, Al-Rumayyan, Al-Tuwaijri, Ba-Armah D. Movement disorder early in the presentation of two children with subacute sclerosing panencephalitis. *Int Neuropsychiatr Dis J* 2019;13:110.
6. Singer C, Lang AE, Suchowersky O. Adult-onset subacute sclerosing panencephalitis: Case reports and review of the literature. *Mov Disord* 1997;12:342-53.
7. Pandey S, Tomar LR, Tater P. Pisa syndrome in a child with subacute sclerosing panencephalitis. *JAMA Neurol* 2018;75:255-6.
8. Haq IU, Snively BM, Sweadner KJ, Suerken CK, Cook JF, Laurie J, *et al*. Revising rapid-onset Dystonia-Parkinsonism: Broadening indications for ATP1A3 testing. *Mov Disord* 2019;34:1528-36.

Submitted: 22-Jul-2020 **Revised:** 02-Aug-2020 **Accepted:** 23-Aug-2020

Published: 25-Jan-2021

This is an open access journal, and articles are distributed under the terms of the Creative Commons Attribution-NonCommercial-ShareAlike 4.0 License, which allows others to remix, tweak, and build upon the work non-commercially, as long as appropriate credit is given and the new creations are licensed under the identical terms.

DOI: 10.4103/aian.AIAN_791_20