

COVID-19 pneumonia treated with Sarilumab: A clinical series of eight patients

To the Editor,

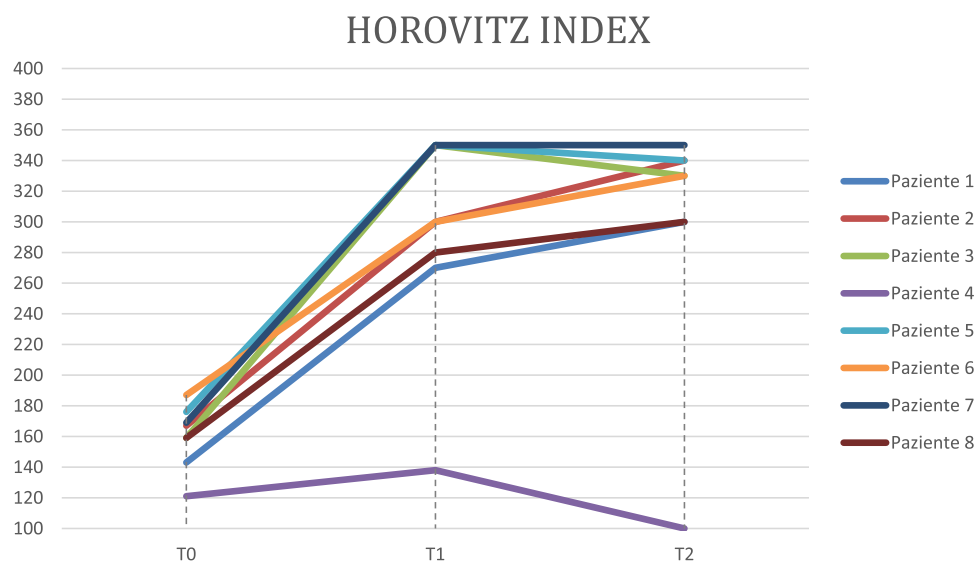
We read with interest the work by Luo et al,¹ who described the use of tocilizumab in 15 patients with moderate-to-critical novel coronavirus infection (Coronavirus disease in 2019 [COVID-19]) caused by severe acute respiratory syndrome coronavirus 2 (SARS-CoV-2). The development of cytokine release syndrome and T cell abnormalities plays a key role in the progression of COVID-19. Under these circumstances, persistent viral stimulation leads to a significant increase in circulating cytokines such as interleukin (IL)-6, IL-10, and tumor necrosis factor α . The levels of these cytokines are negatively correlated with the absolute lymphocyte count, inducing the exhaustion and apoptosis of T cells which can trigger inflammatory damage to the organs.² It has been shown that IL-6 plays a central role in the pathogenesis of SARS-CoV-2-associated cytokine release syndrome and consequently Tocilizumab, a humanized monoclonal antibody against the IL-6 receptor (IL-6R) approved for the treatment of rheumatoid arthritis (RA) and giant cells arteritis, has gained interest as a potential treatment for COVID-19 in clinical series.³ A retrospective study on 21 patients with severe COVID-19 showed that treatment with Tocilizumab (4–8 mg/kg) improves oxygen saturation and computed tomography scan abnormalities, lymphocyte count, and normalizes C-reactive protein (CRP) levels in most of the patients.⁴ The randomized clinical trial investigating the safety and efficacy of Tocilizumab in COVID-19 is still ongoing (ChiCTR2000029765). Based on Chinese data, on 17 March, the Italian Medicines Agency (AIFA) launched a prospective study on the use of Tocilizumab for COVID-19. The rapid exhaustion of the drug led to the use of Sarilumab, another IL-6R inhibitor employed in treatment of RA subcutaneously. AIFA has subsequently approved the Clinical Trial Protocol EFC16844 with reconstituted Sarilumab intravenously. All patients gave their written informed consent according to prospective nature of the study belong Declaration of Helsinki and Italian legislation (Authorization of the Privacy Guarantor No. 9, 12th December 2013). The Institutional Review Board, the Health Director of Hospital in Florence, reviewed and approved this research and the use of clinical and laboratory data of common clinical practice, in the respect of Privacy Law, for clinical and scientific studies and publications. We describe the clinical course of eight

patients (mean age: 62 years; six men and two women) hospitalized in San Giovanni di Dio Hospital (Florence, Italy) for COVID-19, confirmed by the SARS-CoV2 reverse transcription polymerase chain reaction test. We added Sarilumab on their standard daily therapy with hydroxychloroquine 400 mg, azithromycin 500 mg, darunavir 800 mg, cobicistat 150 mg, enoxaparin 100 U/Kg. Sarilumab administration consisted in a dose of 400 mg equivalent to two single-dose prefilled syringes, each containing 200 mg Sarilumab in 1.14 mL solution (175 mg/mL), added to 100 mL 0.9% sodium chloride, for a 1-hour intravenous infusion. The treatment was done after 24 hours from hospitalization (T0), and subsequently after 48 and 96 hours, at the dosage of 200 mg in intravenous infusion. Primary endpoint was the evaluation of respiratory function, described as at least a 30% reduction in oxygen requirement from baseline (meaning the ratio of O₂ flow through the Venturi mask); an improvement of oxygenation expressed by an increased SpO₂/FiO₂ ratio (Horovitz index) by 50 or higher compared to nadir SpO₂/FiO₂ for at least 48 hours; improvement of ultrasound aspects with transition from moderate/severe B Wet Lung pattern to modest B Wet Lung pattern at 96 hours and 7 days on 14 windows (maximum score 42).⁵ Secondary endpoint was the evaluation of CRP, serum amyloid A (SAA) IL-6, D-dimer, lactate dehydrogenase, and lymphocyte count at baseline 24 hours (T0), 96 hours (T1), and 7 days (T2) after the first infusion. Table 1 shows the variation of the parameters, both laboratory and functional, in our clinical series of the eight treated patients. Seven of them showed an improvement of the Horovitz index and a progressive reduction in the echo score (Figures 1 and 2). In these patients, aggressive and early treatment with an IL-6 inhibitor led to discharge within 14 days of hospitalization and seven out of eight patients resulted negative at the molecular test. An 83-year-old patient had no improvement in Horovitz's functional index or echo score and died 13 days after hospitalization. There is also a progressive reduction in the SAA and CRP inflammation parameters. In RA, the determination of early synovitis may predict erosive damage over time⁶ and the treat-to-target strategy is capable of determining clinical remission and blockage of radiological damage.⁷ In this context, timing is even more fundamental. Hence, the rheumatologic concept of a window of opportunity in treating RA can be translated into therapeutic strategies for dealing with the COVID-19 pandemic.

TABLE 1 Parameters evaluated at baseline after 96 hours and after 7 days of treatment

T0 lymphocyte cells/mcL	T1	T2	T0 SAA mg/L	T1	T2	T0 IL-6 pg/mL	T1	T2	T0 CRP mg/dL	T1	T2
560	590	630	961	54	15,6	86	>200	>200	22	6,5	2,3
480	459	638	846	708	17,3	68	>200	>200	36,1	9,6	1,5
458	589	717	1430	36	18,8	126	167	>200	28	5,2	0,75
537	430	426	652	703	269	>200	173	189	17,9	13,2	18,6
459	579	589	133	22	41,7	154	156	170	5,1	6,1	5,2
526	690	689	465	26	21,6	>200	148	183	9,27	2,7	2,2
437	578	692	592	7	15,8	68	136	189	7,18	3,6	0,58
568	631	748	760	12	16,2	74	>200	>200	16	1,4	1,2
LDH U/L			D-dimer ng/mL			Horovitz score			Echo score		
280	234	267	1280	790	640	143	270	300	18	8	4
224	243	314	1670	1150	580	167	300	340	21	7	3
368	256	256	1380	1158	689	159	350	330	24	10	5
450	214	341	3406	3259	2378	121	138	100	24	24	26
478	478	231	1560	1279	873	176	350	340	19	8	6
469	462	256	1730	1364	610	187	300	330	21	6	7
542	466	267	1389	1159	627	169	350	350	19	6	3
643	532	285	1468	1134	563	159	280	300	18	7	2

Abbreviations: CRP, C-reactive protein; IL, interleukin; LDH, lactate dehydrogenase; SAA, serum amyloid A.

**FIGURE 1** Horovitz index at baseline 96 hours after treatment and 7 days in the eight patients

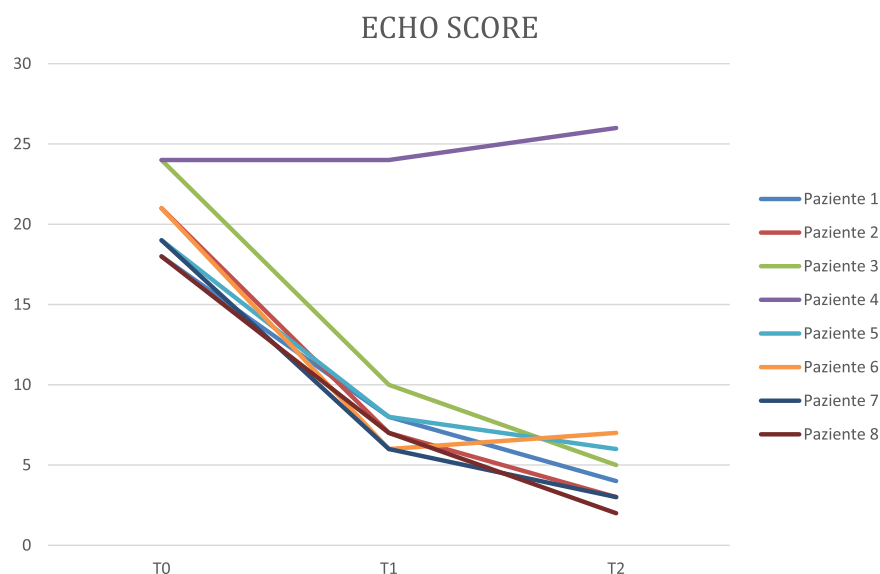


FIGURE 2 Baseline echo score after 96 hours of treatment and 7 days in the eight patients

Maurizio Benucci MD¹

Gianfranco Giannasi²

Paolo Cecchini²

Francesca Li Gobbi¹

Arianna Damiani³

Valentina Grossi⁴

Maria Infantino⁴

Mariangela Manfredi⁴

¹Department of Internal Medicine, Rheumatology Unit, Azienda USL-Toscana Centro, Hospital San Giovanni di Dio, Florence, Italy

²Emergency Department and Covid Unit, Azienda USL-Toscana Centro, Hospital San Giovanni di Dio, Florence, Italy

³Rheumatology Unit, Department of Clinical and Experimental Medicine, University of Florence, Florence, Italy

⁴Department of laboratory, Immunology and Allergology Laboratory, Azienda USL-Toscana Centro, Hospital San Giovanni di Dio, Florence, Italy

Correspondence

Maurizio Benucci, MD, Department of Internal Medicine, Rheumatology Unit, Azienda USL-Toscana Centro, Hospital San Giovanni di Dio, Via Torregalli 3, 50143 Florence, Italy.

Email: maubenucci@tiscali.it and maurizio.benucci@uslcentro.toscana.it

ORCID

Maurizio Benucci <http://orcid.org/0000-0001-8180-6660>

Maria Infantino <http://orcid.org/0000-0002-6200-4467>

REFERENCES

1. Luo P, Liu I, Qiu L, et al. Tocilizumab treatment in COVID-19: a single center experience [published online ahead of print April 6, 2020]. *J Med Virol*. <https://doi.org/10.1002/jmv.25801>
2. Huang C, Wang Y, Li X, et al. Clinical features of patients infected with 2019 novel coronavirus in Wuhan, China. *Lancet*. 2020;395:497-506.
3. Di Giambenedetto S, Ciccullo A, Borghetti A, et al. Off-label use of Tocilizumab in patients with SARS-CoV-2 Infection [published online ahead of print April 16, 2020]. *J Med Virol*. <https://doi.org/10.1002/jmv.25897>
4. Xu X, Han M, Li T, Sun W, et al. Effective Treatment of Severe COVID-19 Patients with Tocilizumab. 2020;ChinaXiv:20200300026.
5. Soldati G, Smargiassi A, Inchingolo R, et al. Proposal for international standardization of the use of lung ultrasound for patients with COVID-19: a simple, quantitative, reproducible method [published online ahead of print March 30, 2020]. *J Ultrasound Med*. <https://doi.org/10.1002/jum.15285>
6. Möller B, Aletaha D, Andor M, et al. Synovitis in rheumatoid arthritis detected by grey scale ultrasound predicts the development of erosions over the next three years. *Rheumatology (Oxford)*. 2019 Oct 19.
7. Smolen JS, Landewé RBM, Bijlsma JWJ, et al. EULAR recommendations for the management of rheumatoid arthritis with synthetic and biological disease-modifying antirheumatic drugs: 2019 update. *Ann Rheum Dis*. 2020;79(6):685-699.