

Differential Diagnosis of Wide QRS Tachycardias

Demosthenes G Katritsis¹ and Josep Brugada²

1. Department of Cardiology, Hygeia Hospital, Athens, Greece; 2. Cardiovascular Institute, University of Barcelona, Spain

Abstract

In this article, the authors discuss the differential diagnostic methods used in clinical practice to identify types of wide QRS tachycardias (QRS duration >120 ms). A correct diagnosis is critical to management, as misdiagnosis and the administration of drugs usually utilised for supraventricular tachycardia can be harmful for patients with ventricular tachycardia.

Keywords

Tachycardias, supraventricular tachycardia, ventricular tachycardia

Disclosure: The authors have no conflicts of interest to declare.

Received: 28 April 2020 **Accepted:** 27 May 2020 **Citation:** *Arrhythmia & Electrophysiology Review* 2020;9(3):155–60. **DOI:** <https://doi.org/10.15420/aer.2020.20>

Correspondence: Demosthenes Katritsis, Hygeia Hospital, 4 Erythrou Stavrou St, Athens 15123, Greece; E: dkatrits@dgkatritsis.gr

Open Access: This work is open access under the CC-BY-NC 4.0 License which allows users to copy, redistribute and make derivative works for non-commercial purposes, provided the original work is cited correctly.

The term narrow QRS tachycardia indicates individuals with a QRS duration \leq 120 ms, while wide QRS tachycardia refers to tachycardia with a QRS duration >120 ms.¹ Narrow QRS complexes are due to rapid activation of the ventricles via the His–Purkinje system, suggesting that the origin of the arrhythmia is above or within the His bundle. However, early activation of the His bundle can also occur in high septal ventricular tachycardia (VT), resulting in relatively narrow QRS complexes of 110–140 ms.² Wide QRS tachycardias can be VT, supraventricular tachycardia (SVT) conducting with bundle branch block (BBB) aberration, or over an accessory pathway, and account for 80%, 15% and 5% of cases, respectively.³ The correct diagnosis of VT is critical to management, as misdiagnosis and the administration of drugs usually utilised for SVT can be harmful for patients in VT.⁴

In this article, we discuss the differential diagnostic methods encountered in clinical practice. The text is mainly based on the recently published ESC guidelines on SVT.¹

Regular Tachycardias

As a rule, the default diagnosis of a wide QRS tachycardia should be VT until proven otherwise. VT is defined as a tachycardia (rate >100 BPM) with three or more consecutive beats that originate in the ventricles.^{5,6} Differential diagnoses include (Table 1):⁷

- SVT with BBB. This may arise due to pre-existing BBB or the development of aberrancy during tachycardia, known as phase 3 block, which more commonly has a right bundle branch block (RBBB) pattern due to the longer refractory period of the right bundle branch.
- SVT with antegrade conduction over an AP that participates in the circuit (antidromic atrioventricular re-entrant tachycardia) or is a bystander during AF, focal atrial tachycardia/flutter or atrioventricular nodal re-entrant tachycardia.

- SVT with widening of the QRS interval induced by drugs or electrolyte disturbances. Class IC and IA drugs cause use-dependent slowing of conduction and class III drugs prolong refractoriness to a greater extent at the His–Purkinje tissue than in the ventricular myocardium. Both can result in atypical BBB morphologies during SVT that mimic VT.
- Apical ventricular pacing, pacemaker-related endless loop tachycardia and artefacts can also mimic VT.

Electrocardiographic Differential Diagnosis

If the QRS morphology is identical during sinus rhythm and tachycardia, then VT is unlikely. However, bundle branch re-entrant VTs and high septal VTs exiting close to the conduction system can have similar morphologies to sinus rhythm. The presence of a contralateral BBB pattern in sinus rhythm is more indicative of VT.

Atrioventricular Dissociation

The presence of either atrioventricular dissociation or capture/fusion beats in the 12-lead ECG during tachycardia are key diagnostic features of VT (Table 2). Atrioventricular dissociation may be difficult to recognise because P waves are often hidden by wide QRS and T waves during a wide QRS tachycardia. P waves are usually more prominent in inferior leads and modified chest lead placement (Lewis lead).³ The relation between atrial and ventricular events is 1:1 or greater, i.e. more atrial than ventricular beats, in most VTs. Atrioventricular nodal re-entrant tachycardia can be associated with 2:1 conduction, but this is rare.⁸ Although VA conduction can be found in up to 50% of patients with VT and a 1:1 relation is possible, most VTs have a relation of <1:1, i.e. more QRS complexes than P waves.

QRS Duration

A QRS duration >140 ms with RBBB or >160 ms with left bundle branch block (LBBB) pattern suggests VT. These criteria are not

Table 1: Differential Diagnosis of Wide QRS Tachycardias

Wide QRS (>120 ms) Tachycardias

Regular:

- Ventricular tachycardia/flutter
- Ventricular paced rhythm
- Antidromic AV re-entrant tachycardia
- Supraventricular tachycardias with aberration/bundle branch block (pre-existing or rate-dependent during tachycardia)
- Atrial or junctional tachycardia with pre-excitation/bystander accessory pathway
- Supraventricular tachycardia with QRS widening due to electrolyte disturbance or antiarrhythmic drugs

Irregular:

- AF or atrial flutter or focal atrial tachycardia with varying block conducted with aberration
- Antidromic AV re-entrant tachycardia due to a nodo-ventricular/fascicular accessory pathway with variable VA conduction
- Pre-excited AF
- Polymorphic VT
- Torsades de pointes
- VF

Occasionally, AF with very fast ventricular response may apparently resemble a regular narrow-QRS tachycardia.

AV = atrioventricular; VA = ventriculoarterial; VT = ventricular tachycardia. Source: Brugada et al. 2019.¹ Reproduced with permission from Oxford University Press.

Table 2: ECG Criteria in the 2019 European Society of Cardiology Guidelines Suggest Ventricular Rather Than Supraventricular Tachycardia in Wide Complex Tachycardia

Atrioventricular dissociation	Ventricular rate > atrial rate
Fusion/capture beats	Different QRS morphology from that of tachycardia
Chest lead negative concordance	All precordial chest leads negative
RS in precordial leads	<ul style="list-style-type: none"> • Absence of RS in precordial leads • RS >100 ms in any lead*
QRS complex in aVR	<ul style="list-style-type: none"> • Initial R wave • Initial R or Q wave >40 ms • Presence of a notch of predominantly negative complex
QRS axis -90° to $\pm 180^\circ$	Both in the presence of right and left bundle branch block morphology
R wave peak time in lead II	R wave peak time ≥ 50 ms
Right bundle branch block morphology	Lead V1: Monophasic R, rSR', biphasic qR complex, broad R (>40 ms), and a double-peaked R wave with the left peak taller than the right (the so-called rabbit ear sign) Lead V6: R:S ratio <1 (rS, QS patterns)
Left bundle branch block morphology	Lead V1: Broad R wave, slurred or notched down stroke of the S wave and delayed nadir of S wave Lead V6: Q or QS wave

*RS = beginning of R to deepest part of S. Source: Brugada et al. 2019.¹ Reproduced with permission from Oxford University Press.

helpful for differentiating VT from SVT in specific settings, such as pre-excited SVT or when class IC or class IA antiarrhythmic drugs are administered.⁹

QRS Axis

Since VT circuits, especially post MI or in cardiomyopathies, frequently lie outside the normal His–Purkinje network, significant axis shifts are likely to occur that enable diagnosis. In SVT patients with aberrancy, the QRS axis is confined between -60° and $+120^\circ$. Extreme axis deviation (from -90° to $\pm 180^\circ$) is strongly indicative of VT in the presence of RBBB and LBBB.⁷

Chest Lead Concordance

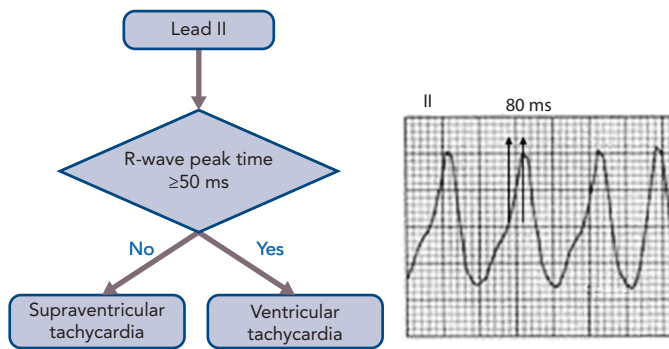
The presence of negative chest lead concordance (i.e. when all QRS complexes in leads V1–V6 are negative) is almost diagnostic of VT, with a specificity of >90%, but is only present in 20% of VTs (Figure 1). Positive concordance can be indicative of VT or an antidromic tachycardia utilising a left posterior or left lateral accessory pathway.¹⁰

Right Bundle Branch Block Morphology

In the V1 lead, typical RBBB aberrancy has a small initial r', since in RBBB the high septum is activated primarily from the left septal bundle. This means that rSR', rSr' or rR' patterns are evident in lead V1. However, in VT the activation wavefront progresses from the LV to the right precordial V1 lead in such a way that a prominent R wave (monophasic R, rSr', biphasic qR complex or broad R >40 ms) will more commonly be seen.¹¹ Additionally, a double-peaked R wave (M pattern) in lead V1 favours VT if the left peak is taller than the right peak – the so-called 'rabbit ear' sign. A taller right rabbit ear characterises RBBB aberrancy but does not exclude VT.

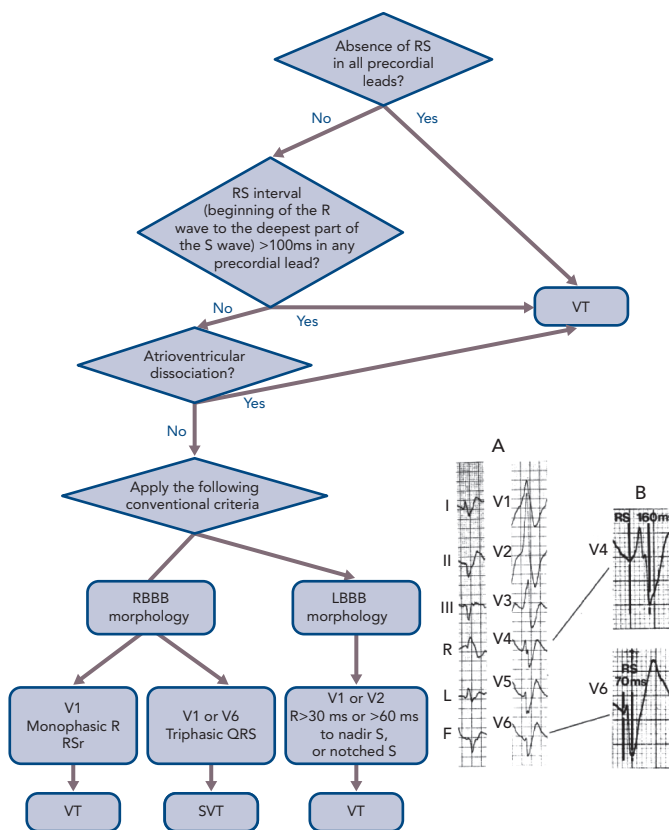
In the V6 lead, a small amount of normal right ventricular voltage is directed away from V6. Since this is a small vector in RBBB aberrancy, the R:S ratio is >1. In VT, all of the right and some of the left ventricular voltage is directed away from V6, leading to an R:S ratio <1 (rS and QS patterns). An RBBB morphology with an R:S ratio <1 in V6 is seen rarely in SVT with aberrancy, mainly when the patient has a left axis deviation during sinus rhythm.

Figure 1: Measurement of the R-wave Peak Time in Lead II



R-wave peak time measured from the isoelectric line to the point of first change in polarity, was >50 ms (80 ms, see arrows on ECG). Source: Katritsis et al. 2017.²⁸ Reproduced with permission from Oxford University Press.

Figure 2: Differential Diagnosis of Wide QRS Tachycardia using the Brugada et al. Algorithm



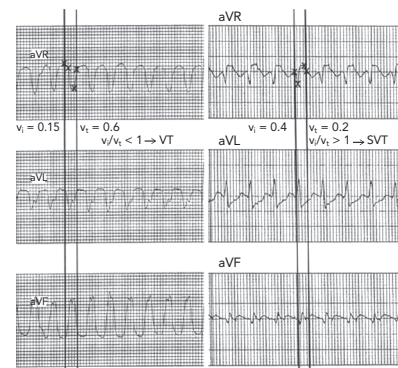
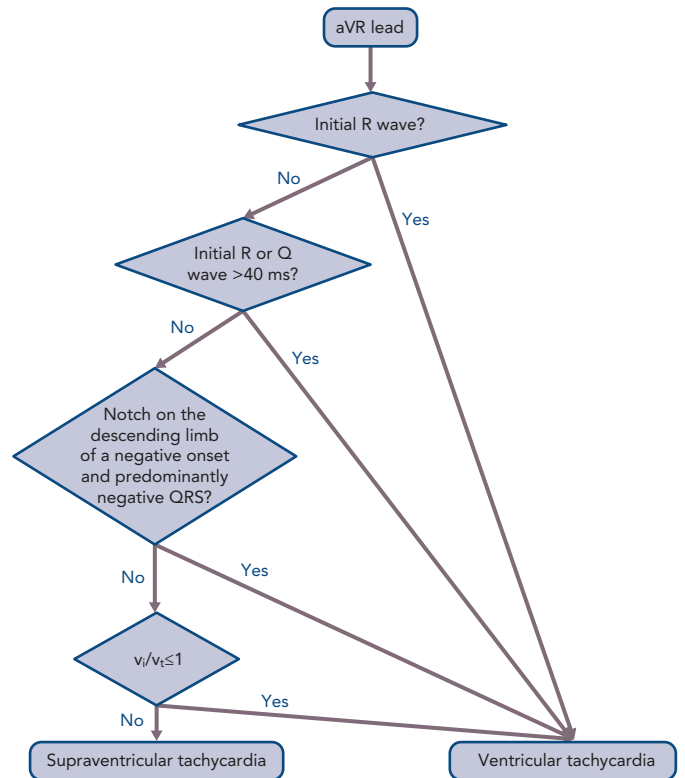
The RS interval (A), enlarged in (B), measures 160 ms in lead V4 and 70 ms in lead V6. Thus, the longest RS interval is >100 ms and diagnostic of ventricular tachycardia. LBBB = left bundle branch block; RBBB = right bundle branch block; SVT = supraventricular tachycardia; VT = ventricular tachycardia. Source: Katritsis et al. 2017.²⁸ Reproduced with permission from Oxford University Press.

Differentiating fascicular VT from SVT with bifascicular block (RBBB and left anterior hemiblock) is very challenging. Features that indicate SVT in this context include QRS >140 ms, r' in V1, overall negative QRS in aVR and R/S ratio >1 in V6.

Left Bundle Branch Block Morphology

In the V1 lead, the presence of broad R wave, slurred or notched downstroke of the S wave and delayed nadir of the S wave are strong predictors of VT for the same reasons as stated for RBBB.¹¹

Figure 3: Differential Diagnosis of Wide QRS Tachycardia using the Verecke et al. Algorithm



ECGs: The vertical lines on the aVR lead show the onset and end of the QRS complex. Crosses indicate the first and last 40 ms of the chosen QRS complex. The ventricular activation velocity ratio (v_i/v_t) is calculated by measuring the vertical excursion in mV recorded on the ECG during the initial (v_i) and terminal (v_t) 40 ms of the QRS complex. Left: During the initial 40 ms of the QRS, the impulse travelled 0.15 mV vertically; therefore, $v_i=0.15$. During the terminal 40 ms, the impulse travelled 0.6 mV vertically; therefore, $v_t=0.6$. Thus, $v_i/v_t < 1$ yields a diagnosis of ventricular tachycardia. Right: $v_i=0.4$ and $v_t=0.2$; thus, $v_i/v_t > 1$ suggests a diagnosis of supraventricular tachycardia. Source: Katritsis et al. 2017.²⁸ Reproduced with permission from Oxford University Press.

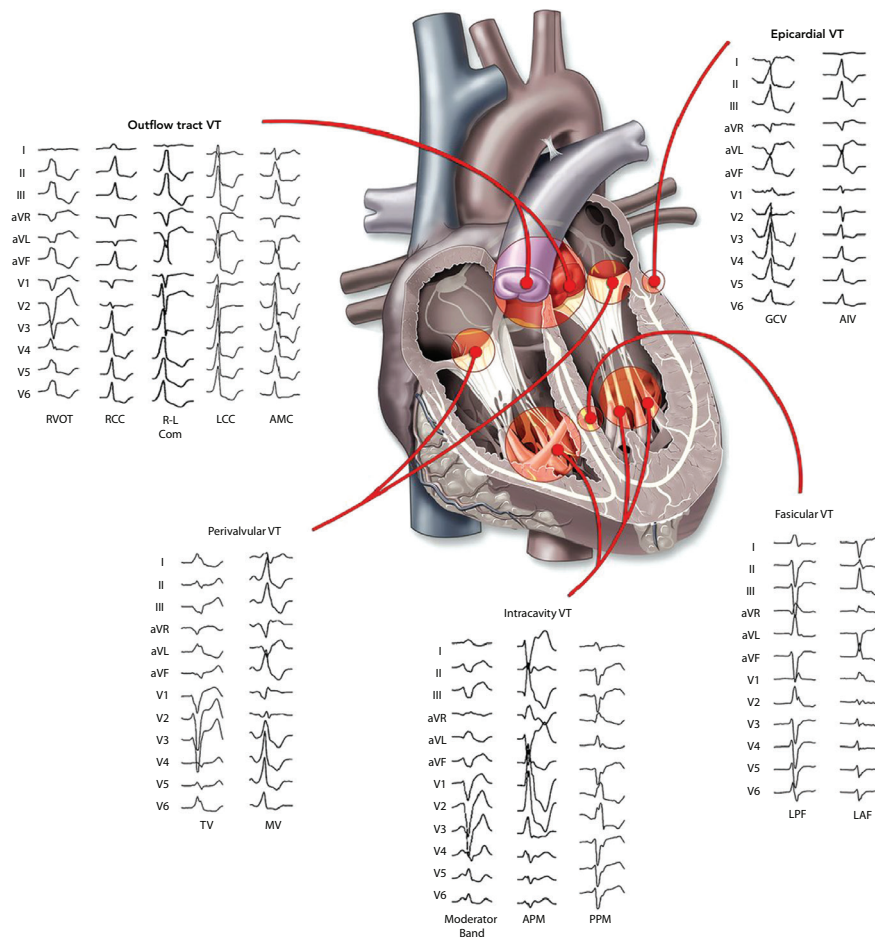
In the V6 lead, no Q wave is present in the lateral precordial leads in true LBBB. The presence of any Q or QS wave in lead V6 favours VT, indicating that the activation wavefront is moving away from the left ventricular apical site.

A number of algorithms have been developed to differentiate VT from SVT.¹²⁻¹⁴ The most established are the Brugada algorithm and the Verecke algorithm, which utilises a single aVR lead.^{12,13,15}

RS Interval in the Precordial Leads

The absence of RS complex in the precordial leads, i.e. only R and S complexes are seen on ECG, is only found in VTs (Figure 2). An RS

Figure 4: Twelve-lead Electrocardiogram Morphology of Different Sites of Idiopathic Ventricular Tachycardia Origin



AIV = anterior inter-ventricular vein; AMC = aortomitral continuity; APM = anterior PAP; GCV = greater cardiac vein; LAF = left anterior fascicle; LCC = left coronary cusp; LPF = left posterior fascicle; MV = mitral annulus; PAP = papillary muscle; PPM = posterior PAP; RCC = right coronary cusp; R-L com = right-left coronary cusp commissure; RVOT = right ventricular outflow tract; TV = tricuspid annulus. Source: Tanawuttiwat et al. 2016.²⁴ Reproduced with permission from Oxford University Press.

complex is found in all SVTs and in 74% of VTs. No SVT with aberrant conduction has an interval >100 ms between the onset of the R wave and the deepest part of the S wave at its longest duration, irrespective of the morphology of the tachycardia.¹⁵ About half of VTs have an RS interval ≤100 ms and the other half have an RS interval >100 ms. The Brugada et al. algorithm has a sensitivity and specificity of 98.7% and 96.5%, respectively.¹²

QRS Complex in the aVR Lead

During sinus rhythm and SVT, the wavefront of depolarisation moves away from the aVR lead, yielding a negative QRS complex in the aVR lead with few exceptions, e.g. inferior myocardial infarction. In contrast, the presence of an initial R wave (Rs complex) in the aVR lead suggests VT (Figure 3). The Verecke et al. algorithm has a 91.5% overall accuracy in the diagnosis of VT.¹³

R-wave Peak Time at Lead II ≥50 ms

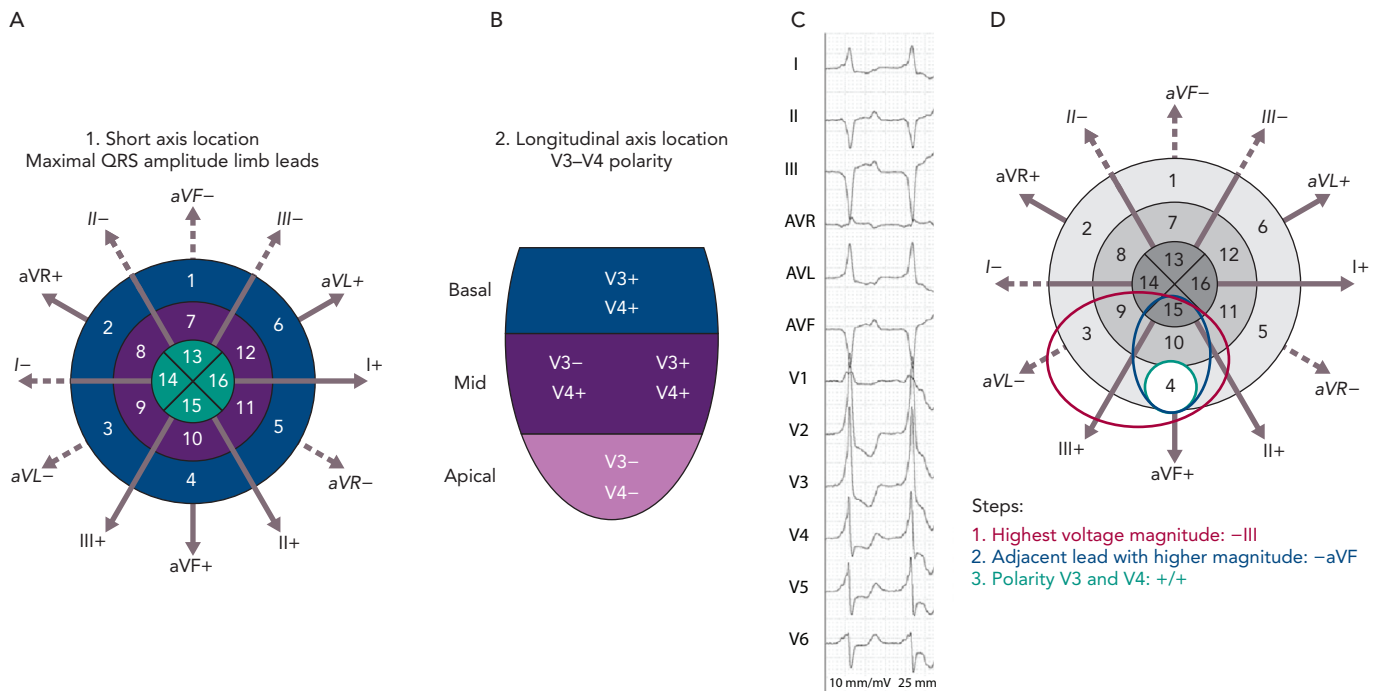
This criterion has the potential advantage that lead II is easy to obtain and is almost always present on ECG rhythm strips recorded in different settings, e.g. ECG monitoring in emergency rooms and intensive care units. In lead II an R-wave peak time ≥50 ms, independent of whether the complex is positive or negative, has been reported to have a sensitivity of 93% and specificity of 99% for identifying VT (Figure 1), but these results were not verified in the first large external application of this criterion.^{10,16}

All criteria have limitations. Several conditions, such as bundle branch re-entrant tachycardia, fascicular VT, VT with exit site close to the His-Purkinje system and wide-QRS tachycardia occurring during antiarrhythmic drug treatment, are difficult to diagnose using the morphological criteria mentioned. This is most pronounced in VT originating from septal sites, particularly Purkinje sites and the septal outflow tract regions.¹⁷ Left posterior fascicular VT, the most common form of idiopathic left ventricular VT, is frequently misdiagnosed as SVT with RBBB and left anterior hemiblock aberration.²

Differentiation between VT and antidromic atrioventricular re-entrant tachycardia is extremely difficult because the QRS morphology in antidromic atrioventricular re-entrant tachycardia is similar to that of a VT originating at the insertion of the accessory pathway in the ventricular myocardium. An algorithm has been derived for differential diagnosis based on the analysis of 267 wide-QRS tachycardias, consisting of VT and antidromic atrioventricular re-entrant tachycardia. The criteria derived from this analysis were found to have a sensitivity of 75% and specificity of 100% and the algorithm was validated in another study but experience is still limited.^{18,19}

Several independent studies have found that various ECG-based methods have specificities of 40–80% and accuracies of ~75%.^{2,10,19–22} A similar diagnostic accuracy of ~75% would be achieved effortlessly by considering every wide QRS tachycardia to be a VT because only

Figure 5: Localisation of the Origin of Scar-related Ventricular Tachycardia



Left panel: QRS axis-based algorithm showing the 17-segment model from the American Heart Association superimposed on a representation of the QRS axis and all the limb leads. Steps to identify the segment of origin of a ventricular arrhythmia are as follows. A: Identify the limb lead with the highest voltage (positive or negative). If in lead I, II or III, analyse the adjacent leads. The adjacent limb lead with higher voltage will determine the group of segments likely to be the site of origin. B: Identify the positivity or negativity of precordial leads V3 and V4; concordance indicates a basal or apical origin, respectively. Other combinations indicate a medial origin. Right panel: Example of the application of the QRS axis-based algorithm. C: An ECG of ventricular tachycardia. D: The application of the QRS axis-based graphical algorithm. In the ECG, the lead with the highest voltage is III2. Applying step 1, the segment the ventricular tachycardia originates from is one of the sections in the red circle. Analysing voltage in the adjacent leads reveals that aVF2 has a higher voltage than aVL1 and the origin is therefore in a segment within the blue circle. Application of step 2 indicates the ventricular tachycardia has a basal origin, as leads V3 and V4 are both more positive than negative. The final segment selected by the algorithm is 4 (green circle). Source: Andreu et al. 2018.²⁵ Reproduced with permission from Elsevier.

25–30% are SVTs. Emerging approaches to integrate these algorithms to provide more accurate scoring systems are being evaluated.²³

Figure 4 presents the ECG morphology of idiopathic ventricular tachycardia with different sites of origin²⁴ and Figure 5 demonstrates localisation of the origin of scar-related VT.²⁵

Electrophysiology Study

On certain occasions, such as tachycardias with borderline QRS duration and/or in the absence of atrioventricular dissociation, an electrophysiology study is necessary for diagnosis.²⁶

Irregular Tachycardias

An irregular ventricular rhythm most commonly indicates AF, multifocal atrial tachycardia or focal atrial tachycardia/atrial flutter with variable atrioventricular conduction, and may occur in the context of both narrow and broad QRS complexes. When AF is associated with rapid

ventricular rates, the irregularity of this ventricular response is less easily detected and can be misdiagnosed as a regular SVT.¹⁶ If the atrial rate exceeds the ventricular rate, then atrial flutter or atrial tachycardia (focal or multifocal) is usually present. Polymorphic VT and, rarely, monomorphic VT may also be irregular. Occasionally, a junctional, non-re-entrant tachycardia may have a variable rate.

The differential diagnosis of an irregular wide QRS tachycardia is either pre-excited AF or polymorphic VT or atrial arrhythmia with variable block in the context of aberrancy. Pre-excited AF manifests as irregularity, varying QRS morphology and rapid ventricular rate owing to the short RP of the accessory pathway. The changing QRS morphology results from varying degrees of fusion due to activation over both the accessory pathway and the atrioventricular node (or over two accessory pathways) which also results in variation in the width of the delta wave. The ventricular rate tends to be higher than in those with non-pre-excited AF.²⁸ ■

- Brugada J, Katritsis D, Arbelo E, et al. 2019 ESC guidelines for the management of supraventricular tachycardias. The Task Force for the management of patients with supraventricular tachycardia of the European Society of Cardiology (ECS). *Eur Heart J* 2019;41:655–720. <https://doi.org/10.1093/eurheartj/ehz467>; PMID: 31504425.
- Michowitz Y, Tovia-Brodie O, Heusler I, et al. Differentiating the QRS morphology of posterior fascicular ventricular tachycardia from right bundle branch block and left anterior hemiblock aberrancy. *Circ Arrhythm Electrophysiol* 2017;10:e005074. <https://doi.org/10.1161/CIRCEP.117.005074>; PMID: 28899954.
- Alzand BSN and Crijns HJGM. Diagnostic criteria of broad QRS complex tachycardia: Decades of evolution. *Europace* 2011;13:465–72. <https://doi.org/10.1093/europace/euq430>; PMID: 21131372.
- Stewart RB, Bardy GH, Greene H. Wide complex tachycardia: misdiagnosis and outcome after emergent therapy. *Ann Intern Med* 1986;104:766–71. <https://doi.org/10.7326/0003-4819-104-6-766>; PMID: 3706928.
- Priori SG, Blomstrom-Lundqvist C, Mazzanti A, et al. 2015 ESC guidelines for the management of patients with ventricular arrhythmias and the prevention of sudden cardiac death: the Task Force for the Management of Patients with Ventricular Arrhythmias and the Prevention of Sudden Cardiac Death of the European Society of Cardiology (ESC). Endorsed by: Association for European Paediatric and Congenital Cardiology (AEPCC). *Eur Heart J* 2015;36:2793–867. <https://doi.org/10.1093/eurheartj/ehv316>; PMID: 26320108.
- Al-Khatib SM, Stevenson WG, Ackerman MJ, et al. 2017 AHA/ACC/HRS guideline for management of patients with ventricular arrhythmias and the prevention of sudden cardiac death: a report of the American College of Cardiology/American Heart Association Task Force on Clinical Practice Guidelines and the Heart Rhythm Society. *Heart Rhythm* 2017;15:e190–252. <https://doi.org/10.1016/j.hrthm.2017.10.035>; PMID: 29097320.
- Wellens HJJ. Ventricular tachycardia: diagnosis of broad QRS complex tachycardia. *Heart* 2001;86:579–85. <https://doi.org/10.1136/heart.86.5.579>; PMID: 11602560.
- Willems S, Shenasa M, Borggreve M, et al. Atrioventricular nodal reentry tachycardia: electrophysiologic comparisons in patients with and without 2:1 infra-His block. *Clin Cardiol* 1993;16:883–8. <https://doi.org/10.1002/clc.4960161209>; PMID: 8168273.
- Ranger S, Talajic M, Lemery R, et al. Kinetics of use-dependent ventricular conduction slowing by antiarrhythmic drugs in humans. *Circulation* 1991;83:1987–94. <https://doi.org/10.1161/01.cir.1991.83.1987>.

- org/10.1161/01.CIR.83.6.1987; PMID: 2040051.
10. Jastrzebski M, Kukla P, Czarnecka D, et al. Comparison of five electrocardiographic methods for differentiation of wide QRS-complex tachycardias. *Europace* 2012;14:1165–71. <https://doi.org/10.1093/europace/eus015>; PMID: 22333239.
 11. Kindwall KE, Brown J, Josephson ME. Electrocardiographic criteria for ventricular tachycardia in wide complex left bundle branch block morphology tachycardias. *Am J Cardiol* 1988;61:1279–83. [https://doi.org/10.1016/0002-9149\(88\)91169-1](https://doi.org/10.1016/0002-9149(88)91169-1); PMID: 3376886.
 12. Brugada P, Brugada J, Mont L, et al. A new approach to the differential diagnosis of a regular tachycardia with a wide QRS complex. *Circulation* 1991;83:1649–59. <https://doi.org/10.1161/01.CIR.83.5.1649>; PMID: 2022022.
 13. Verecke A, Duray G, Szénási G, et al. New algorithm using only lead aVR for differential diagnosis of wide QRS complex tachycardia. *Heart Rhythm* 2008;5:89–98. <https://doi.org/10.1016/j.hrthm.2007.09.020>; PMID: 18180024.
 14. Pava LF, Perafán P, Badiel M, et al. R-wave peak time at DII: a new criterion for differentiating between wide complex QRS tachycardias. *Heart Rhythm* 2010;7:922–6. <https://doi.org/10.1016/j.hrthm.2010.03.001>; PMID: 20215043.
 15. Katritsis DG, Boriani G, Cosio FG, et al. European Heart Rhythm Association (EHRA) consensus document on the management of supraventricular arrhythmias, endorsed by Heart Rhythm Society (HRS), Asia-Pacific Heart Rhythm Society (APHRS), and Sociedad Latinoamericana de Estimulación Cardíaca y Electrofisiología (SOLAECE). *Eur Heart J* 2018;39:1442–5. <https://doi.org/10.1093/eurheartj/ehw455>; PMID: 28756499.
 16. Knight BP, Zivin A, Souza J, et al. Use of adenosine in patients hospitalized in a university medical center. *Am J Med* 1998;105:275–80. [https://doi.org/10.1016/S0002-9343\(98\)00261-7](https://doi.org/10.1016/S0002-9343(98)00261-7); PMID: 9809687.
 17. Yadav AV, Nazer B, Drew BJ, et al. Utility of conventional electrocardiographic criteria in patients with idiopathic ventricular tachycardia. *JACC Clin Electrophysiol* 2017;3:669–77. <https://doi.org/10.1016/j.jacep.2017.01.010>; PMID: 29759535.
 18. Steurer G, GURSOY S, Frey B, et al. The differential diagnosis on the electrocardiogram between ventricular tachycardia and preexcited tachycardia. *Clin Cardiol* 1994;17:306–8. <https://doi.org/10.1002/clc.4960170606>; PMID: 8070148.
 19. Jastrzebski M, Moskal P, Kukla P, et al. Specificity of wide QRS complex tachycardia criteria and algorithms in patients with ventricular preexcitation. *Ann Noninvasive Electrocardiol* 2018;23:e12493. <https://doi.org/10.1111/anec.12493>; PMID: 28901670.
 20. Ceresnak SR, Liberman L, Avasarala K, et al. Are wide complex tachycardia algorithms applicable in children and patients with congenital heart disease? *J Electrocardiol* 2010;43:694–700. <https://doi.org/10.1016/j.jelectrocard.2010.02.008>; PMID: 20382398.
 21. Lau EW, Ng GA. Comparison of the performance of three diagnostic algorithms for regular broad complex tachycardia in practical application. *Pacing Clin Electrophysiol* 2002;25:822–7. <https://doi.org/10.1046/j.1460-9592.2002.00822.x>; PMID: 12049375.
 22. Baxi RP, Hart KW, Verecke A, et al. Verecke criteria as a diagnostic tool amongst emergency medicine residents to distinguish between ventricular tachycardia and supra-ventricular tachycardia with aberrancy. *J Cardiol* 2012;59:307–12. <https://doi.org/10.1016/j.jicc.2011.11.007>; PMID: 22341435.
 23. Jastrzebski M, Sasaki K, Kukla P, et al. The ventricular tachycardia score: a novel approach to electrocardiographic diagnosis of ventricular tachycardia. *Europace* 2016;18:578–84. <https://doi.org/10.1093/europace/euv118>; PMID: 25995387.
 24. Tanawuttiwat T, Nazarian S and Calkins H. The role of catheter ablation in the management of ventricular tachycardia. *Eur Heart J* 2016;37:594–609. <https://doi.org/10.1093/eurheartj/ehv421>; PMID: 26324538.
 25. Andreu D, Fernandez-Armenta J, Acosta J, et al. A QRS axis-based algorithm to identify the origin of scar-related ventricular tachycardia in the 17-segment American Heart Association model. *Heart Rhythm* 2018;15:1491–7. <https://doi.org/10.1016/j.hrthm.2018.06.013>; PMID: 29902584.
 26. Katritsis DG, Josephson ME. Differential diagnosis of regular, narrow-QRS tachycardias. *Heart Rhythm* 2015;12:1667–76. <https://doi.org/10.1016/j.hrthm.2015.03.046>; PMID: 25828600.
 27. Jobbe OMR. Caveats in preexcitation-related atrial fibrillation. *Am J Emerg Med* 2010;28:252–3. <https://doi.org/10.1016/j.ajem.2009.11.004>; PMID: 20159403.
 28. Katritsis DG, Boriani G, Cosio FG, et al. European Heart Rhythm Association (EHRA) consensus document on the management of supraventricular arrhythmias, endorsed by Heart Rhythm Society (HRS), Asia-Pacific Heart Rhythm Society (APHRS), and Sociedad Latinoamericana de Estimulación Cardíaca y Electrofisiología (SOLAECE). *Europace* 2017;19:465–511. <https://doi.org/10.1093/europace/euw301>; PMID: 27856540.