



Evaluation of the Effects of Silicone Oil on the Macula with Optical Coherence Tomography in Patients with Rhegmatogenous Retinal Detachment

✉ Duygu Er*, ✉ Hakan Öner**, ✉ Mahmut Kaya**, ✉ Oya Dönmez***

*University of Health Sciences Turkey Dr. Abdurrahman Yurtaslan Ankara Oncology Training and Research Hospital, Ankara, Turkey

**Dokuz Eylül University Faculty of Medicine, Department of Ophthalmology, İzmir, Turkey

***Private Tinaztepe Galen Hospital, İzmir, Turkey

Abstract

Objectives: The effects of silicone endotamponade duration on the macula were evaluated in patients with rhegmatogenous retinal detachment.

Materials and Methods: Sixty-five eyes of 65 cases with rhegmatogenous retinal detachment that underwent pars plana vitrectomy and silicone endotamponade were included in the study. All cases were classified in three groups according to duration of silicone tamponade: ≤ 3 months, 3-6 months, and ≥ 6 months. All cases were evaluated at 1 week, 1 month, and 3 months after silicone injection, just before and at 1 month after silicone removal in terms of intraretinal pathologies in the macula by using spectral-domain optical coherence tomography (SD-OCT).

Results: Sixteen (26.6%) of the patients were female and 49 (75.4%) were male. The mean age of the patients was 58.1 ± 12.1 years (18-82); the mean follow-up time was 12.4 ± 4 months (6-20). The mean duration of silicone tamponade was 6.7 ± 2.3 months (2-12). In 26.6% of patients with ellipsoid zone/outer limiting membrane defect, a statistically significant improvement in reflectivity was detected after silicone oil removal ($p=0.016$). There was a significant increase in central foveal thickness after silicone removal in eyes with duration of silicone more than 3 months ($p=0.003$ for 3-6 months, $p=0.006$ for ≥ 6 months). The prevalence of cystoid macular edema before and after silicone removal was also significantly higher in the eyes with silicone duration of 6 months or longer ($p<0.001$).

Conclusion: In eyes with silicone endotamponade, structural changes in the macula may differ according to the duration of silicone oil in the eye.

Keywords: Macula, optical coherence tomography, pars plana vitrectomy, rhegmatogenous retinal detachment, silicone oil

Introduction

Silicone oil was first used in vitreoretinal surgery by Cibis in 1962 and has since become one of the preferred intraocular tamponade materials in the treatment of retinal detachment cases.¹ Due to its high postoperative anatomical and functional success, it is often used in the surgical treatment of proliferative vitreoretinopathy (PVR), recurrent detachments, proliferative diabetic retinopathy, retinal detachment associated with giant

retinal tears, and detachments complicated by ocular trauma.² However, complications such as silicone-induced cataract, glaucoma, corneal decompensation, and band keratopathy, as well as microstructural alterations due to mechanical or biochemical damage to the retina have been reported when used as a long-term intraocular tamponade.^{3,4,5} A study in rabbit eyes showed that silicone infiltrated the internal limiting membrane (ILM) tissue after 3 months and then passed the ILM and reached the inner retinal layers after 12-18 months.⁶

Address for Correspondence: Duygu Er, University of Health Sciences Turkey Dr. Abdurrahman Yurtaslan Ankara Oncology Training and Research Hospital, Ankara, Turkey

E-mail: dr.duyguer@hotmail.com **ORCID-ID:** orcid.org/0000-0003-4114-2315

Received: 06.06.2020 **Accepted:** 23.09.2020

Cite this article as: Er D, Öner H, Kaya M, Dönmez O. Evaluation of the Effects of Silicone Oil on the Macula with Optical Coherence Tomography in Patients with Rhegmatogenous Retinal Detachment. Turk J Ophthalmol 2021;51:218-224

©Copyright 2021 by Turkish Ophthalmological Association
Turkish Journal of Ophthalmology, published by Galenos Publishing House.

In some cases, visual results are not very satisfactory despite anatomically successful treatment of the retinal detachment.^{7,8} Postoperative low visual acuity may result from epiretinal membrane, cystoid macular edema (CME), retinal folds, and/or persistent foveal detachment.^{9,10,11}

In order to reduce these complications, silicone should be removed from the eye as soon as stable retinal attachment is achieved. Silicone removal within 3-6 months postoperatively is generally recommended to minimize the potential side effects, but this period is still controversial. Although silicone removal causes relapse in 3.5-13.2% of cases, preventing silicone emulsification is still used as the main criterion instead of silicone-induced macular changes.^{12,13}

Spectral domain optical coherence tomography (SD-OCT) provides high-resolution cross-sectional retinal images regardless of silicone. This enables microstructural changes in the retina to be monitored by SD-OCT even in the presence of silicone.^{14,15}

In this prospective study, we aimed to evaluate intraretinal alterations in the macula with different periods of silicone duration using SD-OCT.

Materials and Methods

This prospective study included patients who underwent surgical treatment for rhegmatogenous retinal detachment in the retina unit of Dokuz Eylul University, Department of Ophthalmology, had regular follow-up, and showed complete macular attachment. Ethics committee approval was obtained before the study and the potential risks and benefits of surgery were explained to all patients and informed consent forms were obtained in accordance with the principles of the Declaration of Helsinki.

Patients with age-related macular degeneration, vitreomacular traction, retinal vein occlusion, diabetic retinopathy, retinal dystrophy, uveitis, glaucoma, corneal opacity, and posterior capsule opacification and those who developed recurrent detachment after silicone removal were not included in the study. In addition, patients with disrupted ellipsoid zone and/or external limiting membrane (EZ/ELM) reflectivity, CME, or subfoveal fluid (SFF) at postoperative 1 week examination were also excluded from the study.

The patients' age, sex, best corrected visual acuity (BCVA), intraocular pressure, and anterior segment findings were recorded preoperatively. All operations were performed by the same physician (H.Ö.). In all cases, a 3-port 23- or 25-gauge pars plana vitrectomy was performed. The detached retina was flattened using perfluorocarbon fluid (perfluorodecalin) and endolaser photocoagulation was performed around the tears and in 360 degrees to the retina. After air-fluid exchange, 1300 cSt silicone oil (Oxane®, Bausch & Lomb, Inc.) was used in patients with PVR stage B and C. During silicone removal, the silicone oil was actively removed by 23 or 25-gauge transconjunctival vitrectomy. Retinal reattachment was observed in all patients in follow-up.

The patients were divided into three groups according to the duration of intraocular silicone endotamponade: 3 months or less,

3-6 months, and 6 months or more. These groups were evaluated for microstructural alterations in the macula using SD-OCT (Heidelberg HRA-OCT Spectralis®, Heidelberg Engineering GmbH, Heidelberg, Germany). SD-OCT examinations were mainly focused on EZ/ELM damage (photoreceptor layer effects), central macular thickness (CMT), and the presence of CME and SFS. EZ/ELM damage was defined as disrupted integrity of the reflective lines over the retinal pigment epithelium (RPE) in the 2.0 mm diameter area corresponding to the central fovea. CME was defined as the presence of intraretinal cystoid fluid accumulations and intraretinal hyporeflective areas separated by hyperreflective septa. The presence of a dome-shaped subretinal hyporeflective space centered on the fovea was evaluated as SFF. In patients with SFF, CMT was measured manually in the SFS region by calculating the retinal thickness remaining over the fluid.

BCVA, intraocular pressure, fundus examination, and SD-OCT measurements were performed routinely at 1 week, 1 month, and 3 months after detachment surgery, before silicone removal, and at 1 month after silicone removal. Images were obtained from a 20x20 degree (6x6 mm) scan area consisting of 49 sections using horizontal scan patterns. OCT findings at 1 week after silicone injection were compared with later OCT findings.

Statistical Analysis

The data were analyzed using SPSS 15.0 software (SPSS Inc, Chicago, IL, USA). Descriptive analysis was performed using mean, standard deviation, and percentage values. The Kolmogorov-Smirnov test was used to evaluate whether the data showed normal distribution. Measurements were compared between eyes with parametric t-test or nonparametric Mann-Whitney U test. OCT findings and CMT in the silicone duration groups were compared using Kruskal-Wallis test. Statistical significance was accepted as $p < 0.05$.

Results

The study included 65 eyes of 65 patients who underwent anatomically successful surgical treatment of rhegmatogenous retinal detachment. Of the patients, 16 (26.6%) were women and 49 (75.4%) were men. The patients' mean age was 58.1 ± 12.1 years (range, 18-82). The mean follow-up period was 12.4 ± 4 months (range, 6-20). All patients had a posterior chamber intraocular lens before pars plana vitrectomy. Surgical treatment consisted of 3-port, 23 or 25-gauge pars plana vitrectomy, and silicone tamponade in all cases. The mean duration of intraocular silicone was 6.7 ± 2.3 months (range, 2-12).

There were 12 eyes in the group with ≤ 3 months silicone duration, 31 eyes in the 3-6 months group, and 22 eyes in the ≥ 6 months group. Intraretinal SD-OCT findings according to intraocular silicone duration are shown in Tables 1, 2, and 3.

The results of the statistical analysis comparing CMT values measured after vitrectomy and silicone removal are shown in Table 4. Eyes with silicone duration longer than 3 months showed a statistically significant increase in CMT between

values measured after silicone injection and after silicone removal ($p < 0.05$), while this increase was not significant in the group with silicone duration of 3 months or less ($p > 0.05$).

When SD-OCT findings were compared according to intraocular silicone duration, no difference was observed between the groups in terms of EZ/ELM changes or SFS, whereas the development of CME was significantly more frequent in the group with silicone duration of 6 months or more than in the other two groups ($p < 0.001$). Of all eyes that developed CME, 21.5% showed an increase in CME after silicone removal, but this increase was not significant ($p > 0.05$).

Comparison of SD-OCT findings immediately before and after silicone intake in all eyes regardless of intraocular silicone duration revealed significant differences in EZ/ELM continuity and SFF ($p = 0.016$ and $p < 0.001$, respectively). Restored reflectivity was observed in 26.6% of patients with EZ/ELM defects after silicone removal, which was determined to be statistically significant ($p = 0.016$). Statistically significant SFS resolution was observed after silicone removal in all patients (100%) with SFS ($p < 0.001$) (Figures 1, 2, 3).

Discussion

Depending on how long the silicone oil used to ensure anatomical success of retinal detachment surgery remains in the eye, there may be additional complications such as cataracts, glaucoma, and keratopathy, as well as microstructural damage to the retina due to mechanical stress or biochemical toxicity, and these changes can now be easily detected with SD-OCT.^{6,7}

The duration of silicone oil in the eye can range from 2 to 13 months.^{16,17,18,19,20,21,22} In many studies, it has been stated that the ideal timing of silicone removal is between 3 and 6 months, and

silicone emulsifies after 6 months.²³ In contrast, Jiang and Li²³ stated that silicone removal should be performed at 2-3 months. Despite the lack of consensus on the timing of silicone removal, it has been established that it should be done when the retina is anatomically attached and stable.¹⁵ Bae et al.²⁴ reported that the silicone removal time should be decided by clinicians based on a benefit-risk analysis. In our study, the mean silicone duration was 6.7 ± 2.3 months (range, 2-12). Of the 65 patients, silicone remained in the eye for less than 6 months in 43 eyes (66.1%) and 6 months or longer in 22 eyes (33.8%).

Caramoy et al.²⁵ determined that silicone primarily caused thinning of the retinal ganglion cell layer and inner plexiform layer. This retinal thinning was assumed to be a result of mechanical pressure from the silicone on the retina. Therefore, SD-OCT studies have shown that timely silicone removal may result in resolution of microstructural changes in the retina, restoration of the photoreceptor layer and ELM, and improved vision.^{24,25} Bae et al.²⁴ observed recovery of ELM reflectivity in 12.5% of patients after silicone removal and emphasized the importance of early silicone removal to prevent macular changes.

In our study, we evaluated EZ and ELM changes together as a better indicator of photoreceptor integrity, and SD-OCT confirmed that the EZ/ELM was intact at postoperative week 1 in all eyes included in the study. When EZ/ELM reflectivity was evaluated in correlation with silicone duration, of the 12 eyes with silicone duration ≤ 3 months, defects were observed in 1 eye (8.3%) at 1 month after silicone injection and in 3 eyes (25%) at 3 months or before silicone removal. The prevalence of defects in this group increased to 50% (6 eyes) after silicone removal. This increase may be due to persistent deterioration of the affected photoreceptors despite early silicone removal. In some studies,

Table 1. Optical coherence tomography (OCT) findings of patients with silicone duration ≤ 3 months

OCT finding	Postop 1 week	Postop 1 month	Postop 3 months	Before silicone removal	1 month after silicone intake
EZ/ELM defect	0	1 (8.3%)	3 (25%)	3 (25%)	6 (50%)
CME	0	4 (33.3%)	4 (33.3%)	4 (33.3%)	2 (16.7%)
SFF	0	1 (8.3%)	1 (8.3%)	1 (8.3%)	0

EZ/ELM: Ellipsoid zone \pm external limiting membrane, CME: Cystoid macular edema, SFF: Subfoveal fluid, Postop: Postoperative

Table 2. Optical coherence tomography (OCT) findings of patients with silicone duration of 3-6 months

OCT finding	Postop 1 week	Postop 1 month	Postop 3 months	Before silicone removal	1 month after silicone intake
EZ/ELM defect	0	8 (25.8%)	9 (29%)	10 (32.3%)	3 (9.7%)
CME	0	3 (9.7%)	4 (12.9%)	4 (12.9%)	13 (41.9%)
SFF	0	4 (12.9%)	4 (12.9%)	4 (12.9%)	0

EZ/ELM: Ellipsoid zone \pm external limiting membrane, CME: Cystoid macular edema, SFF: Subfoveal fluid, Postop: Postoperative

Table 3. Optical coherence tomography (OCT) findings of patients with silicone duration ≥ 6 months

OCT finding	Postop 1 week	Postop 1 month	Postop 3 months	Before silicone removal	1 month after silicone intake
EZ/ELM defect	0	2 (9.1%)	1 (4.5%)	2 (9.1%)	2 (9.1%)
CME	0	6 (27.3%)	10 (45.5%)	11 (50.0%)	13 (59.1%)
SFF	0	1 (4.5%)	1 (4.5%)	1 (4.5%)	0

EZ/ELM: Ellipsoid zone \pm external limiting membrane, CME: Cystoid macular edema, SFF: Subfoveal fluid, Postop: Postoperative

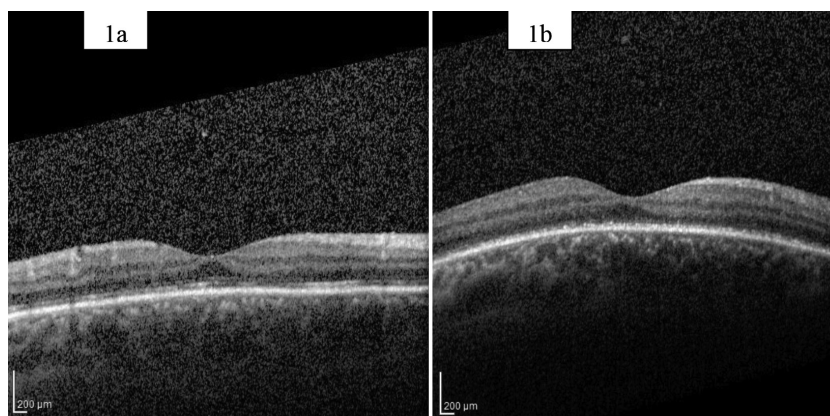


Figure 1. Optical coherence tomography sections of an eye with silicone duration of 5 months. a) Appearance of the macula 1 week after silicone injection. b) Immediately before silicone removal, irregularities in the ellipsoid zone and disruption of the external limiting membrane structure are observed

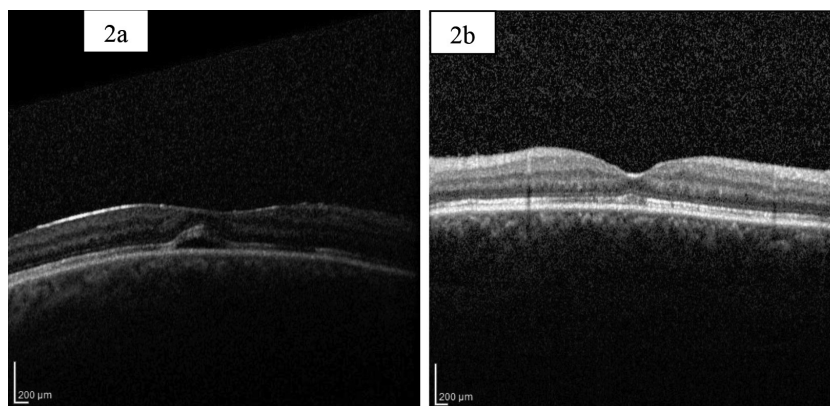


Figure 2. Optical coherence tomography sections of an eye with silicone duration of 4 months. a) Subretinal fluid is observed at 3 months. b) The subretinal fluid had spontaneously resolved by 1 month after silicone removal

Table 4. Comparison of central macular thickness values after silicone injection and removal

	CMT (μm)		
	Silicone duration ≤ 3 months	Silicone duration 3-6 months	Silicone duration ≥ 6 months
Postop 1 week	258	229	227
p	0.220	<0.001	<0.001
Postop 1 month	272	244	256
p	0.110	<0.001	0.001
Postop 3 months	262	275	286
p	0.071	0.007	0.006
Before silicone removal	280	276	315
p	0.084	0.003	0.006
1 month after silicone removal	286	334	366

Postop: Postoperative, CMT: Central macular thickness

it has been reported that the inflammatory response to silicone in the retina develops approximately 1 month after silicone injection and continues after silicone removal.^{24,26}

In addition, silicone oil triggers the mitogenic effect in RPE cells.²⁷ Although silicone has been shown in the literature to be toxic to cultured RPE cells, no significant structural changes on OCT have been reported in the RPE after silicone injection.²⁸ We believe that there may be regeneration of the EZ/ELM layers over time, especially in eyes with intact RPE. However, we think that even if the RPE layer is intact, this regeneration process may start at the earliest 4 months after silicone administration, and degeneration may continue even if the silicone is removed during this period. In fact, unlike the eyes in which the silicone was removed earlier, we observed that the EZ/ELM defect improved significantly or did not worsen at 1 month after silicone removal when performed later than 3 months. Bae et al.²⁴ reported resolution of the EZ defect in 4.9% of eyes at 6-month follow-up, while Eibenberger et al.²⁹ reported this restoration in 33% of eyes at 3-year follow-up.

The influence of silicone on CME is not yet fully understood. However, CME is thought to occur secondary to an increase in vascular permeability due to the accumulation of inflammatory factors between the silicone and retina.^{23,30,31,32} In the literature, CME has been detected at different rates in eyes with silicone. Bae et al.²⁴ reported that CME occurred in 19.6% of eyes that

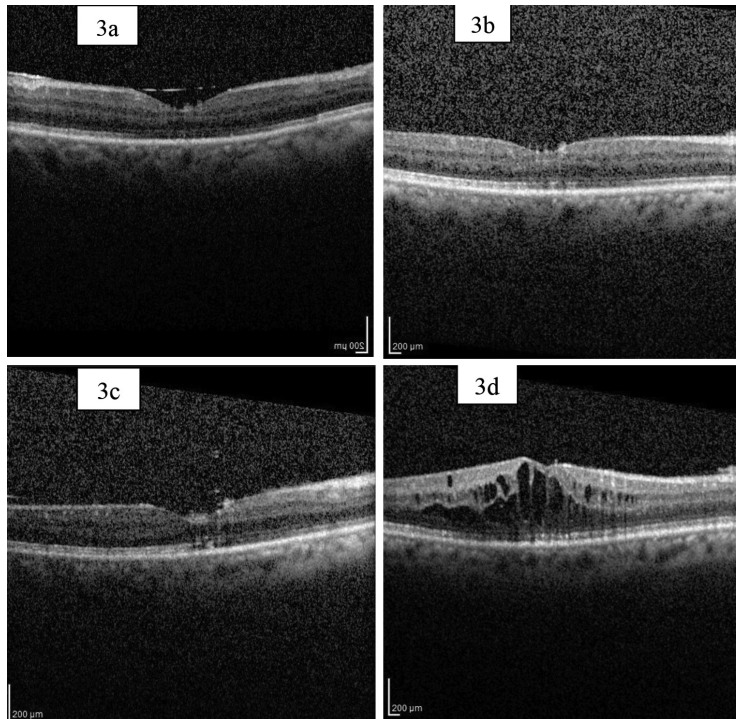


Figure 3. Optical coherence tomography sections of an eye with silicone duration of 7 months. a) Appearance of the macula at 1 week after silicone injection. b) Ellipsoid zone and external limiting membrane reflectivity are within normal limits 1 month after silicone removal. c) Disruption of ellipsoid zone and external limiting membrane reflectivity is observed immediately before silicone removal. d) Cystoid macular edema is observed 1 month after silicone removal

received silicone and resolved in all eyes after silicone removal. Bonnet³³ determined the prevalence of CME to be 51%. In contrast, Kiss et al.³² observed CME in 17.1% of eyes that received silicone and reported that this rate increased to 47% after silicone removal. On the other hand, Eibenberger et al.²⁹ reported microcystic changes in the inner nuclear layer in 21% of eyes after silicone removal. In another study, it was stated that growth factors accumulating under the silicone diffuse into the vitreous cavity after silicone removal, thereby leading to CME resolution due to the decrease in the inflammatory response causing edema.²⁴ In our study, 44.6% of the eyes had CME after silicone injection, while this rate was 43.0% after silicone removal. When all eyes were examined together, CME was detected in 18 eyes (27.6%) immediately before silicone removal. CME occurred significantly more frequently in the group with silicone duration of 6 months or longer compared to the other two groups ($p < 0.001$). After silicone removal, CME resolved in eyes with silicone duration of 3 months or less but increased in eyes with silicone duration longer than 3 months. Silicone duration longer than 6 months may increase its toxic effect and more CME due to the increased inflammatory response. CME may also continue after silicone removal due to the toxic retinal effects associated with prolonged silicone duration.

There are studies indicating that silicone causes some thinning of the inner retinal layers due to mechanical pressure on the retina, high intraocular pressure, or retinal dehydration.^{34,35}

It has also been reported in the literature that potassium released from Müller cells causes neuronal degeneration due to its inability to pass into the silicone, and for this reason retinal thinning can be observed in the presence of silicone endotamponade.¹⁷ These series are supported by our findings that CMT measured after silicone removal increased significantly in the longer duration groups but not in eyes with silicone duration of less than 3 months.

Another phenomenon seen after surgery in vitrectomized eyes that receive silicone is the accumulation of SFF. It is reported to occur at rates of 0-40% after vitrectomy surgery.^{31,32,33,34,35,36} Veckeneer et al.³⁷ reported that eyes with prolonged detachment were at risk of developing more intense SFF. However, in our study, no SFF was detected in SD-OCT measurements taken immediately after surgery but developed later in 9.2% of the eyes. Therefore, we think that this SFF may be a reactive exudation to silicone or that silicone may have an effect on the pump function of the RPE, which spontaneously resolved in all cases after silicone removal.

Conclusion

In conclusion, eyes with rhegmatogenous retinal detachment and silicone endotamponade show silicone-induced macular changes, and these structural disruptions can vary depending on the duration of silicone oil in the eye. We believe silicone removal before 3 months is appropriate to

minimize these structural changes in the retina. Moreover, we believe that the toxic effects on the retina may continue even after silicone removal and can be better demonstrated in new studies with larger patient groups.

Ethics

Ethics Committee Approval: Dokuz Eylul University Faculty of Medicine Non-invasive Research Ethics Committee no: 791-GOA.

Informed Consent: Obtained.

Peer-review: Externally peer reviewed.

Authorship Contributions

Surgical and Medical Practices: H.Ö., Concept: D.E., Design: D.E., Data Collection or Processing: D.E., O.D., Analysis or Interpretation: D.E., M.K., Literature Search: D.E., O.D., Writing: D.E.

Conflict of Interest: No conflict of interest was declared by the authors.

Financial Disclosure: The authors declared that this study received no financial support.

References

- Cibis PA, Becker B, Okun E, Canaan S. The use of liquid silicone in retinal detachment surgery. *Arch Ophthalmol.* 1962;68:590-599.
- Sima P, Zoran T. Long term results of vitreous surgery for proliferative diabetic retinopathy. *Doc Ophthalmol.* 1994;87:223-232.
- No authors listed. The silicone study group. Vitrectomy with silicone oil or sulfur hexafluoride gas in eyes with severe proliferative vitreoretinopathy; results of a randomized clinical trial. Silicone study report 1. *Arch Ophthalmol.* 1992;110:770-779.
- No authors listed. The silicone study group. Vitrectomy with silicone oil or sulfur hexafluoride gas in eyes with severe proliferative vitreoretinopathy; results of a randomized clinical trial. Silicone study report 2. *Arch Ophthalmol.* 1992;110:780-792.
- Ünsal E, Karini B, Çubuk MÖ, Eltutar K. Silikon Yağı Tamponadı Kullanılmış Yırtıklı Retina Dekolmanı Olgularında Cerrahi Sonuçlarımız ve İlişkili Faktörler. *Ret-Vit.* 2018;27:109-116.
- Suzuki M, Okada T, Takeuchi S, Ishii Y, Yamashita H, Hori S. Effect of silicone oil on ocular tissues. *Jpn J Ophthalmol.* 1991;35:282-291.
- Avcı R, Şahin S, Yücel AA, Gelişken Ö. Kronik Oküler Hipotonide Cerrahi Tedavi Yaklaşımları. *Ret-Vit.* 1996;2:562-527. <http://retinavitreous.com/abstract.php?lang=tr&id=535>
- Guzel H, Özkan Ş, Şener B. Kliniğimizde son üç yıl içinde yapılan retina dekolmanı ameliyatı sonuçları. *Türk J Ophthalmol.* 1986;16:146-152.
- Cleary PE, Leaver PK. Macular abnormalities in the reattached retina. *Br J Ophthalmol.* 1978;62:595-603.
- Tani P, Robertson DM, Langworthy A. Prognosis for central vision and anatomic reattachment in rhegmatogenous retinal detachment with macula detached. *Am J Ophthalmol.* 1981;92:611-620.
- Çetin EN, Scanlon C, Saxena S, Akduman L. The Visual Outcome and the Related Factors in Macula off Rhegmatogenous Retinal Detachment. *Ret-Vit.* 2013;21:183-188.
- Oster SE, Mojana F, Bartsch DU, Goldbaum M, Freeman WR. Dynamics of the macular hole silicone oil tamponade interface with patient positioning as imaged by spectral domain optical coherence tomography. *Retina.* 2010;30:924-929.
- Göbel W, Guthoff R. Morphology of macular holes after pars plana vitrectomy with silicone oil endotamponade: a pilot study with high resolution Fourier domain OCT. (Cirrus OCT) *Ophthalmologie.* 2010;107:452-459.
- Choudhary MM, Saeed MU, Ali A. Removal of silicone oil: prognostic factors and incidence of retinal redetachment. *Retina.* 2012;32:2034-2038.
- Teke MY, Balıkoğlu-Yılmaz M, Yuksekkaya P, Citirik M, Elgin U, Kose T, Öztürk F. Surgical outcomes and incidence of retinal redetachment in cases with complicated retinal detachment after silicone oil removal: univariate and multiple risk factors analysis. *Retina.* 2014;34:1926-1938.
- Bozan E, Özdek Ş, Gürel G, Konuk O, Hasanreisioğlu B. İntravitreal Silikon Alınması Sonrası Nüks Retina Dekolmanı. *Türkiye Klinikleri J Ophthalmol.* 2004;13:13-17.
- Smith AJ, Telander DG, Zawadzki RJ, Choi SS, Morse LS, Werner JS, Park SS. High-resolution Fourier-domain optical coherence tomography and microperimetric findings after macula-off retinal detachment repair. *Ophthalmology.* 2008;115:1923-1929.
- Wakabayashi T, Oshima Y, Fujimoto H, Murakami Y, Sakaguchi H, Kusaka S, Tano Y. Foveal microstructure and visual acuity after retinal detachment repair: imaging analysis by Fourier-domain optical coherence tomography. *Ophthalmology.* 2009;116:519-528.
- Hutton WL, Azen SP, Blumenkranz MS, Lai MY, McCuen BW, Han DP, Flynn Jr HW, Ramsay RC, Ryan SJ. The effects of silicone oil removal. Silicone Study Report 6. *Arch Ophthalmol.* 1994;112:778-785.
- Jonas JB, Budde WM, Knorr HL. Timing of retinal detachment after removal of intraocular silicone oil tamponade. *Am J Ophthalmol.* 1999;128:628-631.
- Bassat IB, Desatnik H, Alhalel A, Treister G, Moisseiev J. Reduced rate of retinal detachment following silicone oil removal. *Retina.* 2000;20:597-603.
- Laidlaw DA, Karia N, Bunce C, Aylward GW, Gregor ZJ. Is prophylactic 360-degree laser retinopexy protective? Risk factors for retinal redetachment after removal of silicone oil. *Ophthalmology.* 2002;109:153-158.
- Jiang Y, Li X. The best timing of silicone oil removal. *Zhonghua Yan Ke Za Zhi.* 1997;33:39-41.
- Bae SH, Hwang JS, Gon Yu H. Comparative analysis of macular microstructure by spectral domain optical coherence tomography before and after silicone oil removal. *Retina.* 2012;32:1874-1883.
- Caramoy A, Droegge K, Kirchhof B, Fauser S. Retinal layers measurements in healthy eyes and in eyes receiving silicone oil-based endotamponade. *Acta Ophthalmol.* 2014;92:292-97.
- Wolf S, Schön V, Meier P, Wiedemann P. Silicone oil-RMN₃ mixture ("heavy silicone oil") as internal tamponade for complicated retinal detachment. *Retina.* 2003;23:335-342.
- Asaria RH, Kon CH, Bunce C, Sethi CS, Limb GA, Khaw PT, Aylward GW, Charteris DG. Silicone oil concentrates fibrogenic growth factors in the retro-ocular fluid. *Br J Ophthalmol.* 2004;88:1439-1442.
- Inoue M, Iriyama A, Kadonosono K, Tamaki Y, Yanagi Y. Effects of perfluorocarbon liquids and silicone oil on human retinal pigment epithelial cells and retinal ganglion cells. *Retina.* 2009;29:677-681.
- Eibenberger K, Sacu S, Rezar-Dreindl S, Schmidt-Erfurth U, Georgopoulos M. Silicone Oil Tamponade in Rhegmatogenous Retinal Detachment: Functional and Morphological Results. *Curr Eye Res.* 2020;45:38-45.
- Purtskhvanidze K, Hillenkamp J, Tode J, Junge O, Hedderich J, Roeder J, Treumer E. Thinning of inner retinal layers after vitrectomy with silicone oil versus gas endotamponade in eyes with macula-off retinal detachment. *Ophthalmologica.* 2017;238:124-132.
- Lee SH, Han JW, Byeon SH, Kim SS, Koh HJ, Lee SC, Kim M. Retinal layer segmentation after silicone oil or gas tamponade for macula-on retinal detachment using optical coherence tomography. *Retina.* 2018;38:310-319.
- Kiss CG, Richter-Müsch S, Sacu S, Benesch T, Velikay-Parel M. Anatomy and function of the macula after surgery for retinal detachment complicated by proliferative vitreoretinopathy. *Am J Ophthalmol.* 2007;144:872-877.
- Bonnet M. Macular changes and fluorescein angiographic findings after repair of proliferative vitreoretinopathy. *Retina.* 1994;14:404-410.
- Benson SE, Schlottmann PG, Bunce C, Xing W, Charteris DG. Optical coherence tomography analysis of the macula after vitrectomy surgery for retinal detachment. *Ophthalmology.* 2006;113:1179-1183.
- Shimoda Y, Sano M, Hashimoto H, Yokota Y, Kishi S. Restoration of photoreceptor outer segment after vitrectomy for retinal detachment. *Am J Ophthalmol.* 2010;149:284-290.

36. Theodossiadis PG, Georgalas IG, Emfietzoglou J, Kyriaki TE, Pantelia E, Gogas PS, Moschos MN, Theodossiadis GP. Optical coherence tomography findings in the macula after treatment of rhegmatogenous retinal detachments with spared macula preoperatively. *Retina*. 2003;23:69-75.
37. Veckeneer M, Derycke L, Lindstedt EW, Meurs JV, Cornelissen M, Bracke M, Aken EV. Persistent subretinal fluid after surgery for rhegmatogenous retinal detachment: hypothesis and review. *Graefes Arch Clin Exp Ophthalmol*. 2012;250:795-802.