



## Case report

## Late detachment of Descemet's membrane after penetrating keratoplasty for pellucid marginal degeneration

Jonathan Lin<sup>a</sup>, Salima Hassanaly<sup>a</sup>, Robert A. Hyde<sup>a</sup>, Jennifer Brown<sup>b</sup>, Dan Yoon<sup>a</sup>, Charles Q. Yu<sup>a,\*</sup><sup>a</sup> Department of Ophthalmology & Visual Sciences, University of Illinois College of Medicine, 1855 W Taylor Street, Chicago, IL 60612, USA<sup>b</sup> Jesse Brown VA Medical Center, 820 S Damen Ave, Chicago, IL 60612, USA

## ARTICLE INFO

## Keywords:

Descemet's membrane

PROSE

Pellucid marginal degeneration

Penetrating keratoplasty

Endothelial keratoplasty

Graft rejection

## ABSTRACT

**Purpose:** we report a case of late spontaneous large detachment of Descemet's membrane in recurrent pellucid marginal degeneration after penetrating keratoplasty.**Observations:** a 73-year-old man presented to clinic with spontaneous detachment of his Descemet's membrane 30 years after penetrating keratoplasty for pellucid marginal degeneration. Efforts were made to bubble the membrane back into place without success. The patient then underwent endothelial keratoplasty with successful restoration of cornea clarity.**Conclusions and importance:** this condition may cause diagnostic and treatment dilemmas if not properly identified and managed. In addition this case has information for both the use of scleral contact lens and the success of endothelial keratoplasty in an extremely steep cornea.

## 1. Introduction

Penetrating keratoplasty is an excellent treatment for progressive ectatic disorders such as keratoconus and pellucid marginal degeneration.<sup>1</sup> However, there can be redevelopment of the ectasia in the graft.<sup>2</sup> In some patients, as the corneal stroma continues to progressively steepen and thin, there is spontaneous detachment of the Descemet's membrane. This results in sudden cornea edema that can be mistaken for acute graft rejection. This has been reported in several cases of recurrent keratoconus but not in recurrent pellucid marginal degeneration.<sup>3–6</sup> Here we report a case of spontaneous Descemet's membrane detachment in recurrent pellucid marginal degeneration. The case also reports the use of the Prosthetic Replacement of Ocular Surface Environment (PROSE, Boston Foundation for Sight, Needham, MA) scleral contact lens for recurrent pellucid marginal degeneration and the success of DSAEK in a very steep cornea.

## 2. Case report

A 73-year-old man presented to the cornea clinic with a complaint of decreased vision and intolerance of RGP contact lens use in the right eye. He reported a history of pellucid marginal degeneration in both eyes and penetrating keratoplasty over 30 years prior in the right eye. His best spectacle corrected visual acuity (BSCVA) was 20/100 in the

right eye and 20/40 in the left eye. On exam, the cornea in the left eye was clear. The cornea in right eye demonstrated a clear, full thickness graft with inferior decentration. There was severe steepening and thinning of the inferior right cornea graft and host. Corneal topography demonstrated keratometry of 62D/41D in the right eye. The left eye had keratometry of 48D/38D with a classic crab claw appearance (Fig. 1). Due to concern for thinness of the graft-host junction and the risk of rejection with a repeat eccentric penetrating keratoplasty, the patient was referred to the optometry service for fitting with a PROSE scleral contact lens for the right eye. The patient returned to clinic 3 months later and reported excellent vision and tolerance of the PROSE contact lens. His best corrected visual acuity (BCVA) with his PROSE lens measured 20/25 in the right eye.

One year after his initial visit, the patient presented to clinic acutely for sudden onset of blurred vision in the right eye. He reported this occurred upon awakening, spontaneously, without any history of trauma. On exam, BCVA with contact lens was 20/200 and there was diffuse moderate corneal edema in the right eye. A shallow detachment of Descemet's membrane covering ~70% of the graft was noted (Fig. 2A). This was confirmed by anterior segment optical coherence tomography (AS OCT) (Fig. 3) After discussion, we proceeded with an inferior descemetorhexis from 4 to 8 o'clock followed by bubbling of the detached membrane in an attempt to relieve traction and recenter the graft. A 60% air bubble was left and patient positioned face up

\* Corresponding author.

E-mail address: [chyu83@stanford.edu](mailto:chyu83@stanford.edu) (C.Q. Yu).<https://doi.org/10.1016/j.ajoc.2018.12.016>

Received 22 June 2018; Received in revised form 4 October 2018; Accepted 17 December 2018

Available online 18 December 2018

2451-9936/© 2018 Published by Elsevier Inc. This is an open access article under the CC BY-NC-ND license (<http://creativecommons.org/licenses/by-nc-nd/4.0/>).

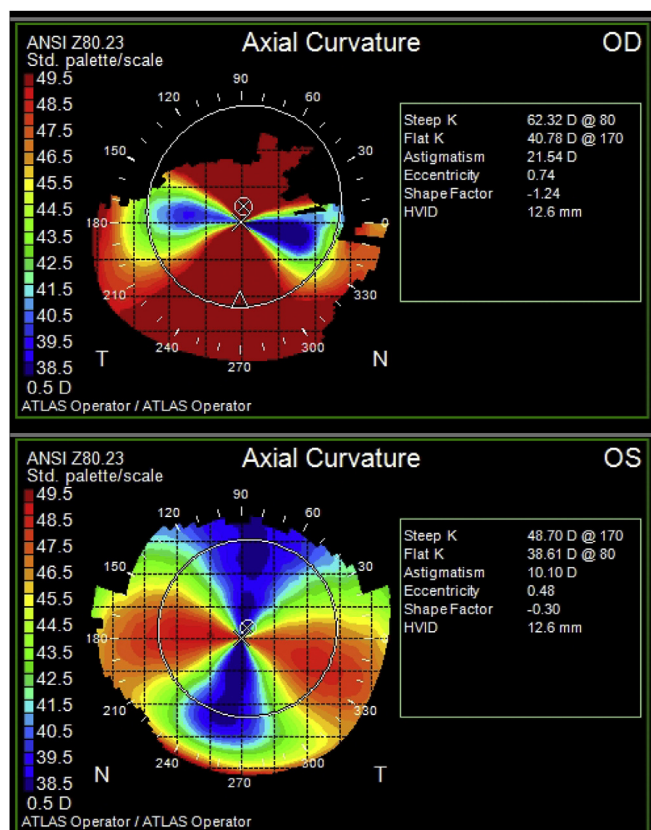


Fig. 1. Axial topography demonstrates severe steepening of the right eye. The left eye has a classic crab claw appearance of pellucid marginal degeneration.

overnight. On postoperative day one, Descemet's membrane was noted to still be detached by AS OCT. A rebubbling procedure was performed and the patient was instructed to position face up. On return visit the next day, Descemet's membrane was still detached. At this time, repeat penetrating keratoplasty or endothelial keratoplasty were among the treatment modalities discussed. Because the patient was tolerating contact lens correction and due to the high risk of repeat full-thickness keratoplasty, the patient underwent Descemet's stripping automated endothelial keratoplasty (DSAEK) with an 8.5 mm diameter, 95 μm thick graft the following week. The DSAEK procedure was uncomplicated and the graft was attached. The patient's cornea cleared and contact lens corrected BCVA was 20/40 at one-month post DSAEK (Fig. 2B).

### 3. Discussion

The first notable aspect of this case is the use of a PROSE lens in recurrent pellucid marginal degeneration. The PROSE lens is a scleral contact lens which is custom manufactured and fitted to patients with severe ocular surface disease.<sup>7</sup> However, given its vault over the cornea it has been reported to be useful in corneal ectasia as well.<sup>8</sup> This is the first report of successful PROSE use in recurrent pellucid marginal degeneration, offering a noninvasive option to avoid the need for a very high-risk repeat eccentric penetrating keratoplasty. We have no reason to believe the use of PROSE led to spontaneous Descemet's detachment in this case.

Secondly, to the best of our knowledge, this is the first report of spontaneous Descemet's detachment in recurrent pellucid marginal degeneration after penetrating keratoplasty. Prior it was a rare complication reported in a handful of cases of recurrent keratoconus. The mechanism is likely similar in both, and related to the different tolerance to stretch of corneal stroma and Descemet's membrane as corneal

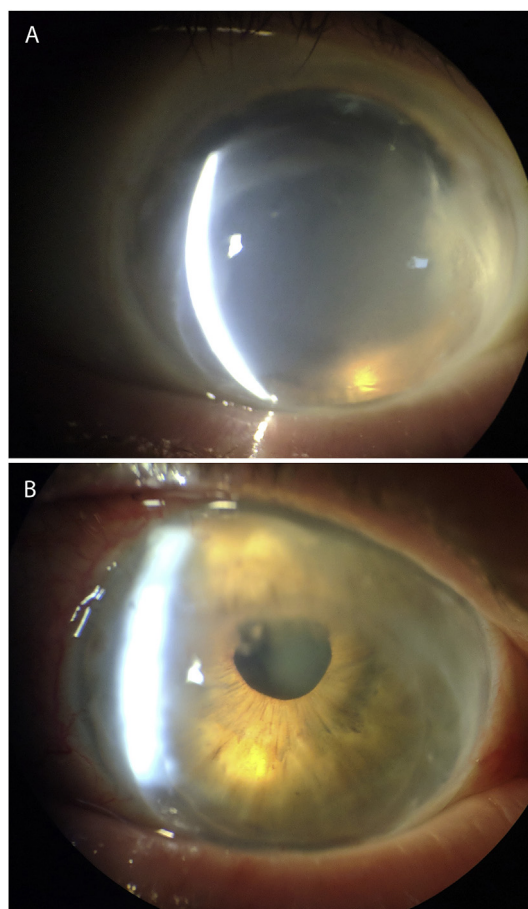
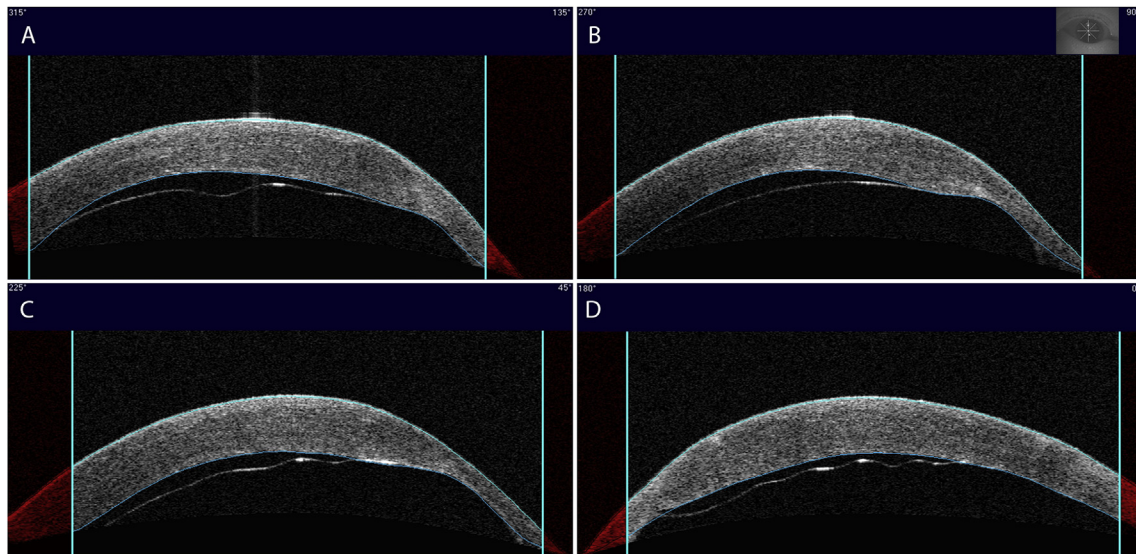


Fig. 2. A. Slit lamp photograph demonstrates diffuse corneal edema and haze. B. Clear cornea graft 1-month post DSAEK. Corneal opacity blocking view of superior pupil is the original graft-host junction.

ectasia recurs. It is important to keep Descemet's detachment within the differential diagnosis for sudden onset of post-graft corneal edema and to carefully examine the patient, using AS OCT if necessary. Failure to recognize this condition could result in inappropriate and ineffective treatment for corneal rejection or infection. There has been report of successfully bubbling of spontaneous detachments that occurred in grafts with recurrent keratoconus.<sup>5</sup> We attempted this procedure after identifying (using OCT) and relieving direction of “tautness” in the inferior to superior meridian. However this attempt was unsuccessful. Of note, the size of the detachment was larger in our case than that reported previously, and perhaps the use of expansile gas such as sulfur hexafluoride could have been helpful. A larger descemetorhexis could have better relieved stresses on Descemet's membrane and improved chances of initial reattachment.

Lastly, prior to surgery it was unclear whether this patient's very steep cornea could have made DSAEK attachment more difficult. Usually, when there is significant corneal steepening, anterior lamellar or penetrating keratoplasty is the procedure of choice. There is little data on endothelial keratoplasty in very steep corneas. Potentially, at some severe level of steepening, radial folds could develop in the graft due to curvature mismatch, preventing attachment. We did not note endothelial keratoplasty to be any more difficult than usual for this patient, and no radial folds formed. In this case, an eye with a keratometry of 62D was not a barrier to successful DSAEK. Descemet's membrane endothelial keratoplasty (DMEK) is also likely a viable option in the treatment of Descemet's detachment due to recurrent corneal ectasia should attempts at re-bubbling fail.

In summary, we here report a case of pellucid marginal



**Fig. 3.** Four planes of AS OCT show Descemet's detachment and tautness extending inferior to superior. A. 135°–315° B. 90°–270° C. 45°–225° D. 0°–180°.

degeneration complicated by spontaneous Descemet's detachment post-penetrating keratoplasty, with implications for PROSE use and endothelial keratoplasty.

#### Patient consent

Written consent to publish case details has been obtained from the patient.

#### Acknowledgements and disclosures

#### Funding

NEI K08EY027459 (CY), Research to Prevent Blindness.

#### Conflicts of interest

None.

#### Authorship

All authors attest that they meet the current ICMJE criteria for authorship.

#### Acknowledgements

This work was supported by National Eye Institute (NEI) P30EY001792 (CY), K08EY027459 (CY), Research to Prevent Blindness.

#### References

- Maharana PK, Dubey A, Jhanji V, Sharma N, Das S, Vajpayee RB. Management of advanced corneal ectasias. *Br J Ophthalmol.* 2016;100:34–40.
- Pramanik S, Musch DC, Sutphin JE, Farjo AA. Extended long-term outcomes of penetrating keratoplasty for keratoconus. *Ophthalmology.* 2006;113:1633–1638.
- Ho VW, Romano V, Steger B, Kaye SB. Possible role of descemet-stroma interface for descemet's membrane detachment after penetrating keratoplasty. *J Ophthalmic Vis Res.* 2018;13:72–74.
- Gorski M, Shih C, Savoie B, Udell I. Spontaneous Descemet membrane detachment 20 Years after penetrating keratoplasty for keratoconus. *Cornea.* 2016;35:1023–1025.
- D'Souza S, Solanki N, Sushma KR, Solanki P. Late onset Descemet's membrane detachment 20 years after penetrating keratoplasty. *Indian J Ophthalmol.* 2017;65:621–623.
- Petrelli M, Oikonomakis K, Andreanos K, Mouchtouris A, Georgalas I, Kymionis G. Surgical management of spontaneous, late-onset Descemet membrane detachment after penetrating keratoplasty for keratoconus: a case report. *Eye Vis (Lond).* 2017;4:14.
- Cressey A, Jacobs DS, Carrasquillo KG. Management of vascularized limbal keratitis with prosthetic replacement of the ocular surface system. *Eye Contact Lens.* 2012;38:137–140.
- Baran I, Bradley JA, Alipour F, Rosenthal P, Le HG, Jacobs DS. PROSE treatment of corneal ectasia. *Contact Lens Anterior Eye.* 2012;35:222–227.