

Intrathoracic extrapleural lung herniation: A new type of lung hernia

 Cihan Ozgur,  Fethi Emre Ustabasioglu,  Nermin Tuncbilek

Department of Radiology, Trakya University Faculty of Medicine, Edirne, Turkey

Cite this article as: Ozgur C, Ustabasioglu FE, Tuncbilek N. Intrathoracic extrapleural lung herniation: A new type of lung hernia. *North Clin Istanbul* 2021;8(3):306.

We describe the case of a 62-year-old man who presented with dyspnea and back pain, without any other accompanying symptoms. Contrast-enhanced thoracic computed tomography (CT) was performed and CT scan revealed saddle pulmonary embolism. Incidentally, a defect was found in the pleura near the posterobasal segment of the left lower lobe (Fig. 1). There was a subsegmental lung herniation through intrathoracic extrapleural space (Fig. 2). There were thickening and calcifications in the pleura adjacent to the defect. The patient did not have a history of surgery and trauma. He had a history of smoking.

Intercostal lung herniation was described in literature [1, 2]. However, to our knowledge, this is the second case which was detected incidentally by CT [3]. Management of a pulmonary hernia depends on symptoms, location, and size. Our case was followed up conservatively.

Informed Consent: Written informed consent was obtained from the patient for the publication of the case report and the accompanying images.

REFERENCES

1. Brock MV, Heitmiller RF. Spontaneous anterior thoracic lung hernias. *J Thorac Cardiovasc Surg* 2000;119:1046–7.
2. Weissberg D. Lung hernia - a review. *Adv Clin Exp Med* 2013;22:611–3.
3. Yuce I, Kantarci M, Ogul H, Sade R. Intrathoracic extrapleural lung herniation. *Eur J Cardiothorac Surg* 2016;49:1287.

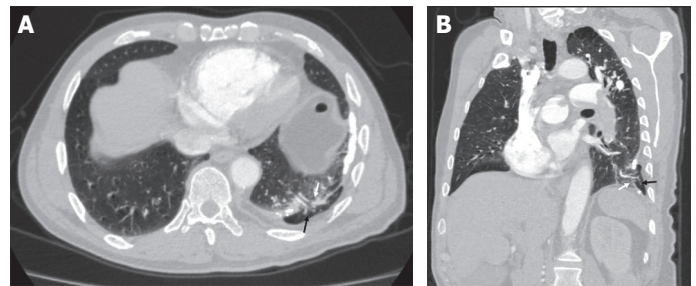


FIGURE 1. (A) Axial computed tomography (CT) and (B) oblique reformatted CT show herniated lung (black arrow), pleural defect (white arrow), pleural thickening, and calcification.

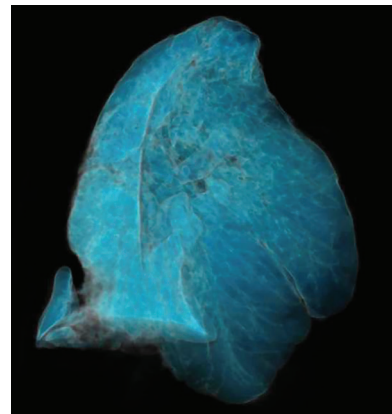


FIGURE 2. Three-dimensional computed tomography scan shows herniated lung.



Received: May 21, 2020 Accepted: June 18, 2020 Online: March 03, 2021

Correspondence: Cihan OZGUR, MD. Trakya Universitesi Tip Fakultesi, Radyoloji Anabilim Dalı, Edirne, Turkey.
Tel: +90 538 451 42 00 e-mail: cihanozguritf@gmail.com

© Copyright 2021 by Istanbul Provincial Directorate of Health - Available online at www.northclinist.com