



Corneal Effect of Air Bubble After Phacoemulsification

Ali Keles,¹ Suleyman Korhan Karaman²

¹Department of Ophthalmology, Faculty of Medicine, Bilecik Seyh Edebali University, Bilecik, Türkiye

²Department of Ophthalmology, University of Health Sciences Ankara Ulucanlar Eye Training and Research Hospital, Ankara, Türkiye

Abstract

Objectives: The aim of the study was to investigate the effect of air bubble on the cornea at the end of the cataract surgery with phacoemulsification.

Methods: This prospective and case-control study included 71 patients with air bubble injected into the anterior chamber at the end of the operation and 63 age-sex-matched control patients without air bubble. Endothelial cell density (ECD), coefficient of variation (CV), hexagonality rate (HEX), and central corneal thickness (CCT) measurements were taken using non-contact specular microscopy preoperatively and at 1-day, 1-week, and 1-month postoperatively.

Results: No significant difference was determined between the groups preoperatively in respect of mean visual acuity, anterior chamber depth, ECD, CV, HEX, and CCT values ($p>0.05$). The intraoperative average ultrasound power, effective phaco time, and ultrasound time values were similar ($p>0.05$). The CCT value was lower in the study group than in the control group on post-operative day 1 ($p=0.012$), but similar at 1 week and 1 month ($p=0.102$, $p=0.330$, respectively). No significant difference was determined between the groups in mean visual acuity, anterior chamber reaction, ECD, CV, and HEX values at 1-day, 1-week, and 1-month postoperatively ($p>0.05$).

Conclusion: Air bubble may be used as an alternative method to reduce corneal edema on the 1st post-operative day. According to the results, although air bubble has no detrimental effect, there is also seen to be no protective effect on the corneal endothelium.

Keywords: Air bubble, central corneal thickness, corneal endothelium, inflammation, phacoemulsification

Introduction

Phacoemulsification is a cataract surgery technique with a low complication rate, which increases visual acuity in the early period due to a small incision and working in a closed system (1). During this surgery, air bubble may be applied to the anterior chamber for various reasons. Air bubble is left in the anterior chamber at the end of surgery as a tamponade to prevent volume from shallowing (2). It has also been

demonstrated that air bubble tamponade for Descemet's membrane detachment after phacoemulsification surgery is effective in relieving corneal clarity with descemet membrane reattachment (3,4). The addition of air bubbles to the anterior chamber at the end of sutureless cataract surgery has been shown to prevent inflow of wound leakage and ocular surface fluid with the positive and negative pressures caused by external forces (5). In addition, air bubble in the anterior

How to cite this article: Keles A, Karaman SK. Corneal Effect of Air Bubble After Phacoemulsification. *Beyoglu Eye J* 2022; 7(4): 261-266.

Address for correspondence: Ali Keles, MD. Department of Ophthalmology, Faculty of Medicine, Bilecik Seyh Edebali University, Bilecik, Türkiye

Phone: +90 228 202 20 11 **E-mail:** alikeles06@gmail.com

Submitted Date: May 10, 2022 **Revised Date:** July 25, 2022 **Accepted Date:** September 01, 2022 **Available Online Date:** November 15, 2022

Beyoglu Eye Training and Research Hospital - Available online at www.beyoglueye.com

OPEN ACCESS This is an open access article under the CC BY-NC license (<http://creativecommons.org/licenses/by-nc/4.0/>).



chamber was considered to have protective effects against the development of experimental *Staphylococcus epidermidis* endophthalmitis by possible mechanisms other than the prevention of reflux. Possible mechanisms may be the bacteriostatic, anti-inflammatory effect of the air, and stimulation of antibody- and cytokine-mediated defense by increasing the antigen concentration near the vascularized iris tissue (6).

Anterior segment fluorophotometry has shown that cataract surgery can cause breakdown of the blood-aqueous barrier with protein leakage and cell reaction in the aqueous humor (7). In a rabbit eye study, air bubble remaining in the anterior chamber after phacoemulsification was found to decrease the anterior chamber reaction (ACR) and nitric oxide level, thus reducing inflammation (8).

The aim of this study was to evaluate the effects of the air bubble on the corneal endothelium.

Methods

This prospective and case-control study was conducted on adult patients undergoing cataract surgery in an eye clinic of tertiary referral hospital. Written informed consent was obtained from all patients. The study was approved for prospective data collection by the Local Ethics Committee (Health Sciences University Ankara Numune Training and Research Hospital, number: E-17-1453, date: 12.07.2017) and followed the tenets of the Declaration of Helsinki. All patients were of Caucasian origin.

Demographic Data

A record was made for each patient of the pre-operative findings of age, sex, systemic disease, routine ophthalmology examination findings (visual acuity measurement, biomicroscopic examination, fundus examination, and intraocular pressure measurement), anterior chamber depth (ACD-measured with optical low coherence reflectometry-LenStar LS 900, Haag-Streit AG, Switzerland), and specular microscopy measurements. Cataract hardness was assessed with the Lens Opacity Classification System III (9).

Exclusion criteria included prior history of corneal opacities, glaucoma, uveitis, preoperative endothelial cell count <1500 cells/mm², pre-operative ACD <2.5 mm, degenerative myopia, proliferative diabetic retinopathy, intraocular surgery, eye trauma, intraoperative complication (zonular dialysis, posterior capsular opening, vitreous loss, nucleus drop, etc.), and systemic autoimmune inflammatory disease.

Surgical Technique

All eyes were dilated using topical cyclopentolate hydrochloride 1% (Sikloplejin®) and tropicamide 1% (Tropamid®). After topical anesthesia (Proparacain HCl 0.5%), two-side

ports were opened and anterior chamber stabilization was achieved with injected viscoelastic material (Healon GV®, AMO) and the anterior chamber was entered with a transparent 2.75 mm corneal incision by the same surgeon (SKK) in all cases. Following capsulorhexis with a diameter of approximately 5.5 mm, the nucleus was emulsified with bimanual phaco chop and divide conquer techniques. After cortex cleaning, a foldable hydrophobic acrylic intraocular lens (Acrysof SA60AT®, Alcon) was implanted into the capsular bag. After viscoelastic clearance in the anterior chamber, 0.5%/0.1 mL moxifloxacin (Vigamox®) was injected into the anterior chamber following stromal hydration with no sutures. At the end of the operation, 0.15 cc air bubble was administered to the anterior chamber in patients of the study group and was not applied to the patients in the control group. After surgery, ofloxacin drops (Exocin® 5 × 1) and prednisolone acetate (Predforte® 4 × 1) were used for 4 weeks.

Average ultrasound power (AVG, %), effective phaco time using Ellips™ FX (EFX, seconds), and ultrasound time (UST, seconds) values of the phacoemulsification performed during the operation were noted using the AMO White-Star Signature® Ellips™ FX phaco system for all patients. The EFX is roughly the effective phaco time with a specific coefficient for the transversal movement expressed in seconds. Endothelial cell loss (ECL) was evaluated as follows: $ECL = \frac{[\text{pre-operative cell count} - \text{post-operative cell count}]}{\text{pre-operative cell count}} \times 100\%$.

Main Outcome Measures

The cases were evaluated postoperatively on day 1, then at the end of the 1st week, and the 1st month with a slit lamp biomicroscope (Topcon SL-3G, Japan) for ACR and the amount of air bubble in the anterior chamber. The corrected distance visual acuity (CDVA) was examined on decimal charts preoperatively and on the 1st-day, 1st-week, and 1st-month postoperatively. Decimal visual acuity was converted to the logarithm of the minimum angle of resolution for statistical analysis.

Endothelial cell density (ECD, cell/mm²), the coefficient of variation (CV, polymegatism, %), hexagonality rate (HEX, pleomorphism, %), and central corneal thickness (CCT, μm) were investigated using a reproducible and reliable non-contact specular microscopy (Tomey EM-4000, Tomey Corp., Nagoya, Japan) preoperatively and day 1, week 1, and month 1 postoperatively (10). All measurements were performed at least 3 times using the "center" method by the same clinician. Subjects were asked to look at the central fixation target, and the automatic alignment function was used. All corneal endothelial cells were manually marked. More than 60 cells per eye were included in each assay.

Statistical Analysis

Data obtained in the study were analyzed statistically using SPSS version 22.0 software (Chicago, IL, USA). Descriptive statistics were stated as mean±standard deviation values. The normal distribution of the variables was tested using visual (histogram and probability graphs) and analytical methods (Kolmogorov–Smirnov/Shapiro–Wilk test). The pre-operative, intraoperative, and post-operative measurements of two groups were compared using the Independent Samples t-test. Categorical variables were compared using the Chi-square test. $P < 0.05$ was considered statistically significant.

Results

Patients who underwent cataract surgery by phacoemulsification were separated into two groups. In the study group of 71 patients, air bubble was applied to the anterior chamber at the end of the operation, and in the control group of 63 patients, no air bubble was applied. None of the patients had any complications related to air injection, such as pupillary block glaucoma or escape of air behind the iris. Air bubble was completely reabsorbed on post-operative day 4 or 5. Figures 1a-d demonstrate the resorption of the air bubble given at the end of surgery within days (Haag-Streit BQ 900 imaging, Koeniz, Switzerland).

The demographic and pre-operative clinical features of participants according to groups and intraoperative parameters are presented in Table 1. The mean age was 65.90 ± 11.05 years in the study group and 65.02 ± 10.38 years in the control group ($p = 0.635$). The male to female ratio was similar in both groups ($p = 0.672$). The best corrected visual acuity on Snellen chart, mean ACD value and cataract hardness of the two groups were similar ($p > 0.05$). No statistically significant difference was found between the two groups in respect of the preoperative ECD, CV, HEX, and CCT values ($p > 0.05$). There was no significant difference between the groups in terms of AVG, EFX, and UST values ($p > 0.05$), (Table 1).

On post-operative day 1, seven patients in the study group (9.8%) and seven patients in the control group (11.1%) could not be measured due to corneal edema ($p > 0.05$). The mean CCT value on post-operative day 1 was lower in the study group compared to the control group ($p = 0.012$), but the mean CCT values were similar at the end of the post-operative 1st week and 1st month ($p = 0.102$, $p = 0.330$, respectively). There was no significant difference between the groups in respect of mean CDVA, ACR, ECD, CV, and HEX values at postoperative day 1, week 1, and month 1 ($p > 0.05$ for all, Table 2).

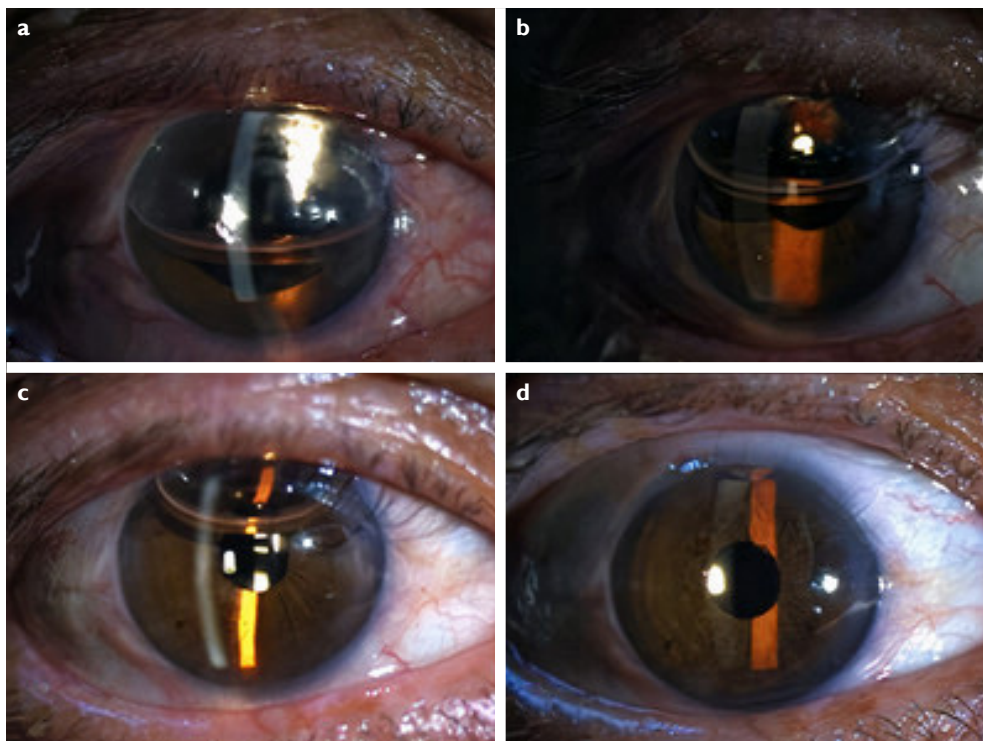


Figure 1. Images of the right eye of a patient with air bubble given at the end of surgery (a). One hour after surgery (b). One day after surgery (c). Two days after surgery (d). On postoperative day 5, the air bubble was completely reabsorbed.

Table 1. Comparison of Patients' Preoperative Characteristics and Intraoperative Parameters

	Air bubble (n=71) (Mean±SD)	No air bubble (n=63) (Mean±SD)	p
Age, years	65.90±11.05	65.02±10.38	0.635
Gender (Male/Female)	46/25	43/20	0.672
Preop CDVA (logMAR)	1.02±0.69	0.97±0.64	0.655
ACD (mm)	3.42±0.40	3.40±0.35	0.769
Cataract Hardness	2.77±0.81	2.70±0.85	0.598
Preop ECD (cell/mm ²)	2427.01±319.05	2453.24±278.52	0.615
Preop CV (%)	40.46±5.12	40.94±7.38	0.665
Preop HEX (%)	44.92±6.80	44.32±5.98	0.592
Preop CCT (µm)	526.08±31.69	532.54±35.29	0.267
AVG (%)	6.41±3.22	6.65±4.47	0.717
EFX (s)	37.15±25.61	30.10±23.18	0.098
UST (s)	99.77±56.96	88.75±56.17	0.262

CDVA: Corrected distance visual acuity; logMAR: logarithm of the minimum angle of resolution; ACD: Anterior chamber depth; ECD: Endothelial cell density; CV: Coefficient of variation; HEX: Hexagonality rate; CCT: Central corneal thickness; AVG: Average ultrasound power; EFX: Effective phaco time; UST: Ultrasound time.

Table 2. Comparison of Postoperative Parameters Between Groups

	Air bubble (n=71) (Mean±SD)	No air bubble (n=63) (Mean±SD)	p
Postop 1.day CDVA (logMAR)	0.17±0.17	0.25±0.32	0.054
Postop 1.day ACR	0.85±0.53	0.84±0.65	0.970
Postop 1.day ECD (cell/mm ²)	2129.14±420.80	2196.79±388.75	0.365
Postop 1.day CV (%)	46.42±10.28	44.86±9.33	0.387
Postop 1.day HEX (%)	38.28±8.17	39.82±8.44	0.313
Postop 1.day CCT (µm)	555.64±37.97	577.44±55.30	0.012
Postop 1.day Misalignment (+/-)	7/64	7/56	0.813
Postop 7.day CDVA (logMAR)	0.09±0.14	0.12±0.25	0.398
Postop 7.day ACR	0.11±0.32	0.13±0.34	0.801
Postop 7.day ECD (cell/mm ²)	2094.03±441.96	2136.90±468.27	0.587
Postop 7.day CV (%)	43.99±5.85	44.19±6.90	0.853
Postop 7.day HEX (%)	37.0±7.04	39.17±6.12	0.060
Postop 7.day CCT (µm)	542.69±41.53	555.98±51.82	0.102
Postop 30.day CDVA (logMAR)	0.04±0.06	0.04±0.12	0.813
Postop 30.day ACR	0±0	0±0	-
Postop 30.day ECD (cell/mm ²)	2073.25±429.72	2093.94±460.57	0.788
Postop 30.day CV (%)	42.06±5.54	43.95±6.59	0.073
Postop 30.day HEX (%)	38.69±6.08	39.54±6.23	0.426
Postop 30.day CCT (µm)	527.53±33.98	533.21±33.02	0.330
ECL (%) 1 st day	12.65±13.73	11.11±12.71	0.526
ECL (%) 1 st week	13.54±14.75	13.11±15.34	0.867
ECL (%) 1 st month	14.51±13.72	14.89±14.92	0.878

CDVA: Corrected distance visual acuity; logMAR: logarithm of the minimum angle of resolution; ACR: Anterior chamber reaction; ECD: Endothelial cell density; CV: Coefficient of variation; HEX: Hexagonality rate; CCT: Central corneal thickness; ECL: Endothelial cell loss.

Discussion

The corneal endothelium is a mechanical barrier against fluid movement into the cornea and is an energy-dependent active pump to move fluid out of the cornea. The endothelium plays a critical role in maintaining corneal transparency by pumping fluid from the stroma into the aqueous humor. Disruption of the endothelial function brings about stromal swelling and corneal edema (11,12). Corneal endothelial cells cannot regenerate, yet stretch to compensate for dead cells that decline the overall cell density of the endothelium and ultimately fluid regulation is affected. Therefore, to compensate for corneal damage, other healthy corneal cells migrate to the damaged area, which results in a reduction in their hexagonality (13,14). In the present study, the effects on corneal endothelial count and morphology were examined of air bubble applied to the anterior chamber at the end of the phacoemulsification.

Olson (15) and Van Horn et al. (16) reported that air bubble has a toxic effect on the corneal endothelium. However, Norn (17) applied air bubble to the anterior chamber in 86 of 135 patients who underwent cataract extraction, and concluded that air bubbles in the anterior chamber did not have any adverse effects on the corneal endothelium, as well as protected the endothelium from post-operative damage. Yuksel et al. (18) showed that the rate of Descemet's membrane detachment and of endothelial and epithelial gap decreased during the early post-operative period in patients who had been given with air bubble after phacoemulsification surgery compared to the control group. The ECD of the two groups was found to be similar preoperatively and at 3-month post-operatively (18). Likewise, Alsmman et al. (19) studied air bubble versus balanced salt solution for anterior chamber reformation at the end of phacoemulsification and found similar endothelial cell count-morphology in both groups at 1- and 3-month follow-up visits. In contrast, Mataftsi et al. (20) compared intrastromal wound hydration with anterior chamber air tamponade to ensure waterproof closure of corneal incisions at the end of the phacoemulsification surgery and reported that air has a detrimental effect on endothelial cell count compared to balanced salt solution. In that study with an average age of patient age of 70 years, compared to a former study of patients aged 50–60 years, they interpreted that younger corneas may have a greater tolerance to the toxic effect of air on endothelial cells, and thus a lesser effect on the final number and density (20). In the present study, in which the mean age of the patients was approximately 67 years, there was no difference according to the specular microscopy analysis at the 1-month follow-up examination.

On the post-operative 1st day, air bubble seemed to have no favorable influence on anterior chamber reaction, sug-

gesting that air bubble is not clinically related to inflammation. A limitation of this study was that the quantitative ACR and flare values could not be measured due to the lack of anterior segment fluorophotometry.

Corneal edema formation has been used as an indirect tool to assess surgically induced ECL (21). In the previous studies, corneal endothelial loss was found to be correlated with increase in CCT on the 1st post-operative day (22). A significantly less increase was observed in CCT data on the post-operative 1st day in the study group applied with air bubble compared to the control group. However, endothelial loss was similar between groups. The lesser increase in pachymetry in the study group is not explained by endothelial loss. There was a significant difference in CCT at 1 day, but similar at 1 week and 1 month, suggesting that this situation is related to the air bubble left in the anterior chamber. Because the effect of the air bubble is maximum on the 1st day and it is completely resorbed within 1 week. Less increase in pachymetry in the study group may be associated with one or both of the following mechanisms as possible cause: First, reduced fluid passage into the stroma due to better endothelial pump function due to the relatively anti-inflammatory environment provided by the air bubble. Second, the reduction of fluid passage into the corneal stroma by the mechanical barrier effect of the air bubble.

Conclusion

There may be less corneal edema on the post-operative 1st day of cases terminated by leaving air bubble in surgery. This procedure can be considered as an inexpensive and easy alternative method increasing patient satisfaction from the post-operative 1st day. As there was no significant difference between ECD and other parameters in the 1-month follow-up results, it was concluded that air bubbles in the anterior chamber have not any side-effects on the corneal endothelium, on the other hand, there is no clinically protective effect against surgery-induced endothelial injury by reducing inflammation sufficiently. There is a need for further comprehensive studies with large patient populations subdivided by air resorption time to determine the exact effect of air bubble.

Disclosures

Ethics Committee Approval: Health Sciences University Ankara Numune Training and Research Hospital (Number: E-17-1453, Date: 12.07.2017).

Peer-review: Externally peer-reviewed.

Conflict of Interest: None declared.

Authorship Contributions: Concept – A.K., S.K.K.; Design – A.K., S.K.K.; Supervision – A.K., S.K.K.; Materials – A.K., S.K.K.; Data collection and/or processing – A.K., S.K.K.; Analysis and/or interpretation – A.K., S.K.K.; Literature search – A.K., S.K.K.; Writing – A.K., S.K.K.; Critical review – A.K., S.K.K.

References

1. de Silva SR, Riaz Y, Evans JR. Phacoemulsification with posterior chamber intraocular lens versus extracapsular cataract extraction (ECCE) with posterior chamber intraocular lens for age-related cataract. *Cochrane Database Syst Rev* 2014;29:CD008812.
2. Samsudin A, Eames I, Brocchini S, Khaw PT. The effect of an air bubble in the anterior chamber on the change in intraocular pressure (IOP). *Ophthalmol Res An Int J* 2014;2:406–17.
3. Ti SE, Chee SP, Tan DT, Yang YN, Shuang SL. Descemet membrane detachment after phacoemulsification surgery: Risk factors and success of air bubble tamponade. *Cornea* 2013;32:454–9.
4. Samarawickrama C, Beltz J, Chan E. Descemet's membrane detachments post cataract surgery: A management paradigm. *Int J Ophthalmol* 2016;9:1839–42.
5. Sim DA, Wong R, Griffiths MF. Injecting an air bubble at the end of sutureless cataract surgery to prevent inflow of ocular surface fluid. *Eye (Lond)* 2007;21:1444–5.
6. Mehdizadeh M, Rahat F, Khalili MR, Ahmadi F. Effect of anterior chamber air bubble on prevention of experimental *Staphylococcus epidermidis* endophthalmitis. *Graefes Arch Clin Exp Ophthalmol* 2010;248:277–81.
7. Ferguson VM, Spalton DJ. Continued breakdown of the blood aqueous barrier following cataract surgery. *Br J Ophthalmol* 1992;76:453–6.
8. Demirci G, Karabas L, Maral H, Ozdek S, Güllikil G. Effect of air bubble on inflammation after cataract surgery in rabbit eyes. *Indian J Ophthalmol* 2013;61:343–8.
9. Chylack LT Jr., Wolfe JK, Singer DM, Leske MC, Bullimore MA, Bailey IL, et al. The lens opacities classification System III. The longitudinal study of cataract study group. *Arch Ophthalmol* 1993;111:831–6.
10. McCarey BE, Edelhauser HF, Lynn MJ. Review of corneal endothelial specular microscopy for FDA clinical trials of refractive procedures, surgical devices and new intraocular drugs and solutions. *Cornea* 2008;27:1–16.
11. Edelhauser HF. The balance between corneal transparency and edema: The proctor lecture. *Invest Ophthalmol Vis Sci* 2006;47(5):1754–67.
12. Bourne WM. Corneal endothelium--past, present, and future. *Eye Contact Lens* 2010;36:310–4.
13. Aribaba OT, Adenekan OA, Onakoya AO, Rotimi-Samuel A, Olatosi JO, Musa KO, et al. Central corneal thickness changes following manual small incision cataract surgery. *Clin Ophthalmol* 2015;9:151–5.
14. Tekin K, Sekeroglu MA, Kiziltoprak H, Yilmazbas P. Corneal densitometry in healthy corneas and its correlation with endothelial morphometry. *Cornea* 2017;36:1336–42.
15. Olson RJ. Air and the corneal endothelium: An in vivo specular microscopy study in cats. *Arch Ophthalmol* 1980;98:1283–4.
16. van Horn DL, Edelhauser HF, Aaberg TM, Pederson HJ. In vivo effects of air and sulfur hexafluoride gas on rabbit corneal endothelium. *Invest Ophthalmol* 1972;11:1028–36.
17. Norn MS. Corneal thickness after cataract extraction with air in the anterior chamber. *Acta Ophthalmol (Copenh)* 1975;53:747–50.
18. Yuksel E, Cubuk MO, Ceylanoglu KS. Intracameral air injection after completion of phacoemulsification cataract surgery: Evaluation of corneal incisions with optical coherence tomography. *J Curr Ophthalmol* 2019;31:142–9.
19. Alsmman AH, Ezzeldawla M, Mounir A, Elhawary AM, Mohamed OA, Farouk M, et al. Effect of reformation of the anterior chamber by air or by a balanced salt solution (BSS) on corneal endothelium after phacoemulsification : A comparative study. *J Ophthalmol* 2018;2018:6390706.
20. Mataftsi A, Dermenoudi M, Matsou A, Tzamalidis A, Brazitikos P, Talimtzis P, et al. Safety of air tamponade versus corneal hydration for sealing clear corneal incisions in cataract surgery. *Graefes Arch Clin Exp Ophthalmol* 2020;258:815–20.
21. Assaf A, Roshdy MM. Comparative analysis of corneal morphological changes after transversal and torsional phacoemulsification through 2.2 mm corneal incision. *Clin Ophthalmol* 2013;7:55–61.
22. Lundberg B, Jonsson M, Behndig A. Postoperative corneal swelling correlates strongly to corneal endothelial cell loss after phacoemulsification cataract surgery. *Am J Ophthalmol* 2005;139:1035–41.