

# Elective implantable cardioverter-defibrillator removal with extraction of leads following catheter ablation of idiopathic ventricular fibrillation and long-term surveillance



Norman C. Wang, MD, MS, FHRS, Sandeep K. Jain, MD, FHRS, Samir Saba, MD, FHRS

*From the Heart and Vascular Institute, University of Pittsburgh Medical Center, Pittsburgh, Pennsylvania.*

## Introduction

Ventricular fibrillation (VF) triggered by premature ventricular complexes (PVCs) is a syndrome within the category of idiopathic VF. Catheter ablation of triggering PVCs, first reported in 2002, may prevent recurrent episodes of VF.<sup>1–3</sup> Implantable cardioverter-defibrillators (ICDs) are recommended in the current American guideline owing to the possibility of arrhythmia recurrence, yet the evidence cited was a single study of 38 patients.<sup>3,4</sup> Long-term absence from significant arrhythmias is not a recognized indication for elective ICD removal with extraction of leads.<sup>5</sup> We report a case of elective ICD removal with extraction of leads in a young woman who underwent catheter ablation of PVC-triggered idiopathic VF following long-term surveillance. To the best of our knowledge, this is the first reported case of this management strategy and serves as proof of concept.

## Case report

In July 2011, a 21-year-old woman of white race/ethnicity with a history of PVCs, but no other medical history, presented to the emergency department for 2 “seizures” that lasted approximately 4 minutes. The first episode occurred the day prior. She had completed a 2-mile run and was seated at a table for breakfast. Witnesses stated that she stood up, felt dizzy, lost consciousness, fell to the floor, and hit her head as she was falling. She had been having lightheadedness without syncope for 1 month.

**KEYWORDS** Catheter ablation; Implantable cardioverter-defibrillator; Lead extraction; Premature ventricular complex; Purkinje; Ventricular fibrillation (Heart Rhythm Case Reports 2020;6:464–468)

**Funding Source:** This manuscript did not receive any specific grant(s) from funding agencies in the public, commercial, or not-for-profit sectors. **Disclosures:** Dr Wang serves as a consultant for Abbott. Dr Jain serves as a consultant for Medtronic; receives research support from Medtronic; and is a research investigator for Abbott, Boston Scientific, and Medtronic. Dr Saba receives research support from Boston Scientific and Medtronic. **Address reprint requests and correspondence:** Dr Norman C. Wang, Heart and Vascular Institute, University of Pittsburgh Medical Center, 200 Lothrop Street, South Tower, 3rd Floor, Room E352.9, Pittsburgh, PA 15213. E-mail address: [wangnc@upmc.edu](mailto:wangnc@upmc.edu).

## KEY TEACHING POINTS

- Catheter ablation of premature ventricular complex-triggered idiopathic ventricular fibrillation may be highly successful in preventing future episodes. However, the current guideline for the management of patients with ventricular arrhythmias and the prevention of sudden death from American Heart Association, American College of Cardiology, and Heart Rhythm Society recommends lifelong treatment with an implantable cardioverter-defibrillator (ICD).
- Not enough data are published to confidently predict if patients who exhibit excellent response to catheter ablation may be considered truly “cured.” Yet, long-term use of ICDs is associated with potentially serious morbidity and mortality. Extraction of leads with long dwell time, particularly >10 years, is associated with a mortality rate of at least 1%–2%.
- An alternative to the Hobson’s choice or “take it or leave it” approach that is common for ICD recommendations is long-term surveillance and ICD removal with extraction of leads after several years of documenting arrhythmia suppression. This strategy may be particularly relevant for young patients. It may be presented as a third option during shared decision-making.

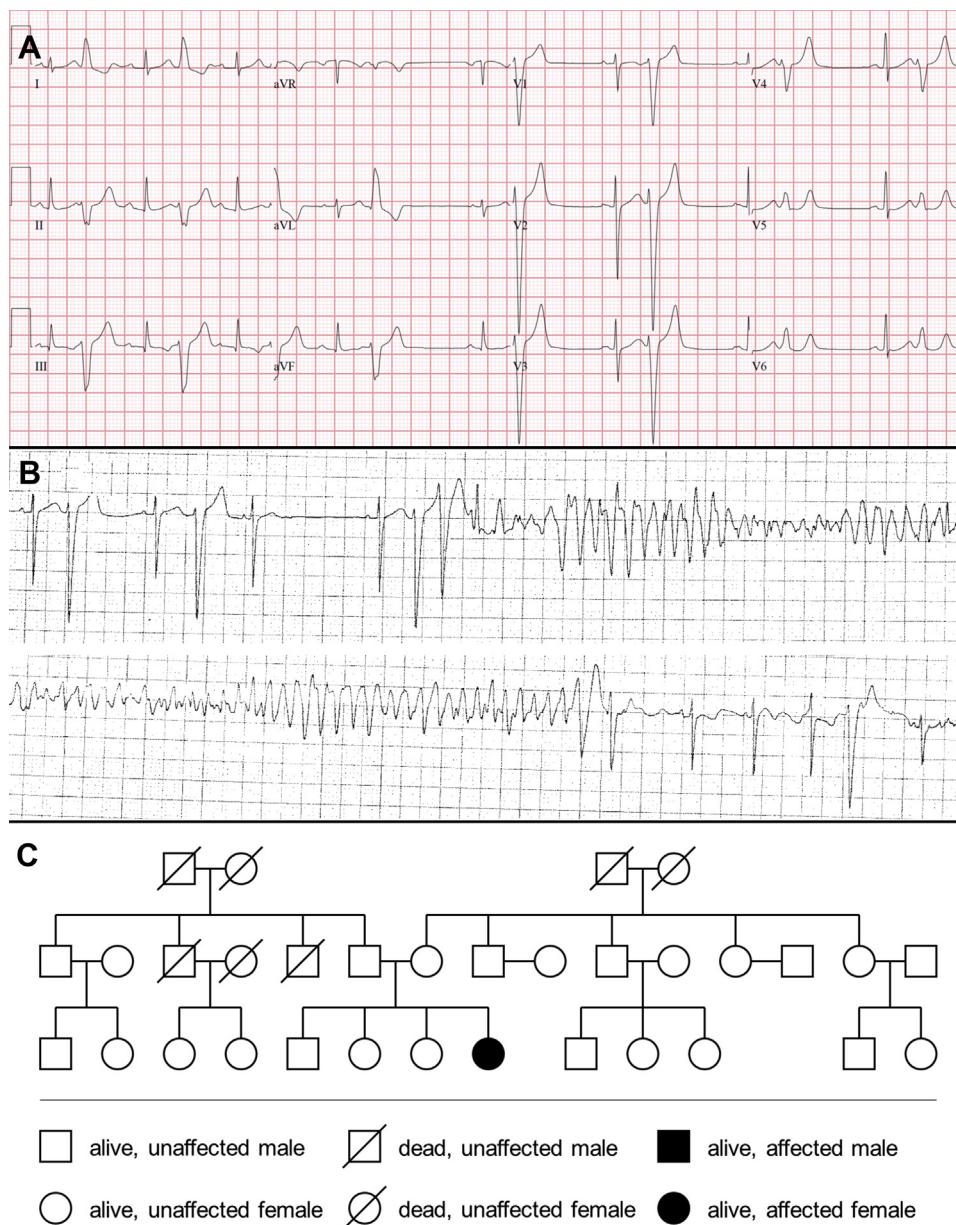
The second episode, which led to the hospital visit, occurred while she was a passenger in a motor vehicle that was being driven by her mother. She had lightheadedness and then syncope as she was about to step out of the car. It was described that she extended her arms, repeatedly bent forward as if she was doing sit-ups, turned gray, and then awoke. She neither bit her tongue nor had urinary

incontinence. Her only medication was an oral contraceptive. She drank alcohol on a social basis and denied tobacco and illicit drug use.

A neurological evaluation with computed tomography and magnetic resonance imaging of her head were unremarkable. An electrocardiogram (ECG) demonstrated sinus rhythm with frequent PVCs (Figure 1A). The PVCs were characterized by left bundle branch block morphology, left superior axis, late precordial transition ( $>V_4$ ), QRS duration of 138 ms, and intrinsicoid deflection of  $<100$  ms in the precordial leads. An echocardiogram was normal. She exercised for 15 minutes on the Bruce protocol of a treadmill stress test and achieved 90% of her maximum predicted heart rate; there

were isolated PVCs during exercise and recovery. While in her hospital room, she had an episode of syncope owing to VF, triggered by a PVC with a coupling interval of 350 ms, that lasted 22 seconds before spontaneously terminating (Figure 1B). Coronary angiography was normal. Cardiac magnetic resonance imaging was normal, with a left ventricular ejection fraction of 68% and no areas of late gadolinium enhancement. There was no family history of sudden death or ventricular arrhythmias (Figure 1C). She did not have Dutch ancestry.

Electrophysiology study was recommended, as isolated PVCs and those that triggered VF were of the same morphology. Electroanatomic mapping was performed using



**Figure 1** A: Twelve-lead electrocardiogram with sinus arrhythmia and premature ventricular complexes in a pattern of bigeminy. B: Telemetry with initiation of ventricular fibrillation following a premature ventricular complex with a coupling interval of 350 ms. The episode terminated after 22 seconds. C: The patient was the only affected individual on her 3-generation pedigree.

a 4-mm-tip NAVISTAR radiofrequency ablation catheter with the CARTO XP system (Biosense Webster, Diamond Bar, CA). Administration of conscious sedation resulted in complete PVC suppression. The endocardial voltage was normal. Isoproterenol was titrated to 2  $\mu\text{g}/\text{min}$ , at which point the clinical PVC was induced. Activation mapping localized the site of origin to the mid-inferolateral right ventricle with a local activation time from a Purkinje potential to the onset of the surface QRS that was 30 ms (Figure 2A). Pace mapping yielded a similar match (Figure 2B). Continued mapping on the area of earliest activation resulted in suppression of the PVCs. Isoproterenol was stopped to facilitate catheter stability. Nine ablation lesions of 60 seconds duration were delivered in a temperature-controlled mode with a target temperature of 55°C at a power of 30–50 W (Figure 3A and B). Lesions were extended to an area of approximately 1 cm<sup>2</sup> around the site of origin. Following ablation, isoproterenol was restarted and titrated up to 5  $\mu\text{g}/\text{min}$ , which achieved a heart rate of 130 beats per minute (bpm). No further ventricular ectopy was observed. Programmed stimulation from the right atrium and the right ventricle did not induce any arrhythmias. A dual-chamber ICD was placed. Her postablation ECG demonstrated a QRS duration of 76 ms without change in morphology (Figure 3C). She was discharged on no cardiac medications.

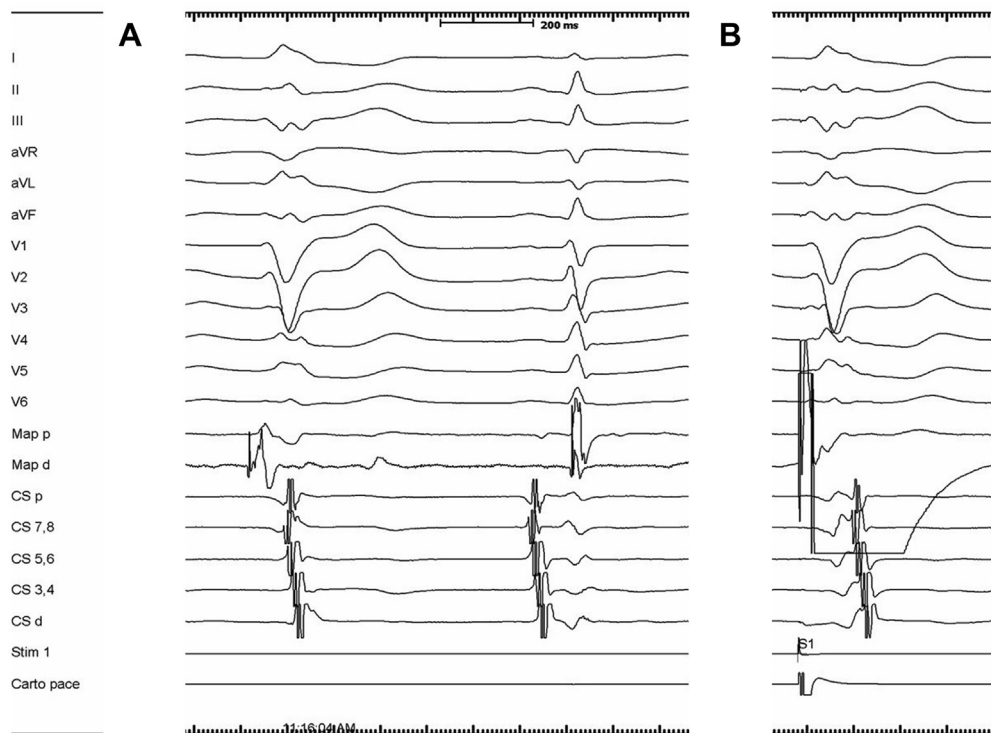
Genetic testing with a catecholaminergic polymorphic ventricular tachycardia panel (GeneDx, Gaithersburg, MD), sent during her hospitalization, revealed no significant disease-causing mutations detected in *RYR2*, *CASQ2*, and

*KCNJ2* genes. She was heterozygous for Ala886Ser in the *RYR2* gene, which was described as a novel variant of unknown significance. This revealed “a non-conservative amino acid substitution of a non-polar Alanine residue with a polar Serine residue at a position that is highly conserved throughout evolution.”

One month after ablation, she exercised for 13 minutes on the Bruce protocol of a treadmill stress test and achieved 95% of her maximum predicted heart rate. There were no PVCs or other arrhythmias during rest, exercise, or recovery. Thirteen months post ablation, she received 2 inappropriate ICD shocks for sinus tachycardia while playing soccer. The treatment threshold was increased from 187 bpm to 200 bpm.

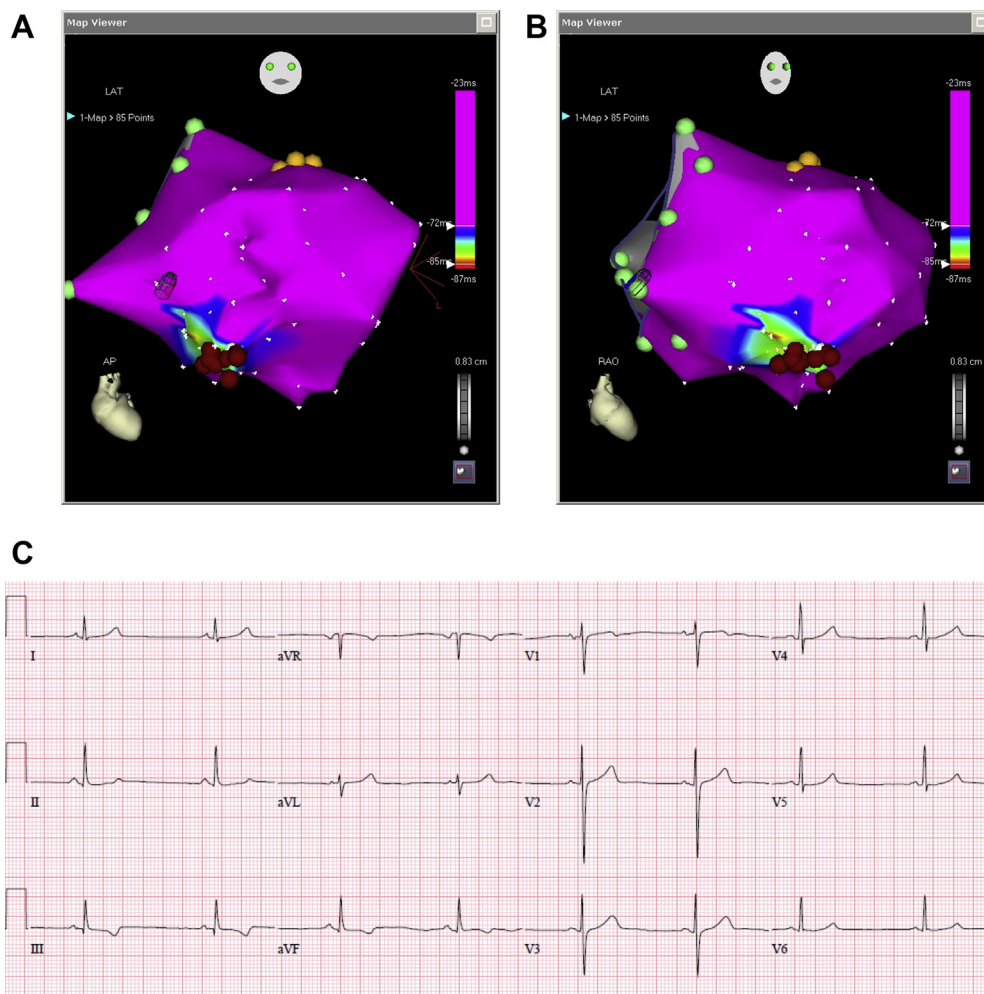
As part of routine surveillance, she had postablation 24-hour Holter monitors that yielded the following PVC burdens: 0 (0.0%) at 1.2 years, 2 (0.0%) at 2.1 years, 127 (0.1%) at 3.2 years with at least 3 PVC morphologies, and 11 (0.0%) at 4.5 years. All PVCs were isolated. An echocardiogram 4.5 years after ablation was normal. ICD interrogations during regularly scheduled routine follow-up demonstrated total absence of nonsustained and sustained ventricular arrhythmia episodes.

The benefits and risks of continued ICD use vs ICD removal with extraction of leads were discussed at routine follow-up clinic visits, where she was often accompanied by her mother. In February 2016, 4.8 years after ablation, she underwent successful ICD removal with extraction of leads using a laser sheath (Spectranetics, Colorado Springs,



**Figure 2** Characteristics at the site of successful ablation. **A:** Best activation map. A Purkinje potential is 30 ms before the QRS complex of the premature ventricular complex on the distal electrode of the map catheter (Map d). A Purkinje potential, fused to the ventricular electrogram, is also present in sinus rhythm. **B:** Best pace map.





**Figure 3** A, B: CARTO XP (Biosense Webster, Diamond Bar, CA) electroanatomic activation maps (A: anterior-posterior projection; B: right anterior oblique projection) with location points for the His bundle (yellow), tricuspid valve annulus (light green), and radiofrequency ablation lesions (red). C: Twelve-lead electrocardiogram 1 day after ablation with sinus rhythm and a QRS duration of 76 ms.

CO). In total, she had 11 outpatient visits with her cardiac electrophysiologist (N.C.W.) between ablation and ICD removal.

She continued to undergo 24-hour Holter monitoring with the following PVC burdens: 0 (0.0%) at 4.9 years and 0 (0.0%) at 6.0 years. An echocardiogram performed 6.9 years post ablation demonstrated normal right and left ventricular size and function with mild tricuspid regurgitation. She continues to do well, 8.9 years after her initial presentation.

## Discussion

We report a case of PVC-triggered idiopathic VF where successful ablation of PVCs emanating from the right ventricular Purkinje system allowed for ICD removal with extraction of leads after long-term surveillance. Based on the 12-lead ECG and the electroanatomic map, the PVC source was likely an anterior papillary muscle, a posterior papillary muscle, or the free wall insertion of the moderator band.<sup>6-8</sup> Intracardiac echocardiography (ICE), not performed in our case, may differentiate these structures.

To the best of our knowledge, there are only 2 series characterizing idiopathic ventricular arrhythmias from the right ventricular papillary muscles where ICE confirmed the anatomic source.<sup>6,7</sup> The studies described 16 patients (8 in each). Neither reported a patient with PVC-triggered VF despite screening a total of 324 patients with ventricular arrhythmias. Purkinje potentials at the site of ablation were described in sinus rhythm, but not preceding PVCs. In contrast, 7 of 10 patients in a series of ICE-confirmed right ventricular moderator band arrhythmias presented with PVC-triggered VF.<sup>8</sup> Five of the 7 patients with PVC-triggered VF had Purkinje potentials that preceded the PVCs. Therefore, we believe the source of PVCs in our patient was most likely the free wall insertion of the right ventricular moderator band.

Broad genetic screening for inherited arrhythmia syndromes in patients with idiopathic VF is not currently recommended.<sup>9</sup> Overexpression of dipeptidyl peptidase-like protein 6 (*DPP6*) has been reported to cause a familial form of PVC-triggered idiopathic VF in 5 Dutch patients with PVC morphologies that were similar to our patient.<sup>10</sup>

PVCs were short-coupled, with triggering coupling intervals from 200 to 280 ms. Our patient had a long coupling interval for VF initiation at 350 ms. A case of idiopathic VF triggered by moderator band PVCs that was associated with a mutation to the *ANK2* gene, which encodes ankyrin-B, was reported from Japan.<sup>11</sup>

The pathophysiology of Purkinje cell PVC-triggered idiopathic VF is not fully understood. Therefore, acutely successful ablation of monomorphic PVCs that trigger idiopathic VF is not a guarantee that PVCs will not arise later from other parts of the Purkinje system. The mechanism by which ablation achieves arrhythmia suppression, trigger elimination, and/or substrate modification is also unknown. Ablation is guided by activation mapping, pace mapping, and Purkinje potential mapping.<sup>1–3,6–8</sup> Experienced centers have described extending the ablation field to approximately 1 cm<sup>2</sup> around the putative site of origin.<sup>3</sup> However, a refractory case of idiopathic VF triggered by PVCs from the right ventricular moderator band ultimately required ablation of the right bundle.<sup>8</sup> Currently, there is not enough published in the literature to determine which patients, if any, can truly be considered “cured.”

Yet, a lifelong commitment to an ICD may also be associated with serious morbidity and mortality. These include subsequent procedures for generator changes at battery depletion (and associated infection risk), risk of inappropriate shocks, and possible generator and lead recalls. A review of how ICDs may uniquely impact young patients has been published.<sup>12</sup> Leads with long dwell times are associated with lead failure, vascular occlusion, and increased periprocedural risk should subsequent lead extraction be required.<sup>13</sup> Extraction of leads with fibrous adhesions and >10-year dwell times has an estimated mortality of at least 1%–2%.<sup>12,13</sup> White women in the United States have a life expectancy of over 80 years. For our patient, a lifelong commitment to an ICD would mean the possibility of 6 decades or more of an indwelling device.

Shared decision-making<sup>14</sup> regarding the potential benefits and risks of elective ICD removal with extraction of leads, emphasizing the paucity of data, is of paramount importance. Discussions regarding ICD recommendations most often take the framework of Hobson’s choice, or “take it or leave it.”<sup>12</sup> The strategy we present offers a third, intermediate alternative. A wearable cardioverter-defibrillator may be a fourth alternative.

For patients for whom our strategy may be considered a reasonable option, we suggest annual Holter monitoring to assess PVC burdens. Discontinuation of antiarrhythmics

during the surveillance period is mandatory. Extraction of leads within 5 years after implantation would reduce procedural risk as longer dwell times are associated with more fibrosis between the interface of leads and adjacent tissues.<sup>13</sup>

## Conclusion

To the best of our knowledge, this is the first report of elective ICD removal with extraction of leads in a patient who underwent successful catheter ablation of idiopathic VF triggered by PVCs from the right ventricular Purkinje system following long-term surveillance. We believe this serves as proof of concept. If confirmed in prospective studies, it may lead to a paradigm shift away from the lifelong recommendation for ICDs when favorable responses are demonstrated. This may be particularly attractive to consider for young patients.

## References

1. Haïssaguerre M, Shoda M, Jaïs P, et al. Mapping and ablation of idiopathic ventricular fibrillation. *Circulation* 2002;106:962–967.
2. Haïssaguerre M, Shah DC, Jaïs P, et al. Role of Purkinje conducting system in triggering idiopathic ventricular fibrillation. *Lancet* 2002;359:677–678.
3. Knecht S, Sacher F, Wright M, et al. Long-term follow-up of idiopathic ventricular fibrillation ablation: a multicenter study. *J Am Coll Cardiol* 2009;54:522–528.
4. Al-Khatib SM, Stevenson WG, Ackerman MJ, et al. 2017 AHA/ACC/HRS guideline for management of patients with ventricular arrhythmias and the prevention of sudden cardiac death: a report of the American College of Cardiology Foundation/American Heart Association Task Force on Clinical Practice Guidelines and the Heart Rhythm Society. *Circulation* 2018;138:e272–e391.
5. Kusumoto FM, Schoenfeld MH, Wilkoff BL, et al. 2017 HRS expert consensus statement on cardiovascular implantable electronic device lead management and extraction. *Heart Rhythm* 2017;14:e503–e551.
6. Crawford T, Mueller G, Good E, et al. Ventricular arrhythmias originating from papillary muscles in the right ventricle. *Heart Rhythm* 2010;7:725–730.
7. Santoro F, Di Biase L, Hranitzky P, et al. Ventricular tachycardia originating from the septal papillary muscle of the right ventricle: electrocardiographic and electrophysiologic characteristics. *J Cardiovasc Electrophysiol* 2015;26:145–150.
8. Sadek MM, Benhayon D, Sureddi R, et al. Idiopathic ventricular arrhythmias originating from the moderator band: electrocardiographic characteristics and treatment by catheter ablation. *Heart Rhythm* 2015;12:67–75.
9. Priori SG, Wilde AA, Horie M, et al. HRS/EHRA/APHRS expert consensus statement on the diagnosis and management of patients with inherited primary arrhythmia syndromes. *Heart Rhythm* 2013;10:1932–1963.
10. Xiao L, Koopmann TT, Ördög B, et al. Unique cardiac Purkinje fiber transient outward current  $\beta$ -subunit comparison: a potential molecular link to idiopathic ventricular fibrillation. *Circ Res* 2013;112:1310–1322.
11. Nishiyama T, Aizawa Y, Ito S, Katsumata Y, Kimura T, Takatsuki S. A subtype of idiopathic ventricular fibrillation and its relevance to catheter ablation and genetic variants. *HeartRhythm Case Rep* 2017;3:277–281.
12. Sherrid MV, Daubert JP. Risks and challenges of implantable cardioverter-defibrillators in young adults. *Prog Cardiovasc Dis* 2008;51:237–263.
13. Mendenhall GS, Saba S. Prophylactic lead extraction at implantable cardioverter-defibrillator generator change. *Circ Arrhythm Electrophysiol* 2014;7:330–336.
14. Lin GA, Fagerlin A. Shared decision making: state of the science. *Circ Cardiovasc Qual Outcomes* 2014;7:328–334.