


## Case Report

# Enzalutamide-induced severe thrombocytopenia complicated by a seizure in a 76-year-old man with castration-resistant prostate cancer

Masaki Murata, Itsuhiro Takizawa, Ryo Maruyama, Takashi Kasahara, Noboru Hara  and Yoshihiko Tomita

Division of Urology, Department of Regenerative and Transplant Medicine, Graduate School of Medical and Dental Sciences, Niigata University, Niigata, Japan

### Abbreviations & Acronyms

ADT = androgen deprivation therapy  
AR = androgen receptor  
CRPC = castration-resistant prostate cancer  
CT = computed tomography  
PSA = prostate-specific antigen

**Correspondence:** Noboru Hara M.D., Ph.D., Division of Urology, Department of Regenerative and Transplant Medicine, Graduate School of Medical and Dental Sciences, Niigata University, 1 Asahimachi, Niigata 951-8510, Japan. Email: harasho@med.niigata-u.ac.jp; noboharasho@par.odn.ne.jp

This is an open access article under the terms of the Creative Commons Attribution-NonCommercial-NoDerivs License, which permits use and distribution in any medium, provided the original work is properly cited, the use is non-commercial and no modifications or adaptations are made.

Received 9 July 2018; accepted 10 October 2018.  
Online publication 31 October 2018

**Introduction:** Adverse events with enzalutamide widely used for men with castration-resistant prostate cancer are of interest.

**Case presentation:** A 76-year-old man developed castration-resistant prostate cancer. He received 160 mg of enzalutamide daily. On the 13th day after treatment, severe thrombocytopenia was observed (platelet count:  $1.9 \times 10^4/\mu\text{L}$ ). Normal coagulation and fibrinolytic systems suggested thrombocytopenia induced by enzalutamide. Enzalutamide was withdrawn immediately, and platelet count uneventfully recovered to  $7.0 \times 10^4/\mu\text{L}$  and  $28.8 \times 10^4/\mu\text{L}$  9 and 30 days after discontinuation, respectively. He restarted enzalutamide therapy without thrombocytopenia recurrence. However, 81 days after restarting enzalutamide, he experienced a seizure. There were no significant findings from brain computed tomography, which suggested that the seizure was also an enzalutamide-associated adverse event.

**Conclusion:** Thrombocytopenia may occur early following enzalutamide therapy, and blood analysis within 2 weeks after treatment may facilitate its management. Enzalutamide-induced thrombocytopenia, complicated by seizure, has not been reported.

**Key words:** castration-resistant prostate cancer, enzalutamide, seizure, severe adverse event, thrombocytopenia.

## Keynote message

Enzalutamide-induced thrombocytopenia may present within 2 weeks after treatment, which suggests that blood cell counts in the early posttreatment period are beneficial. Enzalutamide may be restarted after recovery from thrombocytopenia. Enzalutamide-induced thrombocytopenia may be complicated by seizure.

## Introduction

New agents, such as enzalutamide, that target AR signaling have recently been used for men with CRPC.<sup>1,2</sup>

Enzalutamide is an oral AR-blocking agent developed based on a thiohydantoin derivative and has multiple effects in addition to efficiently blocking AR. Enzalutamide inhibits dimerization and nuclear translocation of AR, AR binding to DNA, and recruitment of cofactors/coactivators to the AR complex.<sup>1–3</sup> Enzalutamide has been associated with specific adverse events. Fatigue is the most frequently observed adverse event (35%), followed by back pain (26–27%), diarrhea (19%), and hot flashes (19%), but they are not severe in most instances.<sup>2,4</sup> Seizure is also an adverse event, but infrequent and reported in less than 0.7% of patients.<sup>1,2</sup> Thrombocytopenia is also a severe adverse event caused by enzalutamide, is exceedingly rare, and may result in death.<sup>5,6</sup> Here, we treated an elderly man with metastatic CRPC, who received enzalutamide therapy, developed severe thrombocytopenia, recovered after enzalutamide withdrawal, but had a seizure after the restart of enzalutamide therapy.

## Case presentation

A 76-year-old man was diagnosed with prostate cancer following PSA screening. He had no past history of neurological or hematological disorders. He had undergone acute myocardial infarction managed by coronary stenting and aspirin therapy, and had an olopatadine allergy. A written informed consent to report this case was obtained from the patient. His baseline PSA level was 40.31 ng/mL, and he had a locally advanced disease by a digital rectal examination, but no node metastasis by CT. Isotope bone scanning revealed multiple bone metastases, and dynamic contrast-enhanced magnetic resonance imaging strongly suggested seminal vesicle involvement. Octant prostate biopsy revealed a Gleason score of 5 + 4 disease in all eight biopsy cores.

He was treated with a gonadotropin-releasing hormone antagonist degarelix and antiandrogen bicalutamide (Fig. 1). The nadir serum PSA level was 0.06 ng/mL; the period from the primary treatment to the PSA nadir was about 4 months, and PSA levels were elevated 12 months after first-line ADT. The bone-modifying agent denosumab was used 4 months after first-line ADT for 18 months, and stopped due to a diagnosis of osteonecrosis in the jaw. Second-line flutamide therapy was withdrawn after 2 months because of liver dysfunction. Laboratory data were checked every 2 months, and no blood/bone marrow toxicity or severe adverse events were observed (Fig. 1).

Subsequently, he received 160 mg of enzalutamide daily as a third-line therapy. Before the induction of enzalutamide, the platelet count was within the normal range ( $29.5 \times 10^4/\mu\text{L}$ ). However, 13 days after starting enzalutamide therapy, it declined markedly ( $1.9 \times 10^4/\mu\text{L}$ ). Normal laboratory findings on the coagulation and fibrinolytic systems and other blood and biochemical analyses suggested thrombocytopenia possibly induced by enzalutamide (Fig. 2). Enzalutamide was withdrawn immediately and the patient was hospitalized. Platelet count decreased further to  $1.0 \times 10^4/\mu\text{L}$  3 days after enzalutamide withdrawal, and gradually increased thereafter

without bleeding events or platelet transfusion. Nine days after discontinuation of enzalutamide, his platelet count was increased to  $7.0 \times 10^4/\mu\text{L}$ , and he was discharged the next day.

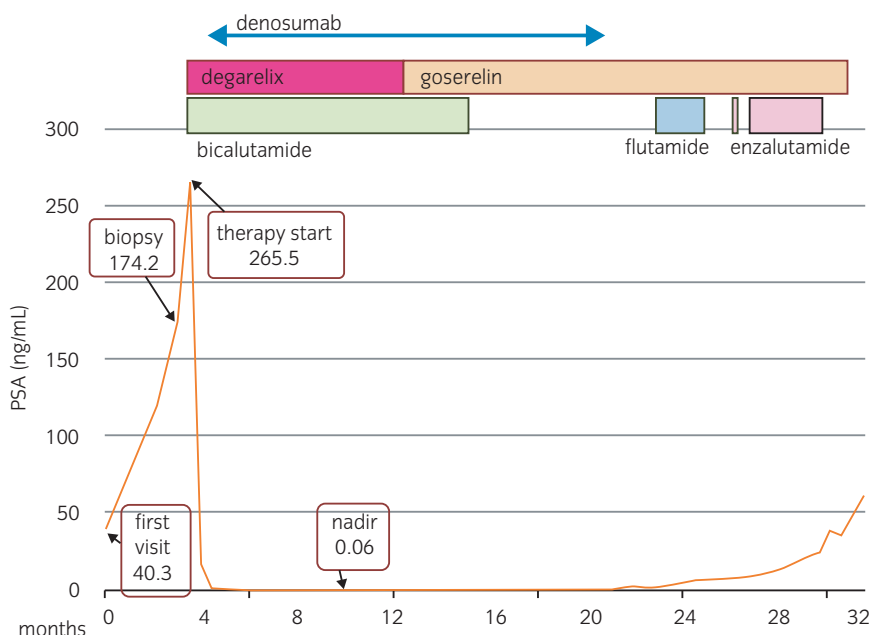
Aspirin therapy also discontinued at the diagnosis of thrombocytopenia, was resumed 7 days after discharge with the confirmation of no bleeding symptoms or disorder in coagulation and fibrinolytic systems. His platelet count recovered to the baseline level ( $28.8 \times 10^4/\mu\text{L}$ ) 30 days after enzalutamide withdrawal, and enzalutamide therapy was restarted at a reduced dose of 80 mg daily (Fig. 2). After restarting enzalutamide, thrombocytopenia did not recur. Due to the persistence of osteonecrosis in the jaw, with possible infections, we did not select chemotherapy or steroid therapy, and enzalutamide was gradually increased to 160 mg daily with PSA levels subsequently decreasing. However, 81 days after restarting enzalutamide, he had a seizure. No significant findings from the brain CT scan and laboratory data suggested that the seizure was an adverse event associated with enzalutamide.

Thereafter, he received estramustine and ethinylestradiol therapies, but both treatments were withdrawn due to drug-induced skin eruptions. He remains alive with palliative treatment, and no additional seizures or neurological disorders occurred for 24 months after the second withdrawal of enzalutamide.

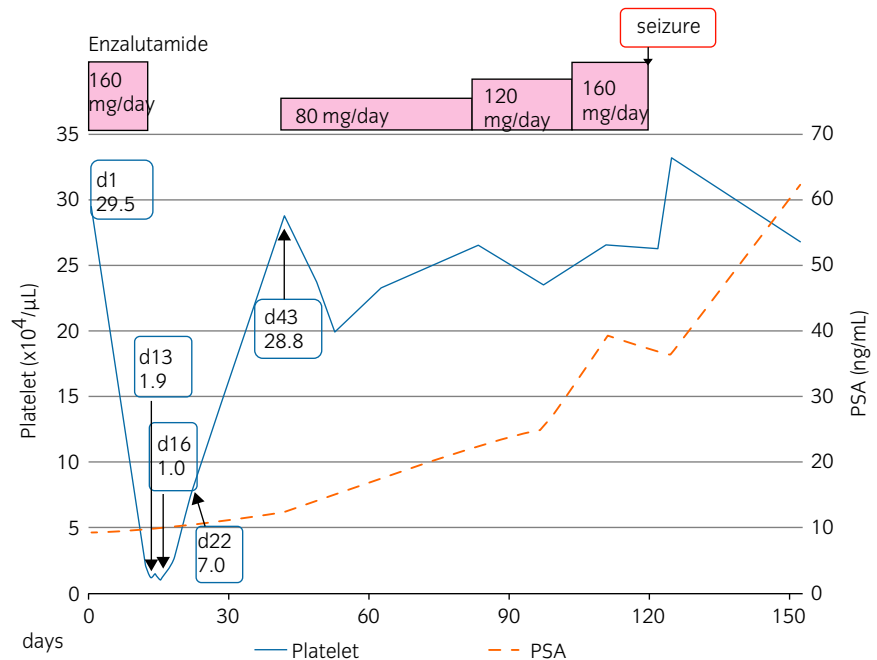
## Discussion

We treated an elderly man with CRPC who developed severe thrombocytopenia, an adverse event possibly associated with enzalutamide therapy, and had a seizure after restarting enzalutamide. These types of adverse events associated with enzalutamide are rare.<sup>1,2,6</sup>

The incidence of moderate-to-severe enzalutamide therapy-related thrombocytopenia is less than 1%. However, there are only a few relevant studies, and its true frequency is



**Fig. 1** Clinical course chart and PSA levels after diagnosis until the induction of enzalutamide.



**Fig. 2** Clinical course chart, platelet count, and PSA levels after the induction of enzalutamide.

unknown.<sup>1</sup> These patients may have been affected by disseminated intravascular coagulation, which is frequently encountered in men with advanced prostate cancer.<sup>1,2,7,8</sup> Although the precise mechanism of thrombocytopenia in our patient was unclear, drug-induced antibodies may be related.<sup>5</sup> There is only one published case report of enzalutamide-induced thrombocytopenia;<sup>6</sup> asymptomatic thrombocytopenia (platelet count:  $1.4 \times 10^4/\mu\text{L}$ ) was observed 2 weeks after starting enzalutamide, and enzalutamide was immediately discontinued. After the platelet count recovered, the patient restarted enzalutamide at a daily dose of 80 mg, and thrombocytopenia did not recur.<sup>6</sup> Similarly, in our case, thrombocytopenia was diagnosed about 2 weeks after the induction of enzalutamide therapy, which suggests that blood analyses are important during the early posttreatment period. Thrombocytopenia also did not recur in our patient after restarting enzalutamide at a reduced dose with subsequent gradual increases.

Seizures are infrequent adverse events caused by enzalutamide, and the incidence is about 0.1–0.7%.<sup>1,2,9</sup> The inhibition of  $\gamma$ -aminobutyric acid-gated chloride channel by enzalutamide may be the mechanism of seizure.<sup>9</sup> Thus, enzalutamide should be administered with particular care in men with a history of seizure or brain disease. Our patient had no neurological disorders, but enzalutamide treatment was stopped following a seizure because controlling seizures during enzalutamide treatment is difficult.<sup>9</sup>

Our patient had an olopatadine allergy. Although the association of drug allergy with enzalutamide-induced thrombocytopenia or seizure is unknown, patients with drug allergies may develop multiple adverse events during enzalutamide therapy. Thus, further studies are warranted for off-target effects of this agent.

## Conclusion

This is the first report of a patient who developed thrombocytopenia and a seizure during enzalutamide therapy.

Thrombocytopenia may occur early during enzalutamide therapy, which suggests that blood analysis within 2 weeks after treatment may facilitate enzalutamide therapy management. In men with enzalutamide-induced thrombocytopenia, enzalutamide can be restarted with careful observation. However, the present case also suggests the need for particular care about other severe adverse events, such as seizures, for men receiving this agent.

## Conflict of interest

The authors declare no conflict of interest.

## References

- Merseburger AS, Haas GP, von Klot CA. An update on enzalutamide in the treatment of prostate cancer. *Ther. Adv. Urol.* 2015; 7: 9–21.
- Scher HI, Fizazi K, Saad F *et al.* Increased survival with enzalutamide in prostate cancer after chemotherapy. *N. Engl. J. Med.* 2012; **367**: 1187–97.
- Tran C, Ouk S, Clegg NJ *et al.* Development of a second-generation antiandrogen for treatment of advanced prostate cancer. *Science* 2009; **324**: 787–90.
- Beer TM, Armstrong AJ, Rathkopf DE *et al.* Enzalutamide in metastatic prostate cancer before chemotherapy. *N. Engl. J. Med.* 2014; **371**: 424–33.
- Aster RH, Bougie DW. Drug-induced immune thrombocytopenia. *N. Engl. J. Med.* 2007; **357**: 580–7.
- Sato A, Kosaka T, Oya M. Continuous use of enzalutamide in a patient who developed enzalutamide-induced thrombocytopenia. *BMJ Case Rep.* 2015; **2015**: bcr2015212567.
- Ong SY, Taverna J, Jakerst C *et al.* Prostate cancer-associated disseminated intravascular coagulation with excessive fibrinolysis treated with degarelix. *Case Rep. Oncol. Med.* 2015; **2015**: 212543.
- Duran I, Tannock IF. Disseminated intravascular coagulation as the presenting sign of metastatic prostate cancer. *J. Gen. Intern. Med.* 2006; **21**: C6–8.
- Ning YM, Brave M, Maher VE *et al.* U.S. Food and Drug Administration approval summary: enzalutamide for the treatment of patients with chemotherapy-naïve metastatic castration-resistant prostate cancer. *Oncologist* 2015; **20**: 960–6.