

## Research Article

# Histological Correlation of Glandular Abnormalities in Cervical Liquid-Based Cytology

**Yosuke Kawakami,<sup>1,2</sup> Tamaki Toda,<sup>3</sup> Toshinao Nishimura,<sup>3</sup> Junichi Sakane,<sup>3</sup>  
Kazuya Kuraoka,<sup>3</sup> Kazuhiro Takehara,<sup>2</sup> Tomoya Mizunoe,<sup>2</sup> and Kiyomi Taniyama<sup>1</sup>**

<sup>1</sup>*Institute for Clinical Research, National Hospital Organization Japan, Kure Medical Center/Chugoku Cancer Center, 3-1 Aoyama-Cho, Kure-City, Hiroshima 737-0023, Japan*

<sup>2</sup>*Department of Obstetrics and Gynecology, National Hospital Organization Japan, Kure Medical Center/Chugoku Cancer Center, 3-1 Aoyama-Cho, Kure-City, Hiroshima 737-0023, Japan*

<sup>3</sup>*Department of Diagnostic Pathology, National Hospital Organization Japan, Kure Medical Center/Chugoku Cancer Center, 3-1 Aoyama-Cho, Kure-City, Hiroshima 737-0023, Japan*

Correspondence should be addressed to Kiyomi Taniyama, taniyamak@kure-nh.go.jp

Received 2 February 2011; Accepted 12 June 2011

Academic Editor: Nirag Jhala

Copyright © 2011 Yosuke Kawakami et al. This is an open access article distributed under the Creative Commons Attribution License, which permits unrestricted use, distribution, and reproduction in any medium, provided the original work is properly cited.

Conventional Papanicolaou smear method is still commonly used for cervical cancer screening in Japan, despite the liquid-based cytology (LBC) that has become a global tendency in the world recently. One of the obstacles in the way of popularization of this method seems to be the confusion as to diagnosis upon cervical glandular lesions. We performed comparison study between LBC and conventional Papanicolaou smear about cytological diagnosis using split-sample method in 4522 patients. In 13 cases analyses, which were reported with either AGC or adenocarcinoma by either method, LBC tends to be milder than that by conventional smear, however, the credibility of LBC is considered to be near to that of conventional smear with regard to screening for glandular abnormalities. These results indicate that cervical cancer screening should shift to LBC under the enough experience and appropriate dealing with the cytological diagnosis.

## 1. Introduction

Uterine cervical cancer is still the most commonly diagnosed cancer among women worldwide, taking second place only after breast cancer [1–4]. The incidence and mortality from cervical cancer decreased considerably in most industrial countries due to lower incidence and the introduction of screening [5, 6]. On the other hand, malignant or precancerous lesions of glandular cells in uterine cervix are increasing recently, as reported that the incidence of adenocarcinoma of Japan is 16.8% in 2009, and many studies reported higher mortality rate of cervical adenocarcinoma [7–12]. The screenings of the glandular lesions are thought to be difficult in comparison with those of the squamous epithelium type, although those early diagnoses become more important for prognosis improvement.

In late years, Japan Association of Obstetricians and Gynecologists announced a standardized system of terminol-

ogy reflected by the Bethesda system (TBS) and the screening of cervical lesions are being performed based on this system [13]. In this new Japanese system, increasing numbers of facilities come to use LBC, which is a global tendency, despite the premise to use conventional smears for sampling. In many reports of the comparison studies between LBC and conventional smear with clinical and histological followups, LBC is better than conventional smear in detecting biopsy-proven disease and in screening out benign abnormalities in terms of squamous lesions [14–22]. However, it still remains unclear how to evaluate the cytological diagnosis of the glandular lesion in the new system using LBC.

We recently started TBS application using both of conventional smears and the liquid-based cytology as a multicenter study which simultaneously investigates HPV infection. In this study, we examined the correlation between conventional smears and LBC in the cytological diagnosis of the glandular lesion in order to make it clear whether LBC has

TABLE 1: Relationship between conventional smear and ThinPrep method.

	ThinPrep (TP)												
	NILM	ASC-US	ASC-H	AGC	LSIL	HSIL	HSILw/FSFI	AIS	SCC	ADC	ADSQ	Total	
Conventional Smear (CS)	NILM	<b>3985</b>	35	1	1	33	7	0	0	0	0	4062	
	ASC-US	47	<b>12</b>	0	0	10	2	0	0	0	0	71	
	ASC-H	2	2	<b>1</b>	0	2	1	1	0	0	0	9	
	AGC	5	1	0	<b>2</b>	0	0	0	0	0	0	8	
	LSIL	73	17	0	0	<b>104</b>	27	0	0	0	0	221	
	HSIL	5	4	0	0	19	<b>77</b>	2	0	5	0	112	
	HSILw/FSFI	0	0	1	0	0	0	<b>0</b>	0	0	0	3	
	AIS	0	0	0	0	0	0	0	<b>0</b>	0	0	0	
	SCC	1	0	0	0	0	4	2	0	<b>15</b>	0	0	25
	ADC	1	1	0	3	0	0	0	0	1	<b>2</b>	0	10
	ADSQ	0	0	0	0	0	0	0	0	0	0	<b>1</b>	1
	Total	4119	72	3	6	168	120	5	0	25	4	0	4522

NILM: negative for intraepithelial lesion or malignancy; ASC-US: atypical squamous cells of undetermined significance; ASC-H: atypical squamous cells, cannot exclude high-grade squamous intraepithelial lesion; AGC: atypical glandular cells; LSIL: low-grade intraepithelial cells; HSIL: high-grade intraepithelial lesion; FSFI: HSIL features suspicious for invasion; AIS: adenocarcinoma in-situ; SCC: squamous cell carcinoma; ADC: adenocarcinoma; ADSQ: adenosquamous cell carcinoma.

the diagnosis precision that is equivalent to conventional smear.

## 2. Materials and Methods

At eight institutions in Hiroshima prefecture, including the key institution, National Hospital Organization, Japan, and Kure Medical Center/Chugoku Cancer Center (NHOKM-CCCC), from November 2007 to July 2009, 4522 cases were retrieved and analyzed as split-sample studies. Initially, smears were taken in the routine fashion using EndoCervex-Brush (Rovers Medical Devices B. V., Oss, The Netherlands) in each institution, fixed either by immersion in 95% ethanol or by spray fixation with a pump-action spray, and preserved before staining (conventional smear, CS). The residual cells remaining on the sampler were rinsed into vials containing 20 mL of preservative, then, sent to the key institution, followed by the treatment according to the ThinPrep (Hologic, Marlborough, Mass, USA) protocol (ThinPrep, TP). An additional sample was obtained with a dacron swab and placed in specimen transport medium (STM) for future human papillomavirus (HPV) DNA testing. Specimens prepared by each method underwent Papanicolaou staining and was enclosed.

The specimens are initially screened by cytotechnologists in the manner of TBS. The screening was performed as blinded experiment, namely, each specimen by the CS or TP method was diagnosed by the other screener, which did not know the information by the other methods nor HPV data. Possibly abnormal specimens are referred to senior cytotechnologists and cytopathologists for review. The specimens diagnosed as abnormal in each institution were shipped to the key institution to be reviewed by the

central committee, which consists of the senior pathologists, for determining the final cytological diagnosis. Prior to the study, all the cytotechnologists and the cytopathologists were engaged in this study who trained in the use of TBS and acquired the certification of ThinPrep test presided over in Cytyc Co. (Marlborough, Mass).

Histological examination was also performed in some cases following the cytology or after few periods, if required for clinical reason. The histological diagnosis was made by pathologist independently from cytology. In all the cases other than NILM, which were diagnosed by either CS and/or TP method, cancer-associated 16 HPV genotyping (types 16, 58, 52, 51, 56, 31, 18, 39, 66, 59, 6, 33, 30, 35, 45, and 11) was performed by multiplex PCR as described previously using the remaining samples in the TP preservative fluid [23]. All the institutions have full reviews and approvals from respective Institutional Review Boards. Statistical analyses were performed in the key institution. Photographs of cytology by CS and TP as well as histological ones were displayed in representative cases.

## 3. Results

We initially performed analysis in all the lesions of the samples, including squamous ones, prior to the analysis specific for glandular lesions. The cytological diagnosis in TBS by CS or TP method in all the 4522 cases is shown in Table 1. The average age of the patients was 46.1. Patients who consulted due to medical checkup were 13.8% and those who had any complaints were 89.3%. The number of cases which diagnosed positive was 460 (10.2%) by CS and 403 (8.9%) by TP. Cytologically positive cases by each method were categorized as follows: 49 cases of ASC (1.1%), 5 cases

TABLE 2: Up-graded case by ThinPrep method.

Conventional smear		ThinPrep								
	Number	ASC-US	ASC-H	AGC	LSIL	HSIL	FSFI	SCC/ADC	Up-grading by TP	
NILM	4062	35	1	1	33	7	0	0	77	1.90%
ASC-US	71	—	—	—	10	2	0	0	12	16.90%
ASC-H	9	—	—	—	2	1	1	0	4	44.40%
AGC	8	—	—	—	0	0	0	0	0	—
LSIL	221	—	—	—	—	27	0	0	27	12.20%
HSIL	112	—	—	—	—	—	2	5	7	6.30%
Total	4483	35	1	1	45	37	3	5	127	2.80%

TABLE 3: Up-graded case by conventional smear method.

ThinPrep		Conventional smear								
	Number	ASC-US	ASC-H	AGC	LSIL	HSIL	FSFI	SCC/ADC	Up-grading by TP	
NILM	4119	47	2	5	73	5	0	2	134	3.30%
ASC-US	72	—	—	—	17	4	0	1	22	30.60%
ASC-H	3	—	—	—	0	0	1	0	1	33.30%
AGC	6	—	—	—	0	0	0	3	3	50.00%
LSIL	168	—	—	—	—	19	0	0	19	11.30%
HSIL	120	—	—	—	—	—	2	4	6	5.00%
Total	4488	47	2	5	90	28	3	10	185	4.10%

TABLE 4: Glandular abnormalities in TBS.

Case	Age	CS	TP	HPV	Histology in cervical biopsy
1	27	NILM	AGC	(-)	Endometrial polyp
2	38	AGC	NILM	56+	ND
3	54	AGC	NILM	16+	Atypical endometrial hyperplasia <sup>a</sup>
4	25	AGC	NILM	(-)	ND
5	61	AGC	NILM	(-)	ND
6	50	AGC	AGC	52+	Endometrioid adenoca, G2 <sup>a</sup>
7	36	AGC	AGC	16+	ND
8	42	AGC	NILM	(-)	Mild glandular dysplasia
9	74	AGC	ASC-US	(-)	clear cell carcinoma
10	58	AdenoCa	AGC	(-)	ND
11	40	AdenoCa	AdenoCa	(-)	Endometrioid adenoca, G1 <sup>a</sup>
12	65	AdenoCa	AGC	(-)	Endometrioid adenoca, G1>G2 <sup>a</sup>
13	74	AdenoCa	AGC	(-)	Ovarian cancer <sup>b</sup>

<sup>a</sup>Disease existed in uterine corpus diagnosed in surgical samples.

<sup>b</sup>Diagnosed in surgical samples.

of AGC (0.11%), 73 cases of LSIL (1.7%), 5 cases of HSIL (0.11%), 1 case of SCC (0.02%), 1 case of ADC (0.02%) in CS, 36 cases of ASC (0.8%), 1 cases of AGC (0.02%), 33 cases of LSIL (0.7%), and 7 cases of HSIL (0.15%), neither cases of SCC nor ADC in TP were reported. There was no large variation of distribution of each category in each method. The diagnoses by TP and CS corresponded with each other in 4198 cases (92.8%).

Discrepancies in the diagnosis between CS and TP were shown in Tables 2 and 3. There were 7 cases in which TP method revealed HSIL and more, and CS was negative, as

well as 7 cases in whom HSIL and more were detected with CS alone. All the other cases diagnosed as positive, either TP or CS alone, were 77 and 134, respectively. In the comparison between CS and TP methods of all the cases, 127 (2.8%) were up-graded by TP and 185 (4.1%) were up-graded by CS. Within the limits of HSIL, FSFI, and SCC/SDC up-grading was observed in 45 (1.0%) cases by TP and in 41 (0.9%) cases in CS.

Table 4 presents the glandular abnormalities detected by either TP or CS. Thirteen cases were reported with either AGC or adenocarcinoma, including 12 cases diagnosed by

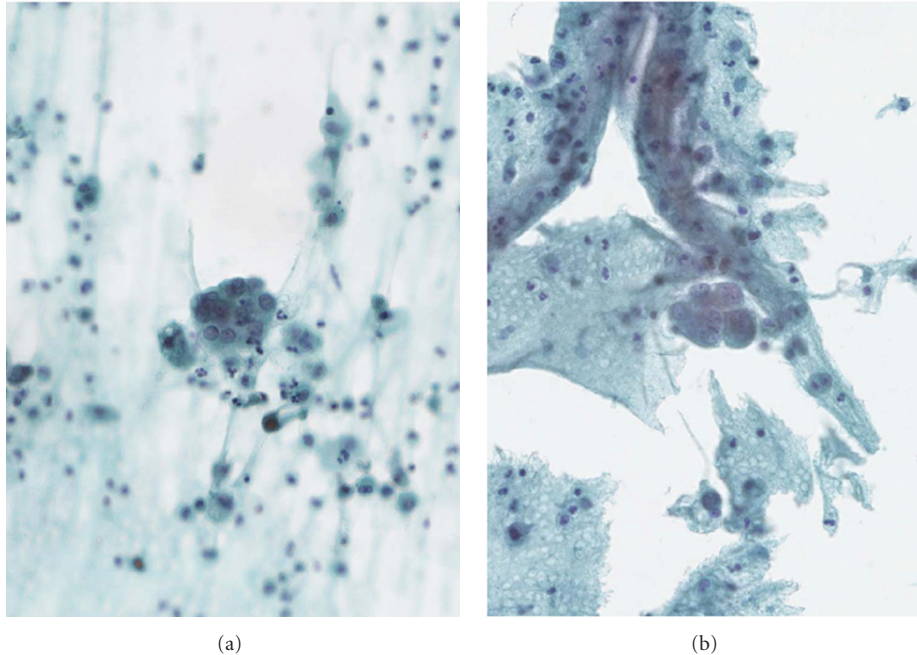


FIGURE 1: Case 9. (a) CS method. A small-crowded cluster is comprised of atypical cells, which have relatively distinct nuclei with indented outlines, suggesting AGC. (b) TP method. Marginal number of atypical cells with dense cytosol in small monolayer cluster were diagnosed as ASC-US (Papanicolaou; original magnification, x600, resp.).

CS and eight cases by TP. Seven cases were diagnosed as either AGC or adenocarcinoma by both CS and TP methods. Among eight cases which were diagnosed as AGC by CS, four were NILM, one was ASC-US, and two were AGC by TP. Similarly, three cases were diagnosed AGC and one case was adenocarcinoma by TP out of four cases which were adenocarcinoma by TP. Thus, this shows that the diagnosis by TP tends to be milder than that by CS in terms of glandular abnormalities. Histological final diagnoses were obtained from either surgical or biopsy samples in eight cases; one benign, two hyperplastic, and five malignant glandular lesions in the 12 cases. There is also one additional case in which glandular abnormality was suspected due to the presence of HPV infection. TP identified six (66.7%) cases as either AGC or adenocarcinoma in these nine cases presenting glandular abnormality, as CS did all nine cases. With regard to screening for glandular abnormalities, the credibility of TP method is considered to be near to that of CS. Representative microscopic field of cytological samples from CS or TP method are exhibited in Figures 1 and 2.

#### 4. Discussion

LBC preparation was approved for use originally in the United States in 1996, reported to reduce the number of false-positive and false-negative smear results by the reason of overcoming several drawbacks in conventional Papanicolaou smear samples [22]. Also, it is one of the large advantages of LBC that remaining specimen can be used for the additional examination like HPV genotyping. In Japan, conventional smear had been used for the screening until recently, but

many institutions have begun LBC in combination to TBS and HPV DNA testing for past a few years. LBC seems to become more and more general method for cervical cancer screening in the future. On the other hand, it is a weak point of LBC that evaluation of glandular abnormalities is not carried out enough. It is reasonable to investigate the capability for diagnosis of glandular abnormalities in cervix, which may become more important disease due to increasing number of the patients.

In this study, there were not so much differences between CS and TP in the detection rate of each category of positive cases. Also, the detection rate of all the positive cases by either CS or TP was similar to that reported previously [20, 21, 24]. In nine cases analyses, in which AGC or adenocarcinoma were considered by histological examination or HPV infection status, screening as the abnormality to be AGC or more was possible in nine cases by CS and in six cases by TP; thus, CS method seems to be better in the point of accuracy for screening. However, no typical cytological features, which were considered to be cause of oversight, were observed in TP samples. It is confirmed that CS would be equivalent to TP, if only good enough quality of specimen is provided.

On the other hand, the actual numbers of glandular abnormalities are extremely low—only 13 cases in total, with only eight cases with histological followup in this study, including even more than 4000 total cases. These numbers may be low and difficult to perform statistical analysis on, or draw definite conclusions from. The incidence of cervical adenocarcinoma in Japan accounts for 16.8% of whole cervical cancer as described, and this may not correspond to the number of cases of the glandular abnormality

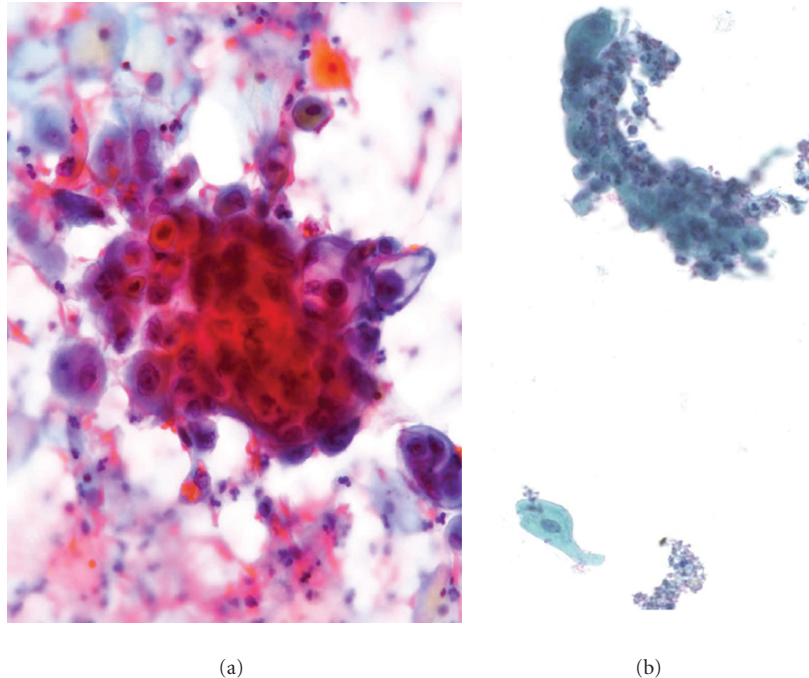


FIGURE 2: Case 12. (a) CS method. A loosely cohesive and crowded tissue fragment displays malignant cells, which have sharp-ended nuclei with enlarged nucleoli, in the myxoid and collagenized matrix, as considered to be adenocarcinoma. (b) TP method. A small number of clusters with irregularly crowded atypical cells are observed in the background, which is clean and devoid of single cells. Since no other such a cluster was observed in the specimen, this case was diagnosed as AGC (Papanicolaou; original magnification, x600, resp.).

having been low in this study. However, in early-stage and the precancerous adenocarcinoma, the cytology is used as adjuvant method in clinical settings, and it seems that the cytological diagnosis rate is lower than a real incidence. Since the numbers limited a thorough statistical analysis and benefits might not provide a true reflection of the value, they were not presented in this study. Also, while it would be appropriate to stratify AGC cases according to the Bethesda Classification, however, in our setting diagnosis of AGC, regardless of the type, would have necessitated further investigations/followup so that patient would not be placed at a disservice as Pap smears is generally considered as a screening modality.

It was thought that the TP method was superior if we considered equalization of the specimen manufacture and additive work (e.g., immunostaining/FISH/HPV DNA test). Therefore, it is important for the screeners to learn the TP and to get enough experience, when it shifts from the CS to TP.

## 5. Conclusion

In summary, this study extends previous work suggesting that the TP method may become at least as good as CS in detecting glandular lesions, with enough case experience and well mastering the criteria. Considering about the clinical advantages of LBC, it is desirable that TP should be popularized under the enough experience of this method to avoid the confusion about the cytological diagnosis. Based

on these results, further larger-scaled studying of this kind would be encouraged to lead more positive conclusions.

## Acknowledgments

The authors thank doctors Makoto Motoi, Hiroshi Sonobe, Yoshiro Tachiyama, Makoto Nagasaki, Ryouji Hayase, Hideo Fujimoto, Kunihiro Omonisi, Nobutaka Nagai, and Shoko Ishimoto for provision of study materials and patients, and Ms. Eiko Tanimoto, Yoshimi Shitakubo, Mikie Shitaune, Yoko Kodama, and Yoshiko Kimura for collection and assembly of data. This work was supported by a Grant from National Hospital Organization Japan and a Grant-in-Aid from Ministry of Health, Labor and Welfare of Japan.

## References

- [1] D. M. Parkin, F. Bray, J. Ferlay, and P. Pisani, "Global cancer statistics, 2002," *Ca-A Cancer Journal for Clinicians*, vol. 55, no. 2, pp. 74–108, 2005.
- [2] A. Figo, "Cervical cancer prevention in low-resource settings," *International Journal of Gynecology and Obstetrics*, vol. 90, no. 1, pp. 86–87, 2005.
- [3] M. A. Quinn, J. L. Benedet, F. Odicino et al., "Carcinoma of the cervix uteri. FIGO 6th Annual Report on the results of treatment in gynecological cancer," *International Journal of Gynecology & Obstetrics*, vol. 95, supplement 1, pp. 43–103, 2006.
- [4] R. Sankaranarayanan, "Overview of cervical cancer in the developing world. FIGO 6th Annual Report on the results of treatment in gynecological cancer," *International Journal of*

- Gynecology & Obstetrics*, vol. 95, supplement 1, pp. 205–210, 2006.
- [5] M. Arbyn, A. O. Raifu, E. Weiderpass, F. Bray, and A. Anttila, “Trends of cervical cancer mortality in the member states of the European Union,” *European Journal of Cancer*, vol. 45, no. 15, pp. 2640–2648, 2009.
  - [6] American Cancer Society, *Cancer Facts & Figures 2010*, American Cancer Society, 2010.
  - [7] S. Liu, R. Semenciw, A. Probert, and Y. Mao, “Cervical cancer in Canada: changing patterns in incidence and mortality,” *International Journal of Gynecological Cancer*, vol. 11, no. 1, pp. 24–31, 2001.
  - [8] B. E. Miller, S. D. Flax, K. Arheart, and G. Photopoulos, “The presentation of adenocarcinoma of the uterine cervix,” *Cancer*, vol. 72, no. 4, pp. 1281–1285, 1993.
  - [9] R. K. Peters, A. Chao, and T. M. Mack, “Increased frequency of adenocarcinoma of the uterine cervix in young women in Los Angeles County,” *Journal of the National Cancer Institute*, vol. 76, no. 3, pp. 423–428, 1986.
  - [10] S. M. Schwartz and N. S. Weiss, “Increased incidence of adenocarcinoma of the cervix in young women in the United States,” *American Journal of Epidemiology*, vol. 124, no. 6, pp. 1045–1047, 1986.
  - [11] H. O. Smith, M. F. Tiffany, C. R. Qualls, and C. R. Key, “The rising incidence of adenocarcinoma relative to squamous cell carcinoma of the uterine cervix in the United States—a 24-year population-based study,” *Gynecologic Oncology*, vol. 78, no. 2, pp. 97–105, 2000.
  - [12] Japanese Society of Obstetrics and Gynecology, “Patient Annual Report 2009,” *Acta Obstetrica et Gynecologica*, vol. 63, no. 3, pp. 1055–1099, 2011.
  - [13] Japanese Society of Obstetrics and Gynecology, “The guideline of cytological reporting based on the Bethesda System 2001,” 2008.
  - [14] A. K. Adhya, V. Mahesha, R. Srinivasan et al., “Atypical glandular cells in cervical smears: histological correlation and a suggested plan of management based on age of the patient in a low-resource setting,” *Cytopathology*, vol. 20, no. 6, pp. 375–379, 2009.
  - [15] N. I. Mood, Z. Eftekhari, A. Haratian, L. Saeedi, P. Rahimi-Moghaddam, and F. Yarandi, “A cytohistologic study of atypical glandular cells detected in cervical smears during cervical screening tests in Iran,” *International Journal of Gynecological Cancer*, vol. 16, no. 1, pp. 257–261, 2006.
  - [16] H. S. Mitchell, “Outcome after a cytological prediction of glandular abnormality,” *Australian and New Zealand Journal of Obstetrics and Gynaecology*, vol. 44, no. 5, pp. 436–440, 2004.
  - [17] P. J. J. M. Klinkhamer, W. J. Meerding, P. F. W. M. Rosier, and A. G. J. M. Hanselaar, “Liquid-based cervical cytology: a review of the literature with methods of evidence-based medicine,” *Cancer*, vol. 99, no. 5, pp. 263–271, 2003.
  - [18] J. S. Bentz, L. R. Rowe, E. V. Gopez, and C. J. Marshall, “The unsatisfactory ThinPrep Pap Test missed opportunity for disease detection?” *American Journal of Clinical Pathology*, vol. 117, no. 3, pp. 457–463, 2002.
  - [19] L. Minge, M. Fleming, T. VanGeem, and J. W. Bishop, “AutoCyte Prep system vs. conventional cervical cytology: comparison based on 2,156 cases,” *Journal of Reproductive Medicine for the Obstetrician and Gynecologist*, vol. 45, no. 3, pp. 179–184, 2000.
  - [20] M. L. Hutchinson, D. J. Zahniser, M. E. Sherman et al., “Utility of liquid-based cytology for cervical carcinoma screening: results of a population-based study conducted in a region of Costa Rica with a high incidence of cervical carcinoma,” *Cancer*, vol. 87, no. 2, pp. 48–55, 1999.
  - [21] A. B. Carpenter and D. D. Davey, “ThinPrep Pap test: performance and biopsy follow-up in a University Hospital,” *Cancer*, vol. 87, no. 3, pp. 105–112, 1999.
  - [22] K. R. Lee, R. Ashfaq, G. G. Birdsong, M. E. Corkill, K. M. McIntosh, and S. L. Inhorn, “Comparison of conventional Papanicolaou smears and a fluid-based, thin-layer system for cervical cancer screening,” *Obstetrics and Gynecology*, vol. 90, no. 2, pp. 278–284, 1997.
  - [23] M. Nishiwaki, T. Yamamoto, S. Tone et al., “Genotyping of human papillomaviruses by a novel one-step typing method with multiplex PCR and clinical applications,” *Journal of Clinical Microbiology*, vol. 46, no. 4, pp. 1161–1168, 2008.
  - [24] A. J. M. van Aspert-van Erp, F. M. M. Smedts, and G. P. Vooijs, “Severe cervical glandular cell lesions and severe cervical combined lesions: predictive value of the Papanicolaou smear,” *Cancer*, vol. 102, no. 4, pp. 210–217, 2004.